

Successful Cord Blood Stem Cell Transplantation for an Adult Case of Chronic Active Epstein-Barr Virus Infection

Masuhō Saburi, Masao Ogata, Takako Satou, Natsumi Yoshida, Kentaro Nagamatsu, Yuko Nashimoto, Yui Moroga, Kuniko Takano, Kazuhiro Kohno and Kuniaki Shirao

Abstract

A 41-year-old man was referred to our hospital for treatment of anaplastic lymphoma kinase (ALK)-negative anaplastic large cell lymphoma. Chronic active Epstein-Barr virus (CAEBV) was diagnosed based on the findings of elevated EBV antibody titers and positive EBV-DNA in the peripheral blood, and cord blood stem cell transplantation (CBT) was performed. The EBV-DNA levels in the blood fell below the limit of detection. His lymphoma relapsed on Day 165 with the appearance of eruptions, which disappeared after the withdrawal of tacrolimus. One year after transplantation, there were no signs of recurrence. This encouraging result suggests that CBT should be considered for adult cases of CAEBV with aggressive clinical manifestations.

Key words: chronic active Epstein-Barr virus infection, adult, cord blood stem cell transplantation

(Intern Med 55: 3499-3504, 2016)

(DOI: 10.2169/internalmedicine.55.7432)

Introduction

Chronic active Epstein-Barr virus (CAEBV) infection is characterized by persistent or recurrent infectious mononucleosis-like symptoms and by the chronic proliferation of Epstein-Barr virus (EBV)-infected T/NK cells. Most cases of CAEBV are reported in childhood, and little is known about the characteristics or the treatment strategies for adult cases. Patients with CAEBV occasionally develop hemophagocytic lymphohistiocytosis and hematopoietic malignancies. Allogeneic hematopoietic stem cell transplantation (allo-HSCT) is considered a curative treatment option. Although unrelated bone marrow is considered the first choice of stem cell source for patients who do not have an human leucocyte antigen (HLA)-identical sibling donor, the long period required for donor coordination makes it difficult for patients with aggressive disease to receive HSCT. Cord blood is an alternative stem cell source, and less time is needed for donor coordination. There have only been a few reports of adult cases of CAEBV receiving cord blood

stem cell transplantation (CBT). We herein describe a case of a 41-year-old man who received CBT for the treatment of aggressive CAEBV.

Case Report

A 41-year-old man was referred to our hospital for a gingival tumor. His clinical history started in 1980 at the age of 6 years, when he developed an occasional fever and numerous recurrent, pea-sized, erythematous nodules and papules on his face and extremities, which then spread to his whole body and were exacerbated by sun exposure and insect bites. In 1987, at the age of 13, he was diagnosed by our hospital dermatology division with hydroa vacciniforme (HV) associated with lymphomatoid papulosis-like eruptions, and he was treated with prednisolone (PSL) and cyclophosphamide (1). Iwatsuki et al. have shown that EBV can be detected in the dermal tissue using *in situ* hybridization and a polymerase chain reaction (PCR) (2). In 1996, at 23 years of age, he was diagnosed with EBV-associated cutaneous T-cell lymphoproliferative disorder. He was also ob-

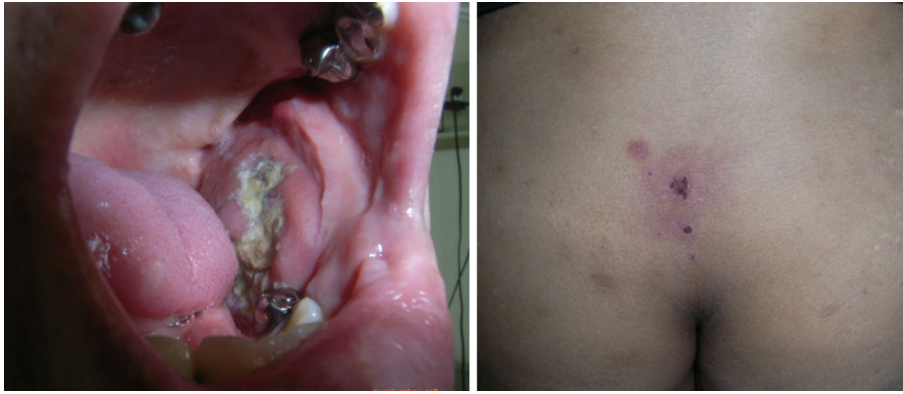


Figure 1. Macroscopic findings of gingival mass and gluteal skin eruptions.

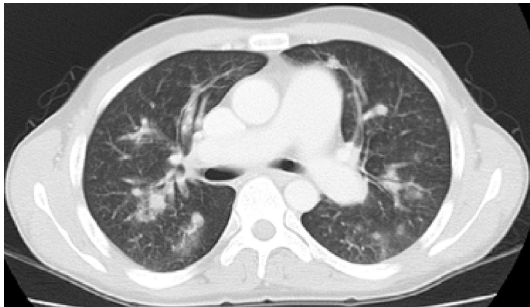

Figure 2. Computed tomography shows multiple pulmonary nodule shadows in whole lung fields.

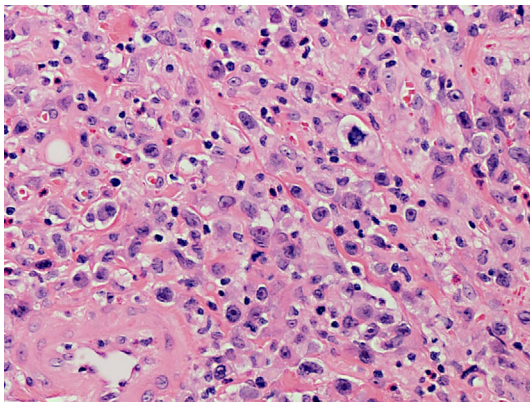


Figure 4. Histological study of gingival mass (original magnification, $\times 200$): Atypical lymphocytes diffusely invade to muscular layer.

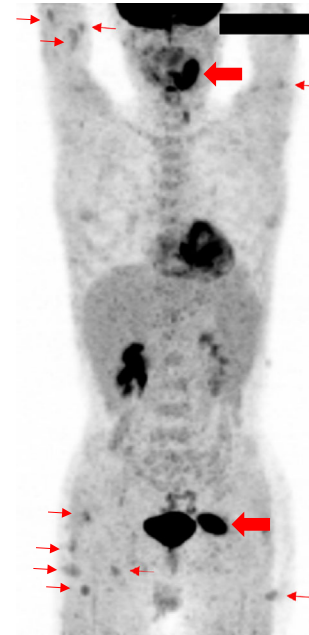


Figure 3. ^{18}F -fluorodeoxyglucose positron emission tomography (FDG-PET) shows FDG accumulation in the gingival mass, the systemic eruptions, and the gluteal muscle. Multiple pulmonary nodules show poor FDG avidity on FDG-PET image.

served by other hospital teams. In March 2003, he developed a cerebellar hemorrhage of unknown etiology and underwent surgical removal of the hematoma. At that time, his EBV-DNA levels in the peripheral blood were 8.9×10^4 copies/ 10^6 cells.

In May 2014, at 41 years of age, he complained of abdominal pain with fever, which was found to be due to cholecystitis. Multiple pulmonary nodule shadows, hepatosplenomegaly, and a gingival mass were noted (Fig. 1, 2). ^{18}F -fluorodeoxyglucose positron emission tomography (FDG-PET) showed FDG accumulation in the gingival mass, the

systemic eruptions, and the gluteal muscle (Fig. 3). A pathological examination of the mass revealed the growth of atypical lymphocytes that were positive for CD3 (partial), CD4 (partial), CD30, MUM1, granzyme B, and TIA-1 and negative for CD79a, CD20, CD8, CD56, and anaplastic lymphoma kinase (ALK) on immunostaining. EBV-encoded small RNA *in situ* hybridization (EBER-ISH) was positive in atypical lymphocytes (Fig. 4, 5). Given these findings, ALK-negative anaplastic large cell lymphoma was diagnosed.

After two courses of etoposide, prednisolone, vincristine, cyclophosphamide, and doxorubicin (EPOCH) therapy, the gingival mass rapidly decreased in size, and the lung nodules disappeared. However, his fever persisted, and the levels of serum hepatobiliary enzymes increased. CAEBV was

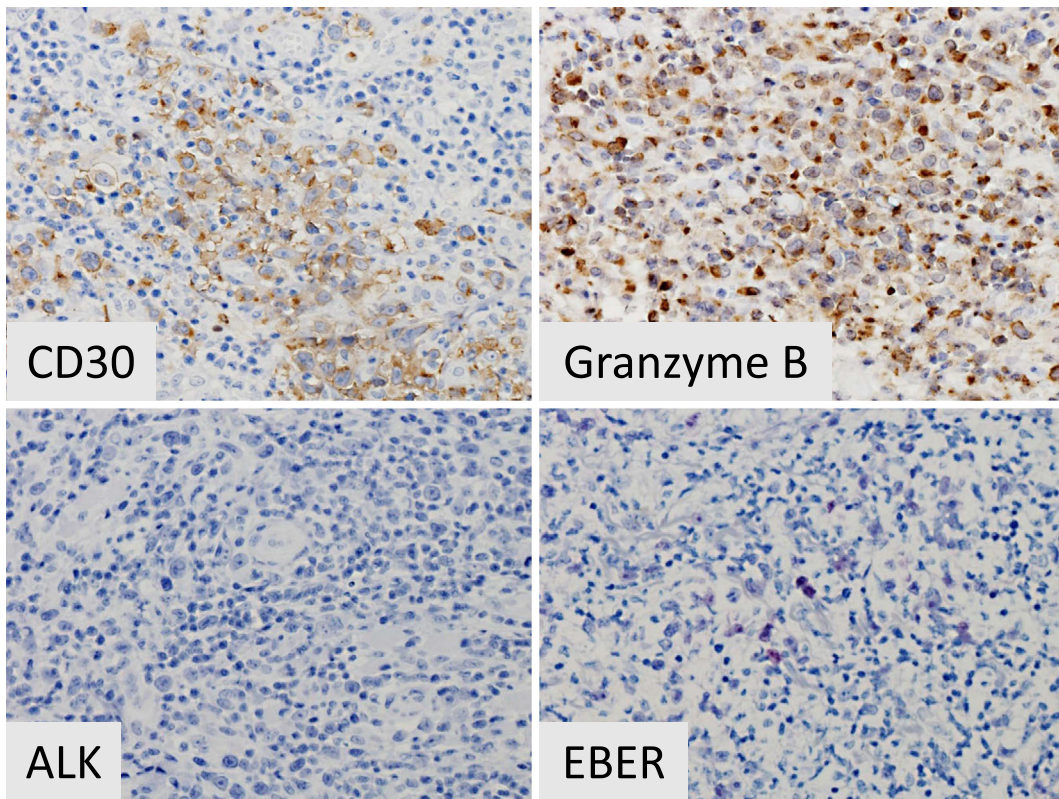


Figure 5. Immunohistochemical studies and EBER-ISH of gingival mass: CD30⁺, granzyme B⁺, ALK⁻, and EBER-ISH⁺.

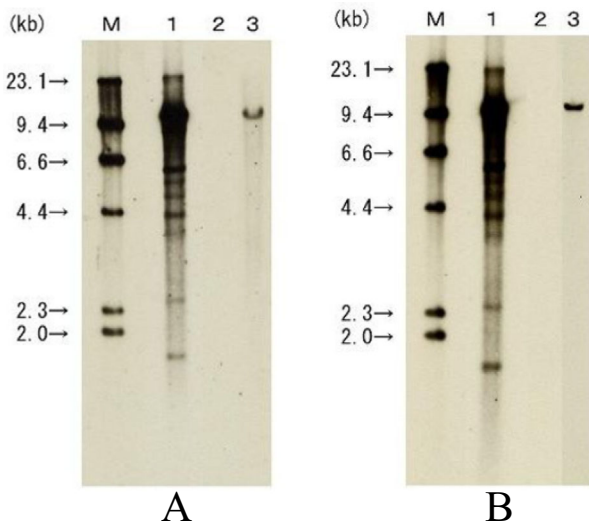


Figure 6. EBV southern blot analysis (A: whole blood, B: gingival mass). M: size marker, 1: positive control, 2: negative control, 3: patient specimen. Monoclonal proliferation of EBV-infected cells was demonstrated in peripheral blood and in gingival mass tissue by Southern blot analysis.

diagnosed based on the findings of EBV antibody titer elevation (viral capsid (VCA)-IgG 320 titers; VCA-IgM <10 titers; EB nuclear antigen (EBNA) 40 titers; early antigen (EA)-IgG 80 titers) and positive EBV-DNA in the peripheral blood (4.7×10^4 copies/ 10^6 cells), in addition to the infectious mononucleosis-like symptoms. Monoclonal proliferation of

EBV-infected cells was demonstrated in the peripheral blood and in the oral mass tissue via a Southern blot analysis (Fig. 6).

The EPOCH therapy was then changed to Capizzi therapy (high-dose cytarabine and L-asparaginase) in conjunction with PSL 50 mg/body (3). However, despite two courses of Capizzi therapy, the patient's fever, eruptions, and elevated hepatobiliary enzymes recurred, and his EBV-DNA levels did not decrease. We therefore decided to perform CBT urgently.

The conditioning regimen consisted of fludarabine 125 mg/m², melphalan 140 mg/m², and whole-body irradiation at 4 Gy. Tacrolimus and mycophenolate mofetil were administered for graft-versus-host disease (GVHD) prophylaxis. The patient received cord blood from a human leukocyte antigen (HLA) 4/6 matched-unrelated donor, with a transplant cell count of 2.96×10^7 /kg and a CD34 of 1.05×10^5 /kg. He developed a pre-engraftment immune reaction 10 days after CBT, but this improved without additional treatment. Neutrophil engraftment was observed on Day 22. On Day 24, an analysis of the peripheral blood chimerism of the CD3-positive cells revealed complete donor type, and the EBV-DNA levels in the blood fell below the detection limit. Grade I acute GVHD (skin 1, liver 0, gut 0) improved with topical steroids, and the BK virus-associated hemorrhagic cystitis improved with hyperhydration and bladder irrigation, using a Foley catheter.

He was discharged on Day 75. The EBV-DNA remained below the detection limit, and the FDG-PET showed no

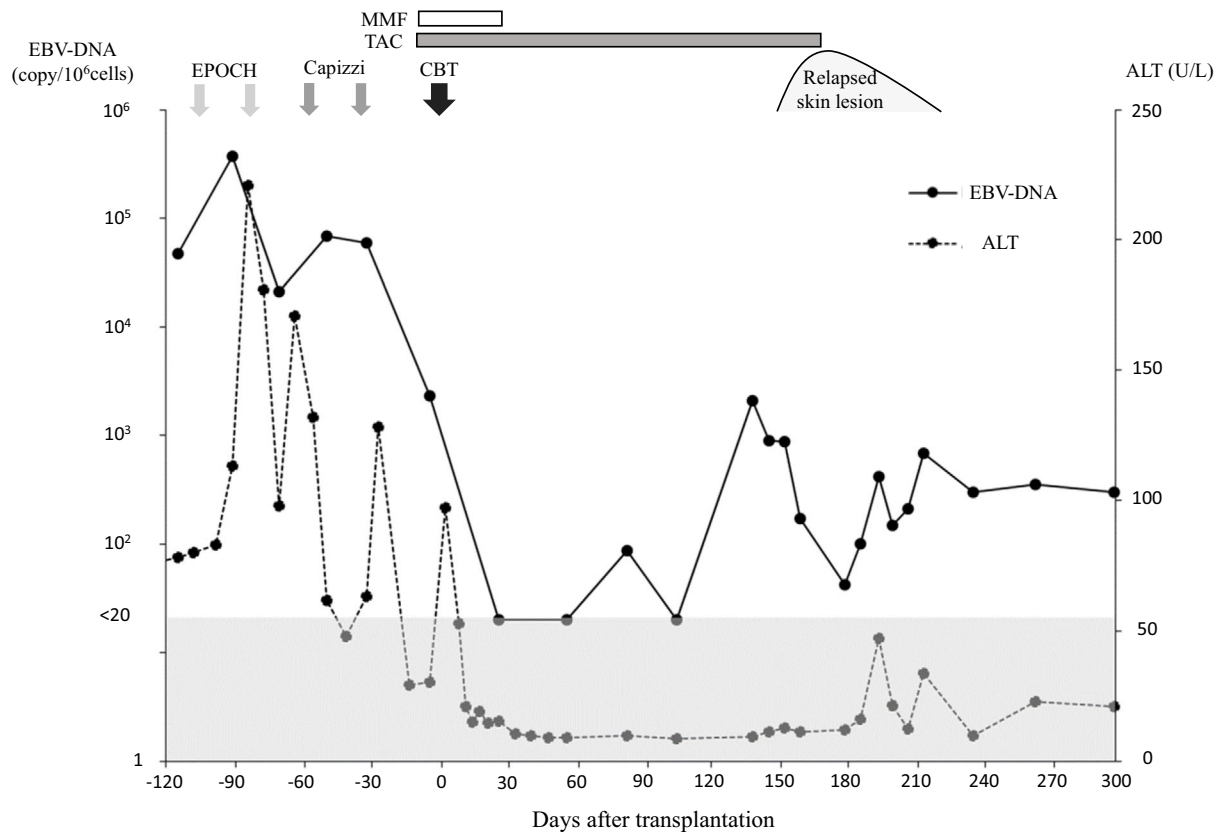


Figure 7. Clinical course. EPOCH: etoposide, prednisolone, vincristine, cyclophosphamide, doxorubicin, Capizzi: high-dose cytarabine, L-asparaginase, CBT: cord blood transplantation, ALT: alanine aminotransferase, MMF: mycophenolate mofetil, TAC: tacrolimus

signs of recurrence on Day 104. On Day 140, the EBV-DNA load in peripheral blood rose transiently to 1.2×10^4 copies/ 10^6 cells, but the peripheral blood chimerism of the CD3-positive cells and whole blood was complete donor type. On Day 165, skin eruptions appeared on the axilla and thigh. A histopathological examination of the skin eruptions revealed the invasion of EBER-ISH-positive T cells, and the withdrawal of tacrolimus successfully induced complete remission again (Fig. 7). One year after transplantation, there were no signs of recurrence.

Discussion

CAEBV presents with various clinical manifestations, including a prolonged or intermittent fever, lymphadenopathy, hepatosplenomegaly, and eruptions (4). Malignant lymphoma develops in 16% of patients with CAEBV (5). Because of the various clinical features, CAEBV is sometimes difficult to diagnose. In our case, the patient showed a fever, anemia, splenomegaly, and HV-like eruptions that had started in childhood. It is difficult to differentiate CAEBV from systemic HV, but CAEBV with HV-like eruptions has been reported in the literature (6, 7). In 2005, Okano et al. proposed guidelines for the diagnosis of CAEBV, one of which was the presence of EBV genomes in the affected tissues, including the peripheral blood (4). A diagnosis of CAEBV was made for the present case based on the pro-

longed and recurrent clinical symptoms and the presence of EBV-DNA in the peripheral blood. However, some patients may still not have been correctly diagnosed with CAEBV.

The prognosis of CAEBV is very poor. In the absence of effective therapy, almost all patients will die within 5-15 years from the onset due to hepatic or cardiac failure, hemophagocytic syndrome, malignant lymphoma, opportunistic infections, or intracranial/gastrointestinal bleeding (3, 5, 8). Allo-HSCT is considered to be the only curative treatment. Since the present patient had no matched sibling donors, we started a donor search through the Japan Marrow Donor Program. However, his liver dysfunction and fever worsened despite treatment with intensive chemotherapy. Cord blood is a useful donor source when immediate HSCT is required due to aggressive clinical symptoms.

Sawada et al. reported that the prognosis of patients with CAEBV who received CBT with reduced intensity conditioning (RIC) was comparable to that of patients who received bone marrow transplantation with RIC (9). They stated that the cord blood can function as an alternative source for bone marrow or peripheral blood stem cell transplantation. However, 13 of 15 cases (87%) in the RIC group in their study were children, and the outcome for adult patients who received CBT for CAEBV remained unclear.

In the literature, we found 8 adult (≥ 20 years old) cases of CAEBV treated with CBT (Table) (3, 9-12). The median age was 38 years (range: 20-56), and engraftment was

Table. Characteristics of Adult Patients with CAEBV Receiving CBT Reported in the Literature.

Case	Age	Sex	Disease type	Pretreatment (courses)	Conditioning	GVHD prophylaxis	HLA disparity	HLA antibody	TNC ($\times 10^7/\text{kg}$)	Infused cells CD34+ ($\times 10^5/\text{kg}$)	Engraftment	GVHD acute	GVHD chronic	Outcome	Reference
1	47	F	CAEBV	NA	Flu/CY/ATG/TBI6Gy	TAC/sMTX	4/6	NA	NA	NA	+	-	-	Alive/CR	3
2	23	F	CAEBV	5	ATG/Flu/Mel/mPSL/VP16	TAC/sMTX	5/6	negative	3.41	0.96	+	NA	NA	NA	9
3	38	M	CAEBV	2	ATG/Flu/Mel/mPSL/VP16	TAC/sMTX	4/6	negative	1.64	1.23	+	NA	NA	NA	9
4	20	F	HMV+CAEBV+PTCL	NA	NA	NA	NA	NA	NA	NA	+	NA	NA	Alive/CR	10
5	52	F	CAEBV+ENKL	NA	NA	NA	NA	NA	NA	NA	-	NA	NA	Died/TRM	10
6	56	F	CAEBV	12	Flu/Bu/TBI4Gy	TAC	4/6	NA	2.78	NA	+	II	+	Alive/CR	11
7	36	F	CAEBV	0	Flu/Mel/TBI4Gy	TAC/sMTX	N/C	NA	NA	0.85	+	NA	+	NA/CR	12
8	41	M	CAEBV+ALCL	4	Flu/Mel/TBI4Gy	TAC/MMF	4/6	positive	2.96	1.05	+	I	-	Alive/CR	our case

NA: not available; HMV: hypersensitivity to mosquito bite; CAEBV: chronic active Epstein-Barr virus infection; PTCL: peripheral T-cell lymphoma; ENKL: extranodal NK/T cell lymphoma; SHV: severe hydropic vacuoliforme; ALCL: anaplastic large cell lymphoma; ATG: antithymocyte globulin; Flu: fludarabine; Mel: melphalan; mPSL: methylprednisolone; VP16: etoposide; Bu: busulfan; TBI: total body irradiation; CY: cyclophosphamide; TAC: tacrolimus; sMTX: short-term methotrexate; MMF: mycophenolate mofetil; TNC: total nucleated cells; GVHD: graft-versus-host disease; CR: complete remission; TRM: treatment-related mortality

achieved in 7 cases. One patient (Case #2) died due to regimen-related toxicity before neutrophil engraftment. In six cases, the conditioning regimen was RIC. In five cases, the median number of pretransplant-therapy courses before HSCT was four. In four cases, the median nucleated cell count of the cord blood was $2.87 \times 10^7/\text{kg}$ (range: $1.64-3.41 \times 10^7/\text{kg}$), and the median number of CD34-positive cells was $1.00 \times 10^5/\text{kg}$ (range: $0.85-1.23 \times 10^5/\text{kg}$). Five of the six cases achieved complete remission.

However, there may be major issues with regard to CBT in adults, one of which being the conditioning regimen. Kawa et al. reported an excellent outcome in patients who received RIC. In a retrospective analysis of 29 CAEBV cases, they compared the outcomes of allo-HSCT with the myeloablative conditioning (MAC) and RIC regimens (3). The 3-year event-free survival rate was $54.4\% \pm 15.0\%$ for the MAC group and $85.0\% \pm 8.0\%$ for the RIC group. The 3-year overall survival rate was $54.5\% \pm 15.0\%$ for the MAC group and $95.0\% \pm 4.9\%$ for the RIC group ($p=0.016$). They reported that allo-HSCT after RIC is a promising approach in the treatment of CAEBV. This may also apply to adult cases.

In the present case, the EBV-DNA load in the peripheral blood dropped below the detection limit on Day 24 but rose transiently to 1.2×10^4 copies/ 10^6 cells at the time of recurrence with skin eruptions. The patient sustained a low copy number of EBV genomes in the peripheral blood, without recurrence of a fever, liver damage, or gingival lymphoma. In a case reported by Watanabe et al., the patient developed a persistent EBV infection in donor T cells and sustained a low copy number of EBV genomes in T cells without clinical symptoms for 60 months after unrelated bone marrow transplantation (13). In the present case, we detected no infected cells in the peripheral blood, but the complete donor chimerism of the peripheral blood suggested a phenomenon similar to that observed in the previous report.

In conclusion, the encouraging outcome in the present case suggests that CBT should be considered for adult cases of CAEBV with aggressive clinical manifestations. Further studies will be required to evaluate the efficacy of CBT.

The authors state that they have no Conflict of Interest (COI).

Acknowledgement

The authors thank Dr. Sakuhei Fujiwara for his invaluable suggestions.

References

1. Terashi H, Katagiri K, Fujiwara S, et al. Association of recurrent ulcerating papules resembling lymphomatoid papulosis with hydroa vacciniforme. *Nishinohon J Dermatol* **52**: 911-916, 1990 (in Japanese, Abstract in English).
2. Iwatsuki K, Ohtsuka M, Harada H, Han G, Kaneko F. Clinicopathologic manifestations of Epstein-Barr virus-associated cutaneous lymphoproliferative disorders. *Arch Dermatol* **133**: 1081-1086, 1997.
3. Kawa K, Sawada A, Sato M, et al. Excellent outcome of allogeneic

- neic hematopoietic SCT with reduced-intensity conditioning for the treatment of chronic active EBV infection. *Bone Marrow Transplant* **46**: 77-83, 2011.
4. Okano M, Kawa K, Kimura H, et al. Proposed guidelines for diagnosing chronic active Epstein-Barr virus infection. *Am J Hematol* **80**: 64-69, 2005.
 5. Kimura H, Hoshino Y, Kanegane H, et al. Clinical and virologic characteristics of chronic active Epstein-Barr virus infection. *Blood* **98**: 280-286, 2001.
 6. Park BM, Ahn JS, Lee JB, Won YH, Yun SJ. Chronic active Epstein-Barr virus infection-associated hydroa vacciniforme-like eruption and Behçet's-like orogenital ulcers. *Dermatology* **226**: 212-216, 2013.
 7. Katagiri Y, Mitsuhashi Y, Kondo S, et al. Hydroa vacciniforme-like eruptions in a patient with chronic active EB virus infection. *J Dermatol* **30**: 400-404, 2003.
 8. Ishihara S, Okada S, Wakiguchi H, et al. Chronic active Epstein-Barr virus infection in children in Japan. *Acta Paediatr* **84**: 1271-1275, 1995.
 9. Sawada A, Inoue M, Koyama-Sato M, et al. Umbilical cord blood as an alternative source of reduced-intensity hematopoietic stem cell transplantation for chronic Epstein-Barr virus-associated T or natural killer cell lymphoproliferative diseases. *Biol Blood Marrow Transplant* **20**: 214-221, 2014.
 10. Isobe Y, Aritaka N, Setoguchi Y, et al. T/NK cell type chronic active Epstein-Barr virus disease in adults: an underlying condition for Epstein-Barr virus-associated T/NK-cell lymphoma. *J Clin Pathol* **65**: 278-282, 2012.
 11. Nakagawa M, Hashino S, Takahata M, et al. Successful reduced-intensity stem cell transplantation with cord blood for a poor-prognosis adult with refractory chronic active Epstein-Barr virus infection. *Int J Hematol* **85**: 443-445, 2007.
 12. Onishi Y, Sugimura K, Ohba R, et al. Resolution of chronic active EBV infection and coexisting pulmonary arterial hypertension after cord blood transplantation. *Bone Marrow Transplant* **49**: 1343-1344, 2014.
 13. Watanabe Y, Sasahara Y, Satoh M, et al. A case series of CAEBV of children and young adults treated with reduced-intensity conditioning and allogeneic bone marrow transplantation: a single-center study. *Eur J Haematol* **91**: 242-248, 2013.
- The Internal Medicine is an Open Access article distributed under the Creative Commons Attribution-NonCommercial-NoDerivatives 4.0 International License. To view the details of this license, please visit (<https://creativecommons.org/licenses/by-nc-nd/4.0/>).