

Available online at www.sciencedirect.com

ScienceDirect

journal homepage: www.elsevier.com/locate/radcr

Case Report

Verification of thrombus formation just after endoscopic injection sclerotherapy with ligation for esophagogastric varices by venous phase of left gastric arteriography ☆

Fumio Chikamori, MD^{a,*}, Shunsuke Kanazawa^b, Niranjana Sharma, MD^c^aDepartment of Surgery, Japanese Red Cross Kochi Hospital, 1-4-63-11 Hadaminamimachi, Kochi 780-8562, Japan^bDepartment of Gastroenterology, Japanese Red Cross Kochi Hospital, 1-4-63-11 Hadaminamimachi, Kochi 780-8562 Japan^cAdv Train Gastroint & Organ Transp Surgery, 12 Scotland Street, Dunedin 9016, New Zealand

ARTICLE INFO

Article history:

Received 22 July 2022

Accepted 27 July 2022

Keywords:

Left gastric arteriography

Emergency hybrid procedure

Splanchnic caput Medusae

Esophagogastric varices

Endoscopic injection sclerotherapy with ligation

Left gastric artery embolization

ABSTRACT

Management of hepatic venous pressure gradient (HVPG) is important in the treatment of portal hypertension. We report a case that was treated by a hybrid procedure combining endoscopic injection sclerotherapy with ligation (EISL), left gastric artery embolization (LGE), and partial splenic artery embolization (PSE) based on a new concept “splanchnic caput Medusae.” The venous phase of left gastric arteriography just after EISL demonstrated thrombus formation in the gastric varices and the cardiac branch of the left gastric vein. The para-esophageal vein and lesser curvature branch of the left gastric vein were not affected. HVPG decreased from 14 to 11 mmHg immediately after LGE and PSE. 3D-CT reconstruction portal image revealed that the portal system reversed to almost normal form. This is the first case report in which thrombus formation in gastric varices and cardiac branch just after EISL could be demonstrated by the venous phase of left gastric arteriography.

© 2022 The Authors. Published by Elsevier Inc. on behalf of University of Washington.

This is an open access article under the CC BY-NC-ND license

[\(http://creativecommons.org/licenses/by-nc-nd/4.0/\)](http://creativecommons.org/licenses/by-nc-nd/4.0/)

Introduction

Management of hepatic venous pressure gradient (HVPG) is important in the treatment of portal hypertension [1,2]. We proposed a new concept: “splanchnic caput Medusae” in which the spleen is her face and portal collateral pathways are

her snake hairs [3]. In the new concept, partial splenic artery embolization (PSE) is considered the treatment of Medusae’s face. We have reported that PSE not only increases platelet count but also reduces the splenic venous blood flow volume, portal venous pressure, and spleen/liver volume ratio [4–6]. Endoscopic injection sclerotherapy (EIS) and endoscopic variceal ligation (EVL) are considered the treatment of

☆ Competing Interests: The authors declare no conflicts of interest associated with this manuscript.

* Corresponding author.

E-mail address: chikamo2300@gmail.com (F. Chikamori).

<https://doi.org/10.1016/j.radcr.2022.07.098>

1930-0433/© 2022 The Authors. Published by Elsevier Inc. on behalf of University of Washington. This is an open access article under the CC BY-NC-ND license (<http://creativecommons.org/licenses/by-nc-nd/4.0/>)

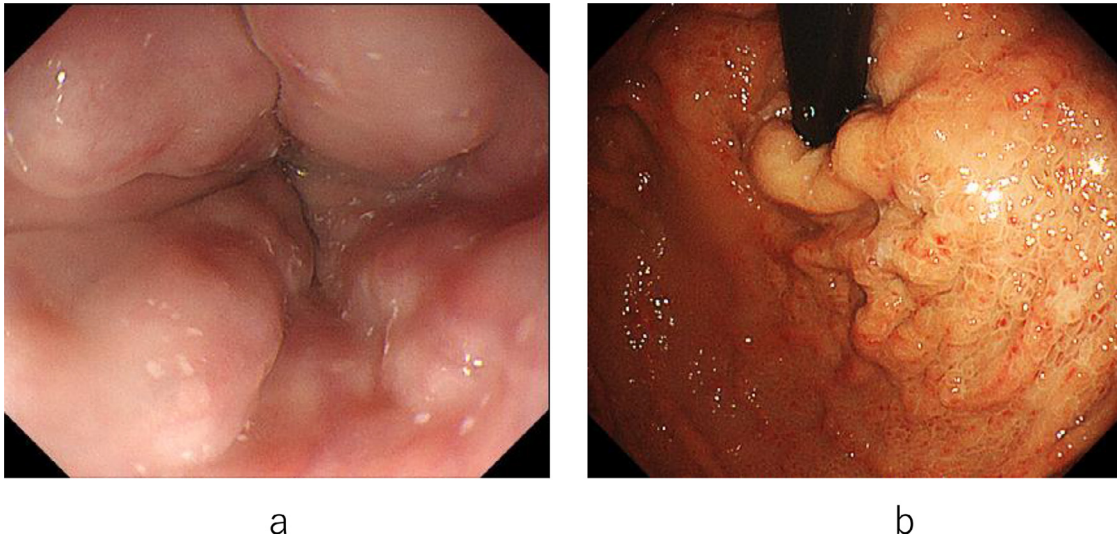


Fig. 1 – Endoscopic picture before the hybrid procedure. (A) Endoscopic picture shows nodular esophageal varices. (B) Endoscopic picture shows nodular gastric varices with mild portal hypertensive gastropathy.

Medusae’s hair. Because portal venous pressure is associated with bleeding, it is important to reduce portal venous pressure to prevent rebleeding [7]. We have reported an emergency hybrid procedure that combines endoscopic treatment with PSE for bleeding esophagogastric varices [8]. However, in the cases of esophagogastric varices without splenomegaly, dilatation of the left gastric arteriovenous shunt is considered the cause of varices formation [9,10]. This time, we experienced an elective hybrid procedure combining endoscopic injection sclerotherapy with ligation (EISL) [11], left gastric artery embolization (LGE), and PSE. Left gastric arteriography (LGA) is a procedure that precedes LGE. Here, we report a case in which thrombus formation in gastric varices and cardiac branch of the left gastric vein just after EISL could be demonstrated by the venous phase of LGA.

Case

A 57-year-old male with hematemesis was referred to the department of surgery at our hospital. He had a history of alcohol and hepatitis C virus (HCV) related cirrhosis with ascites and was treated with diuretics 3 years ago. He underwent sofosbuvir / velpatasvir therapy for HCV infection 2 years ago.

On admission, he did not have jaundice and his consciousness level was lucid. Laboratory studies revealed hemoglobin 3.6 g/dL (normal range, 13.5–17.4); total leukocyte count 7550 / μ L (3500–8000 / μ L); platelet count 8.8×10^4 / μ L (12.3 – 33.1×10^4 / μ L); total bilirubin 1.4 mg/dL (0.3–1.3 mg/dL); albumin 3.1 g/dL (3.8–5.0 g/dL); aspartate transaminase (AST) 116 U/L (10–32 U/L); alanine transaminase (ALT) 155 U/L (5–27 U/L); prothrombin time (PT) 47.6% (70%–130%); Mac-2 binding protein glycosylated isomers (M2BPGi) 4.61 COI (2+) (<1.00); serum ammonia (NH₃) 24 μ g/dL (12–66 μ g/dL). The retention rate of indocyanine green at 15 minutes (ICG15) was 45% (<10%).

The Child-Pugh score was 8 and the class was B. Hepatitis B surface antigen was negative. HCV-RNA was undetectable.

Endoscopy confirmed nodular esophagogastric varices and mild portal hypertensive gastropathy (PHG) without active bleeding (Figs. 1A and B). Abdominal ultrasonography and contrast-enhanced CT showed liver cirrhosis with a small amount of ascites. 3D-CT demonstrated that the esophagogastric varices were supplied by the cardiac branch of the left gastric vein. The spleen volume was 204 ml, the liver volume was 1559 ml; giving a spleen/liver volume ratio of 0.13 (Fig. 2A). According to “splanchnic caput Medusae” concept [3], the spleen was regarded as her face and esophagogastric varices as her snake hairs.

In this case, because active variceal bleeding was not evident, a hybrid procedure was performed electively. EISL, LGE, and PSE were performed consecutively under general anesthesia in the digital subtraction angiography (DSA) room. In EISL, a total of 2.5 ml of 5% ethanolamine oleate (5%EO) with iopamidol was injected into the cardiac branch of the left gastric vein for 10 minutes under fluoroscopy (Figs. 3A and B). The variceal site of injection was ligated immediately after the removal of the needle to protect against variceal bleeding (Fig. 3C). Seven more variceal ligations were added to stop the variceal blood flow.

Subsequently, hepatic venous catheterization, LGE, and PSE were performed. Hepatic venous cannulation via the right antecubital vein was performed. Hepatic venous pressure gradient (HVPG) was 14 mmHg (normal range, 1–5 mmHg). The venous phase of celiac arteriography just after EISL demonstrated that the left gastric vein trunk was visualized away from the liver (Fig. 4A). The venous phase of super-selective LGA demonstrated the thrombus formation in gastric varices and the cardiac branch of the left gastric vein (Fig. 4B). The para-esophageal vein and lesser curvature branch of the left gastric vein were not affected. The left gastric vein trunk was visualized towards the liver. According to these findings, the

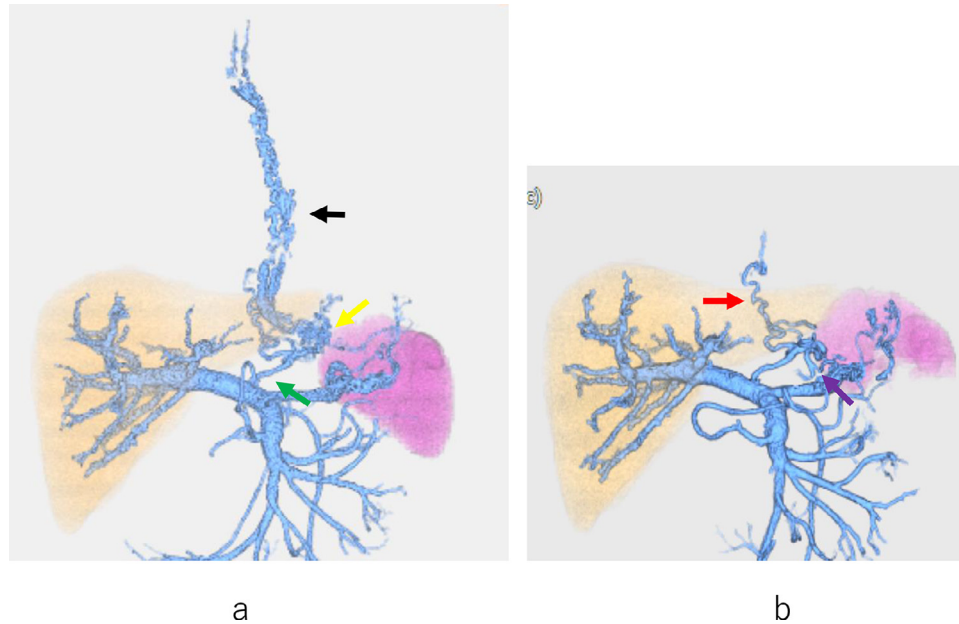


Fig. 2 – 3D-CT reconstruction image before and after the hybrid procedure. (A) 3D-CT reconstruction image before the hybrid procedure shows the left gastric vein (green arrow), gastric (yellow arrow), and esophageal varices (black arrow). (B) 3D-CT reconstruction image after the hybrid procedure shows the portal system that has reversed to almost normal form. The para-esophageal vein (red arrow) and lesser curvature branch (purple arrow) of the left gastric vein are not affected.

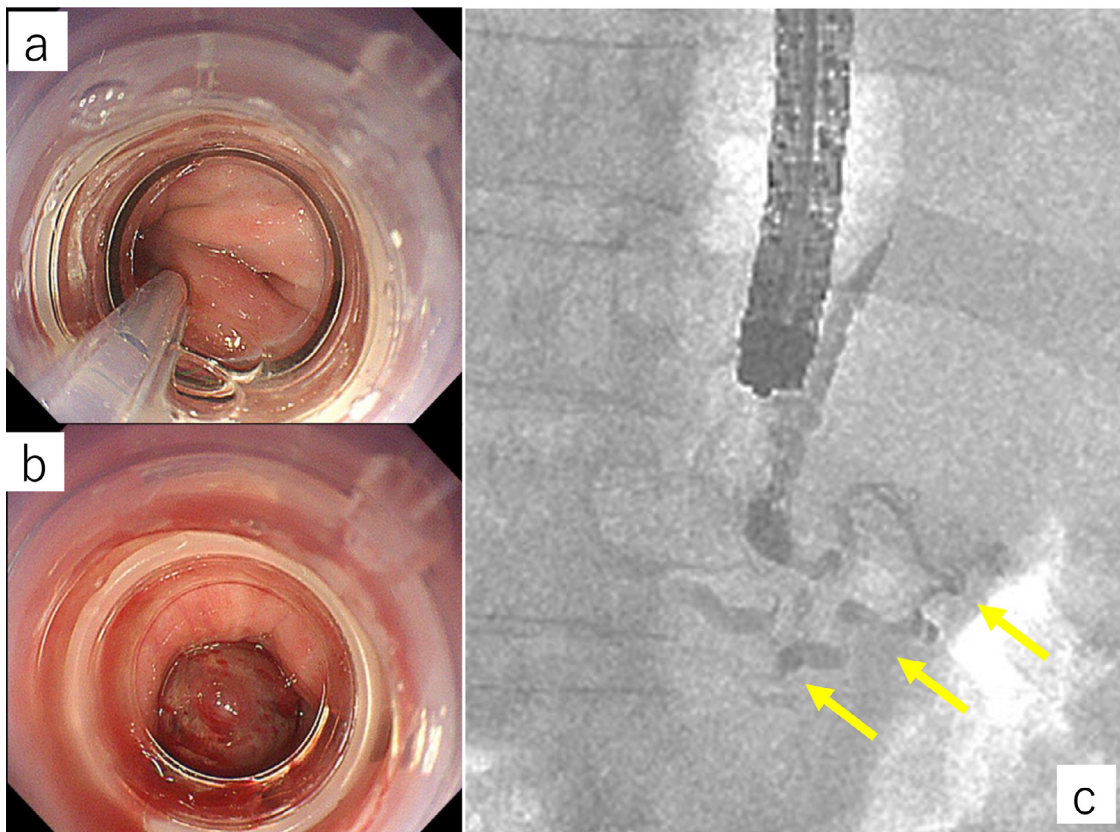


Fig. 3 – Endoscopic picture and endoscopic varicogram during EISL. (A) Endoscopic picture shows esophageal varices punctured by injection needle during EISL. (B) Endoscopic picture shows the variceal site of injection that was ligated immediately after the removal of the needle. (C) Endoscopic varicogram during EISL shows esophageal varices, gastric varices, and cardiac branch of the left gastric vein (yellow arrow).

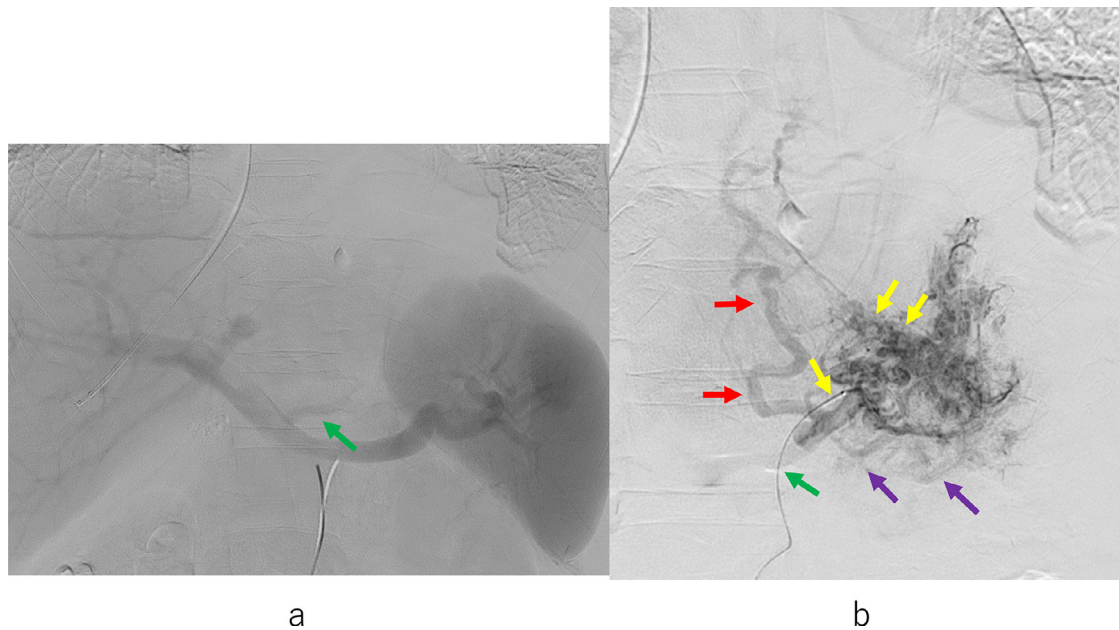


Fig. 4 – Venous phases of celiac arteriogram and super-selective left gastric arteriography (LGA) just after EISL. (A) The venous phase of celiac arteriogram just after EISL shows that the left gastric vein trunk is visualized away from the liver (green arrow). (B) The venous phase of super-selective LGA just after EISL shows the thrombus formation in gastric varices and the cardiac branch of the left gastric vein (yellow arrow). The para-esophageal vein (red arrow) and lesser curvature branch (purple arrow) of the left gastric vein are not affected. The left gastric vein trunk is visualized towards the liver (green arrow). According to these findings, the blood flow direction of the left gastric vein trunk is angiographically diagnosed as a bi-directional pattern.

blood flow direction of the left gastric vein trunk was angiographically diagnosed as a bi-directional pattern. In this case, splenomegaly was not evident. PSE was performed for the treatment of thrombocytopenia. However, it seemed difficult to expect the portal decompression effect only by PSE. Because the involvement of left gastric artery blood flow in the formation of esophagogastric varices was considered to be significant, LGE was performed using microcoils (Figs. 5A and B). HVPG decreased to 11 mmHg immediately after LGE and PSE.

3D-CT reconstruction portal image 3 days after the hybrid procedure revealed sufficiently obliterated esophagogastric varices. The para-esophageal vein and lesser curvature branch of the left gastric vein were not affected. The corrected spleen/liver volume ratio was 0.11. The portal system reversed to almost normal form (Fig. 2B). Two weeks after the hybrid procedure, endoscopic examination revealed that the esophagogastric varices were significantly reduced in size, and PHG was improved (Figs. 6A and B). The platelet count increased to $55.8 \times 10^4 /\mu\text{L}$, and he was discharged.

Discussion

We reported the first case in which thrombus formation in gastric varices and cardiac branch just after EISL could be demonstrated by the venous phase of left gastric arteriography (LGA).

Currently, endoscopic treatment such as EIS or EVL is the first choice for esophagogastric variceal bleeding [12]. The pharmacological effect of 5%EO on blood coagulation and vascular damage in dogs has been reported [13]. 5% EO destroys the endothelial cells of the vessel of the dog 30 seconds after injection into the vessels. The site of the destroyed endothelial cells is covered with fibrin 5 minutes after the injection of 5%EO. Two hours after the injection, red blood cells and fibrin accumulate on the damaged vessels. Mural thrombus occludes the bloodstream 24 hours after the injection. With EIS alone, variceal blood flow resumes just after injection of 5%EO, so it takes time to occlude varices and their feeders by thrombus. On the other hand, because variceal blood flow is blocked with EISL, it has been considered that occlusion by thrombus in variceal feeders is formed just after EISL. However, there were no reports that could prove thrombus formation just after EISL. In this case, thrombus formation in gastric varices and cardiac branch just after EISL could be demonstrated by the venous phase of LGA (Fig. 4B).

Endoscopic varicography [14] is useful to identify the variceal feeders in which 5%EO with iopamidol is retrogradely injected. However, it is difficult to prove thrombus formation by endoscopic varicography only. Percutaneous transhepatic portography [15] is useful to evaluate thrombus formation after endoscopic therapy; however, it is invasive. Its use is limited to elective and in special cases. Contrast-enhanced CT and 3D-CT reconstruction image are useful for assessing blood flow alterations, but it lacks resolution. The first advantage of LGA is that it is included in the hybrid procedure and can be

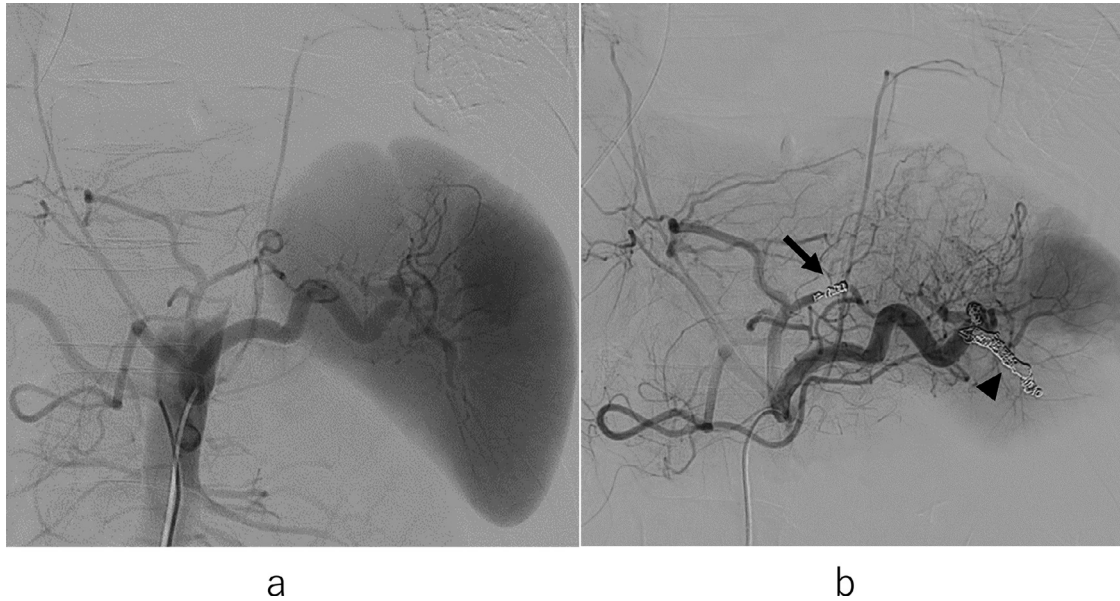


Fig. 5 – Celiac arteriogram before and after LGE and PSE. (A) Arterial phase of celiac arteriogram before LGE and PSE. (B) Arterial phase of celiac arteriogram after LGE (arrow) and PSE (arrow head).

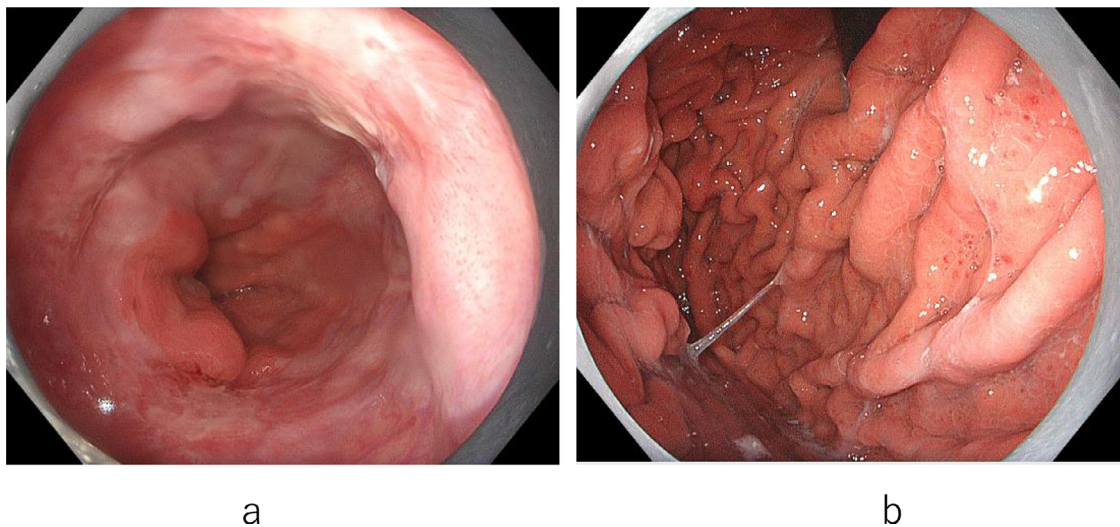


Fig. 6 – Endoscopic picture 2 weeks after the hybrid procedure. (A) Endoscopic picture shows that the esophageal varices are significantly reduced in size. (B) Endoscopic picture shows that the gastric varices are reduced in size and PHG is improved.

evaluated just after EISL. The 2nd advantage is that it has a high resolution. The 3rd advantage is that the blood flow direction of the main trunk of the left gastric vein can be evaluated. The 4th advantage is that LGE can be added.

Portal venous pressure is directly correlated with variceal bleeding [7]. Because direct portal pressure measurement is invasive, HVPG is measured as an alternative. Rebleeding can be prevented by setting the HVPG to 12 mmHg or less [1,2]. PSE not only increases platelet count but also reduces the portal venous pressure, splenic venous blood flow volume and spleen/liver volume ratio [4–6]. We have reported the advantages of the hybrid procedure combining endoscopic treat-

ment and PSE for esophagogastric varices [8]. However, in this case, splenomegaly was not evident and it seemed difficult to expect the portal decompression effect only by PSE. Because the involvement of left gastric artery blood flow in the formation of esophagogastric varices was considered to be significant, LGE was added. Actually, HVPG decreased from 14 to 11 mmHg immediately after LGE and PSE.

Hemodynamic effects of the left gastric artery on esophageal varices have been reported [9,10]. The direction of blood flow in the main trunk of the left gastric vein is important in considering the cause of esophagogastric varices. Hepatopetal or bi-directional LGV blood flow pattern indicates

the involvement of left gastric artery blood flow as the cause of esophagogastric varices. Control of LGA hemodynamics may be useful for the suppression of variceal recurrence. In the future, for esophagogastric varices without splenomegaly, we would like to actively evaluate portal hemodynamics by LGA and HVPG to establish the indication for LGE.

PHG was also improved after the hybrid procedure in this case. A high incidence of PHG is observed in patients with severe liver dysfunction, with a high HVPG, and who have undergone endoscopic treatment with sclerotherapy [16]. LGE and PSE decreased HVPG and it may have contributed to the improvement of PHG.

The hybrid procedure combining EISL with LGE and PSE was effective for the treatment of esophagogastric varices with PHG. We conclude that the venous phase of LGA is useful for evaluating thrombus formation just after EISL for esophagogastric varices.

Patient consent

Written informed consent was obtained from the patient for publication of this case report and accompanying images.

REFERENCES

- [1] Garcia-Tsao G, Abraldes JG, Berzigotti A, Bosch J. Portal hypertensive bleeding in cirrhosis: risk stratification, diagnosis, and management: 2016 practice guidance by the American Association for the study of liver diseases. *Hepatology* 2017;65(1):310–35. doi:10.1002/hep.28906.
- [2] Albillos A, Garcia-Tsao G. Classification of cirrhosis: the clinical use of HVPG measurements. *Dis Markers* 2011;31(3):121–8. doi:10.3233/DMA-2011-0834.
- [3] Chikamori F, Sharma N, Ito S, Mizobuchi K, Ueta K, Takasugi H, et al. Stepwise partial splenic embolization for portal hypertension based on a new concept: splanchnic caput Medusae. *Radiol Case Rep* 2020;16(3):564–70 eCollection 2021 Mar. doi:10.1016/j.radcr.2020.12.020.
- [4] Chikamori F, Kuniyoshi N, Kawashima T, Takase Y. Short-term portal hemodynamic effects of partial splenic embolization for hypersplenism. *Hepatogastroenterology* 2007;54(78):1847–9.
- [5] Chikamori F, Nishida S, Selvaggi G, Tryphonopoulos P, Moon JI, Levi DM, et al. Effect of liver transplantation on spleen size, collateral veins, and platelet counts. *World J Surg* 2010;34(2):320–6. doi:10.1007/s00268-009-0314-x.
- [6] Chikamori F, Mizobuchi K, Ueta K, Takasugi H, Yukishige S, Matsuoka H, et al. Flood syndrome managed by partial splenic embolization and percutaneous peritoneal drainage. *Radiol Case Rep*. 2020;16(1):108–12 eCollection 2021 Jan. doi:10.1016/j.radcr.2020.10.045.
- [7] Bosch J, Garcia-Pagan JC. Prevention of variceal rebleeding. *Lancet* 2003;361(9361):952–4. doi:10.1016/S0140-6736(03)12778-X.
- [8] Chikamori F, Maeda A, Sharma N. An emergency hybrid procedure that combines endoscopic treatment with partial splenic embolization for bleeding esophagogastric varices. *Radiol Case Rep*. 2022;17(5):1640–5 eCollection 2022 May. doi:10.1016/j.radcr.2022.02.041.
- [9] Matsumoto A, Hamamoto N, Ohnishi A, Miyoshi H, Sugi K, Kojima H, et al. Left gastric vein hemodynamics and variceal recurrence in patients undergoing prophylactic endoscopic ligation of high-risk esophageal varices. *Gastrointest Endosc* 1999;50(6):768–74. doi:10.1016/s0016-5107(99)70156-2.
- [10] Kiyono S, Maruyama H, Kondo T, Sekimoto T, Shimada T, Takahashi M, et al. Hemodynamic effect of the left gastric artery on esophageal varices in patients with cirrhosis. *J Gastroenterol* 2016;51(9):900–9 Epub 2016 Jan 18. doi:10.1007/s00535-015-1157-x.
- [11] Nishikawa Y, Hosokawa Y, Doi T, Shima S, Miyoshi M, Ohnishi T, et al. Simultaneous combination of endoscopic sclerotherapy and endoscopic ligation for esophageal varices. *Gastrointest Endosc* 1995;42(4):358–60. doi:10.1016/s0016-5107(95)70138-9.
- [12] Yoshida H, Mamada Y, Taniyai N, Tajiri T. New methods for the management of esophageal varices. *World J Gastroenterol*. 2007;13(11):1641–5. doi:10.3748/wjg.v13.i11.1641.
- [13] Masaki M, Obara K, Suzuki S, Orikasa K, Mitsuhashi H, Iwasaki K, et al. The destructive effects of sclerosant ethanalamine oleate on mammalian vessel endothelium. *Gastroenterol Jpn* 1990;25(2):230–5. doi:10.1007/BF02776821.
- [14] Chikamori F, Nishio S, Kuniyoshi N, Shibuya S, Takase Y. Blood supply routes of recurrent esophageal varices following endoscopic embolization. *Dig Surg* 2000;17(1):17–22. doi:10.1159/00001879.
- [15] Takase Y, Shibuya S, Chikamori F, Orii K, Iwasaki Y. Recurrence factors studied by percutaneous transhepatic portography before and after endoscopic sclerotherapy for esophageal varices. *Hepatology* 1990;11(3):348–52. doi:10.1002/hep.1840110303.
- [16] Ferraz JG, Wallace JL. Underlying mechanisms of portal hypertensive gastropathy. *J Clin Gastroenterol* 1997;25(suppl 1):S73–8. doi:10.1097/00004836-199700001-00012.