

Case report

Idiopathic macular telangiectasia type 2: A six-year study with multimodal imaging of a presumed unilateral case

Mohammad Zarei, Mehdi Mazloumi*, Reza Karkhaneh, Ramak Roohipoor

Eye Research Center, Farabi Eye Hospital, Tehran University of Medical Sciences, Tehran, Iran

Received 17 November 2017; revised 21 December 2017; accepted 2 January 2018

Available online 3 February 2018

Abstract

Purpose: To present a rare manifestation of macular telangiectasia type 2 (MacTel type 2) followed up for over six years.

Methods: A 61-year-old woman with one year history of blurred vision of her left eye was referred.

Results: Whereas the funduscopy, spectral-domain optical coherence tomography (SD-OCT), fluorescein angiography (FA), and fundus auto-fluorescence (FAF) were normal in the right eye, they revealed noticeable findings typical of MacTel type 2 in the left eye. After over six years follow-up, OCT-angiography (OCTA) showed no remarkable difference between the two eyes, and en face OCT showed subtle abnormal change in the right eye as well as typical pathological changes in the left eye.

Conclusion: MacTel type 2 can present unilaterally and remain so for a long time. The role of multimodal imaging in diagnosis and follow-up is of utmost importance.

Copyright © 2018, Iranian Society of Ophthalmology. Production and hosting by Elsevier B.V. This is an open access article under the CC BY-NC-ND license (<http://creativecommons.org/licenses/by-nc-nd/4.0/>).

Keywords: Unilateral; Macular telangiectasia type 2; Multimodal imaging

Introduction

Macular telangiectasia type 2 (MacTel type 2) is an acquired neurodegenerative macular disorder characterized by loss of retinal transparency temporal to the fovea, right angle retinal venules, retinal pigment hyperplasia, and occasionally subretinal neovascularization (SRNV).¹ Traditionally, MacTel type 2 has been cited in the literature as a bilateral disorder which can affect both eyes in an asymmetric or sequential pattern.^{2,3} This report describes a case of presumed unilateral MacTel type 2 diagnosed by multimodal imaging, including high-resolution spectral-domain optical coherence tomography (SD-OCT), fluorescein angiography (FA), fundus auto-fluorescence (FAF), en face OCT, and OCT-angiography

(OCTA) in a 61-year-old woman. She has been following up for over 6 years to find out any subtle manifestations of disease in the fellow eye.

Case report

A 61-year-old woman presented with unilateral blurring of vision in the left eye for the past year. Her medical history was noteworthy for diabetes mellitus type 2 for the past 20 years and her medications included metformin and glibenclamide. She had no history of ocular surgery, trauma, radiation treatment, or sun gazing.

At presentation, best corrected visual acuity (BCVA) was 10/10 in the right eye and 8/10 in the left eye. The anterior segment examination was unremarkable. Dilated funduscopic examination showed no abnormal finding for the right eye, but revealed some reddish orange pigment alterations temporal to the fovea in the left eye (Fig. 1 A, B). While the SD-OCT, FA, and FAF were normal in the right eye, they revealed noticeable

The authors declare that they do not have any conflict of interest.

* Corresponding author. Eye Research Center, Farabi Eye Hospital, South Kargar Street, PO Box 141557146, Tehran, Iran.

E-mail address: Mazloumi.mehdi@gmail.com (M. Mazloumi).

Peer review under responsibility of the Iranian Society of Ophthalmology.

<https://doi.org/10.1016/j.joco.2018.01.003>

2452-2325/Copyright © 2018, Iranian Society of Ophthalmology. Production and hosting by Elsevier B.V. This is an open access article under the CC BY-NC-ND license (<http://creativecommons.org/licenses/by-nc-nd/4.0/>).

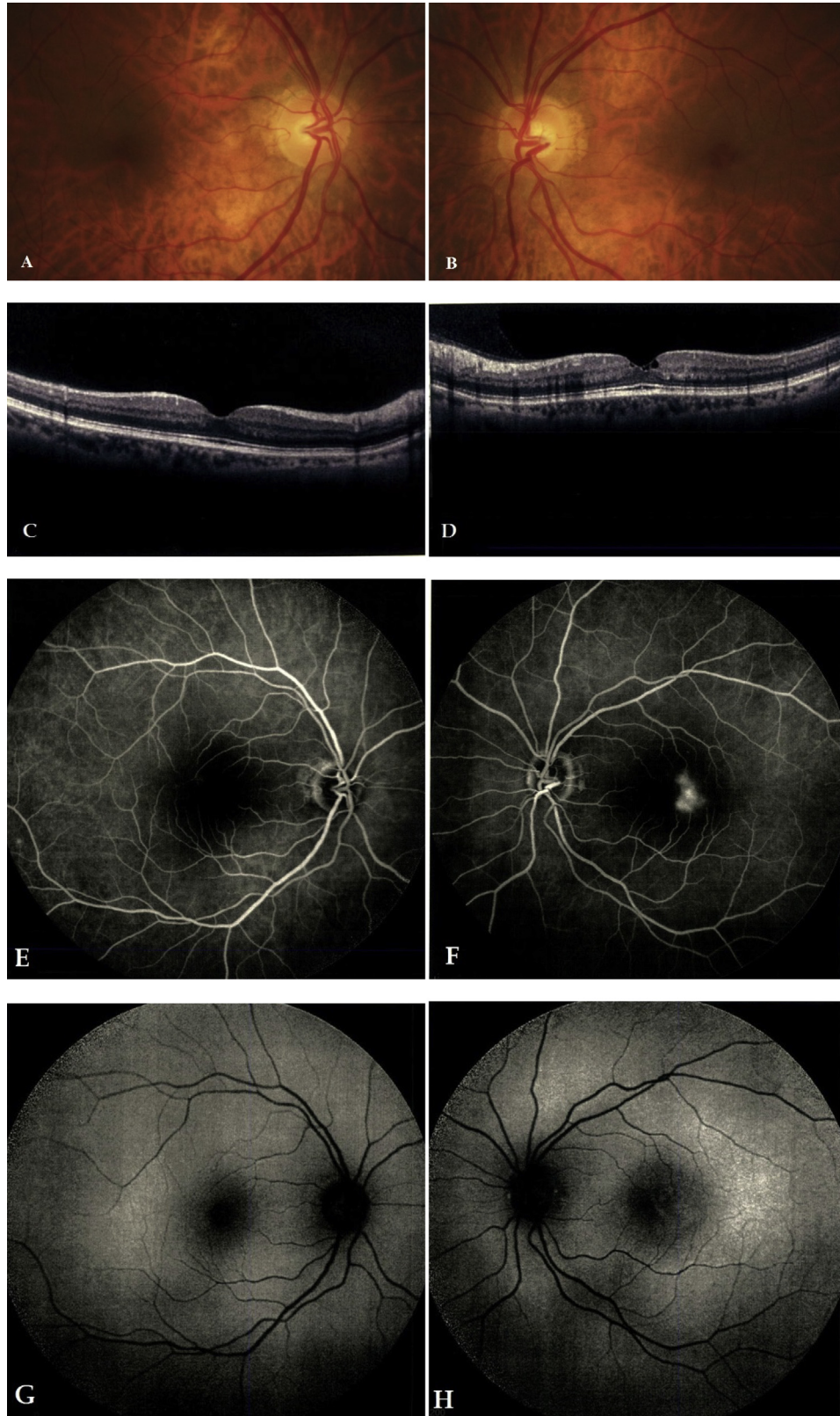


Fig. 1. First visit: (A), (C), (E), (G) and (I): right eye; (B), (D), (F), (H) and (J): left eye. (A) and (B): fundus examination showing small pigment alterations in the foveal area of the left eye. (C) and (D): spectral-domain optical coherence tomography (SD-OCT) showing outer retinal atrophy, pseudocyst formation and internal limiting membrane (ILM) draping on the left eye. (E) and (F) Fluorescein angiography (FA) showing fine hyperfluorescent dots with subsequent leakage temporal to the fovea on the left eye (G) and (H): Fundus autofluorescence (FAF) showing temporal juxtafoveal hyperautofluorescence on the left eye. (I) and (J): infrared reflectance image shows no change in both eyes.

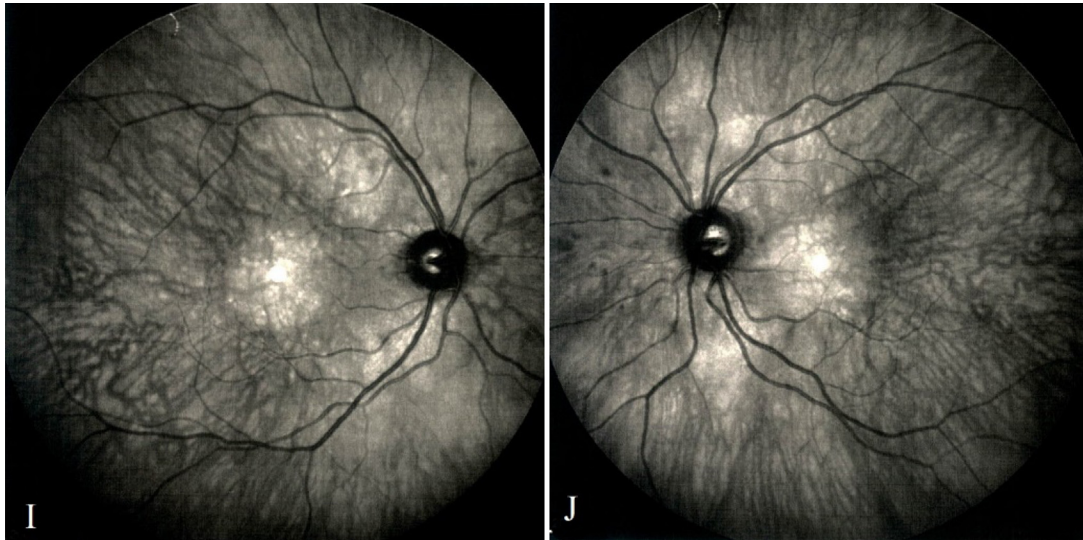


Figure 1. (continued).

findings in the left eye: mild outer retinal atrophy, pseudocyst formation and internal limiting membrane (ILM) draping in SD-OCT (Fig. 1 C, D), fine hyperfluorescent dots temporal to the fovea which showed leakage in the late phase of FA (Fig. 1 E, F), and temporal juxtafoveal hyper-autofluorescence in FAF, which all were typical of MacTel type 2⁴ (Fig. 1 G, H). Hence, diagnosis of MacTel type 2 was considered, and the patient was advised to note for any metamorphopsia or any sudden visual alterations.

She returned 12 months later complaining of worsening of her vision on her left eye. Visual acuity was 10/10 in the right eye and 7/10 in the left eye. Fundusoscopic pictures were unchanged in both eyes (Fig. 2 A, B). While SD-OCT in the left eye showed some minimal progression in atrophic changes of outer retinal layers, it was still completely unremarkable in the right eye.

After a follow-up period of 6 years, the BCVA was 10/10 in the right eye and 6/10 in the left eye, SD-OCT remained normal in the right eye but showed some outward drifting of inner retinal layers in addition to preexisting changes in the left eye (Fig. 3 A, B). While FAF of the left eye shows mild increased hyper-autofluorescence, the FAF of right eye is still normal (Fig. 3 C, D). The en face OCT of both superficial and deep capillary plexuses of the left eye showed hyperreflective

dots as well as dilated and disorganized vascular network in both layers. It is of note that the en face OCT of deep capillary plexus of right eye showed some abnormal changes temporal to the fovea although that these changes were not typical of MacTel type 2 (Fig. 3 G–J). The patient underwent OCTA to find out any subtle evidence of choroidal neovascularization in both eyes. The vessel density map of OCTA showed no remarkable abnormality in both eyes. (Fig. 2 K, L).

Discussion

MacTel type 2 has been described as a bilateral macular disorder which can have asymmetric presentations. Brue et al. reported two cases with unilateral clinical findings. While they found angiographic leakage in one case at the time of initial presentation, the other case showed clinical and angiographic manifestations only after 13 years follow-up.⁵ It is noteworthy that the authors did not perform any other imaging procedure for the latter patient during the time of follow-up. Issa et al. interestingly studied five patients with apparently unilateral MacTel type 2 by means of multimodal imaging and functional testing including microperimetry, visual acuity, reading ability, and Amsler test. They mentioned that even in apparently unilateral cases, some subtle changes

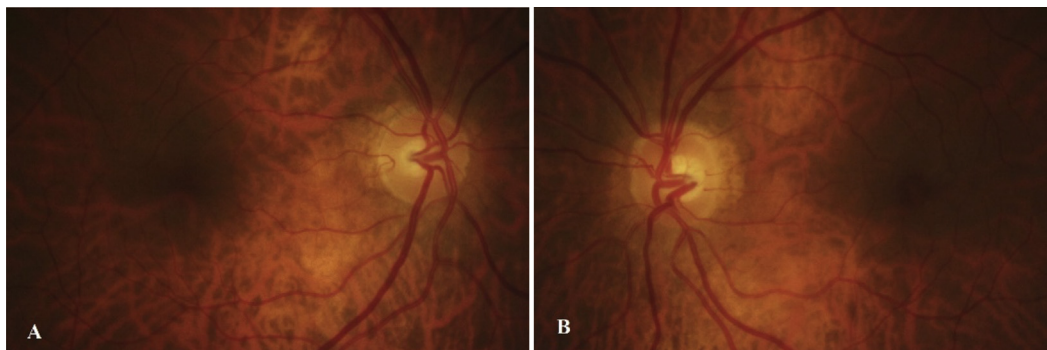


Fig. 2. (A) and (B): Fundus photograph of both eyes after 12 months follow-up showed no obvious change.

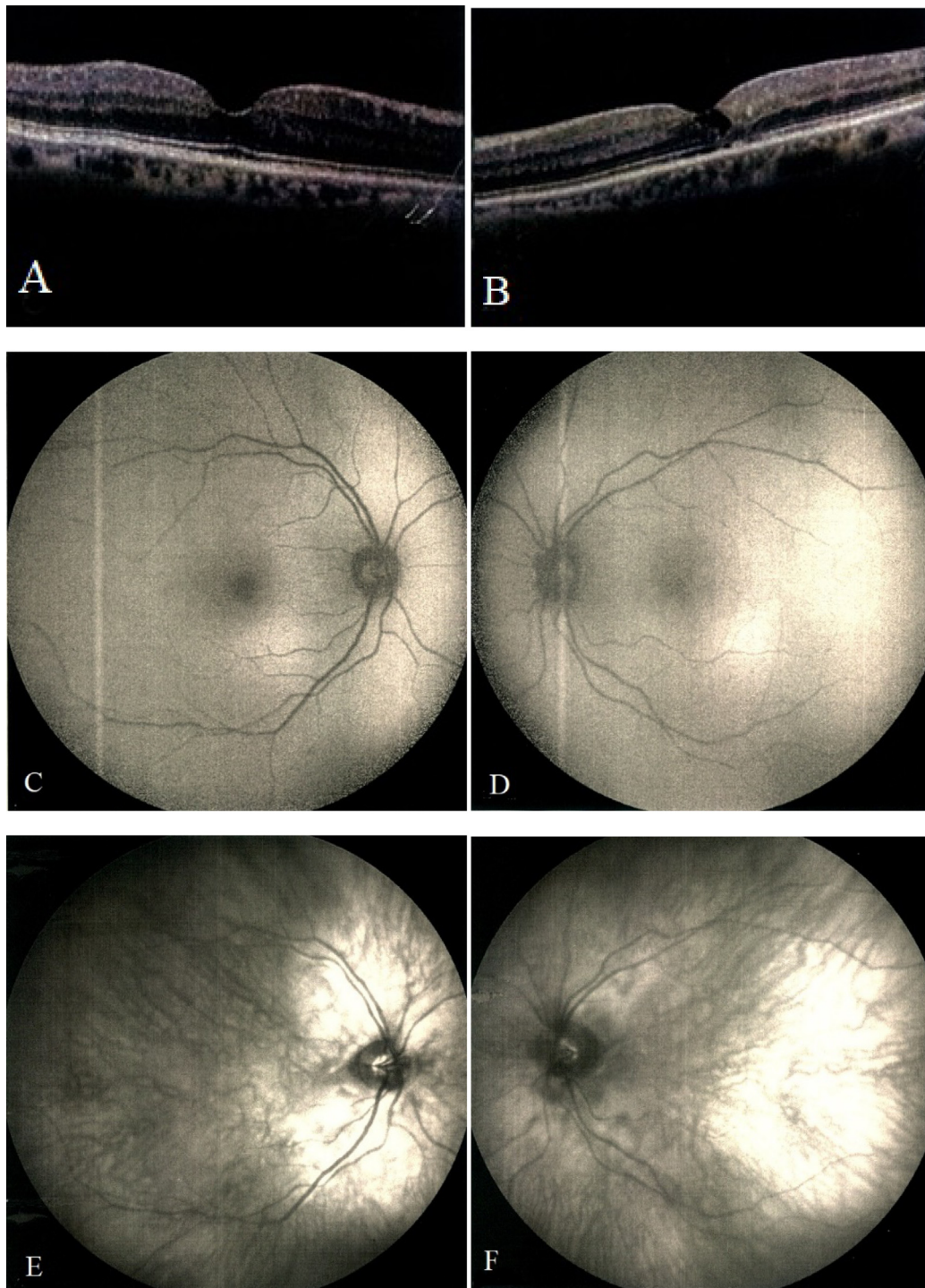


Fig. 3. Last visit: (A), (C), (E), (G) (I) and (K): right eye; (B), (D), (F), (H), (J) and (L): left eye. (A) and (B): spectral-domain optical coherence tomography (SD-OCT) showing outer retinal atrophy with obvious outward drifting of inner retina, pseudocyst formation and internal limiting membrane (ILM) draping on the left eye. (C) and (D): while fundus autofluorescence (FAF) of the left eye shows mild increased hyperautofluorescence, the FAF of the right eye is still normal. (E), (F): infrared reflectance image shows no remarkable change in both eyes. (G) and (H): while en face OCT of superficial capillary plexus in the right eye is normal, it shows hyperreflective dots as well as dilated and disorganized capillary network in the perifoveal region. (I) and (J): en face OCT of deep capillary plexus of the left shows abnormal dilated and disorganized vascular network in the left eye. However, it shows some abnormal and suspicious changes just temporal to the fovea in the right eye which could be attributed to the earliest structural changes in the previously presumed normal eye (K) and (L): vessel density map of OCT-angiography (OCTA) shows no significant change in both eyes.

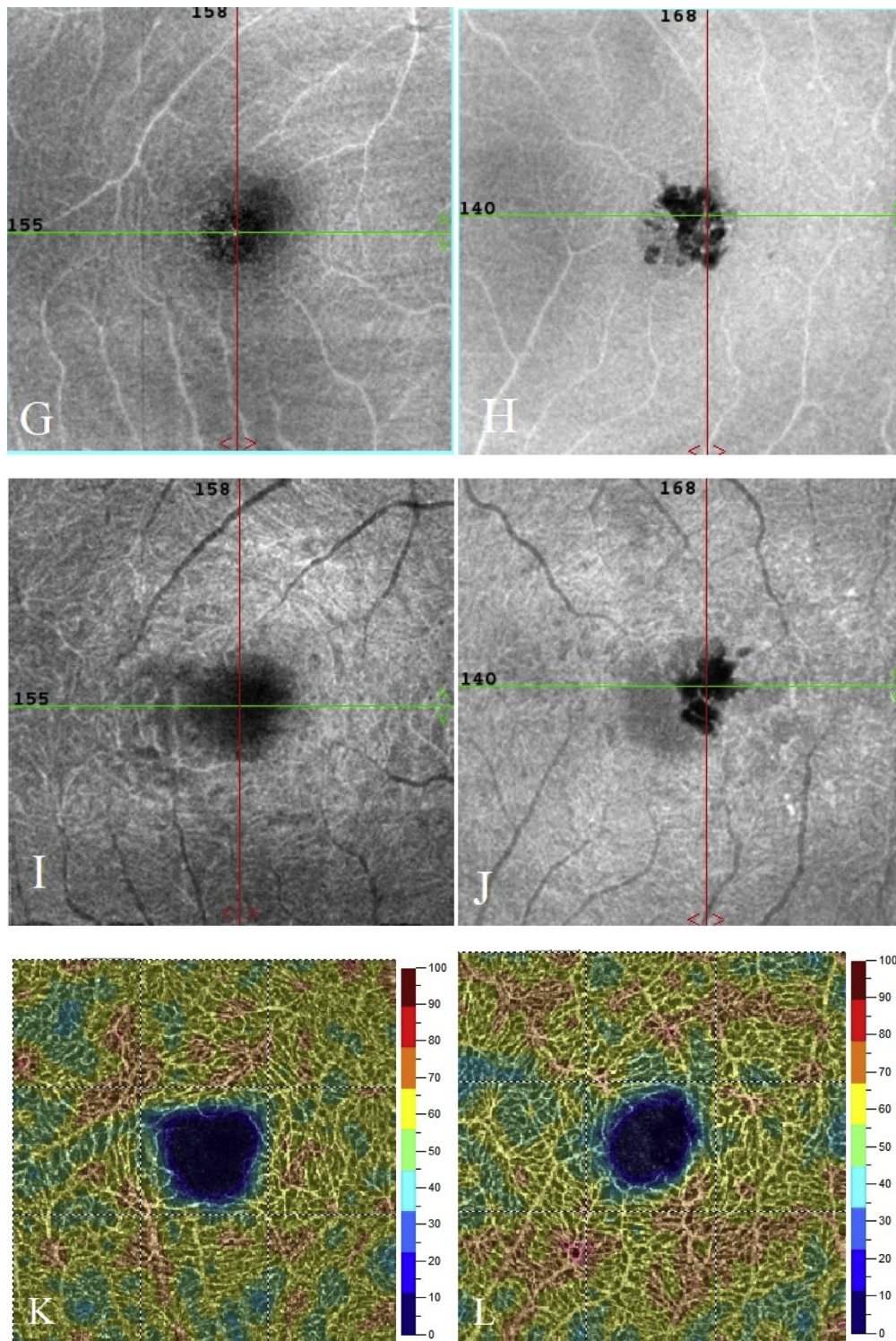


Figure 3. (continued).

would be revealed in the fellow eye including asymmetry in fovea pit, decreased cone density and decrease macular pigment density.⁶ To the best of our knowledge, our case is the first with unilateral presentation of MacTel type 2 which unilaterality of the disease has been confirmed by multimodal imaging including SD-OCT, infrared reflectance, Blue FAF, FA, en face OCT, and OCTA after 6 years follow-up.

To better understand the role of multimodal imaging in MacTel type 2 conundrum, we should consider the interesting pathophysiologic events which take place in a sequential continuum. It has been shown that Müller cells have important role in controlling retinal vasculature in embryology through adulthood by producing antiangiogenic substances maintaining outer retina as an avascular area.⁷ Therefore, loss of Müller

cells and photoreceptors may lead not only to tissue depletion and disfiguration, but also to increased level of free vascular endothelial growth factor in the outer retina.² In the other words, the first pathophysiologic event in MacTel type 2 is a neurodegenerative process with subsequent vascular alterations in the latter stages.⁸ Hence, it is reasonable that significant time gap between these two events may occur and therefore structural findings including disorganization of the inner layers with fusion of the inner retinal layers associated with progressive atrophy of the outer layers, formation of small intraretinal cystoid spaces in OCT, increased autofluorescence (AF) within 1 disk diameter of the foveal center due to the depletion of luteal pigment, and vascular changes detected in en face OCT and OCTA may precede the vascular phenomena such as leakage in FA.⁹ After 6 years, to observe any pathological changes in the other eye, we performed funduscopy examination, infrared reflectance, SD-OCT, FAF, en face OCT, and OCTA. However, normal fundus examination and imaging studies of the fellow eye remained stable during this time (Fig. 3). OCTA is of particular value in the diagnosis of MacTel type 2, whether in the early or late stages of the condition because visualization of the telangiectasia is not obscured by dye leakage as occurs on standard FA. Furthermore, OCTA can clearly distinguish telangiectasia from SRNV and thus avoid unnecessary injections of anti-VEGF agents. Spaide et al. have shown that the most important retinal vascular changes in MacTel type 2 occurred in the deep capillary plexus of the retina, a layer poorly visualized by FA and, to a lesser extent, in the inner vascular plexus. These vessels have been noticed to be thinner, less densely packed, and, in more advanced disease, had an abnormal arrangement.¹⁰ However, the vessel density map of our patient, provided with OCTA, showed no obvious abnormality in either eye.

En face OCT is a non-invasive, and reproducible technique which has been recognized as valuable modality in diagnosis and follow-up of patients with MacTel type 2. It could provide more information than B-scans on intraretinal neovascularization, photoreceptor loss, and choroidal cavitations. Also, en face OCT provides better visualization of the retinal vessels and telangiectasia than FA.¹¹ In our patient, we found hyperreflective dots as well as abnormally dilated and disorganized perifoveal retinal capillary vasculature in the left eye. Although they were not typical, we interestingly found some suspicious changes resembling a capillary drop out just temporal to the fovea in the deep capillary plexus of the right eye which could be related to the earliest structural changes of the presumed normal eye. Although it could be attributed just to an imaging artifact, this finding may highlight the brilliant role of en face OCT to earlier diagnosis of subtle structural

changes in eyes with otherwise normal clinical and imaging findings.

We have to take the other differential diagnosis of MacTel type 2 into account regarding the unusual presentation of this patient. Macular branch retinal vein occlusion (BRVO) would be the potential cause of this picture; however, the patient had neither vascular sheathing in funduscopy examination nor capillary non-perfusion in FA. Two other differential diagnoses worth mentioning are hydroxychloroquine use and radiation retinopathy, which were readily ruled out in our patient based on her medical history.

This case shows that MacTel type 2 can present as a unilateral disease and remain so for a long time, and unilaterality is not a reliable feature for ruling out this diagnosis. The role of multimodal imaging including en face OCT in the diagnosis, follow-up, and management of patients with MacTel type 2 is of utmost importance.

References

1. Chatziralli IP, Sharma PK, Sivaprasad S. Treatment modalities for idiopathic macular telangiectasia: an evidence-based systematic review of the literature. *Semin Ophthalmol.* 2017;32(3):384–394.
2. Spaide RF, Suzuki M, Yannuzzi LA, Matet A, Behar-Cohen F. Volume-rendered angiographic and structural optical coherence tomography angiography of macular telangiectasia type 2. *Retina.* 2017;37(3):424–435.
3. Wu L, Evans T, Arevalo JF. Idiopathic macular telangiectasia type 2 (idiopathic juxtafoveolar retinal telangiectasis type 2A, Mac Tel 2). *Surv Ophthalmol.* 2013;58(6):536–559.
4. Wong WT, Forooghian F, Majumdar Z, Bonner RF, Cunningham D, Chew EY. Fundus autofluorescence in type 2 idiopathic macular telangiectasia: correlation with optical coherence tomography and microperimetry. *Am J Ophthalmol.* 2009;148(4):573–583.
5. Brue C, Tseng JJ, Barbazetto I, Lima LH, Yannuzzi LA. Peculiar manifestation of macular telangiectasia type 2. *Retin Cases Brief Rep.* 2011;5(4):309–312.
6. Charbel Issa P, Heeren TF, Kupitz EH, Holz FG, Berendschot TT. Very early disease manifestations of macular telangiectasia type 2. *Retina.* 2016;36(3):524–534.
7. Hu J, Popp R, Fromel T, et al. Muller glia cells regulate Notch signaling and retinal angiogenesis via the generation of 19,20-dihydroxydocosapentaenoic acid. *J Exp Med.* 2014;211(2):281–295.
8. Ooto S, Hangai M, Takayama K, et al. High-resolution photoreceptor imaging in idiopathic macular telangiectasia type 2 using adaptive optics scanning laser ophthalmoscopy. *Invest Ophthalmol Vis Sci.* 2011;52(8):5541–5550.
9. Coscas G, Coscas F, Zucchiatti I, Bandello F, Soubrane G, Souled E. SD-OCT stages of progression of type 2 macular telangiectasia in a patient followed for 3 years. *Eur J Ophthalmol.* 2013;23(6):917–921.
10. Spaide RF, Klancnik Jr JM, Cooney MJ. Retinal vascular layers in macular telangiectasia type 2 imaged by optical coherence tomographic angiography. *JAMA Ophthalmol.* 2015;133(1):66–73.
11. Wolff B, Basdekidou C, Vasseur V, Sahel JA, Gaudric A, Mauget-Faysse M. “En face” optical coherence tomography imaging in type 2 idiopathic macular telangiectasia. *Retina.* 2014;34(10):2072–2078.