

Primary Sternal Osteomyelitis Caused by *Actinomyces israelii*

Jun Ho Lee, M.D.¹, Seok Chol Jeon, M.D.², Hyo-Jun Jang, M.D.³, Hyuck Kim, M.D.¹,
Young Hak Kim, M.D.¹, Won-Sang Chung, M.D.¹

Primary sternal osteomyelitis is a rare disease. Common infectious organisms causing primary sternal osteomyelitis include *Staphylococcus aureus* and *Pseudomonas aeruginosa*. *Actinomyces* species are common saprophytes of the oral cavity, but there have been few reports in the literature of primary sternal osteomyelitis caused by *Actinomyces* species. We describe a case of primary sternal osteomyelitis caused by *Actinomyces israelii* without pulmonary involvement.

Key words: 1. Actinomycosis
2. Sternum
3. Infection
4. Osteomyelitis

CASE REPORT

A 55-year-old man presented with a fever and upper sternal pain, swelling, and redness. Over the previous 10 days, he had been treated in local clinics for costochondritis. Despite treatment, the pain and swelling rapidly progressed. The patient's past medical history was negative for chest trauma, acupuncture, diabetes mellitus, alcoholism, drug abuse, and tooth extraction. However, he had been scheduled for dental scaling.

On examination, his heart rate was 110 beats per minute, his respiratory rate was 16 breaths per minute, and his temperature was 38.4°C. A mass, approximately 4×4 cm in size, was noted on the upper sternum. The overlying skin was erythematous (Fig. 1).

Preoperative blood tests showed leukocytosis (13,200/mm³) with neutrophilia (10,530/mm³) and an elevated C-reactive protein level (14.7 mg/dL). The chest radiograph findings were unremarkable. Chest computed tomography (CT) revealed an osteolytic lesion in the anterior portion of the sternum, a low-attenuation lesion suggestive of an abscess, and edematous changes in the left pectoralis major (Fig. 2).

He was treated empirically with flomoxef sodium and levofloxacin for presumed osteomyelitis. A fine-needle aspiration biopsy of the mass was performed the day after admission. Despite antibiotics, the patient's fever continued. No organisms were isolated from blood cultures or aspiration cultures. Incision and drainage without resection of the sternum was performed on hospital day six due to persistent and uncontrolled fever.

Departments of ¹Thoracic and Cardiovascular Surgery and ²Radiology, Hanyang University Seoul Hospital, Hanyang University College of Medicine, ³Department of Thoracic and Cardiovascular Surgery, Seoul National University Bundang Hospital, Seoul National University College of Medicine

† This article was presented as a poster presentation at the Chest Wall Interest Group Meeting in Seoul, at the meeting of the Korean Society for Thoracic and Cardiovascular Surgery, June 13, 2013.

Received: September 19, 2014, Revised: October 2, 2014, Accepted: October 13, 2014, Published online: February 5, 2015

Corresponding author: Won-Sang Chung, Department of Thoracic and Cardiovascular Surgery, Hanyang University Seoul Hospital, Hanyang University College of Medicine, 222 Wangsimni-ro, Seongdong-gu, Seoul 133-791, Korea
(Tel) 82-2-2290-8466 (Fax) 82-2-2290-8466 (E-mail) wschung@hanyang.ac.kr

© The Korean Society for Thoracic and Cardiovascular Surgery. 2015. All right reserved.

© This is an open access article distributed under the terms of the Creative Commons Attribution Non-Commercial License (<http://creativecommons.org/licenses/by-nc/3.0>) which permits unrestricted non-commercial use, distribution, and reproduction in any medium, provided the original work is properly cited.

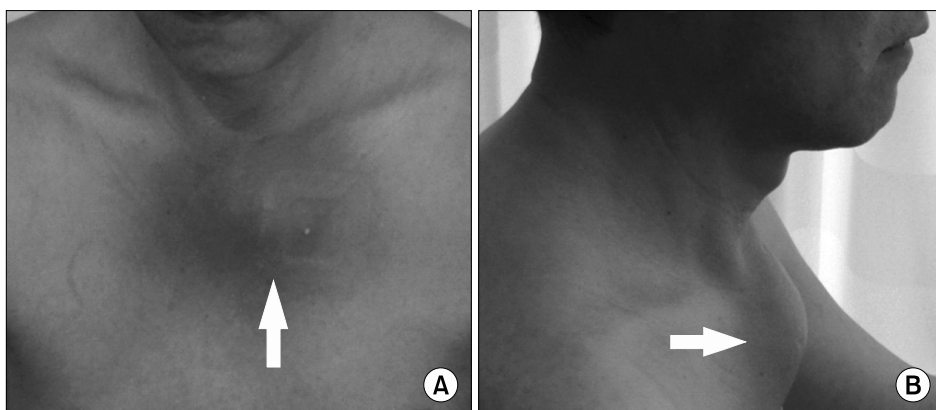


Fig. 1. (A, B) Erythematous sternal mass (arrow) with a white pustule marking the fine needle aspiration biopsy site.

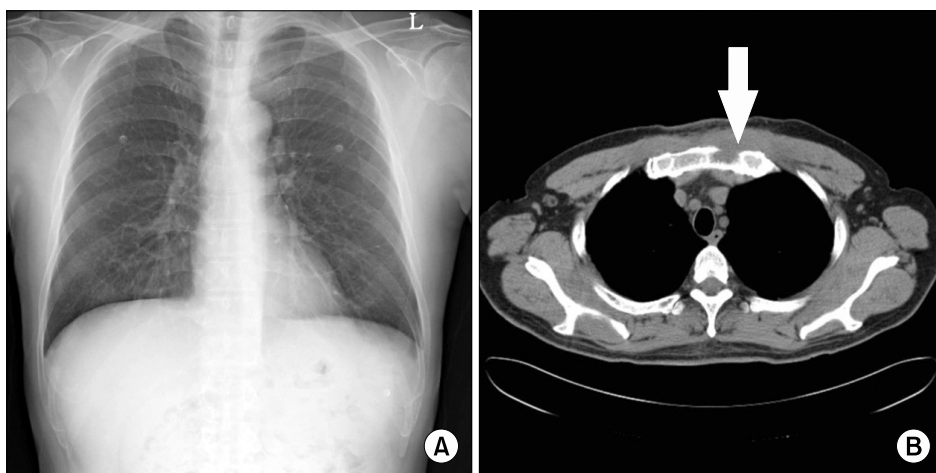


Fig. 2. (A) Chest radiograph showing unremarkable findings. (B) Chest computed tomography image showing an osteolytic lesion in the anterior sternum, a low-attenuation lesion suggestive of an abscess (arrow), and edematous changes in the left pectoralis major.

The diagnosis of actinomycosis was confirmed by histopathology, which revealed a sulfur granule enveloped by an infiltrate of neutrophils and organisms with filaments arranged in a sunburst pattern (Fig. 3). Amoxicillin/clavulanic acid was added to his treatment regimen, and the patient gradually improved, although mild wound dehiscence occurred. The patient was discharged on the tenth postoperative day with mild wound dehiscence. The dehiscence was treated with a disinfectant at an outpatient clinic and had completely healed one month after discharge. A chest CT obtained four months after discharge revealed that the sternum had healed completely.

DISCUSSION

Primary sternal osteomyelitis is rare, and only one case of primary sternal osteomyelitis caused by *Actinomyces israelii* has been reported in the literature [1]. Primary sternal osteo-

myelitis usually presents as redness and swelling with vague chest pain or tenderness over the sternum. The vague chest pain can be confused with costochondritis, and the redness, swelling, and tenderness can be misdiagnosed as cellulitis, Tietze syndrome, sternoclavicular arthritis, or neoplasm [2]. For these reasons, delayed diagnosis and inappropriate treatment are common in primary sternal osteomyelitis. In our case, the patient was misdiagnosed as having costochondritis or Tietze syndrome and was treated inappropriately for 10 days in local clinics while the infection rapidly progressed. Prompt diagnosis and treatment is necessary to avoid inappropriate treatment and progression to a more serious illness such as mediastinitis or bacteremia, which can be fatal.

Various imaging modalities can be used to diagnose sternal osteomyelitis [3]. It takes 10 to 21 days for an osseous lesion to become visible on conventional radiographs. Therefore, a bone scan is useful in differentiating cellulitis from osteomye-

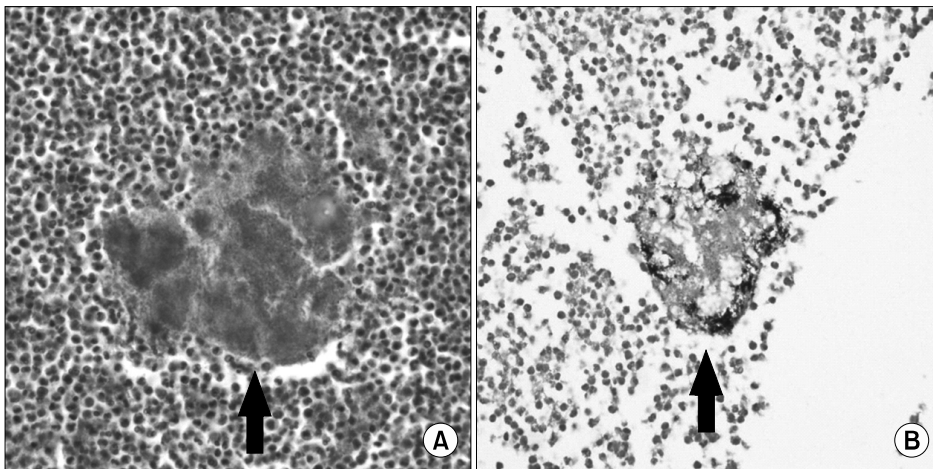


Fig. 3. (A, B) Histopathology of the biopsy revealed a sulfur granule (arrow) enveloped by an infiltrate of neutrophils and organisms with filaments arranged in a sunburst pattern (H&E, $\times 400$).

litis in the early phase of the disease [3]. CT imaging can provide more detailed anatomical information such as soft tissue changes, the extent of posterior cortical bony destruction, and the presence of substernal fluid. In advanced phases of the disease, CT is useful not only for diagnosis but also for treatment planning. In our case, chest CT revealed that the posterior cortical bone was intact, which allowed us to perform an incision and drainage using an open technique.

Soft tissue biopsy is essential in order to exclude primary bone pathology and to obtain a microbiological isolate to direct appropriate antimicrobial therapy. *Staphylococcus aureus* is the most common causative organism of osteomyelitis [2]. *Pseudomonas aeruginosa* is the most common infectious organism in intravenous drug abusers [2]. There has been only one reported case of primary sternal osteomyelitis caused by *Actinomyces israelii* [1], which was the final diagnosis of our patient as well.

Actinomycosis is a chronic and slowly progressive granulomatous disease caused by *Actinomyces* species, which are filamentous gram-positive anaerobic bacteria that colonize the human oropharynx, gastrointestinal tract, and urogenital tract [4]. Direct isolation of the organism from a clinical specimen or from sulfur granules is necessary to make a definitive diagnosis. However, the failure rate of isolating the organism is higher than 50%. The reasons for this include previous antibiotic treatment, overgrowth of concomitant organisms, and inadequate diagnostic methodology [5]. The presence of gram-positive filamentous organisms and sulfur granules on histological examination strongly supports the diagnosis of ac-

tinomycosis [4]. Treatment for actinomycosis is high dose (range, 18 to 24 million units/day) intravenous penicillin G over two to six weeks, followed by a dose of 2 to 4 g/day of oral penicillin V for six to 12 months [4]. Perhaps due to the antibiotics used in preoperative treatment, we could not isolate any organisms from our specimen. However, gram-positive filamentous organisms and sulfur granules were seen on the histologic section. Because our patient suffered from periodontal disease, we believe the *Actinomyces*, which is part of the normal flora of the oral cavity, hematogenously spread to the sternum resulting in primary sternal osteomyelitis.

The treatment of primary sternal osteomyelitis includes prolonged antibiotic therapy, which involves limited resection or radical resection with reconstruction [4]. A few cases (<10%) of primary sternal osteomyelitis will resolve with antibiotic therapy alone [1], but some cases of primary sternal osteomyelitis have been successfully managed with a combination of aspiration for diagnostic purposes and prolonged antibiotic therapy, despite posterior cortical bone destruction and substernal fluid collection [6]. Early surgical treatment should be considered in all cases because it is a definitive treatment that results in decreased morbidity and is more cost-effective [7]. A surgical procedure is necessary in cases of *Pseudomonas aeruginosa* infection or in chronic cases where antibiotics have failed. If not grossly infected, a limited resection is recommended in order to preserve the posterior cortical bone to, in turn, maintain the stability of the bony thorax, which leads to new bone formation [8]. A radical resection with re-

construction may be required if the sternum has been severely damaged from mediastinitis [8].

Although primary sternal osteomyelitis is rare, it should be considered in patients with anterior sternal pain. In advanced disease, chest CT is useful for both in diagnosis and treatment planning. To our knowledge, here we make the first report of primary sternal osteomyelitis in the Republic of Korea caused by *Actinomyces*, which was successfully treated with limited resection and prolonged oral antibiotic therapy.

CONFLICT OF INTEREST

No potential conflict of interest relevant to this article was reported.

REFERENCES

1. Pinilla I, Martin-Hervas C, Gil-Garay E. *Primary sternal osteomyelitis caused by Actinomyces israelii*. South Med J 2006;99:96-7.
2. Gill EA Jr, Stevens DL. *Primary sternal osteomyelitis*. West J Med 1989;151:199-203.
3. Pineda C, Vargas A, Rodriguez AV. *Imaging of osteomyelitis: current concepts*. Infect Dis Clin North Am 2006;20:789-825.
4. Brook I. *Actinomycosis: diagnosis and management*. South Med J 2008;101:1019-23.
5. Bennhoff DF. *Actinomycosis: diagnostic and therapeutic considerations and a review of 32 cases*. Laryngoscope 1984;94:1198-217.
6. Upadhyaya M, Keil A, Thonell S, Orford J, Burgner D. *Primary sternal osteomyelitis: a case series and review of the literature*. J Pediatr Surg 2005;40:1623-7.
7. Lin JC, Miller SR, Gazzaniga AB. *Primary sternal osteomyelitis*. Ann Thorac Surg 1996;61:225-7.
8. Mir-Sepasi MH, Gazzaniga AB, Bartlett RH. *Surgical treatment of primary sternal osteomyelitis*. Ann Thorac Surg 1975;19:698-703.