

A sectional-splinting technique for impressing multiple implant units by eliminating the use of an open tray

SURYAKANT C. DEOGADE, GUNJAN DUBE¹

Abstract

Since the inception of root form implant dentistry by P-I Branemark in the early 1980's, so many technical advances have been put forward by several authors. However, the open tray impression technique is still performed for impressing multiple implant fixtures as it was first described in the original Branemark procedure manual. The most critical aspect for a successful implant-supported restoration is the passive and an accurate fit of superstructures to avoid preload and loading stresses. Splinting impression technique in multiple implants has gained popularity. Auto-polymerizing acrylic resin is among the most routinely practiced splinting material for multiple implant units. However, unfortunately, it exhibits shrinkage, which makes an impression quite inaccurate. This case report presents the solution to minimize the shrinkage of resin by utilizing sectional-splinting technique as advocated in the previous implant literature.

Keywords: Auto-polymerizing resin, impression copings, passive fit, splinting, superstructure

Introduction

Once the remaining natural teeth are lost, patients are faced with a difficult and challenging state of edentulism.^[1] This state is mostly associated with discomfort and psychological stress.^[2] The conventional treatment modality for such patients would be the removable denture prosthesis. However, with increased amount of resorption of the residual alveolar ridge, the denture bases become less stable and retentive. This, consequently, leads to the deterioration in natural appearance and masticatory performance. It is a fact that the chewing efficiency of complete denture wearers is considerably lower than that of individuals with natural teeth.

Osseointegrated implants provide an alternative treatment for such individuals to improve the retention, stability, and function of the mandibular complete denture prosthesis.^[3,4] Dental implants have proven to improve self-perceived oral health, chewing function, speech, and even social contacts.^[5-7] The

prime concern of fabricating implant-supported restorations is the preparation of superstructures that possess accurate fit when joined to multiple abutments.^[8-10] Due to uniqueness of the implant-bone relationship, a slight misfit of the superstructure will result in the accumulation of preload and loading stresses in the implant-supported restorative complex. These stresses may lead to marginal bone loss and failure of implants due to loss of osseointegration as well as in relation to mechanical problems as loosening of screws and fatigue fractures of implant components.^[11-16]

The prime requirements for obtaining an accurate fit are accurate impression. In the literature, several impression methods have been discussed for multiple implants. Among, splinted impression technique has gained popularity and proven to be the most accurate while impressing multiple implants.^[17,18] The most commonly used material for splinting is an auto-polymerizing acrylic resin, which exhibits polymerization shrinkage. Thus, minimizing the shrinkage of the acrylic resin becomes the most important factor to ensure an accurate impression while performing splint technique. Some authors advocated to section the splint material connection leaving a thin gap and then to rejoin with a small amount of the same material to minimize the shrinkage. While others connected all of the impression copings with splint material and then waited for complete polymerization of the material.^[19-22]

This case report presents a sectional-splinting technique for obtaining an accurate impression of multiple implants by eliminating the use of an open tray.

Case Report

A 47-year-old medically fit female with good oral hygiene and no history of smoking reported the Department of

Departments of Prosthodontics, and ¹Oral Surgery, Hitkarini Dental College and Hospital, Jabalpur, Madhya Pradesh, India

Correspondence: Dr. Suryakant C. Deogade, Flat No. 502, Block-D, Apsara Apartment, South Civil Lines, Pachpedi Road, Jabalpur - 482 001, Madhya Pradesh, India.
E-mail: dr_deogade@yahoo.co.in

Access this article online	
Quick Response Code: 	Website: www.contemplindent.org
	DOI: 10.4103/0976-237X.132347

Prosthodontics, demanding a new restoration for her mandible. She complained about her unretentive and unstable lower denture. In the maxillary arch, she had esthetically unsatisfactory fixed partial denture with 23 and 25 regions that she did not want to replace at the time. Even her 16 and 26 were missing which she denied for replacement. Her main concern was to replace the existing lower denture with a fixed prosthesis to restore function, phonetics, and a natural appearance. She was given an option of new conventional complete denture or implant-supported removable overdenture, which she rejected and requested for fixed prosthesis. Therefore, it was decided to insert six interforaminal implants and fabricate a cement-retained fixed prosthesis using a sectional-splinting technique.

Prosthetic Procedures

A new lower complete denture with correct vertical and horizontal dimensions was prepared to plan the proper implant positions. Six implants (ADIN Dental Implants Sys. Ltd., Israel) were placed and allowed to heal submerged for 3 months.

When implant re-exposure and soft-tissue management were completed, all healing abutments were removed and closed tray impression copings (ADIN Dental Implants Sys. Ltd., Israel) were inserted [Figure 1]. Radiologically seating of copings was confirmed and then an impression was made with addition silicone (Reprosil; Dentsply DeTrey GmbH, Konstanz, Germany). Impression copings were then removed and healing abutments replaced. Impression copings along with analogs (ADIN Dental Implants Sys. Ltd., Israel) were oriented properly in the impression [Figure 2] and the cast was then poured in type IV dental stone (KALROCK, Kalabhai Karson Pvt. Ltd., Mumbai, India) [Figure 3]. After retrieval of cast, pattern resin (GC Pattern Resin; GC Corp., Tokyo, Japan) was used to build an acrylic scaffold around the impression copings [Figure 4]. In this way, an acrylic bar was prepared and was allowed to cure for 24 h. It was then milled using a 2° bur on a milling machine, and retention dimples were placed buccally and lingually. The bar was then sectioned into six individual pieces with the help of handpiece diamond disk (Komet 911 H; Gebr. Brasseler GmbH, Lemgo, Germany) and a 0.2 mm gap space was left between single pieces [Figure 5]. The cut pieces were given numbers [Figure 6] and were planned to connect just before the impression procedure with an incremental application technique to minimize polymerization shrinkage of the resin.^[23,24]

The patient was called for next appointment and was seated and the healing abutments were removed. All of the numbered impression copings were removed from the model and were screwed into their corresponding implant in the mouth. After complete adjustments, a radiograph was obtained to confirm the proper seating of copings to the implants. After that, the pattern resin was used to lute

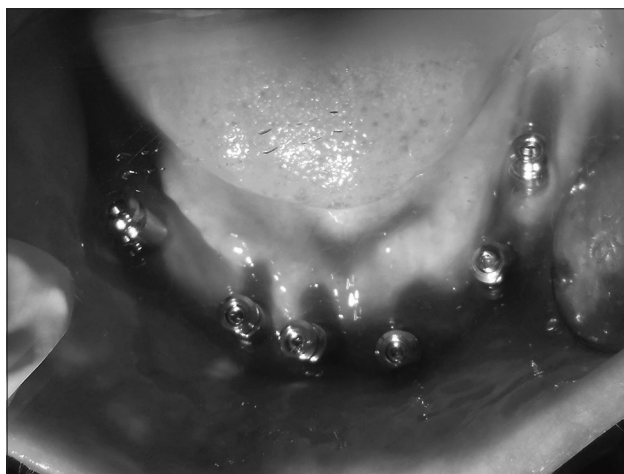


Figure 1: Closed tray impression copings attached

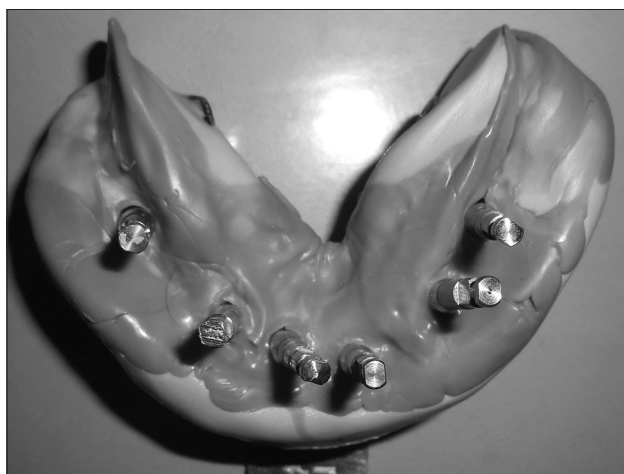

Figure 2: Copings and analogs oriented in impression

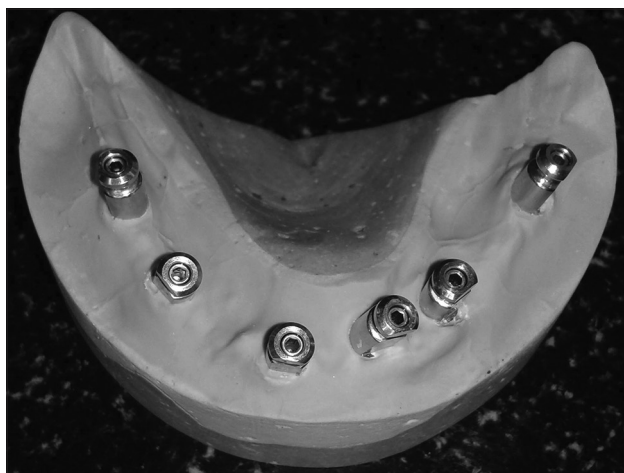

Figure 3: Cast poured for splinting

the acrylic wings together [Figure 7]. The resin was allowed to set for 10 min.

Once the resin was completely polymerized the prosthetic screws were fully tightened to 20 Ncm and the screw

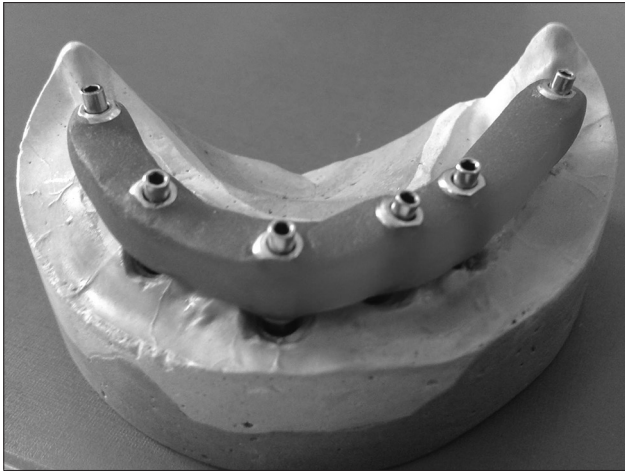


Figure 4: Pattern resin bar fabricated

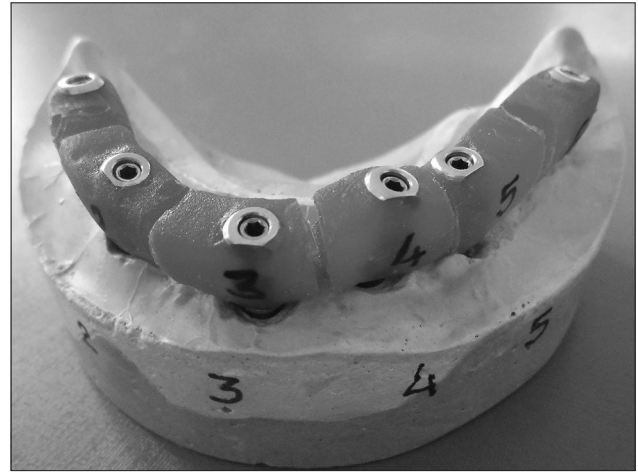


Figure 5: Resin bar sectioned and numbered




Figure 6: Sectioned pieces marked with numbers

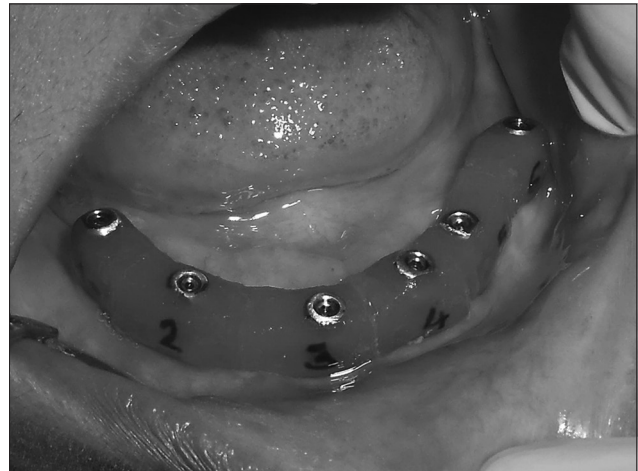

Figure 7: Bar positioned in patients' mouth

access holes in the impression copings were blocked with elastomer. VPS impression material was then injected into a stock tray and inserted over the acrylic bar and allowed to set. After that, the tray was easily removed from the patients' mouth and the impression was inspected. The bar was then removed in one piece and the healing abutments were replaced. The patient was given their provisional prosthesis and dismissed.

The analogs were attached to the impression copings [Figure 8] and the entire assembly was then reinserted into the definitive impression [Figure 9]. The retentive dimples in the acrylic bar allowed the bar to "snap" back into place in the definitive impression. The gingival soft-tissue material (Esthetic Mask, DETAX, Ettlingen/Germany) was injected over the undersurface of the bar and the model was poured in type V stone (ULTRAROCK, Kalabhai Karson Pvt. Ltd., Mumbai, India). On this model, a record base with a wax rim was fabricated to record patient's maxillo-mandibular relation. After that the mounting was completed and the abutments were screwed for their preparation. The casting procedure was

completed [Figure 10] and metal try-in was done and the model was again sent to laboratory for the fabrication of metal-ceramic restorations [Figure 11].

The metal-ceramic prosthesis was checked in patients' mouth for any occlusal interferences and cementation procedure performed [Figure 12]. Patient was educated about the oral hygiene maintenance protocols and recalled for regular check-up. Patient's expectations were fulfilled in concern to the function and the natural appearance.

Discussion

A successful implant-supported restoration can be achieved only when it exhibits a passive fit on the osseointegrated implants. While tightening the prosthetic screws to attach the superstructure to the abutments, an undue torque can jeopardize the outcome of treatment. In case a passive fit is not obtained, then the superstructure is usually sectioned, repositioned, and soldered. Therefore, the reproduction of accurate master cast is essential to achieve the same position of the abutments in the patient's mouth.



Figure 8: Analogs attached to bar

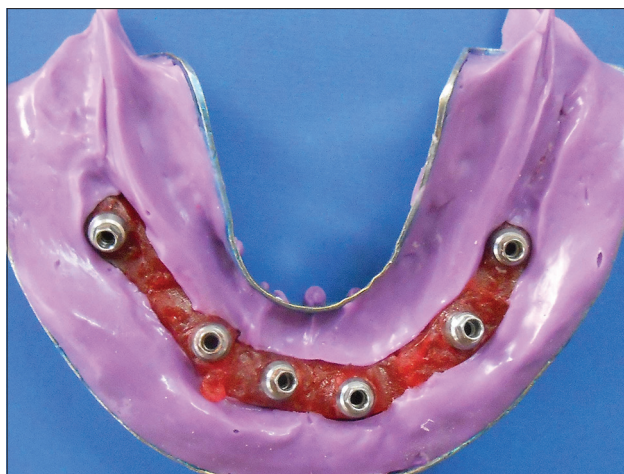

Figure 9: Bar-analog assembly oriented in impression

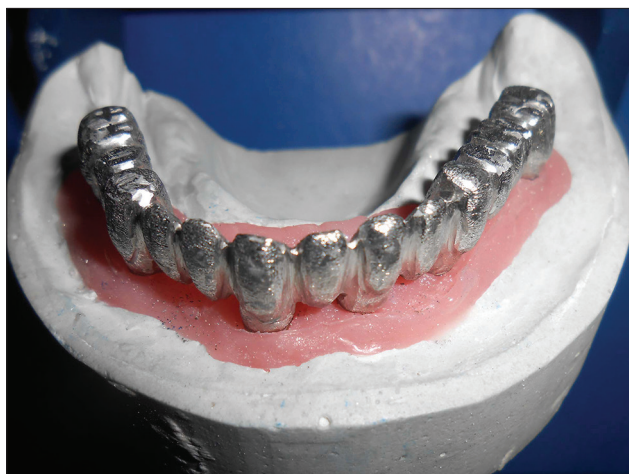

Figure 10: Metal copings fabrication

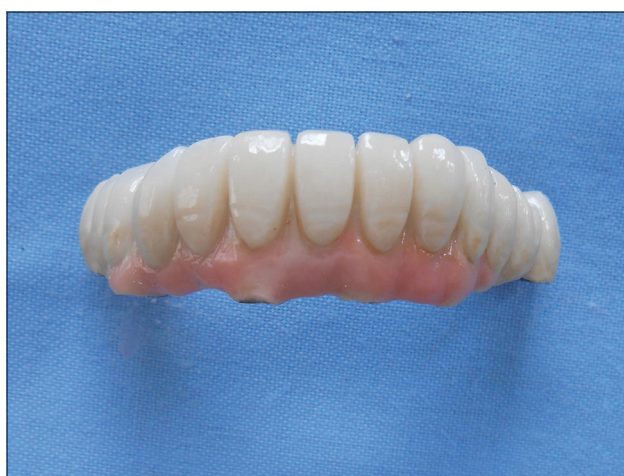

Figure 11: Cement-retained fixed prosthesis

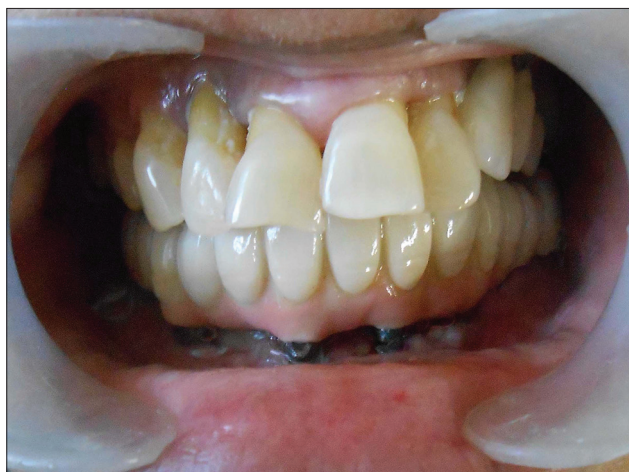

Figure 12: Prosthesis cemented in patients' mouth

An important factor that decides precision fit of superstructure is the accuracy of impression. Several literatures are available about the accuracy of fit between superstructures and abutments.^[14,17,18] The accuracy of fit is mandatory due to the unique quality of the implant-bone relationship. A slight inaccuracy of fit can result in the accumulation of preload and loading stresses in the

implant-crown complex. These problems can lead to screw loosening and ultimately loss of osseointegration.^[11-16] Therefore, an accurate fit of superstructures in the clinical conditions is the prime requisite to avoid the accumulation of stresses and strains which might cause an uncontrolled implant loading.^[25-28] The splinted impression technique has been shown to be a primary factor in increasing the precision of fit of the implant-supported restorative complex.^[17,18,29]

It has been shown that the splinting technique using acrylic resin can cause incomplete polymerization^[19-22] and shrinkage during polymerization process. These factors create stresses at the impression coping acrylic resin interface.^[30] It has been shown that the total shrinkage of acrylic resin is between 6.5% and 7.9% in the first 24 h, with 80% of shrinkage occurring in the first 17 min after mixing.^[23]

Open tray impression technique is most frequently practiced while impressing multiple implant units. This technique exhibits certain drawbacks which are as follows:

1. It requires an accurate modification of a stock tray over multiple impression copings, which is a messy and time-consuming process
2. Drilling accurate holes in the tray for the guide screws is more tedious job in multiple implant units
3. Fabrication of an acrylic splinting to attach the impression copings together is very time-consuming and frustrating
4. After completion of splinting, it takes acrylic over 24 h to fully cure without shrinkage
5. Aligning the holes in the filled tray with the guide screws is a blind procedure. Also, the care is taken that the guide screws should penetrate through the filled tray easily
6. Once the impression material sets, the length of the guide screws makes it difficult for the clinician to unscrew it in the posterior area
7. If the impression is not acceptable, then all the impression copings must be removed from the impression and the whole procedure repeated.

All of the above problems make the open tray impression procedure very time-consuming and stressful for the clinician, staff, and the patient. This case presentation describes a clinical approach where multiple implant units have to be restored with fixed prosthesis, by eliminating the use of an open tray procedure. The technique describes the utilization of sectional-splinting method to achieve an accurate impression. The sectioned units were rejoined in the patients' mouth with the resin material and the definitive impression was obtained. This approach minimizes the polymerization shrinkage of resin and helps to reproduce the same relationship of implants as that of in the patients' mouth.

Conclusion

This case report describes a clinical technique for impressing multiple implant units as described in the previous literatures. This technique saves valuable clinical chair time as well as provides a much more predictable and accurate final impression. After 6 months' evaluation, the outcome of the implant-supported prosthesis was successful and the patient was quite satisfied.

References

1. Straus R, Sandifer JC, Hall DS, Haley JV. Behavioral factors and denture status. *J Prosthet Dent* 1977;37:264-73.
2. Mersel A, Babayof I, Berkey D, Mann J. Variables affecting denture satisfaction in Israeli elderly: A one year follow-up. *Gerodontology* 1995;12:89-94.
3. Van Steenberghe D, Quirynen M, Calberson L, Demanet M. A prospective evaluation of the fate of 697 consecutive intra-oral fixtures ad modum Branemark in the rehabilitation of edentulism. *J Head Neck Pathol* 1987;6:53-8.
4. Sadowsky SJ. Mandibular implant-retained overdentures: A literature review. *J Prosthet Dent* 2001;86:468-73.
5. Allen PF, McMillan AS, Walshaw D. A patient-based assessment of implant-stabilized and conventional complete dentures. *J Prosthet*

- Dent 2001;85:141-7.
6. Awad MA, Locker D, Korner-Bitensky N, Feine JS. Measuring the effect of intra-oral implant rehabilitation on health-related quality of life in a randomized controlled clinical trial. *J Dent Res* 2000;79:1659-63.
7. Heydecke G, Thomason JM, Lund JP, Feine JS. The impact of conventional and implant supported prostheses on social and sexual activities in edentulous adults Results from a randomized trial 2 months after treatment. *J Dent* 2005;33:649-57.
8. Lekholm U, Adell RM, Brånemark PI. Complications. In: Brånemark PI, Zarb GA, Albrektsson T, editors. *Tissue-Integrated Prostheses: Osseointegration in Clinical Dentistry*. Chicago: Quintessence; 1985. p. 233-40.
9. Rangert B, Jemt T, Jörneus L. Forces and moments on Branemark implants. *Int J Oral Maxillofac Implants* 1989;4:241-7.
10. Adell R, Lekholm U, Rockler B, Brånemark PI. A 15-year study of osseointegrated implants in the treatment of the edentulous jaw. *Int J Oral Surg* 1981;10:387-416.
11. Albrektsson T, Jansson T, Lekholm U. Osseointegrated dental implants. *Dent Clin North Am* 1986;30:151-74.
12. Cox JF, Zarb GA. The longitudinal clinical efficacy of osseointegrated dental implants: A 3-year report. *Int J Oral Maxillofac Implants* 1987;2:91-100.
13. Skalak R. Biomechanical considerations in osseointegrated prostheses. *J Prosthet Dent* 1983;49:843-8.
14. Henry PJ. An alternative method for the production of accurate casts and occlusal records in osseointegrated implant rehabilitation. *J Prosthet Dent* 1987;58:694-7.
15. Davis DM, Zarb GA, Chao YL. Studies on frameworks for osseointegrated prostheses: Part 1. The effect of varying the number of supporting abutments. *Int J Oral Maxillofac Implants* 1988;3:197-201.
16. Worthington P, Bolender CL, Taylor TD. The Swedish system of osseointegrated implants: Problems and complications encountered during a 4-year trial period. *Int J Oral Maxillofac Implants* 1987;2:77-84.
17. Assif D, Fenton A, Zarb G, Schmitt A. Comparative accuracy of implant impression procedures. *Int J Periodontics Restorative Dent* 1992;12:112-21.
18. Assif D, Marshak B, Schmidt A. Accuracy of implant impression techniques. *Int J Oral Maxillofac Implants* 1996;11:216-22.
19. Inturregui JA, Aquilino SA, Ryther JS, Lund PS. Evaluation of three impression techniques for osseointegrated oral implants. *J Prosthet Dent* 1993;69:503-9.
20. Hsu CC, Millstein PL, Stein RS. A comparative analysis of the accuracy of implant transfer techniques. *J Prosthet Dent* 1993;69:588-93.
21. Naconecy MM, Teixeira ER, Shinkai RS, Frasca LC, Cervieri A. Evaluation of the accuracy of 3 transfer techniques for implant-supported prostheses with multiple abutments. *Int J Oral Maxillofac Implants* 2004;19:192-8.
22. Del'Acqua MA, Arioli-Filho JN, Compagnoni MA, Mollo Fde A Jr. Accuracy of impression and pouring techniques for an implant-supported prosthesis. *Int J Oral Maxillofac Implants* 2008;23:226-36.
23. Mojon P, Oberholzer JP, Meyer JM, Belser UC. Polymerization shrinkage of index and pattern acrylic resins. *J Prosthet Dent* 1990;64:684-8.
24. Assif D, Marshak B, Nissan J. A modified impression technique for implant-supported restoration. *J Prosthet Dent* 1994;71:589-91.
25. Lie A, Jemt T. Photogrammetric measurements of implant positions. Description of a technique to determine the fit between implants and superstructures. *Clin Oral Implants Res* 1994;5:30-6.
26. Hoshaw S. Investigation of bone modelling and remodeling at a loaded bone-implant interface [thesis]. Troy, NY: Rensselaer Polytechnic Institute; 1992.
27. Frost HM. Vital biomechanics: Proposed general concepts for skeletal adaptations to mechanical usage. *Calcif Tissue Int*

- 1988;42:145-56.
28. Jemt T. Failures and complications in 391 consecutively inserted fixed prostheses supported by Brånemark implants in edentulous jaws: A study of treatment from the time of prosthesis placement to the first annual checkup. *Int J Oral Maxillofac Implants* 1991;6:270-6.
29. Barrett MG, de Rijk WG, Burgess JO. The accuracy of six impression techniques for osseointegrated implants. *J Prosthodont* 1993;2:75-82.
30. O'Brien WJ. *Dental Materials and Their Selection*. 2nd ed. Chicago: Quintessence; 1997. p. 100-1.

How to cite this article: Deogade SC, Dube G. A sectional-splinting technique for impressing multiple implant units by eliminating the use of an open tray. *Contemp Clin Dent* 2014;5:221-6.

Source of Support: Nil. **Conflict of Interest:** None declared.

Dispatch and return notification by E-mail

The journal now sends email notification to its members on dispatch of a print issue. The notification is sent to those members who have provided their email address to the association/journal office. The email alerts you about an outdated address and return of issue due to incomplete/incorrect address.

If you wish to receive such email notification, please send your email along with the membership number and full mailing address to the editorial office by email.