

# Atypical recurrent Kawasaki disease with retropharyngeal involvement: A case study and literature review

Rachel K. Cason<sup>1,2</sup>, Umakumaran P. Ponniah<sup>1</sup>, Elizabeth S. Makil<sup>1</sup>, Mary C. Niu<sup>1,3</sup>

<sup>1</sup>Department of Pediatrics, University of Oklahoma Health Sciences Center, Oklahoma City, Oklahoma, USA, <sup>2</sup>Department of Pediatrics, Duke University School of Medicine, Durham, North Carolina, USA, <sup>3</sup>Department of Pediatrics, University of Utah Health Sciences Center, Primary Children's Hospital, Salt Lake City, Utah, USA

## ABSTRACT

Kawasaki disease (KD) is a systemic inflammatory condition primarily affecting young children. We present an adolescent male with two episodes of complete KD between the age of 2 and 14 years. At age 14, he presented with findings suggestive of a retropharyngeal abscess. This was later determined to be a recurrence of KD, diagnosed after the development of coronary artery aneurysms. Our case reinforces the role of maintaining a high index of suspicion for KD, both in patients with prior KD episodes and in those with persistent fever who do not fulfill the diagnostic criteria for typical KD. This is particularly important for patients presenting with atypical symptoms not commonly associated with KD, such as inflammation of the retropharyngeal and parapharyngeal spaces.

**Keywords:** Coronary aneurysm, Kawasaki, retropharyngeal abscess

## INTRODUCTION

Kawasaki disease (KD) is a systemic inflammatory condition predominantly affecting children between the ages of 1 and 9 years.<sup>[1,2]</sup> KD can be diagnosed or suspected with proposed American Heart Association or Japanese Ministry criteria. Evidence of coronary artery (CA) involvement can be further added to establish the diagnosis of KD.<sup>[3]</sup> While most patients experience complete resolution and subsequently remain symptom-free, a small proportion experience recurrence.<sup>[4]</sup> Here, we describe an adolescent male with multiple KD recurrences, whose third recurrence manifested as fever and inflammation in the retropharyngeal space, and culminated in the development of coronary artery aneurysms (CAA).

## CLINICAL PRESENTATION

A 14-year-old African-American male (52 kg, 171 cm, and 1.56 m<sup>2</sup>) presents with 3 days of fever to 102°F, left

neck swelling, dysphagia, and painful neck movement. Two weeks before the presentation, he had had 3–5 days of mild congestion and cough. His medical history was significant for KD at 12 and 14 months of age. Both episodes were treated with intravenous immunoglobulin (IVIG) and acetylsalicylic acid (ASA); there was no CA involvement. He has otherwise been healthy.

Physical examination reveals a mildly erythematous oropharynx as well as prominent and painful swelling of the left neck. The tongue and lips are normal in appearance. There is no rash, conjunctival injection, or swelling of the hands and feet. Initial laboratory results demonstrate the following: white blood cells (WBC) 19.61 k/mm<sup>3</sup> (granulocytes 73.5%, immature granulocytes 0.9%, lymphocytes 11.2%, monocytes 14.0%, eosinophils 0.0%, and basophils 0.07%), Hb 14.7 g/dl, Hct 43.8%, platelets 229 k/mm<sup>3</sup>, erythrocyte sedimentation rate (ESR)

This is an open access journal, and articles are distributed under the terms of the Creative Commons Attribution-NonCommercial-ShareAlike 4.0 License, which allows others to remix, tweak, and build upon the work non-commercially, as long as appropriate credit is given and the new creations are licensed under the identical terms.

**For reprints contact:** reprints@medknow.com

**How to cite this article:** Cason RK, Ponniah UP, Makil ES, Niu MC. Atypical recurrent kawasaki disease with retropharyngeal involvement: A case study and literature review. *Ann Pediatr Card* 2020;13:244-7.

### Access this article online

Quick Response Code:



Website:

www.annalspc.com

DOI:

10.4103/apc.APC\_89\_19

**Address for correspondence:** Dr. Mary C. Niu, Department of Pediatrics, Division of Pediatric Cardiology, Primary Children's Hospital Eccles Outpatient Services Building, Salt Lake City 84113, Utah, USA. E-mail: mary.niu@hsc.utah.edu

Submitted: 13-Jun-2019

Revised: 16-Oct-2019

Accepted: 03-Apr-2020

Published: 11-Jun-2020

18 mm/h, and C-reactive protein (CRP) 63.1 mg/l. On head and neck computed tomography (CT), there is an ill-defined fluid collection in the left retropharyngeal space with early phlegmonous changes. Antibiotics are started for presumed retropharyngeal abscess.

Over the next 48 h, fever and neck pain persist, and the patient develops left anterior cervical lymphadenopathy measuring 2 cm × 2 cm. His failure to respond to antibiotics prompts consideration of noninfectious and additional infectious etiologies. An echocardiogram is performed and is normal. The retropharyngeal fluid collection is drained surgically; drainage reveals serosanguinous fluid without purulence. Culture and Gram stain of the fluid and blood are sent and ultimately return negative.

## HOSPITAL COURSE

Polymerase chain reaction 20 and workup for streptococcus pharyngitis, Epstein-Barr virus, Adenovirus, and tularemia were negative, as were cultures from the surgical drainage. Notably, Antistreptolysin O (ASO) was normal at 28 u/ml, and throat swab cultures demonstrated normal oral flora. Because the infectious workup remained negative, a second echocardiogram was obtained on hospital day (HD) 6 to reassess for KD – this demonstrated mild dilation and ectasia of the left main CA (LMCA) (4.4 mm, z-score 1.7); mild dilation of the left anterior descending artery (LAD) (4.5 mm, z-score 4.2); normal right CA (RCA) (3.4 mm, z-score 1.27); and circumflex arteries (2.9 mm). A diagnosis of KD was made. High-dose ASA (80 mg/kg/day) was started, and IVIG (2 g/kg) was administered. On HD 7, the patient developed abdominal pain, diarrhea, and cracked red lips. Laboratory values continued to demonstrate severe systemic inflammation: CRP 151.7 mg/L, ESR >145 mm/h, Hb 8.8 g/dl, WBC 22.5 k/mm<sup>2</sup>, serum Na 131 mEq/l, and albumin 3 g/dl.

A third echocardiogram was obtained to re-evaluate the CAs and showed CAA progression [Figure 1]: The LAD had bead-like aneurysms (8.1 mm–8.6 mm proximally [z-score: 13.2–13.9] and 6 mm distally [z-score: 7.9]); the RCA was dilated at 5.3 mm × 6.9 mm (z-scores: 5.1 and 8.5, respectively); LMCA dimensions remained unchanged. Due to CAA progression and severity, CT coronary angiography was performed [Figure 2] and confirmed the echocardiographic findings. The patient was given one dose of infliximab (10 mg/kg) and started on enoxaparin thromboprophylaxis (1 mg/kg BID), cyclosporine (10 mg/kg/day divided BID), and atorvastatin (10 mg QD) for its anti-inflammatory effects; his ASA was decreased to low dose (81 mg QD) when he defervesced after HD 6. His echocardiogram, thereafter, remained stable, and he was discharged once CRP levels were <1.2 mg/μg. As an outpatient, he remained on a 2-week cyclosporine taper,

atorvastatin, low-dose ASA, and warfarin. Follow-up echocardiograms at 2 weeks and 2 months demonstrated stable aneurysms and dilation.

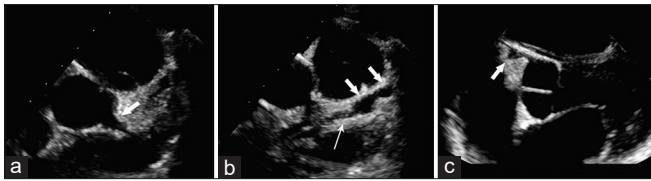
## DISCUSSION

KD is an acute vasculitis of medium-sized vessels primarily affecting young children between ages 1 and 9 years.<sup>[1,2]</sup> When diagnosing KD, it is important to recognize its complete and incomplete presentations. Incomplete KD is more common in infants ≤1 year and children ≥9 years<sup>[2,3]</sup> and may be diagnosed when ≥5 days of unexplained fever is associated with 2 or 3 of the principal clinical features of KD.<sup>[3]</sup> Early echocardiography is particularly helpful in diagnosing incomplete KD and can help prevent catastrophic complications by prompting earlier treatment. Other helpful laboratory findings in making the diagnosis of incomplete KD include hypoalbuminemia, anemia, elevated alanine aminotransferase, thrombocytosis, leukocytosis, and sterile pyuria.<sup>[3]</sup>

Recurrent KD is uncommon, occurring in approximately 2%–4% of patients with KD, with incidence rates of 4–7/1000 person-years. Although KD is more likely to recur within the first 2 years after the initial episode,<sup>[5,6]</sup> recurrence as late as 18 years has been described.<sup>[7]</sup> Similarly, multiple recurrences of KD in a single patient are rare. Yanagawa *et al.* found that only 0.2% of patients in a Japanese survey had three or more episodes.<sup>[8]</sup> Falcini *et al.* reported a case of a 3-year-old boy who had four episodes of KD within 33 months.<sup>[9]</sup> Although data regarding risk factors for multiple recurrences is sparse, interactions between genetic propensity and environmental factors, as well as immune and geographic susceptibilities have been proposed.<sup>[10,11]</sup>

This case highlights the importance of performing serial echocardiography when fever persists, and inflammatory markers remain high, even when there is no obvious initial CA involvement. CA injury is due in part to the effect of the immune response on the endothelium and layers of the artery.<sup>[12]</sup> In our patient's case, it is possible that the two prior KD episodes (without CA involvement) intensified the degree of CA injury during the third KD episode. Therefore, in patients with prior KD, there may be a stronger impetus for repeating early and serial echocardiograms.

Our case also draws attention to the deep neck (i.e., retropharyngeal and/or parapharyngeal) inflammation as a manifestation of KD. In a recent study of US inpatients, approximately 0.6% of KD patients presented with deep neck space involvement. Older (≥4-year-old), nonwhite, non-Hispanic patients, like our patient were more likely to have deep neck involvement.<sup>[13]</sup> When surgical drainage is performed, there is no evidence of



**Figure 1: Coronary artery aneurysms of the left (a and b) and right (c) coronary arteries on echocardiogram. (a) Aneurysm of the LMCA proximal to its bifurcation (arrow). (b) Extensive vasculitic changes to the LAD include proximal ectasia (thin arrow) and bead-like aneurysms (wide arrows). (c) Aneurysm of the proximal RCA (arrow)**

abscess,<sup>[14]</sup> and typical KD treatments (e.g., IVIG, ASA)<sup>[15,16]</sup> usually results in complete resolution of retropharyngeal abscess-like symptoms. Thus, there should be a high index of suspicion for KD in children with persistent fever and deep neck inflammation unresponsive to empirical antibiotic therapy.

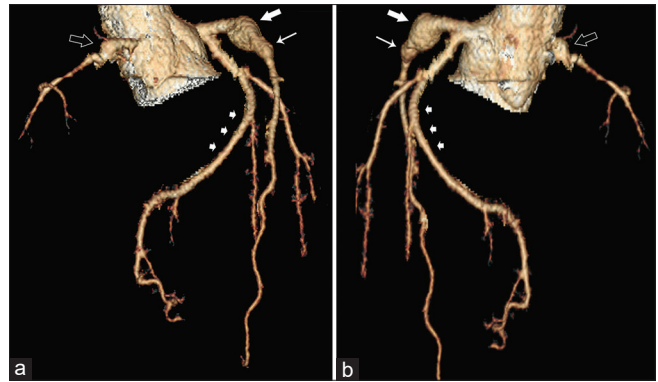
A single dose of IVIG (2 g/kg) in conjunction with moderate (30–50 mg/kg/day) to high-dose ASA (80–100 mg/kg/day) remains the mainstay treatment for KD for halting disease progression. Additional therapy during the acute phase of the illness in patients who fail to respond to IVIG, and ASA include a second dose of IVIG, steroids (e.g., intravenous methylprednisolone), and immune-modulating drugs (e.g., infliximab, etanercept, and cyclosporine). The presence of rapidly expanding aneurysms warrants escalation in antithrombotic therapy (with systemic anticoagulation and a second antiplatelet agent) to prevent thrombotic occlusion of CAAs. Once afebrile for 48–72 h, high-dose ASA is discontinued and replaced with low-dose ASA.<sup>[12]</sup> Low-dose ASA may be discontinued at 6–8 weeks after illness onset if there are no coronary changes. For patients with coronary abnormalities, ASA may be continued indefinitely.

## CONCLUSION

Our case illustrates the importance of age as a factor in KD presentation, manifestation, and outcome. Specifically, presentation at an older age was associated with incomplete KD, atypical retropharyngeal involvement, and delayed diagnosis only after the development of giant CAAs on later echocardiograms. A high index of suspicion for KD is necessary for the persistently febrile patient, particularly when there is a personal history of KD, as this may intensify the vasculitic manifestation and make the patient more vulnerable to CA injury. Finally, serial echocardiograms should be performed when fever persists, and inflammatory markers remain high, even when there is no obvious CA involvement on the initial echocardiogram.

### Declaration of patient consent

The authors certify that they have obtained all appropriate patient consent forms. In the form the



**Figure 2: CT coronary angiography demonstrates aneurysmal changes in the RCA (open arrow) and LAD (wide and thin arrows). Note the giant aneurysm (wide arrow) in the proximal LAD adjacent to a smaller distal aneurysm (thin arrow). The circumflex artery (small arrows) is unaffected. (a) Anterior view; (b) Posterior view**

patient(s) has/have given his/her/their consent for his/her/their images and other clinical information to be reported in the journal. The patients understand that their names and initials will not be published and due efforts will be made to conceal their identity, but anonymity cannot be guaranteed.

### Financial support and sponsorship

Nil.

### Conflicts of interest

There are no conflicts of interest.

## REFERENCES

1. Yanagawa H, Nakamura Y, Yashiro M, Oki I, Hirata S, Zhang T, *et al.* Incidence survey of Kawasaki disease in 1997 and 1998 in Japan. *Pediatrics* 2001;107:E33.
2. Manlhiot C, Yeung RS, Clarizia NA, Chahal N, McCrindle BW. Kawasaki disease at the extremes of the age spectrum. *Pediatrics* 2009;124:e410-5.
3. Newburger JW, Takahashi M, Gerber MA, Gewitz MH, Tani LY, Burns JC, *et al.* Diagnosis, treatment, and long-term management of Kawasaki disease: A statement for health professionals from the Committee on Rheumatic Fever, Endocarditis, and Kawasaki Disease, Council on Cardiovascular Disease in the Young, American Heart Association. *Pediatrics*. 2004;114:1708-33.
4. Yanagawa H, Nakamura Y, Yashiro M, Ojima T, Koyanagi H, Kawasaki T. Update of the epidemiology of Kawasaki disease in Japan—from the results of 1993-94 nationwide survey. *J Epidemiol* 1996;6:148-57.
5. Sudo D, Nakamura Y. Nationwide surveys show that the incidence of recurrent Kawasaki disease in Japan has hardly changed over the last 30 years. *Acta Paediatr* 2017;106:796-800.
6. Maddox RA, Holman RC, Uehara R, Callinan LS, Guest JL, Schonberger LB, *et al.* Recurrent Kawasaki disease: USA and Japan. *Pediatr Int* 2015;57:1116-20.

7. McMahon MA, Wynne B, Murphy GM, Kearns G. Recurrence of Kawasaki disease in an adult patient with cholecystitis. *Ir Med J* 2007;100:400-1.
8. Hirata S, Nakamura Y, Yanagawa H. Incidence rate of recurrent Kawasaki disease and related risk factors: From the results of nationwide surveys of Kawasaki disease in Japan. *Acta Paediatr* 2001;90:40-4.
9. Falcini F, D'Adamo G, Rigante D. A four-time-recurring typical complete Kawasaki syndrome successfully treated with intravenous immunoglobulin: A case report with literature review. *Rheumatol Int* 2013;33:2653-5.
10. Nakamura Y, Oki I, Tanihara S, Ojima T, Yanagawa H. Cardiac sequelae in recurrent cases of Kawasaki disease: A comparison between the initial episode of the disease and a recurrence in the same patients. *Pediatrics* 1998;102:E66.
11. Ninomiya T, Takada H, Nagatomo Y, Nanishi E, Nagata H, Yamamura K, *et al.* Development of Kawasaki disease in a patient with PFAPA. *Pediatr Int* 2013;55:801-2.
12. McCrindle BW, Rowley AH, Newburger JW, Burns JC, Bolger AF, Gewitz M, *et al.* Diagnosis, treatment, and long-term management of Kawasaki disease: A scientific statement for health professionals from the American heart association. *Circulation* 2017;135:e927-99.
13. Inagaki K, Blackshear C, Hobbs CV. Deep neck space involvement of Kawasaki disease in the US: A population-based study. *J Pediatr* 2019;215:118-22.
14. Homicz MR, Carvalho D, Kearns DB, Edmonds J. An atypical presentation of Kawasaki disease resembling a retropharyngeal abscess. *Int J Pediatr Otorhinolaryngol* 2000;54:45-9.
15. Hester TO, Harris JP, Kenny JF, Albernaz MS. Retropharyngeal cellulitis: A manifestation of Kawasaki disease in children. *Otolaryngol Head Neck Surg* 1993;109:1030-3.
16. Bradley MK, Crowder TH. Retropharyngeal mass in a child with mucocutaneous lymph node syndrome. *Clin Pediatr (Phila)* 1983;22:444-5.