



Incessant tachycardia in a patient with advanced heart failure and left ventricular assist device: What is the mechanism?

Amit Noheria^{a, b, *}, Siva K. Mulpuru^b, Peter A. Noseworthy^b, Samuel J. Asirvatham^{b, c}

^a Cardiovascular Division, Washington University School of Medicine, 660 S. Euclid Ave., Campus Box 8086, St. Louis, MO 63110, USA

^b Department of Cardiovascular Diseases, Mayo Clinic, 200 First St. SW, Rochester, MN 55905, USA

^c Department of Pediatric and Adolescent Medicine, Mayo Clinic, 200 First St. SW, Rochester, MN 55905, USA

ARTICLE INFO

Article history:

Received 6 April 2016

Accepted 16 April 2016

Available online 19 April 2016

Keywords:

Wide complex tachycardia

Ventricular tachycardia

Entrainment

Bundle-branch reentry tachycardia

Left ventricular assist device

ABSTRACT

We present a case of incessant wide-complex tachycardia in a patient with left-ventricular assist device, and discuss the differential diagnosis with an in-depth analysis of the intracardiac tracings during the invasive electrophysiologic study, including interpretation of the relative timing of the fascicular signals during tachycardia and in sinus rhythm, and interpretation of pacing and entrainment maneuvers.

Copyright © 2016, Indian Heart Rhythm Society. Production and hosting by Elsevier B.V. This is an open access article under the CC BY-NC-ND license (<http://creativecommons.org/licenses/by-nc-nd/4.0/>).

1. Case presentation

A 54-year-old man with end-stage hypertrophic cardiomyopathy had a Heart Mate II (Thoratec Corporation, Pleasanton, CA) left ventricular assist device (LVAD) for advanced heart failure and had a cardiac resynchronization therapy-defibrillator (CRT-D) in place. At the time of his LVAD implantation, linear surgical cryoablations had been performed from the apical cannula to the mitral valve annulus along the posterior and posteroseptal left ventricle (LV). He now presented with palpitations and congestive heart failure. He was noted to be in a wide complex tachycardia at 172 beats per minute with intermittent changes in the QRS axis/morphology (Fig. 1A). The tachycardia could be interrupted with overdrive pacing from the right or left ventricular pacing lead, but would subsequently reinitiate. On echocardiography, the LVAD cannula was normally positioned without any evidence of LV chamber

collapse or mechanical interaction between the cannula and the myocardium. The patient was started on flecainide 150 mg by mouth two times a day to suppress the tachycardia. This however converted it to a slow (107 beats per minute) but incessant tachycardia with a stable rate and consistent morphology.

He was brought to the electrophysiology laboratory and diagnostic catheters were placed in the coronary sinus (CS), right ventricle (RV) and His bundle region. He was in sustained tachycardia with a stable cycle length (560–570 msec) and morphology, and a slower dissociated sinus rhythm in the atria. Some sinus beats advanced the His bundle electrogram and QRS without any change in the surface QRS morphology, and reset the tachycardia (Fig. 1B, asterisk). The tachycardia was unable to be overdriven with atrial pacing due to atrioventricular (AV) block at faster pacing rates. The tachycardia terminated with a premature ventricular complex (PVC) during attempted atrial overdrive pacing, but reinitiated with the first AV conducted beat (Fig. 1C). The HV (His to ventricle) interval for conducted atrial beats was 88 msec and HV interval during tachycardia was 60 msec.

Overdrive pacing from the RV posteroseptal catheter was performed. Pacing at successively shorter cycle lengths demonstrated progressive fusion (Fig. 2A). Mapping of the fascicular signals on the mid-to-basal right ventricular septum during tachycardia demonstrated a distal-to-proximal activation of the right bundle branch and His. The response to entrainment from the RV septum is shown in Fig. 2B. What can you deduce about the tachycardia circuit?

Abbreviations: AV, atrioventricular; CRT-D, cardiac resynchronization therapy-defibrillator; CS, coronary sinus; HV, His to ventricle; LV, left ventricle; LVAD, left ventricular assist device; PVC, premature ventricular complex; RV, right ventricle; VT, ventricular tachycardia.

* Corresponding author. Washington University School of Medicine, 660 S. Euclid Ave., Campus Box 8086, St. Louis, MO 63110, USA.

E-mail addresses: anoheria@wustl.edu (A. Noheria), mulpuru.siva@mayo.edu (S.K. Mulpuru), noseworthy.peter@mayo.edu (P.A. Noseworthy), asirvatham.samuel@mayo.edu (S.J. Asirvatham).

Peer review under responsibility of Indian Heart Rhythm Society.

<http://dx.doi.org/10.1016/j.ipej.2016.04.001>

0972-6292/Copyright © 2016, Indian Heart Rhythm Society. Production and hosting by Elsevier B.V. This is an open access article under the CC BY-NC-ND license (<http://creativecommons.org/licenses/by-nc-nd/4.0/>).

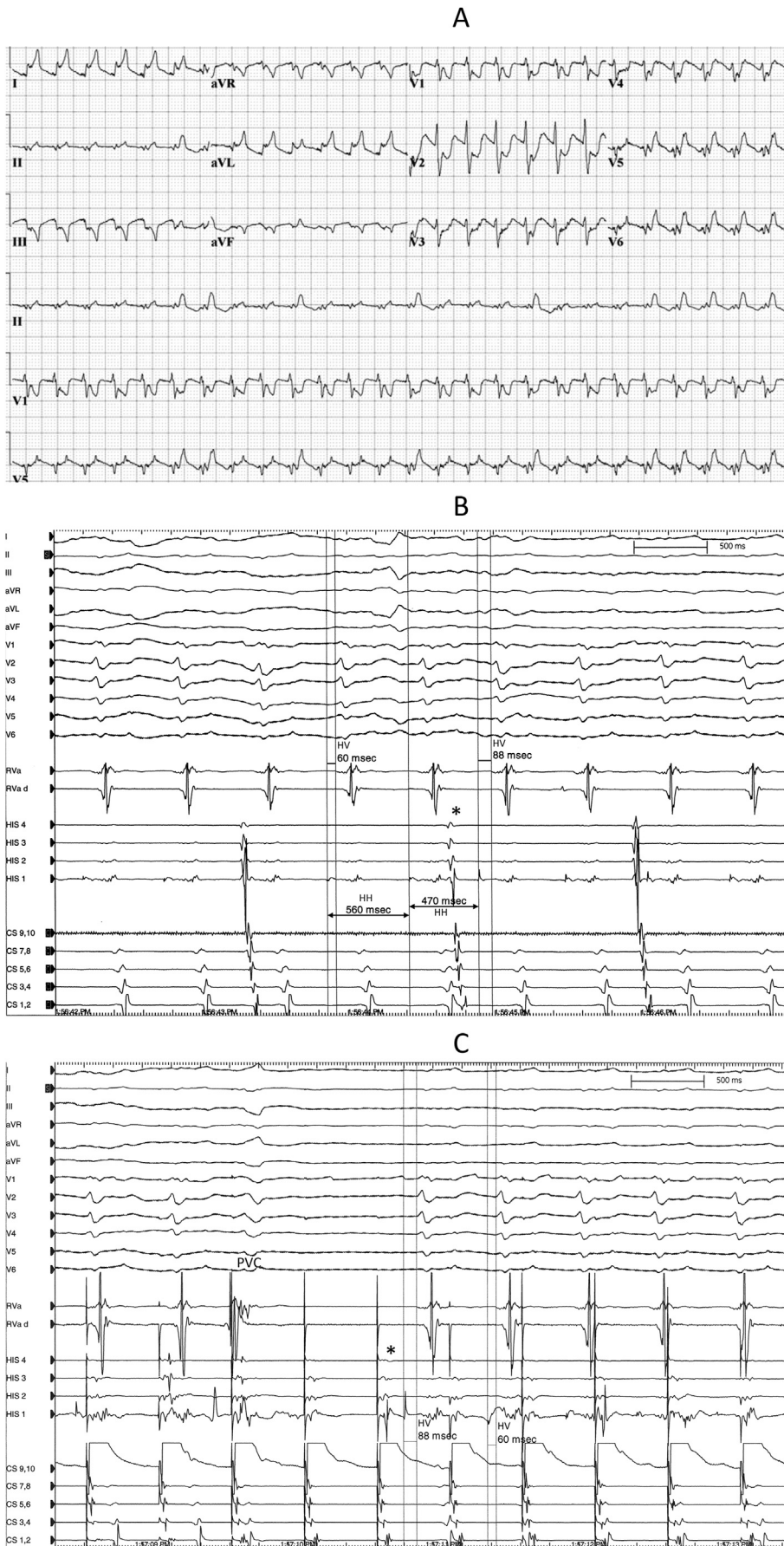


Fig. 1. Panel A – 12-Lead electrocardiogram of the presenting tachycardia. **Panel B** – Surface electrocardiogram and intracardiac electrograms of the clinical tachycardia. A sinus beat (asterisk) advances the His bundle electrogram and the QRS complex, and resets the tachycardia. **Panel C** – Termination of tachycardia with a premature ventricular complex (PVC) during attempted overdrive pacing from the atrium (dissociated). Subsequently the second atrial complex (asterisk) conducts to the ventricle with HV interval of 88 msec and QRS morphology same as tachycardia, and reinitiates tachycardia. HH, His to His; HV, His to Ventricle/QRS.

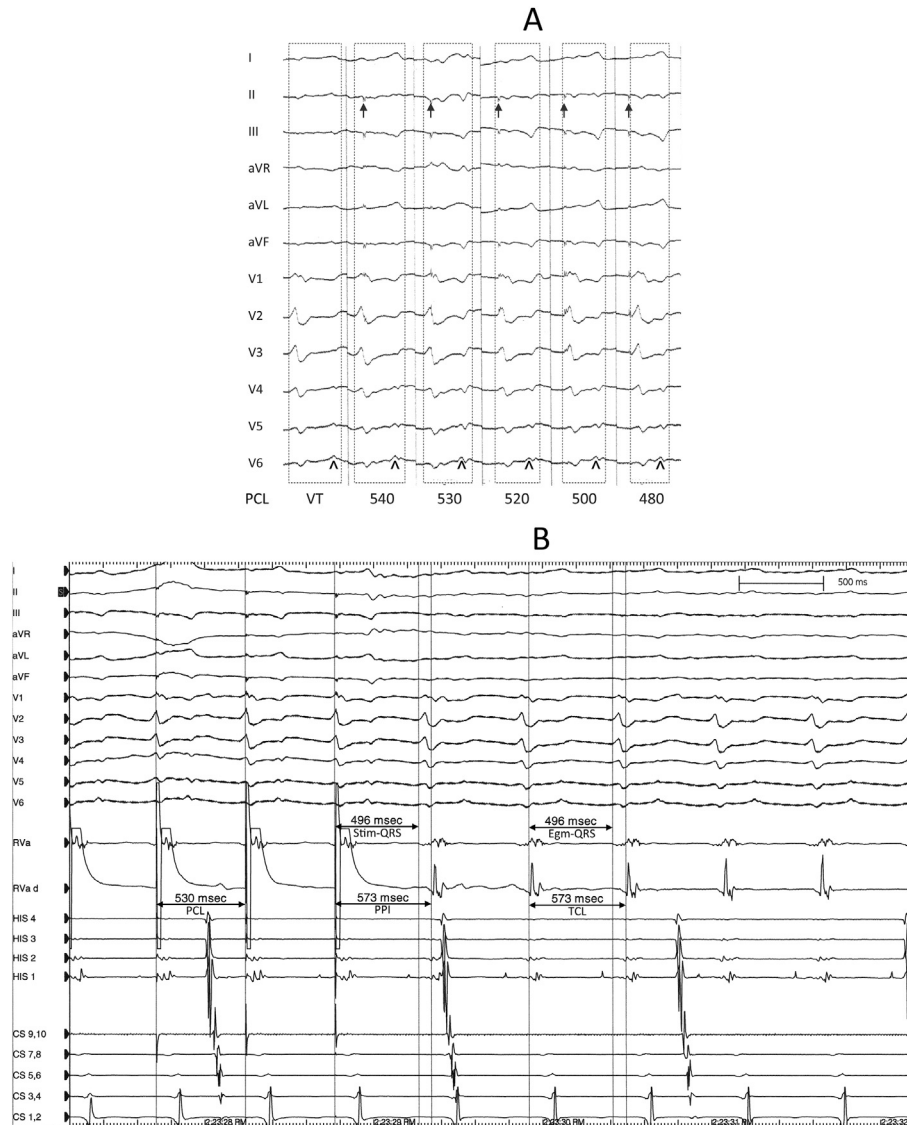


Fig. 2. Panel A – Progressive fusion with successively shorter pacing cycle length (PCL) from the right ventricle. Arrows point to the artifact from pacing stimuli. Dashed boxes outline the 12-lead QRS morphology. The initial component of the QRS remains stable (orthodromically captured). The arrowheads point to the delayed terminal QRS deflection that changes with entrainment (antidromically activated) and is progressively advanced with shorter PCLs resulting in narrower fused QRS complexes. VT, ventricular tachycardia at cycle length 565 msec; numbers represent the PCL in msec. **Panel B** – Entrainment of the tachycardia from the right ventricle. PCL, pacing cycle length; PPI, post pacing interval; TCL, tachycardia cycle length; Stim-QRS, pacing stimulus to QRS onset; Egm-QRS, local ventricular electrogram to QRS onset.

2. Discussion

The QRS complexes during tachycardia have a sharp initial component suggesting early engagement of the fascicular system (Fig. 1B). The subsequent profoundly delayed low-frequency component of the QRS complex has a vector directed away from lead V₁ and towards the lateral leads, possibly indicating passive delayed activation of the LV free wall. Differential diagnosis of the tachycardia includes (i) supraventricular tachycardia with intraventricular conduction abnormality, (ii) fascicular tachycardia, (iii) bundle branch reentry, and (iv) myocardial ventricular tachycardia (VT) with an exit that quickly engages the conduction system. In Fig. 1C, the HV interval during the tachycardia (60 msec) is shorter than the HV interval with a conducted atrial beat (88 msec). Compared to the actual HV conduction interval with sequential activation of His followed by V during sinus rhythm, a shorter HV during tachycardia suggests activation of His and V occurring in

parallel from a common intervening site [1,2]. This finding excludes supraventricular tachycardias with antegrade activation of the His-bundle (e.g. AV nodal reentry). Further, the tachycardia morphology is identical to the conducted QRS complex (Fig. 1C). This observation effectively excludes a myocardial VT distinct from the fascicular system.

Pacing from the RV posteroseptum during tachycardia at progressively shorter cycle lengths shows fusion between unchanged orthodromically captured initial “fascicular” component of the QRS with progressive advancement of the antidromically paced second component (progressive fusion, Fig. 2A). This proves the mechanism of tachycardia to be reentry. Entrainment from the RV posteroseptum (Fig. 2B) demonstrates a post pacing interval equal to the tachycardia cycle length (PPI = TCL), and a stimulus-to-QRS (Stim-QRS) interval during pacing equal to the electrogram-to-QRS (Egm-QRS) during tachycardia, indicating the pacing site to be within the reentry circuit. Presence of manifest QRS fusion and

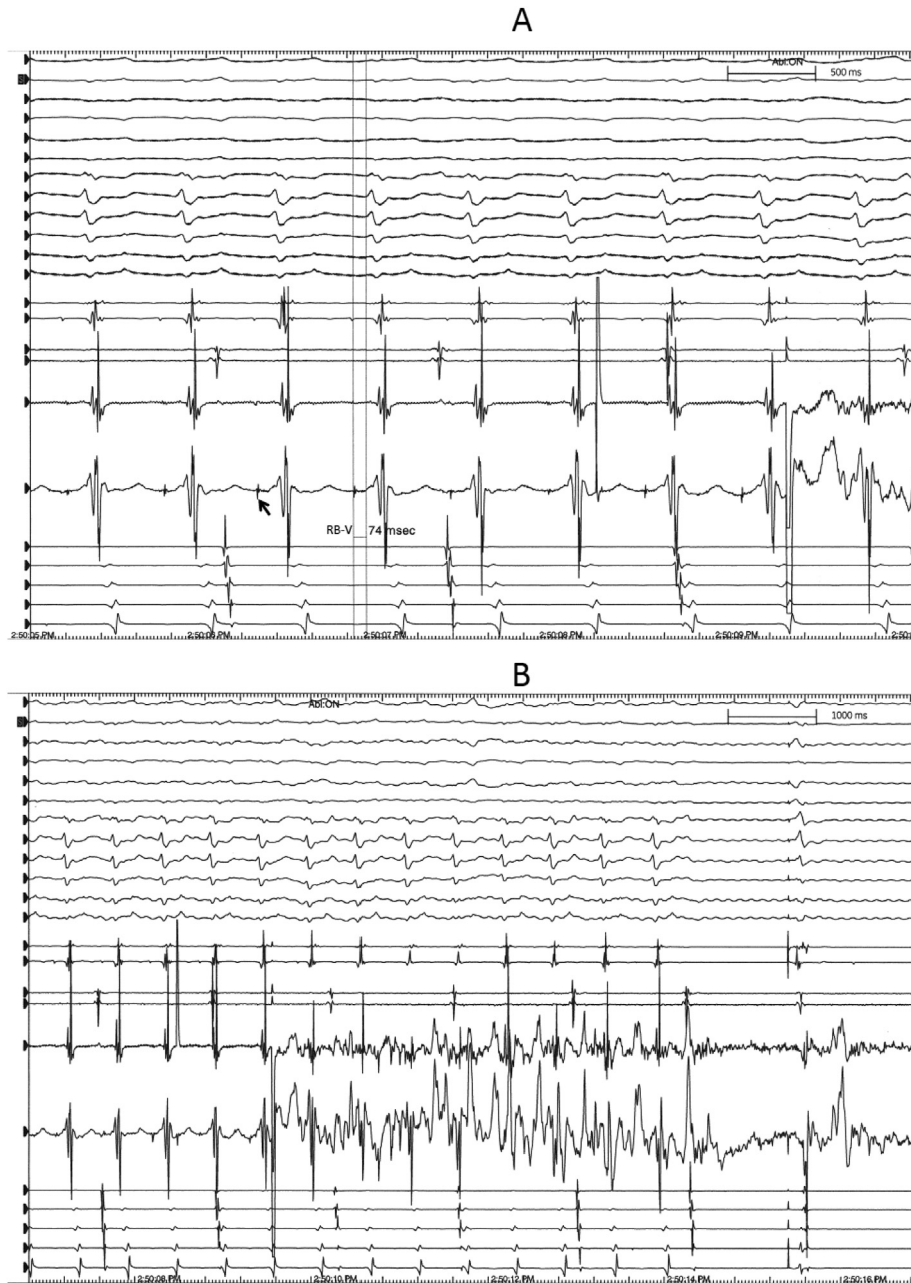


Fig. 3. Panel A – The right bundle potential (arrow) at the site of ablation distal to the site His bundle recording. Right bundle activation occurs prior to His resulting in a longer RB-V (right bundle to Ventricle/QRS) interval (74 msec) compared to HV interval (60 msec) during tachycardia. **Panel B** – Termination of tachycardia with delivery of radiofrequency ablation at the site of right bundle potential. Tachycardia was subsequently non-inducible. **Panel C** –, Sinus rhythm with complete atrioventricular block and dissociated paced ventricular rhythm post ablation. Activation of the His bundle/proximal right bundle is seen antegradely (arrow) following atrial activation (sinus rhythm) and retrogradely (arrowhead) following ventricular activation (paced), however, without further conduction in either direction. A, atrium, H, His, V, ventricle. **Panel D** – Illustration of the putative tachycardia circuit involving the conduction system. Entrainment from the RV septum (asterisk) suggested area of extremely slow conduction (zig-zag line) leading retrogradely into the right bundle branch. The QRS morphology for conducted sinus beats was the same as tachycardia, presumably antegrade conduction through the left bundle branch (antegrade right bundle branch block, RBBB). The QRS morphology for RBBB was unusual, presumably because of conduction block (red X) and profoundly delayed passive activation of the LV free wall. The delayed passive activation of the LV free wall with a wavefront spreading leftwards and posteriorly could explain the delayed negative deflection in lead V₁ and a corresponding R' wave in lead V₆. LV, left ventricle, LVAD, left ventricular assist device, RA, right atrium, RV, right ventricle.

the long Egm-QRS interval (and orthodromic stim-QRS interval) suggest the RV pacing site to be at the entrance to the protected isthmus of the VT circuit [3,4].

The His bundle electrogram is captured orthodromically during entrainment (Stim-His interval during pacing equal to Egm-His interval during tachycardia) with a long Stim-His or Egm-His interval. This suggests the activation during tachycardia to propagate from the RV septal pacing site (participating in the reentry circuit),

through the protected isthmus (critical slow conduction zone), and then retrogradely through the conduction system to the bundle of His. During tachycardia, the right bundle branch demonstrates distal-to-proximal activation. The His bundle electrogram precedes the QRS, and the tachycardia morphology matches AV conducted QRS complexes. These observations suggest that activation during tachycardia propagates retrograde through right bundle branch and then activates the ventricles antegrade through the conduction

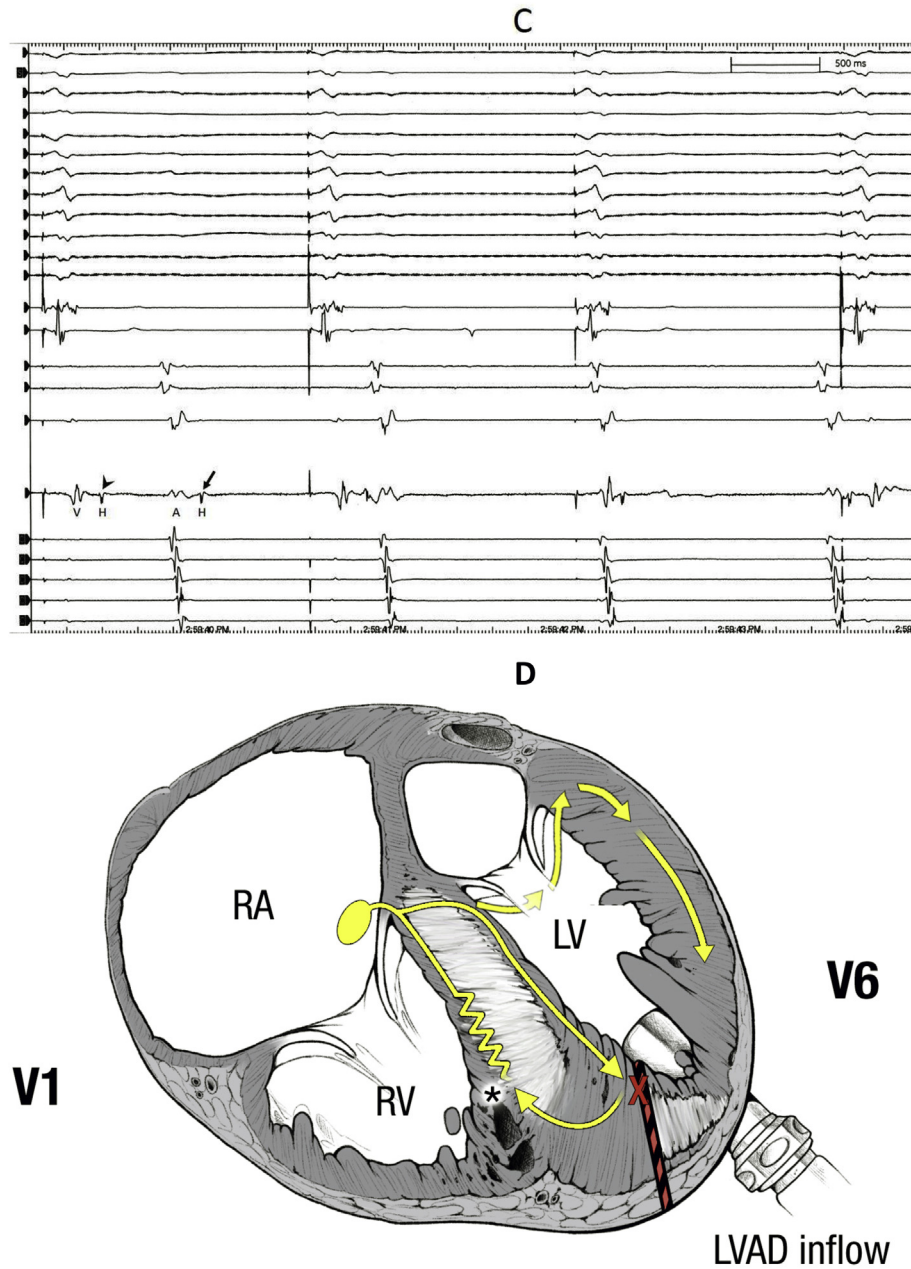


Fig. 3. (continued).

system (left fascicle). A shorter HV interval during tachycardia compared to sinus rhythm is consistent with activation simultaneously propagating from the takeoff of the left fascicle in either direction (up the bundle of His and down the left bundle branch to generate the QRS) [1,2]. The similar QRS morphology of conducted sinus beats (Fig. 1C) can be explained by antegrade conduction block in the right bundle branch or in the protected slow zone (distal right bundle or myocardium engaged by the right bundle exit) [4].

Although the above findings are suggestive of mechanistic involvement of the bundle branches in the reentry circuit, we have not conclusively proven their participation. It is possible that a contained reentry circuit engages the right bundle branch and this bystander retrograde activation of the right bundle is the only way for the VT to exit to the rest of the ventricular myocardium.

We made a clinical decision not to access the LV to map the left ventricle and left bundle branch to assess for their participation in the reentry circuit. We did not succeed in our attempt to consistently pace capture the right bundle branch to demonstrate it to be a part of the circuit with entrainment. Regardless, as we had a high suspicion for reentry to involve the right bundle branch we targeted the proximal right bundle for radiofrequency ablation (Fig. 3A). The previously incessant tachycardia terminated with focal ablation at this site and was rendered non-inducible (Fig. 3B). Further consolidation lesions were delivered targeting the fascicular signals extending proximally to the His bundle. Following ablation complete bidirectional block was seen at the level of the His bundle (Fig. 3C).

A noteworthy feature of the QRS morphology with “right bundle branch block” is the absence of the terminal R’ in lead V₁ and S

wave in lateral leads, and instead presence of a terminal posterior/leftward directed vector with negative deflection in V_1 and R' wave in lateral leads (Fig. 1A). To explain this we hypothesize profound conduction delays/block from the septum to the LV free wall (on account of prior surgical ablation, cardiomegaly, ventriculotomy and scarring). Despite the right bundle block, the terminal QRS vector is generated by passive delayed posteriorly directed activation of the LV free wall, although, without mapping the LV this remains a conjecture. An illustration of the putative reentry circuit and the passive delayed activation of the LV free wall despite right bundle branch block and antegrade conduction through the left bundle branch is shown in Fig. 3D.

There are two discretely different QRS morphology/axis seen on the presenting ECG (Fig. 1A), though the variability disappeared after treatment with flecainide. A speculative cause for the variability could be intermittent terminal conduction directed towards leads II and V_{5-6} (positive deflection) in presumably an apical lateral segment of the LV close to the LVAD cannula site. In a majority of the beats at baseline, and after treatment with flecainide, this deflection disappears, either on account of complete conduction block to this segment, or recruitment with a different activation wavefront. This is consistent with the advanced degree of scarring and intraventricular conduction blocks seen in this patient.

3. Key teaching points

- 1 The differential diagnosis of a wide complex tachycardia with an initial sharp QRS deflection includes (i) supraventricular tachycardia with intraventricular conduction abnormality, (ii) fascicular tachycardia, (iii) bundle branch reentry, and (iv) myocardial ventricular tachycardia with an exit that quickly engages the conduction system.
- 2 An His to ventricle (HV) or fascicular signal to ventricle (FV) interval during tachycardia shorter than the true in-series conduction HV/FV interval noted during sinus rhythm, attests to the

parallel activation of the His/fascicle and the ventricle, possibly from an intervening common site within the fascicular system. This finding may be useful in excluding supraventricular tachycardia with antegrade engagement of the His-Purkinje system, and fascicular sites proximal to the arrhythmogenic substrate during mapping of focal fascicular arrhythmias.

- 3 Entrainment of a reentrant arrhythmia from a site that shows a post-pacing interval equal to the tachycardia cycle length ($PPI = TCL$), in the absence of a change in the tachycardia or far-field capture, proves participation of the paced site in the reentry circuit.

Conflict of interest

None.

Acknowledgement

We thank Mr. Frank M. Corl for his assistance in creating the illustration.

References

- [1] Ma W, Wang X, Cingolani E, Thajudeen A, Gupta N, Nageh MF, et al. Mapping and ablation of ventricular tachycardia from the left upper fascicle: how to make the most of the fascicular potential? *Circ Arrhythm Electrophysiol* 2013;6:e47–51.
- [2] Asirvatham SJ, Stevenson WG. Editor's perspective: bundles branch reentry. *Circ Arrhythm Electrophysiol* 2013;6:e92–4.
- [3] Stevenson WG, Friedman PL, Sager PT, Saxon LA, Kocovic D, Harada T, et al. Exploring postinfarction reentrant ventricular tachycardia with entrainment mapping. *J Am Coll Cardiol* 1997;29:1180–9.
- [4] Merino JL, Peinado R, Fernandez-Lozano I, Sobrino N, Sobrino JA. Transient entrainment of bundle-branch reentry by atrial and ventricular stimulation: elucidation of the tachycardia mechanism through analysis of the surface ECG. *Circulation* 1999;100:1784–90.