

Use of Biotronik closed loop pacemaker to treat recurrent syncope in pediatric patient with dysautonomia



Jennifer Shortland, MD,^{*†} Orhan Uzun, MD,[†] Deirdre Wilson,^{*} Graham A. Stuart, FRCP,^{*‡} Mark A. Walsh, MD^{*‡}

From the ^{*}Bristol Royal Hospital for Children, Bristol, United Kingdom, [†]University Hospital of Wales, Cardiff, United Kingdom, and [‡]Bristol Heart Institute, Bristol, United Kingdom.

Introduction

Syncope is a common problem in adolescents and most patients can be managed conservatively with lifestyle modifications.¹ Some patients may benefit from medications to either augment blood pressure or alleviate tachycardia; these strategies alone, however, often do not result in complete resolution of symptoms.^{2,3} For those most severely affected, syncope can be severely debilitating, with inability to attend full-time education and partake in normal activities. These patients have often tried multiple pharmacotherapeutic strategies and have often been reviewed by many different subspecialists. Patients on the most severe end of the spectrum often have an underlying dysautonomia; conditions such as hypermobility, postural orthostatic tachycardia syndrome (POTS), and chronic fatigue are frequently described to coexist.⁴

The Closed Loop Stimulation (CLS) function has been successfully used in patients with vasovagal syncope.^{5,6} The CLS algorithm works by monitoring right ventricular impedance, which is thought to be one of the first physiological changes prior to syncope. Early detection and chronotropic augmentation of cardiac output is thought to be the mechanism behind the increased benefit when compared with heart rate-based algorithms. We describe the use of the CLS algorithm in a pediatric patient with dysautonomia, POTS, and severe orthostatic intolerance. Placement of the pacemaker resulted in a dramatic improvement in symptoms and allowed a patient who was confined to the hospital to embark on a path to recovery.

Case report

An 11-year-old girl was referred with a history of syncopal episodes. She did not have any preceding medical problems. There was a distant family member who had been diagnosed with long QT syndrome. The episodes occurred both at rest

and with exercise; they were usually associated with a prodrome. She did not have any features suggestive of hypermobility syndrome or connective tissue disease. There was a 6- to 12-month history of fatigue, which became progressively worse over the following year. A baseline electrocardiogram and echocardiogram were both normal. Over the following 12 months, the syncopal episodes became more frequent. A head-up tilt test was performed; the heart rate reached a maximum of 148 beats per minute, 17 minutes into the test (baseline 85 beats per minute) and the blood pressure dropped to 69/53 mm Hg, at which point the patient became syncopal. The patient continued to have a borderline tachycardia during the syncopal event. A couple of months later she had a syncopal episode at school. During one of her lessons she became dizzy, with associated blurry vision. She collapsed onto the floor and was unresponsive. The school nurse assessed her immediately and she was said to be pulseless. Chest compressions were given for 30 seconds and she became rousable. Owing to parental concern, an adrenaline challenge was performed, which demonstrated appropriate shortening of the QT interval; a loop recorder was also implanted at the same time. Initial medical treatments consisted of midodrine and fludrocortisone. A beta-blocker was tried initially; however, it was discontinued owing to severe fatigue after administration. Psychological support was provided for the patient by a multidisciplinary team. The loop recorder documented multiple episodes of collapse; some of these were preceded by tachycardia and some were associated with a normal heart rate.

The episodes of collapse were sometimes associated with tonic posturing of the trunk and seizure-like episodes. Neurologic investigations to rule out a neurologic cause for her recurrent of collapses included brain magnetic resonance imaging and electroencephalogram: these were both normal. A collapse in hospital during electroencephalogram monitoring demonstrated a 7-second episode of complete heart block (Figure 1); this was also evident on the loop recorder. We elected to place a single-chamber ventricular pacemaker because of the previous episode of collapse and requirement for cardiopulmonary resuscitation. The pacemaker was set to

KEYWORDS Dysautonomia; POTS; Pacemaker; Closed loop; Pediatric (Heart Rhythm Case Reports 2017;3:27–29)

Address reprints and correspondence: Dr Mark Walsh, Bristol Royal Hospital for Children, Upper Maudlin Street, Bristol, BS2 8BJ, UK. E-mail address: mark.walsh@UHBristol.nhs.uk.

KEY TEACHING POINTS

- Recurrent syncope is a common problem in young patients. Most cases are treatable with a combination of medications, lifestyle modifications, and psychological support.
- Dysautonomia is an uncommon cause of syncope in this age group; however, when it is present, individuals can be profoundly affected with life-altering symptom. Medical treatment of this group of patients is often unsuccessful.
- We report on a patient refractory to medical treatment, who had a dramatic improvement in symptoms after implantation of the Biotronik Closed Loop System.

VVI at 50 beats per minute; at follow-up it was found to be pacing 5%–10% of the time. We recognized that the pacemaker was unlikely to improve the majority of the syncopal episodes, as most were not related to bradycardia. The patient had extensive psychology input and we felt that a secondary conversion disorder was unlikely. Autoantibodies for ganglionic AChR receptor were negative on 2 separate occasions. The patient's condition deteriorated, requiring multiple extended hospital admissions. Ivabradine 2.5 mg 3 times daily was commenced and despite some initial improvement, the collapses continued. Octreotide (intramuscular) was administered at a high dose; however, this also did not improve symptoms. Collapses were occurring 10–20 times per day, and the patient was unable to mobilize from her bed. We decided to upgrade the pacemaker to a CLS system. This procedure was performed when the patient was 14 years old (weight 55 kg, height 160 cm). A Select Secure 69-cm atrial lead was placed and the existing pacemaker was upgraded to an Epyra DR-T (Biotronik GmbH & Co) (Figure 2). The pacemaker was programmed with a rate of 60–140, with an AV delay of 180 msec, with a medium sensor threshold (CLS feature). The pacemaker demonstrated 44% atrial pacing and no ventricular pacing.

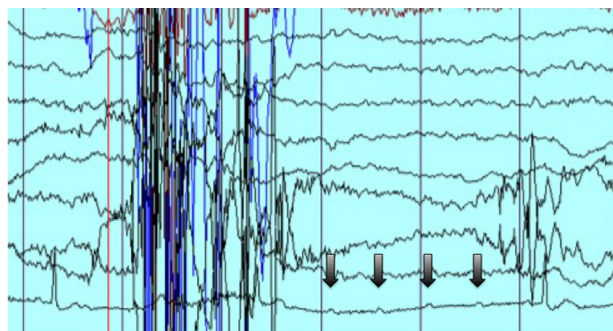


Figure 1 This electroencephalogram (EEG) tracing demonstrates an episode of complete heart block (arrows) presumably related to dysautonomia. There was no seizure activity documented on the EEG when the patient was symptomatic.

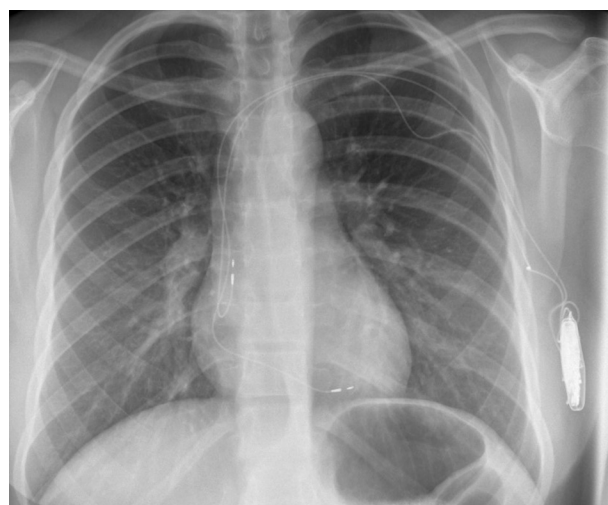

Figure 2 Chest radiograph shows Biotronik Closed Loop Stimulation system, implanted in the axilla.

There was an immediate improvement in the patient's color the following morning and she was able to mobilize better. She was discharged from hospital 4 days after implantation; she had been an inpatient for 6 weeks by this stage. She has had occasional episodes of syncope since discharge; however, her quality of life has greatly improved. She has managed to return to school and has resumed some of her normal activities.

Discussion

This report demonstrates the usefulness of the CLS pacemaker for a pediatric patient with severe orthostatic intolerance secondary to dysautonomia. Patients with this severity of symptoms are uncommon; they are, however, often refractory to pharmacologic treatment and can require extended hospital admission. The CLS system managed to improve this patient's symptoms when other treatment modalities were unsuccessful.

Orthostatic intolerance in the pediatric age group is often multifactorial. There are often overlapping phenotypes of neurocardiogenic syncope, POTS, and dysautonomia. Psychosomatic symptoms also are common and can either be the main cause of syncope at presentation or develop over time if appropriate psychological support is not readily available.¹ Our patient demonstrated features of POTS on the tilt test, yet some of the collapses documented on loop recorder tracings showed a normal heart rate. Autoimmune dysautonomia is most likely the underlying cause of this patient's condition. The ganglionic AChR antibody test was negative; however, only 50% of patients who have autoimmune ganglionopathy have a positive result.⁷ Given the fact that other neurologic symptoms have not developed over time, and that there was an improvement in symptoms with the CLS pacemaker, another underlying neurologic diagnosis is unlikely.

The CLS system works by sensing changes in right ventricular impedance.^{8,9} For patients with orthostatic

intolerance, postural change causes decreased venous return to the heart, which in turn increases myocardial contractility. The CLS algorithm detects this increase in contractility and augments the heart rate, thus increasing cardiac output. Algorithms using heart rate drop, may be providing chronotropy too late to prevent syncope. This may account for the better results for some types of orthostatic intolerance using the CLS system.⁶

The most interesting thing about this report is the fact that a pacemaker that works by accelerating the heart rate seemed to dramatically improve symptoms in a patient whose collapses were predominantly sinus rhythm / sinus tachycardia. It is possible that in patients with dysautonomia, the CLS algorithm somehow supports a dysfunctional autonomic nervous system by increasing and decreasing the heart rate in response to orthostatic conditions. The fact that the patient is using the pacemaker 44% of the time, despite a moderate sensor setting and a relatively sedentary lifestyle still, may support this theory. Patients with this severity of symptoms are, thankfully, quite rare; however, for those that are refractory to medical therapy, this type of pacemaker is worth considering.

References

1. Blad H, Lamberts RJ, van Dijk GJ, Thijs RD. Tilt-induced vasovagal syncope and psychogenic pseudosyncope: overlapping clinical entities. *Neurology* 2015;85:2006–2010.
2. McDonald C, Frith J, Newton JL. Single centre experience of ivabradine in postural orthostatic tachycardia syndrome. *Europace* 2011;13:427–430.
3. Izcovich A, Gonzalez Malla C, Manzotti M, Catalano HN, Guyatt G. Midodrine for orthostatic hypotension and recurrent reflex syncope: a systematic review. *Neurology* 2014;83:1170–1177.
4. Mathias CJ, Low DA, Iodice V, Owens AP, Kirbis M, Grahame R. Postural tachycardia syndrome—current experience and concepts. *Nat Rev Neurol* 2012;8:22–34.
5. Lindovska M, Kamenik L, Pollock B, Hoenen S, Bokelmann T, Spitzer W, Salbach P, Behroz A, Frey A. Clinical observations with Closed Loop Stimulation pacemakers in a large patient cohort: the CYLOS routine documentation registry (RECORD). *Europace* 2012;14:1587–1595.
6. Proietti R, Manzoni G, Di Biase L, et al. Closed loop stimulation is effective in improving heart rate and blood pressure response to mental stress: report of a single-chamber pacemaker study in patients with chronotropic incompetent atrial fibrillation. *Pacing Clin Electrophysiol* 2012;35:990–998.
7. Vernino S, Low PA, Fealey RD, Stewart JD, Farrugia G, Lennon VA. Autoantibodies to ganglionic acetylcholine receptors in autoimmune autonomic neuropathies. *N Engl J Med* 2000;343:847–855.
8. Schaldach M, Ebner E, Hutten H, von Knorre GH, Niederlag W, Rentsch W, Volkmann H, Weber D, Wunderlich E. Right ventricular conductance to establish closed-loop pacing. *Eur Heart J* 1992;13(Suppl E):104–112.
9. Schaldach M, Hutten H. Intracardiac impedance to determine sympathetic activity in rate responsive pacing. *Pacing Clin Electrophysiol* 1992;15:1778–1786.