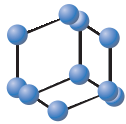
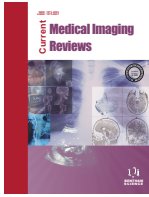

RESEARCH ARTICLE



**BENTHAM
SCIENCE**

The Clinical Value of Prenatal 3D Ultrasonic Diagnosis on Fetus Hemivertebra Deformity- A Preliminary Study



Yanting Wen^{*}, Guishuang Xiang, Xiaoqiu Liang and Xiaoqian Tong

Ultrasound Department, Fifth People's Hospital of Chengdu, Chengdu 611130, Sichuan, China

Abstract: Objective: The present study is planned to discuss the clinical value of prenatal 3D ultrasonic diagnosis on fetus hemivertebra deformity through the retrospective analysis of clinical data of fetus hemivertebra deformity.

Methods: Selected 9 fetus hemivertebra deformity cases, which have been admitted to our hospital during the period from January, 2010 to January, 2016 as study samples, and analyzed their 2D and 3D ultrasonic examination data.

Results: 4 cases of the fetus hemivertebra deformity occurred at lumbar vertebra, 3 cases at thoracic vertebra, and 2 cases at thoracolumbar vertebra. There were scoliosis and opened spine bifida (OSB). In 7 cases, there was absence of ribs in fetus. The 2D ultrasonic image showed that: The echo at the center of fetus vertebral arch lesion was blurred or lost. The coronal section showed the deformity of the spine. There was obvious loss of the ossification center. From the cross section, we could see that the vertebral body of the fetus was shrinking and the edges were relatively blurred. The 3D ultrasonic image showed that: the echo at the ossification center of the fetus vertebra was relatively blurred, or even lost. The image also indicated scoliosis deformity of the spine. The vertebral body lesion could be accurately located.

Conclusion: 9 cases of fetus hemivertebra deformity have been detected through examination. Labor inductions have been carried out after getting the permission from the family members. The X-ray examination of the fetus after labor induction showed that the diagnosis was correct. Prenatal ultrasonic examination holds strong potential for the diagnosis of fetus hemivertebra deformity quite early and deserves further clinical evaluation with large sample size.

Keywords: Early diagnosis, fetus hemivertebra deformity, prenatal 3D ultrasonic, lumbar vertebra, OSB, coronal section.

1. INTRODUCTION

Hemivertebra deformity is a congenital aplasia disease. During the fetus development process, abnormal development or movement directions of the joint cells would lead to hemivertebra deformity. There are various types of congenital vertebral deformity. Currently, the vertebral deformity types that the prenatal ultrasonic examination could identify included: Partial rachischisis, spinal meningocele, teratoma at the sacral bone, etc. [1]. The ultrasonic examination could help make correct diagnosis on most of the fetus deformities and thus is the first choice for the regular fetus examinations and for diagnosing deformities [2]. Due to the changes in the fetus position, the 2D ultrasonic examination is not able to always provide satisfying coronal image of the vertebral column. However, the coronal image is very meaningful for the observation of vertebral body lesion form and scoliosis condition [3]. On the other hand, the coronal image of the fetus vertebral

column is easy to get when applying the 3D ultrasonic examination. By adjusting the 3D images and choosing different imaging modes, we could observe the deformity of the vertebral column and vertebral body from multiple angles, which is a useful complement for the 2D ultrasonic examination. Also, the sweeping process is simplified so that the confidence of the inspectors has been improved [4]. In the present study, through the 2D and 3D ultrasonic imaging of 9 cases of fetus hemivertebra deformity, we have performed a preliminary study to explore the clinical value of ultrasound in fetus deformity.

2. MATERIALS AND METHODS

Induced labor surgery was operated on the above 9 pregnant women. After the surgery, X-ray examination has been applied to prove the existence of fetus hemivertebra deformity. The GE Voluson 730 Expert 3D diasonograph was applied for ultrasonic examination. The transducer frequency was kept at 2-5MHz. Regularly swept the pregnant women and got the data of fetus face, limbs, vertebral column, visceral organs, placenta, umbilical cord, and so on. After detecting the lesion carefully, the condition

ARTICLE HISTORY

Received: July 11, 2016
Revised: September 05, 2016
Accepted: September 15, 2016

DOI:
10.2174/1573405612666161024160609

*Address correspondence to this author at No. 33, Mashi street, Wenjiang District, Chengdu 611130, Sichuan, China; Tel: +86028-82728120; E-mail: yanting_wen1@163.com

of the lesion was recorded. The image was grabbed 3 times and properly stored the image to guarantee the optimized manifestation images. With the permission from the family members of the pregnant women, the induced labor surgeries have been operated for 9 pregnant women who have been definitely diagnosed. X-ray examination and dissection had been carried out on the fetus after the surgery.

3. RESULTS

Selected 21000 pregnant women, aged from 22 to 43 years old with an average age of (26.3±3.8) years old who had prenatal ultrasonic examination in our hospital during the period from January 2010 to January 2016. The gestational weeks were 13 to 41 weeks and the average was of (30.7±7.3) weeks. 9 cases had a definite diagnosis of fetus hemivertebra deformity, with the gestational weeks of 16 to 27 weeks and an average of (22.4±0.8) weeks.

The ultrasonic diagnostic images showed that: in terms of the location of the fetus hemivertebra deformity, 4 cases occurred at lumbar vertebra, 3 cases at thoracic vertebra, and 2 cases at thoracolumbar vertebra. There were scoliosis and opened spine bifida (OSB). In 7 cases, there was absence of ribs in fetus. The 2D ultrasonic image showed that: The echo at the center of fetus vertebral arch lesion was blurred or lost. The coronal section showed the deformity of the spine. There was obvious loss of the ossification center. From the

cross section, we could see that the vertebral body of the fetus was shrinking and the edges were relatively blurred. When carrying out the 2D ultrasonic examination, the number of ossification centers should be carefully checked, or else, there might be misdiagnosis. The 3D ultrasonic image showed that: The echo at the ossification center of the fetus vertebra was relatively blurred, or even lost. The image indicated scoliosis deformity of the spine. The vertebral body lesion could be accurately located. Such diagnosis is more effective. Please refer to Table 1 and Fig. (1) for specific ultrasonic examination results.

4. DISCUSSION

Hemivertebra deformity refers to the vertebral deformity caused by the forming dysfunction of one side of the vertebral body. It is also one of the major reasons for congenital spine deformity. There are two forms: single and multiple. It is rare in clinical cases. Usually, it could be diagnosed through prenatal examination. This disease is often caused by the dysplasia or abnormal development of fetus. The arthromeres of the fetus start to grow from the embryo period and it is formed by the continuous development of the mesoblastema around the neural canals. The ventral side is the sclerotomes inside the fetus. The continuous mesenchyme division and their movement to the vertebral side and the middle consequently wrap around the notochord and develop vertebral column in the fetus [5]. If

Table 1. Prenatal ultrasonic diagnosis of 9 fetuses.

No.	Age of Pregnant Women	Gestational Weeks	Diagnostic Results	Other Deformities
1	23	23	Hemivertebra deformity	Absence of ribs
2	26	24	Hemivertebra deformity	Absence of ribs
3	28	24	Hemivertebra deformity	Absence of ribs
4	22	24	Hemivertebra deformity	Absence of ribs
5	29	24	Hemivertebra deformity	Absence of ribs
6	24	26	Hemivertebra deformity	Absence of both kidneys, absence of ribs
7	24	23	Hemivertebra (instrumented vertebra)	Absence of ribs
8	26	26	Hemivertebra (instrumented vertebra)	Absence of ribs
9	25	25	Multiple hemivertebra (instrumented vertebra)	Schistorachis, acromphalus

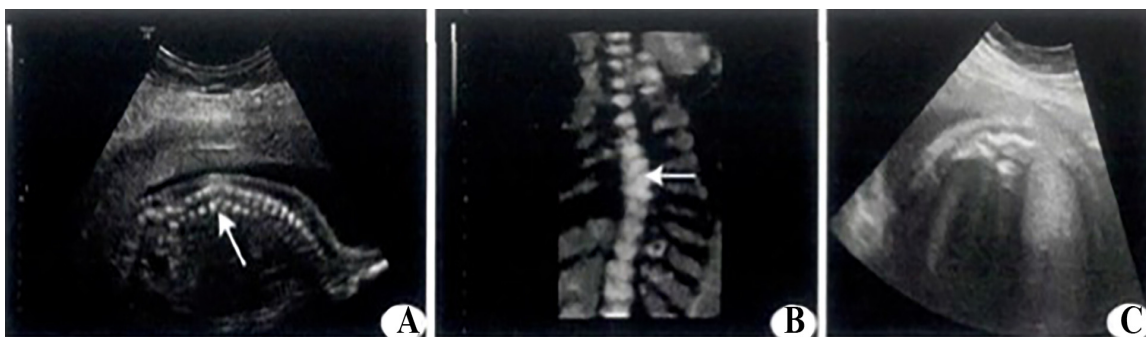


Fig. (1). Ultrasonogram of fetus hemivertebra deformity (A: 2D ultrasonic sagittal view arrow of the vertebral column indicated that lesion vertebral body is smaller than those nearby, with partial loss; B: 3D ultrasonic coronal arrow of the vertebral body was in the shape of triangle; C: The cross section vertebral body was smaller than the normal one and the shape was irregular).

the mesenchyme could not divide normally move effectively, the hemivertebra deformity would be caused, which could severely affect the survival rate and life indexes [6]. Therefore, the strict prenatal examination and imaging of the vertebral column of the fetus is of great significance. It could avoid the further growth of the fetuses with deformity and provide guidance for early treatment as well as the termination of pregnancy [7].

Deformity is one of the main reasons causing the death of fetuses and newborns. It is of great clinical value for the pregnant women to have prenatal examination on fetus deformity. Ultrasonic examination is the most common and effective method in current diagnosis. Showing the advantages of noninvasive, convenient, economic, and repeatable, it could be applied throughout the whole pregnancy. For the diagnosis of hemivertebra deformity, the ultrasonic examination is the best way to make a definite diagnosis. The detection rate of bone bridge could reach 100% [8]. It could able to show both the condition of the vertebral column of the fetus, as well as clearly detected the length, angle of vertebral plate, pedicle of vertebral arch, vertebral body and canalis vertebralis. Moreover, it showed the deformity degrees as well as the lesion location, providing strong evidence for early clinical diagnosis [9, 10].

The 2D ultrasonic examination can clearly show the specific details of the fetus hemivertebra deformity, including the condition of the lesion, the ossification center, the scoliosis, and so on [11, 12]. Even though the 2D ultrasonic examination is able to detect the lesion of hemivertebra, the images are of weak stereoscopic impression and not vivid enough. The clinical physicians have to establish the space of the fetus vertebral body based on the sweeping results, which has certain limitations [13]. In the meantime, if there is no posterior process in the fetus hemivertebra deformity, it is necessary to sweep the ossification centers from multiple sections and check the number, or else, there might be misdiagnosis [14, 15]. In the examination of all organs of the fetus, the 3D ultrasonic examination could present the optimized images of the vertebral column. The 3D ultrasonic examination could even accurately evaluate the condition of the vertebral column and bones of the fetus and detect the abnormal development effectively. This examination could accurately show the condition of the whole vertebral column of the fetus. The condition of scoliosis could be presented better because of the vivid 3D images, so that the lesion part could be precisely located [16]. Besides, the 3D images after reconstruction could be spatially rotated and the indexes could be observed comprehensively from multi angles [17]. Through 3D ultrasonic examination, the examination time for the pregnant women could also be reduced. In the meantime, doctors are able to make clinical diagnostic decisions with the help of reasonable storage of the images [18].

CONCLUSION

In the present study, we have had retrospective analysis on the clinical data of fetus hemivertebra deformity. Through ultrasonic imaging, we have found that 4 cases of the fetus hemivertebra deformity occurred at lumbar vertebra, 3 cases at thoracic vertebra, and 2 cases at thoracolumbar vertebra.

There were scoliosis and opened spine bifida (OSB). In 7 cases, there was absence of ribs in fetus. The 2D ultrasonic image showed that: The echo at the center of fetus vertebral arch lesion was blurred or lost. The coronal section showed the deformity of the spine. There was obvious loss of the ossification center. From the cross section, we could see that the vertebral body of the fetus was shrinking and the edges were relatively blurred. The 3D ultrasonic image showed that: the echo at the ossification center of the fetus vertebra was relatively blurred, or even lost. The image indicated scoliosis deformity of the spine [19]. The major disadvantage of 2D ultrasonography is that while carrying out the 2D ultrasonic examination, the number of ossification centers should be carefully checked, or else, might lead to misdiagnosis. On the other hand, the 3D ultrasonic examination has its own advantages of stereo-imaging to clearly show the condition of the lesion. The images are more vivid and show more sense of space. The simple operation also improves the accuracy and success rate of the diagnosis, which has complemented the weakness of 2D ultrasonic examination and is a way of great diagnostic value. Therefore, the 3D ultrasonic examination is able to locate the vertebral body lesion more accurately and the diagnosis is more effective. Meanwhile, the writer of this paper has analyzed and studied the data of gestational weeks. Due to the fact that the vertebral column of the sacral bone of the fetus starts ossification from the 17th week, so the best time for the pregnant women to have the ultrasonic examination on the hemivertebra of the fetus is after the 18th gestational week [20].

The major advantage of the present study is that it provided a new direction in the field of ultrasonography and warranted future clinical use for the better management of the hemivertebra deformity in the fetus. The only drawback is small sample size. However, a preliminary inference could be made from the above study that a 3 D prenatal ultrasonic examination holds good potential for the timely diagnosis of fetus hemivertebra deformity but future clinical evaluation with large sample is required.

ETHICS APPROVAL AND CONSENT TO PARTICIPATE

Not applicable.

HUMAN AND ANIMAL RIGHTS

No Animals/Humans were used for studies that are base of this research.

CONSENT FOR PUBLICATION

Not applicable.

CONFLICT OF INTEREST

The authors declare no conflict of interest, financial or otherwise.

ACKNOWLEDGEMENTS

Declared none.

REFERENCES

- [1] Zhang HM, Hu B, Lin X, Fu QM, Zhou BH, Jiang ZN. Prenatal ultrasonic manifestation and clinical significance of fetal hemivertebra. *Beijing Da Xue Xue Bao* 2014; 46: 319-22.
- [2] Weisz B, Achiron R, Schindler A, Eisenberg VH, Lipitz S, Zalel Y. Prenatal sonographic diagnosis of hemivertebra. *J Ultrasound Med* 2004; 23: 853-7.
- [3] Chen M, Chan B, Lam TP, Shek T, Lee CP, Tang MH. Sonographic features of hemivertebra at 13 weeks' gestation. *J Obstet Gynaecol Res* 2007; 33: 74-7.
- [4] Goldstein I, Makhoul IR, Weissman A, Drugan A. Hemivertebra: prenatal diagnosis, incidence and characteristics. *Fetal Diagn Ther* 2005; 20: 121-6.
- [5] Gul A, Erol O. Prenatal diagnosis of hemivertebra in association with dextrocardia, atrioventricular septal defect and preaxial polydactyl. *Prena Diagn* 2006; 5: 581-582.
- [6] Huissoud C, Bish C, Charrin K, Rudigoz RC, Guibaud L. Prenatal diagnosis of partial lumbar asoma by two- and three-dimensional ultrasound and computed tomography: Embryological aspects and perinatal management. *Ultrasound Obstet Gynecol* 2008; 32: 579-81.
- [7] Basude S, McDermott L, Newell S, *et al.* Fetal hemivertebra: Associations and perinatal outcome. *Ultrasound Obstet Gynecol* 2015; 45: 434-8.
- [8] Leung YL, Buxton N. Combined diastematomyelia and hemivertebra. A review of the management at a single centre. *J Bone Joint Surg* 2005; 87B: 1380-4.
- [9] Wax JR, Watson WJ, Miller RC, *et al.* Prenatal sonographic diagnosis of hemivertebrae-associations and outcomes. *J Ultrasound Med* 2008; 27: 1023-7.
- [10] Hefti F. Congenital anomalies of the spine. *Orthopade* 2002; 31: 34-43.
- [11] Leung YL, Buxton N. Combined diastematomyelia and hemivertebra. A review of the management at a single centre. *J Bone Joint Surg* 2005; 87-B: 1380-4.
- [12] Has R, Yuksel A, Buyukkurt S, Kalelioglu I, Tatli B. Prenatal diagnosis of diastematomyelia: Presentation of eight cases and review of the literature. *Ultrasound Obstet Gynecol* 2007; 30: 845-9.
- [13] Karasahim KE, Gezginç K, Alanbay I, Ulubay M, Başer I. Ultrasonographic diagnosis of diastematomyelia during the 14th week of gestation. *Taiwan J Obstet Gynecol* 2009; 48: 163-6.
- [14] Bollini G, Launay F, Docquier PL, Viehweger E, Jouve JL. Congenital abnormalities associated with hemivertebrae in relation to hemivertebrae location. *J Pediatr Orthop B* 2010; 19: 90-4.
- [15] Sepulveda W, Wong AE, Fauchon DE. Fetal spinal anomalies in a first-trimester sonographic screening program for aneuploidy. *Prenat Diagn* 2011; 31: 107-14.
- [16] Moser JC. Evaluation of hemivertebrae and fetal ribs using 3D sonography. *J Diagn Med Sonog* 2005; 21: 119-25.
- [17] von Koch CS, Glenn OA, Goldstein RB, Barkovich AJL. Fetal magnetic resonance imaging enhances detection of spinal cord anomalies in patients with sonographically detected bony anomalies of the spine. *J Ultrasound Med* 2005; 24: 781-9.
- [18] Bhaduri M, Fong K, Toi A, Tomlinson G, Okun N. Fetal anatomic survey using three-dimensional ultrasound in conjunction with first-trimester nuchal translucency screening. *Prenat Diagn* 2010; 30: 267-73.
- [19] Chaoui R, Benoit B, Mitkowska-Wosniak H, Heling KS, Nicolaides KH. Assessment of intracranial translucency (IT) in the detection of spina bifida at the 11-13-weeks scan. *Ultrasound Obstet Gynecol* 2009; 34: 249-52.
- [20] Varras M, Akrivis C. Prenatal diagnosis of fetal hemivertebra at 20 weeks' gestation with literature review. *Int J Gen Med* 2010; 3: 197-20.