



Case report

Description of the rare localization of *Dirofilaria repens* in human in the right inguinal lymph node



Larisa Ermakova^{a,c}, Sergey Nagorny^a, Igor Kornienko^{a,b}, Julia Kiosova^a, Sergey Todorov^c, Natalia Pshenichnaya^{c,d,*}, Ainash Kuandykova^e

^a Rostov Research Institute of Microbiology and Parasitology, Rostov-on-Don, Russia

^b Federal Research Center Southern Scientific Center of the Russian Academy of Sciences, Rostov-on-Don, Russia

^c Rostov State Medical University, Rostov-on-Don, Russia

^d Central Research Institute of Epidemiology, Moscow, Russia

^e Khoja Akhmet Yassawi International Kazakh-Turkish University, Turkestan, Kazakhstan

ARTICLE INFO

Article history:

Received 9 May 2020

Accepted 11 November 2020

Keywords:

Dirofilaria repens

Inguinal lymph node

Polymerase chain reaction

ABSTRACT

D. repens is the causative agent of subcutaneous dirofilariasis in canine animals. In recent years, human invasion by this vector-borne helminthiasis has been recorded in many countries with temperate climate, but the localization of this helminth in the cavities of the human body is extremely rare. Cases of atypical localization of *D. repens* are described in the organs of the chest, cervical lymph node, in the spermatic cord and epididymis. It usually requires differential diagnosis with neoplastic or metastatic processes. We report a case of the detection of *Dirofilaria repens* in the right inguinal lymph node in a 56-year-old woman. Helminth was identified by parasitological and molecular biological methods. A morphological study of cross sections of the nematode in histological preparations and molecular biological method, the polymerase chain reaction (PCR) of scrapings of histological material, were used in parallel.

© 2020 The Author(s). Published by Elsevier Ltd. This is an open access article under the CC BY-NC-ND license (<http://creativecommons.org/licenses/by-nc-nd/4.0/>).

Introduction

Dirofilaria repens is a causative agent of subcutaneous dirofilariasis in canine animals, more rarely, feline [1,2]. This transmissible helminthiasis is widespread in areas where high level of damage to the final hosts (canine) is registered, and high level of transmission by mosquitoes of the genera *Aedes*, *Culex*, *Anopheles* takes place. Such regions include the countries of southern Europe and the south of the Russian Federation [3–5]. In these territories *Dirofilaria repens* infection in humans for whom dirofilariasis is “inadvertent human pathogens” are recorded [6].

Annually, in the south of Russia, up to 10 cases of autochthonous transmission of dirofilariasis are reported during the period of maximum mosquito activity [7], usually from May to October. However, there are frequent cases of transportation of this nematode to the northern regions of the Russian Federation. The clinical feature of human *D. repens* invasion is the predominant localization of the nematode subcutaneously in the periorbital area, subconjunctival or under the skin of head or neck (up

to 70 % of cases) [8–10]. Therefore, the cases of rare localization of this helminth are of significant clinical interest.

The aim of this paper is to describe a rare case of *Dirofilaria repens* in human in the right inguinal lymphatic node, that caused problem in diagnosis of dirofilariasis.

Case description

On August 27, 2019, patient S., 53 years old, sought medical attention for bulging and pain in the inguinal area in the medical organization in the city of Tyumen in the North of Russia. She had complaints of mild fever 37.8°C, hyperemia and edema of the skin and pain in the right inguinal area. Palpation revealed a painful, mobile lymph node, enlarged up to 1.5–2 cm in diameter. The patient was examined to exclude infectious diseases (HIV, felinosis), neoplastic and autoimmune processes. Also she received supportive treatment (antibiotics, non steroid anti-inflammatory drugs, H1 histamine blockers). During the treatment, the patient's condition slightly improved, however, a right inguinal lymph node remained enlarged. The results of laboratory and instrumental studies allowed to exclude infectious diseases, the neoplastic and autoimmune processes. Ultrasound examination revealed single inguinal heterogeneous lymphatic node, up to 1.5 cm in diameter.

* Corresponding author at: Central Research Institute of Epidemiology, Moscow, Russia.

E-mail address: pshenichnaya@cmd.su (N. Pshenichnaya).

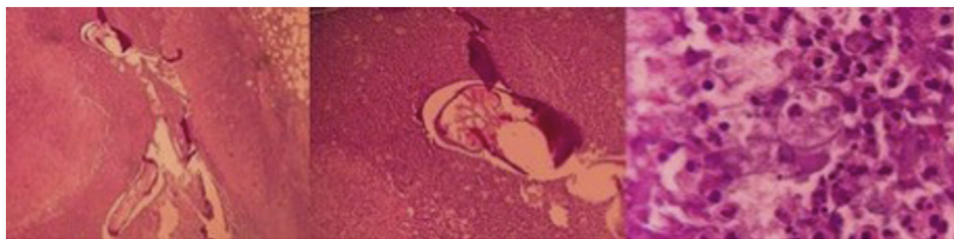


Fig. 1. Histological specimen of the right inguinal lymph node of the patient. ((Description of the histological specimen: in the center of the lymph node there are two transverse sections of dirofilaria, having a cuticular membrane with surrounding pronounced neutrophilic infiltration, macrophage stromal infiltration with chronic purulent inflammation, with an accumulation of neutrophils, giant multinuclear cells such as foreign bodies with the development of granulation tissue. Stained with hematoxylin-eosin. $\times 100$).

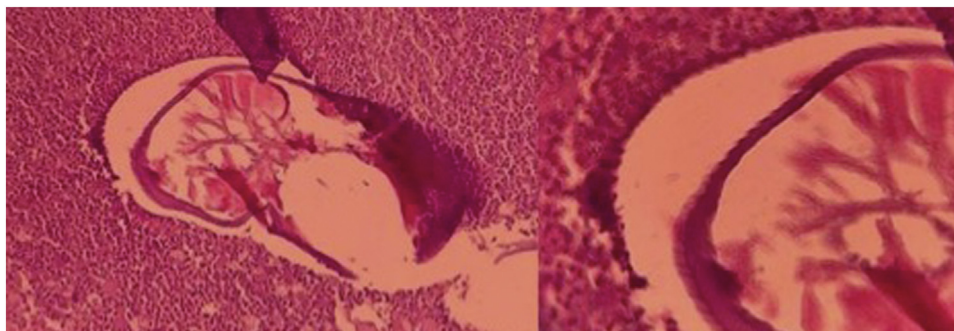


Fig. 2. Cross section of a nematode with comb-shaped cuticular outgrowths.

To exclude the cancer «in situ» right inguinal lymphatic node was removed. Histological picture did not conform any types of neoplasma, but fragments of the helminth were found

The study of histological sections discovered two fragments of a cross section of the nematode in the specimens from the center of the lymph node, with a cuticular membrane with surrounding severe chronic purulent inflammation, and the development of granulation tissue (Fig. 1).

The parasite was identified as *Dirofilaria repens* by the size of the cross-sectional diameters and characteristic comb-shaped outgrowths (Fig. 2).

Later, it was established that patient visited Southeast Asia (India) in the past year. To exclude the tropical anthroponous lymphatic filariasis (brugiosis) as well as the invasion of *D. immitis* we studied the blood by a concentration method to discover microfilaria, but this test was negative.

To identify the species of parasite in histological samples we used polymerase chain reaction (PCR). The material was scraped off with a sterile scalpel from a slide and placed in a sterile 1.5 ml tube. DNA was isolated from histologic sample using a commercial DNA IQ reagent kit (Promega, USA) according to the instructions in the original modification [11]. Using a DNA IQ reagent kit (Promega), highly purified DNA products were obtained.

DNA amplification was carried out by PCR using a GeneAmp PCR System 9700 thermal cycler (Applied Biosystems). To assess the specificity of the amplification reaction, we used positive (a sample with control DNA MK1 – a DNA sample from a person of a known genotype from the COrDISPlus reagent kit (GORDIZ LLC) and negative (a sample without DNA) controls. Electrophoresis was carried out using an ABI PRISM DNA analyzer 3130xl in accordance with the instructions. In the process of electrophoresis, information about laser gel scanning and fluorescence detection was automatically transferred to the control computer and processed by ABI PRISM 3130 DataCollection v. 3.0. The processing of the results and identification of alleles was carried out automatically using the GeneMapper ID program (version 3.2). Alleles

corresponding to the standard ones were identified in the control MK1 DNA sample. Alleles were identified using the S450 size standard and the allelic ice probe attached to the COrDISPlus test system. Studies have identified the presence of degraded DNA belonging to a female person.

In the obtained DNA samples, nematodes were identified by enzymatic amplification on a DT-Prime 5 instrument (DNA Technology, Moscow). Original specific primers were selected and synthesized for PCR for the mitochondrial dirofilaria COI gene fragment (they are at the patenting stage). The final concentration of magnesium ions was 2.5 mM. Amplification modes: initial denaturation at 95 °C for 7 min, then 40 cycles, including 95 °C 10 s, 52 °C 15 s, 72 °C 30 s. Morphologically confirmed samples containing *D. repens* and *D. immitis* DNA were used as a positive control, and a sample without DNA as a negative control. Amplification products were visualized on a 2% agarose gel (Fig. 3).

Species of *D. repens* helminths were verified by the morphological study of nematode cross section and confirmed by PCR.

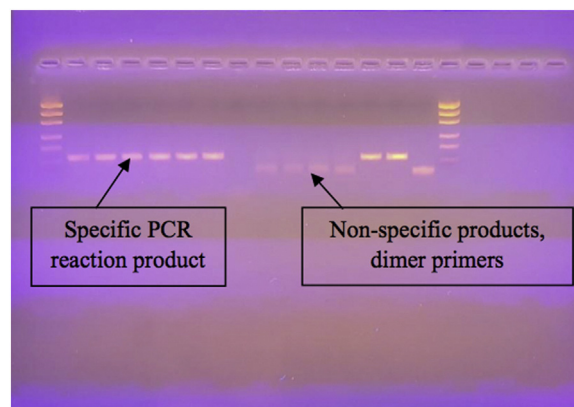


Fig. 3. DNA amplification products of samples.

Discussion

Localization of *D. repens* inside the cavities of the human body is extremely rare. Only isolated cases of atypical localization of this nematode are presented. In 2015 A.M. Bronstein et al. [12] described a case of pleuropulmonary

Dirofilariasis caused by *D. repens*. In 1981, scientists from Israel described a case of *D. repens* in an enlarged, painless cervical lymph node removed from a 29-year-old patient in Israel [13]. In 1997, *D. repens* was found in the spermatic cord in a 52-year-old resident of the province of Ravenna in northern Italy [14]. Also in 2013 in Italy and France, 2 cases of autochthonous dirofilariasis with damage to the spermatic cord and epididymis were described, which led to the formation of false tumors [15]. In a 29-year-old man from St. Tropez (Italy), the formation that appeared in the left epididymus progressed in the form of erythema with damage in the both testicles and spread to the inguinal region, accompanied by leukocytosis. And the 66-year-old man, a resident of the Var department (France) had an inflammatory, firm and mobile nodule attached to the spermatic cord. Histological examination in both cases established *D. repens* invasion. Publications about the rare localizations of this helminth can expand knowledge of the rare localizations of *D. repens* and reduce the time for the establishment of the correct diagnosis.

Conclusion

This case is of significant interest to physicians of various specialities (surgeons, oncologists, infectious disease specialists and pathologists in primarily in the differential diagnosis of malignant neoplasms of the lymphatic system.

CRediT authorship contribution statement

Larisa Ermakova: Conceptualization, Investigation, Methodology, Writing - original draft. **Sergey Nagorny:** Investigation, Methodology, Supervision. **Igor Kornienko:** Investigation, Methodology. **Julia Kiosova:** Investigation, Methodology. **Sergey Todorov:** Writing - original draft. **Natalia Pshenichnaya:** Writing - review & editing, Supervision. **Ainash Kuandykova:** Writing - review & editing.

Declaration of Competing Interest

None.

Acknowledgements

None.

References

- [1] Sergiev VP, Lobzin YuV, Kozlov SS. Human parasitic diseases (protozoa and helminthiases). SPb.: Publishing House Foliant; 2011. p. 608 [in Russian].
- [2] Shulyak BF, Arkhipov IA. Canine nematodoses (zoonoses and zoonotroponoses). Moscow: Moscow Kosmomed; 2008. p. 495 [in Russian].
- [3] Simon F, Siles-Lucas M, Morchon R, et al. Human and animal dirofilariasis: the emergence of a zoonotic mosaic. *Clin Microbiol Rev* 2012;25(3):507–44, doi: <http://dx.doi.org/10.1128/CMR.00012-12>.
- [4] Ermakova L, Nagorny S, Krivorotova E, Pshenichnaya N, Matina O. Dirofilaria repens in the Russian Federation: current epidemiology, diagnosis, and treatment from a federal reference center perspective. *Int J Infect Dis* 2014;23:47–52, doi: <http://dx.doi.org/10.1016/j.ijid.2014.02.008>.
- [5] Ermakova L, Nagorny S, Pshenichnaya N, Krivirotova E. Comments in response to the authors of "Human dirofilariasis due to Dirofilaria repens in the Russian Federation—remarks concerning epidemiology". *Int J Infect Dis* 2014;28:226–7, doi: <http://dx.doi.org/10.1016/j.ijid.2014.04.024>.
- [6] Krivirotova E, Nagorny S. Xenomonitoring of the dirofilariasis in the South and North-West of the Russian Federation. *Parasitol* 2016;50(5):357–64 [in Russian] <https://europepmc.org/article/med/29211425> [accessed 9 May 2020].
- [7] Gratz N. The vector-borne human infections of Europe: the distribution and burden on public health. Geneva: WHO; 2004. p. 144. . [accessed 9 May 2020] <https://apps.who.int/iris/handle/10665/107548>.
- [8] Ermakova L, Nagorny S, Pshenichnaya N, Ambalov Y, Boltachiev K. Clinical and laboratory features of human dirofilariasis in Russia. *IDCases* 2017;9:112–5, doi: <http://dx.doi.org/10.1016/j.idcr.2017.07.006>.
- [9] Klinteberg K, Petersen E, Pshenichnaya N, Ermakova L, Nagorny S, Larsen C. Periorbital Dirofilaria repens imported to Denmark: a human case report. *IDCases* 2015;2(1):25–6, doi: <http://dx.doi.org/10.1016/j.idcr.2014.12.001>.
- [10] Pampiglione S, Rivasi F. Human dirofilariasis due to Dirofilaria (Nochtiella) repens: an update of world literature from 1995 to 2000. *Parassitologia* 2000;42:231–54. . [accessed 9 May 2020] <https://pubmed.ncbi.nlm.nih.gov/11686084/>.
- [11] Kornienko IV, Kharlamov SG. Methods for the study of human DNA. Isolation of DNA and its quantification in the aspect of forensic research of material evidence of biological origin. Rostov-on-Don: SFU; 2012. p. 495 [in Russian].
- [12] Bronstein AM, Malyshev NA, Fedyanina LV, Frolova AA, Davydova IV, et al. Clinical masks of lung and pleurisy dirofilariasis: an analysis of own observations and literature review. *Epidemiol Infect Dis* 2015;20(1):43–9 [in Russian].
- [13] Zweig A, Karasik A, Hiss J. Dirofilaria in a cervical lymph node in Israel. *Hum Pathol* 1981;12(10):939–40, doi: [http://dx.doi.org/10.1016/S0046-8177\(81\)80201-8](http://dx.doi.org/10.1016/S0046-8177(81)80201-8).
- [14] Pampiglione S, Montevecchi R, Lorenzini P, Puccetti M. Dirofilaria (Nochtiella) repens in the spermatic cord: a new human case in Italy. *Bulletin de la Societe de pathologie exotique* 1997;90(1):22–4. . [accessed 9 May 2020] <https://pubmed.ncbi.nlm.nih.gov/9264743/>.
- [15] Leccia N, Patouraux S, Carpentier X, et al. Pseudo-tumor of the scrotum, a rare clinical presentation of dirofilariasis: a report of two autochthonous cases due to Dirofilaria repens. *Pathog Glob Health* 2012;106(6):370–2, doi: <http://dx.doi.org/10.1179/2047773212Y.0000000029>.