



Video-assisted Transaxillary Nipple-sparing Mastectomy and Immediate Implant-based Breast Reconstruction: A Novel and Promising Method



Songbo Zhang¹ · Yanyan Xie¹ · Faqing Liang¹ · Yao Wang¹ · Nan Wen¹ · Jiao Zhou¹ · Yu Feng¹ · Xinran Liu¹ · Qing Lv^{1,2} · Zhenggui Du^{1,2}

Received: 5 April 2021 / Accepted: 7 August 2021 / Published online: 23 August 2021
© Springer Science+Business Media, LLC, part of Springer Nature and International Society of Aesthetic Plastic Surgery 2021

Abstract

Background Although video-assisted breast surgery is gaining popularity, endoscopic reconstruction after mastectomy is still facing lots of problems, bring about that endoscopic method has not yet become a standard procedure for breast cancer reconstruction. Here, we introduce a novel surgical technique of video-assisted transaxillary nipple-sparing mastectomy and immediate implant-based breast reconstruction and describe the detailed surgical procedure using this technique.

Methods Detailed steps of surgical procedure, the patient characteristics and the mean operative time of this new technique were described in this article. All patients were asked to score their satisfaction with their reconstructed breasts preoperatively, 1 month, 3 months, 6 months and 12 months postoperatively using the BREAST-Q.

Results At first, we used our “conventional method” and performed on 10 patients from April 2017 to June 2020; the operative time was 324.80 ± 66.39 minutes. After improving several procedures of the technique, the “optimized method” was performed on 14 cases from July 2020 to November 2020; the operative time decreased to 193.71 ± 28.75 minutes with shortest was 133 minutes; the optimized method was novel and easy to learn and be generalized. Most of the patients were satisfied with the

reconstruction results. There was no significant difference between preoperative scores and scores at 3 months, 6 months and 12 months ($p = 0.364$). Since there is no wound on the breast dome, no obvious postoperative complications were observed except for one patient presented with infection.

Conclusions This new technique has allowed surgeons to achieve excellent and reproducible outcomes in a single-stage procedure and represents an excellent technique for patients who wish to have a scarless and aesthetically pleasing appearance after mastectomy for breast cancer. This article also highlights the mean operative time (193.71 ± 28.75 minutes) that has been made possible with this new technique.

Level of Evidence V This journal requires that authors assign a level of evidence to each article. For a full description of these Evidence-Based Medicine ratings, please refer to the Table of Contents or the online Instructions to Authors <http://www.springer.com/00266>.

Keywords Breast reconstruction · Endoscope · Nipple-sparing mastectomy · Transaxillary · Implant · Operative time

Introduction

Breast cancer is the most common cancer among women worldwide [1, 2]. In the development of breast cancer treatment, minimizing the surgical wound, and preserving the function and aesthetic appearance have always been the ultimate goals after securing oncological safety. Endoscopic or robotic mastectomy with implant reconstruction is a novel surgical treatment trend that provides better cosmetic outcomes for breast cancer patients [3, 4]. It is

Songbo Zhang and Yanyan Xie have contributed equally to this study.

✉ Zhenggui Du
docduzg@163.com

¹ Department of Breast Surgery, West China Hospital, Sichuan University, 37 Guoxue Street, Chengdu 610041, China

² Clinical Research Center for Breast, West China Hospital, Sichuan University, Sichuan, China

difficult to build air cavity by many existing methods of endoscopic mastectomy and implant reconstruction, which leads to the requirements of special equipments such as a skin-lift system, longer operative time and relatively more visible scar despite the small incision [5–7]. Moreover, robot-assisted surgery is expensive, [8–10] which brings patients financial burdens. For those reasons, endoscopic methods have not yet become standard for breast cancer reconstruction [6, 11]. This study presents a novel surgical approach for video-assisted transaxillary mastectomy and immediate implant breast reconstruction, which is recommended for patients without breast ptosis. This technique does not require special surgical equipments and allows surgeons to easily perform mastectomy in a very short time without compromising oncological safety or leaving a scar on or near the breast dome. Moreover, it is easy to learn and has many advantages and limited complications; therefore, we believe that this technique has the potential to become a popular technique in the future.

Patients and Methods

This surgical method is indicated for all patients who are qualified for nipple-sparing mastectomy. Indications: 1. early breast cancer (tumor size ≤ 5 cm) with radiotherapy contraindications or reluctance to undergo radiotherapy; 2. the distance from tumor to nipple ≥ 2 cm; 3. young, healthy, nonsmoking patients with no to mild breast ptosis who have not had prior breast surgery or radiation; 4. fusion tendency of lymph nodes. Contraindications: 1. patients with Paget's disease, breasts with moderate or severe ptosis and skin involvement of tumor; 2. centrally located tumor that was suspicious for nipple and areola or pectoralis muscle involvement as assessed by physical examination or radiological studies; 3. microcalcifications close to the subareolar region. For patients with negative clinical assessment for lymph nodes, sentinel lymph node biopsy (SLNB) was recommended primarily. If SLNB or preoperative aspiration biopsy was positive, axillary lymph nodes dissection (ALND) was recommended primarily. Follow-up treatments including chemotherapy, radiotherapy and endocrine therapy were applied according to the patient's tumor grading. Preoperatively, standard examinations for breast cancer such as physical examination, ultrasound and mammography should be performed. Informed consent forms were acquired from all of the patients before surgeries. All patients were asked to score their satisfaction with the reconstructed breasts preoperatively, 1 month, 3 months, 6 months and 1 months post-operatively using BREAST-Q.

Surgical Technique

A detailed video demonstrating the procedure can be accessed in Video 1 (Supplemental Digital Content 1).

Markings

Preoperative marking was performed with the patient in the standing position. An embedded-in-axilla line of approximately 5–7 cm and two special markings were drawn (Fig. 1A.a.). The solid line was drawn at the inframammary fold, while the dotted line where the pectoralis major was divided in the later procedures was drawn approximately 1–1.5 cm below the solid line.

Positioning and Preparation

Cefazolin 2.0 gram were administered 30 min prior to the first incision and would be administered 12 hours after the surgery. For the procedure, the patient was placed in a supine position. The arm on the operation side that was left available in case axillary removal was required. The chest wall was prepped and draped under standard sterile management. It should be noted that the operated side arm should be wrapped particularly to lift it up to the forehead during surgery and expose the axillary fossa under endoscopic vision.

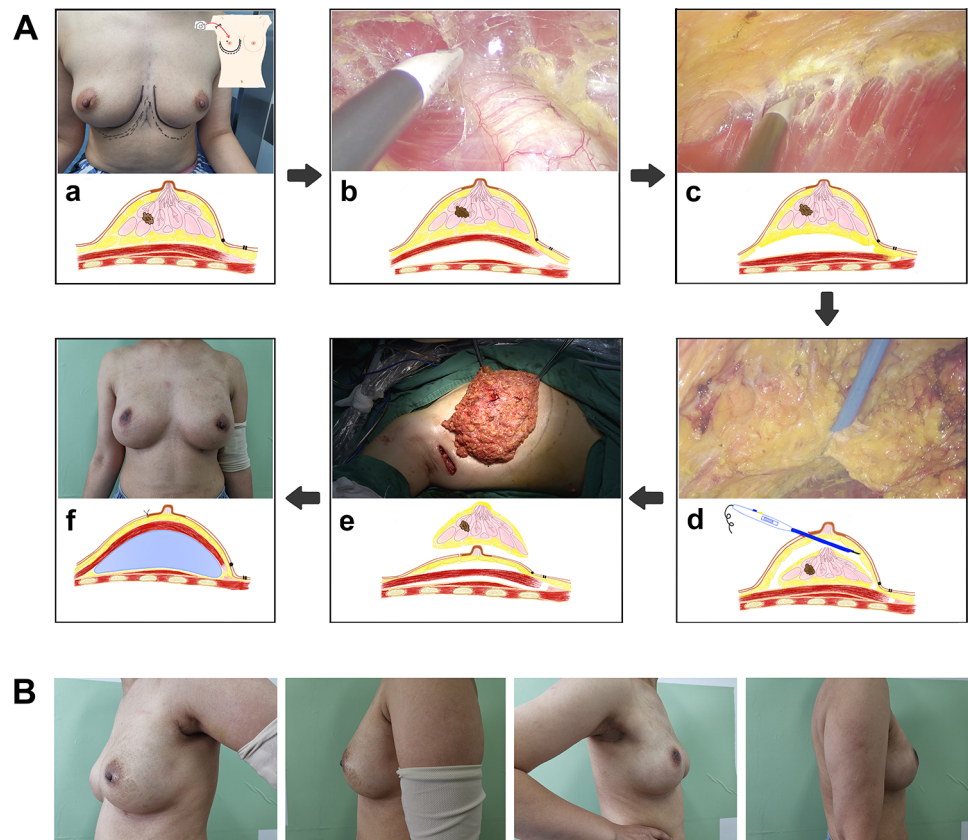
Axillary Incision

Incision was made along the embedded-in-axilla line marking using Peng's multifunctional operative dissector (Shuyou SY-IIA-2), and ALND or SLNB were performed manually by Peng's dissector as needed.

Air Cavity Building and Subpectoral and Retromammary Space Dissection

First, the dissection was started with a Peng's dissector in the posterior space to the pectoralis major muscle in a 5 cm area under direct vision. The disposable wound retractor/protector (SHKA80/90-80/150), wrapped by the opening end of one sterile surgical glove (6#), was placed through the incision. Surgical sterile gloves have accurate elasticity to perfectly fit the lap-protector and achieve air tightness. Two bladeless trocars (Aesculap, EJ701R and EJ751R) were inserted into different fingerholes of the glove to create entry sites for the coagulation hook (Aesculap,

Fig. 1 Surgical procedures. **a** a. markings; **b**. subpectoral space dissection; **c**. retromammary space dissection; **d**. subcutaneous dissection; **e**. the whole gland was dissected out; **f**. implant placement. **b** Three months after reconstruction



GK372R+GK384R) and endoscope (KARL-STORZ). Although the GelPort laparoscopic system may achieve the same result [12], it is not cost effective, and its limited diameter leads to rigid instrumentation and problems with instrument collision. Using a soft surgical sterile glove not only is cost-effective, but also increases the agility of the surgical technique. Muscle relaxants should be administered by an anesthesiologist before constructing the air cavity. The patency of the optical cavity was maintained by coordinating the application of CO₂ insufflation at 10–12 mmHg pressure.

At this point, the coagulation hook was inserted to dissociate the fascia between the pectoralis major and pectoralis minor or ribs until it reached the medial and inferior endpoint of the pectoralis major (Fig. 1A.b.). Given the abundance of vessels in the muscle bundle, the medial and inferior attachment points of the pectoralis major were dissociated along the dotted lines using an ultrasonic knife (Ethicon Endo-Surgery HAR36) to avoid bleeding. Then, dissociation of the serratus anterior fascia was continued using the coagulation hook in the dotted line laterally, and an ultrasonic knife was used to stop the bleeding.

Subsequently, the lap-protector was loaded, and the retromammary space was dissected approximately 5 cm under direct vision. Using the same method, dissociation of the retromammary space was continued to the solid line

inferiorly, the infraclavicular line superiorly and the parasternal line medially under endoscopic vision (Fig. 1A.c.). Careful preservation of the serratus anterior fascia should be noted when dissociating the lateral and lateral-inferior parts.

Subcutaneous Dissection and Creation of the “HUAXI Hole 1”

First, the outer upper quadrant was dissociated under direct vision until the root of the nipple was cut off. The transected end of the nipple was sent for intraoperative frozen sectioning. Next, the air cavity was constructed using the same method. Thereafter, the subcutaneous plane of the breast was dissected using Peng’s dissector inserted through a 5-mm small incision, which was named “HUAXI Hole 1.” To hide the scar as much as possible, the “HUAXI Hole 1” is usually created at the superior-lateral margin of the areola. Due to this small incision, Peng’s dissector could easily dissociate the superomedial, inferomedial and inferolateral parts of the breast flap under endoscopic vision. The whole gland was then excised and removed via the axillary incision (Fig. 1A. d, A. e.).

Definition of the Conventional Method and Optimized Method

Before July 2020, our dissectional order of layers was “prepectoral-subcutaneous-submuscular” which is called “conventional method” in this article. To optimize the surgery, after July 2020, our dissectional order of layers was improved to “submuscular-prepectoral-subcutaneous” as described in the surgical procedure of this article which is called “optimized method” in this article.

Implant Cavity Irrigation and Breast Reconstruction

The implant cavity was irrigated, and appropriate surgical drainage was instituted with a drainage tube that exited from the end of the axillary incision. Prosthesis was then conducted into the submuscular cavity as usual (Fig. 1A, f.). The axillary incision wound was closed using a subcuticular running suture.

Clinical Experience and Results

Patient Demographics and Procedural Characteristics

A retrospective review of all the patients who underwent video-assisted transaxillary nipple-sparing mastectomy and immediate implant-based breast reconstruction was performed. Twenty-four consecutive female patients (27 breasts reconstructed in total) underwent this procedure between April 22, 2017, and November 6, 2020. The age of the patients ranged from 28 to 37 years, and the body mass index ranged from 17.2 to 20.2 kg/m². The tumor sizes were verified by the results of postoperative biopsy. All patients were operated by a single surgeon. Three patients underwent bilateral reconstruction, one of whom underwent left expander and right prosthesis reconstruction. Among the study subjects, 75% had invasive ductal carcinoma. All of the patients’ tumors were within 5 cm. The prosthesis used ranged from 180 to 585 cc. Median follow-up time of 24 patients is 10.85 months. Detailed baseline data are shown in Table 1. The postoperative results are shown in Fig. 1B. Six more patients’ postoperative front views are shown in Fig. 2A.

Table 1 Clinical and demographic characteristics of patients

	No./total No. (%) of patients (n = 24)
Age, mean(SD), y	39.04 (8.405)
Height, mean(SD), cm	158.00 (4.672)
Weight, mean(SD), kg	54.04 (6.532)
Body mass index, mean(SD)	21.66 (2.610)
<i>Laterality of reconstruction, No.(%)</i>	
Unilateral	21 (87.5%)
Bilateral	3 (12.5%)
<i>Reconstruction materials, No.(%)</i>	
Prosthesis	19* (79.2%)
Expander	6* (25.0%)
<i>Diagnosis, No.(%)</i>	
DCIS	6 (25.0%)
IDC	18 (75.0%)
<i>Tumor size(cm), No.(%)</i>	
≤2	17 (70.8%)
>2, ≤5	6 (25.0%)
Unknown	1 (4.2%)
<i>Tumor location, No.(%)</i>	
Central or peri-areolar	6 (25.0%)
Lateral	7 (29.2%)
Medial	9 (37.5%)
Borderline	1 (4.2%)
Unknown	1 (4.2%)
<i>No. of metastatic lymph nodes, No.(%)</i>	
None	20 (83.3%)
1-3	2 (8.3%)
4-9	1 (4.2%)
>10 or subclavical	0 (0.0%)
Unknown	1 (4.2%)
<i>Lymph node management, No.(%)</i>	
SLND	17 (70.8%)
ALND	6 (25.0%)
ALND after SLND	1 (4.2%)
<i>Nipple management</i>	
Nipple removal	1 (4.2%)
Nipple spare	23 (95.8%)

DCIS ductal carcinoma in situ, IDC invasive ductal carcinoma, SLND sentinel lymph node dissection, ALND axillary lymph node dissection
* Represents including one patient with prosthesis on one side and with expander on the other side

Operative Time

Our team first started performing endoscopic transaxillary nipple-sparing mastectomy and immediate implant-based breast reconstruction in April 2017. The mean operative time and anesthesia time are shown in Table 2. The

Fig. 2 Six patients' postoperative front views. **a** Right-side reconstruction; **b** right-side reconstruction; **c** left-side reconstruction; **d** left-side reconstruction; **e** right-side reconstruction; **f** right-side reconstruction

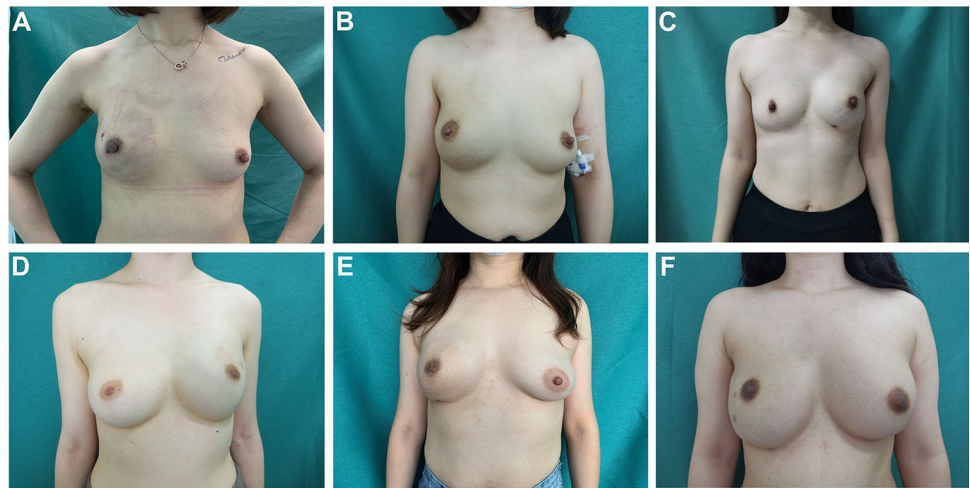
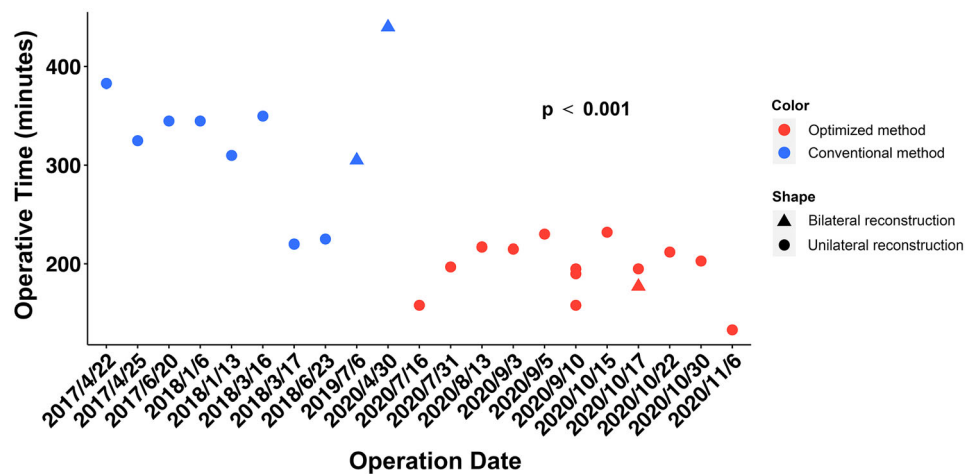


Table 2 Operative and anesthesia time by dissection orders

	Conventional method	Optimized method	<i>p</i> value
Operative time (minutes)	324.80 ± 66.39	193.71 ± 28.75	< 0.001
Anesthesia time (minutes)	408.40 ± 72.55	214.29 ± 95.15	< 0.001

Fig. 3 Variation trend of the operative time of 24 individual cases from April 2017 to November 2020



variation trend in operative time of individual cases is shown in Fig. 3, in which a dramatic decrease of the operative time, due to the surgical optimization, was observed during the period from April 2017 to November 2020.

Cost Analysis

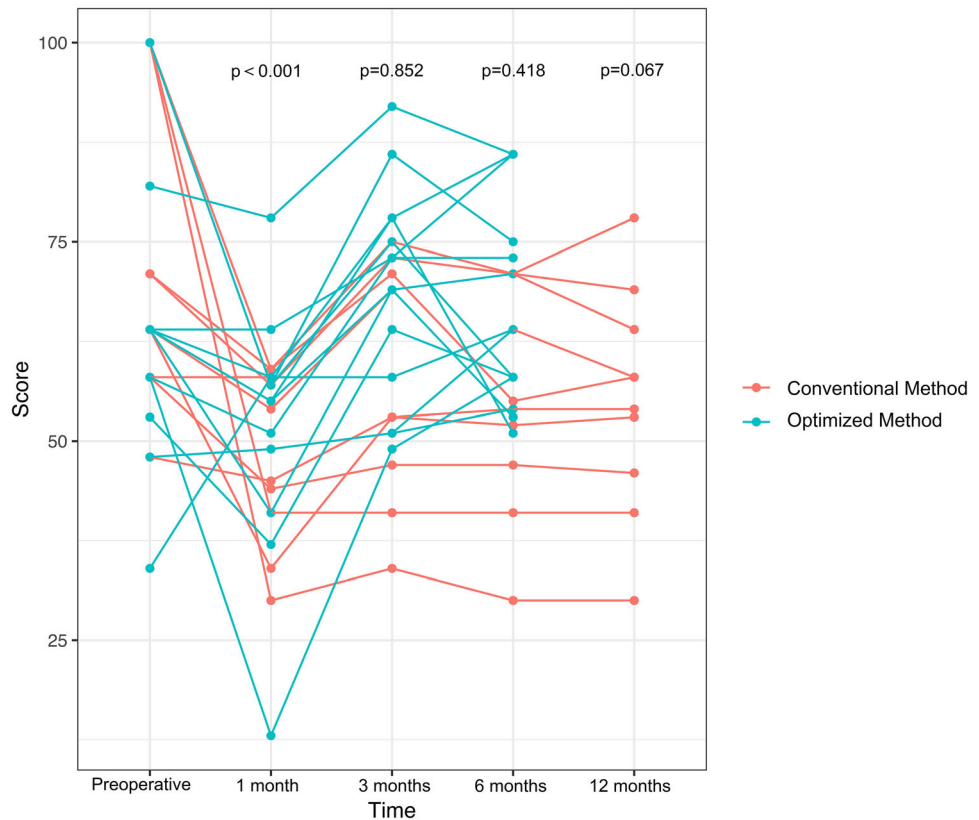
The total hospitalization expense was 35966.78 ± 11560.27 CNY (5533.69 ± 1778.61 USD) by this new technique versus 35307.52 ± 12118.84 CNY (5432.51 ± 1864.64 USD) by open surgery (*p* = 0.03).

Patients' Satisfaction and Complications

Although the patient-reported outcome of satisfaction with the breasts (score using BREAST-Q) decreased from 68.13 ± 19.14 preoperatively to 50.12 ± 13.13 at 1 month (*p* < 0.001) after the surgery, revival scores of 64.17 ± 14.54, 62.21 ± 14.10, 55.10 ± 13.89 were observed at 3 months, 6 months, 12 months, respectively. There was no significant difference between preoperative scores and scores at 3 months, 6 months, 12 months (*p* = 0.852, 0.418, 0.067, respectively). Patients' scorings are shown in Fig. 4; some of the postoperative scorings even exceeded the preoperative scorings.

In terms of postoperative complications, there were no cases of postoperative hemorrhage and ischemia. Implant

Fig. 4 Variation trend of 24 patients' BREAST-Q scoring on satisfaction with the breast preoperatively, 1 month, 3 months, 6 months and 12 months postoperatively



loss on account of postoperative infection occurred in one case. Due to the absence of an incision and scar on the breast dome, the incision and nipple-areolar complication rates were extremely low.

Oncological Safety

So far, recurrence and survival rates of our optimized method and conventional method are both zero. Longer follow-up data need further updating. Our technique follows the rules of nipple-sparing mastectomy. So, we assume that the recurrence and survival rate of this method should be as same as of nipple-sparing mastectomy and the oncological safety is guaranteed.

Discussion

Although video-assisted breast surgery is gaining popularity, endoscopic reconstruction after mastectomy is still facing lots of problems such as the endoscopic limitations of small working space, rigid instrumentation and instrument collision [13], dissociation difficulties caused by falling mammary glands after subcutaneous dissociation, and the fact that prosthesis cavity maintenance can only be

achieved by retractors. While the skin-lift system has previously solved the retractor difficulty, uneven forces on the dissected layer still led to poor surgical vision and dissociation difficulties, increased surgery time and reduced surgical performance [5, 7]. Thus, endoscopic method is still not a standard surgical option for breast reconstruction after mastectomy [6, 11]. New innovative techniques are needed to make endoscopic breast reconstruction easier and more standardized.

Instead, our technique changed the conventional dissection order of layers [13] to the newly described dissection order. We have taken advantage of the tension formed by the air cavity, which makes the breast a tent-like structure to dissect the subpectoral space fascia. The retromammary space and subcutaneous tissue are then dissected utilizing the air cavity tension combined with the gravity of the pectoralis major muscle and mammary gland. Our technique enables surgeons to have greater surgical vision during surgery and improved surgical efficiency without the need for specialized equipment, thereby avoiding the time-consuming deficiencies; thus, it is easy to learn and generalize.

We also introduce the novel concept of “HUAXI Hole 1.” “HUAXI Hole 1” is a small incision at the superior-lateral margin of the areola, through which the longest Peng’s dissector is inserted, allowing surgeons to easily

reach the inferomedial, inferolateral and superomedial quadrants. Also, this new method brought surgeons back to the old operative hand feelings by using electric dissector which is easier to handle than the coagulation hook or ultrasonic knife. The incision is very small (5 mm), leaving almost no visible scar on the breast and therefore improves the aesthetics of the breast compared to that obtained in other techniques.

After improving the dissection order and making good use of “HUAXI Hole 1,” we were able to decrease the average operative time, including axillary operation, from our conventional method of 324.80 ± 66.39 minutes to our optimized method of 193.71 ± 28.75 minutes (shortest was 133 minutes). In contrast, the mean operative time for the skin-lift method [14] (including axillary management) is 347 minutes. Moreover, robot-assisted mastectomy with implant breast reconstruction takes approximately 150 min without axillary operation and 351 min with axillary operation [8, 15]. Our operative time is so far the shortest in either endoscopic or robot-assisted method. Robot-assisted surgery also adds a significant financial burden. Indeed, research has shown that approximately 3732 USD is needed for robot-assisted surgery compared with endoscopic surgery [9, 16]. Since there is no other special surgical instruments except for endoscopic-related instruments were needed during the surgery of the new technique, along with the fact that it is a relatively minimally invasive procedure which reduces the time of hospitalization stay, the average total hospitalization expense of this new technique was just 101.18 USD more than that of traditional open surgery ($p = 0.03$).

The prosthesis was placed into the subpectoral layer. To perform the subpectoral insertion in a post-mastectomy reconstruction situation, the cut end of the pectoralis major muscle is attached to the inframammary fold by subcutaneous fat tissue. This method allows the pectoralis major muscle to completely cover the prosthesis, increasing the covering thickness and making the breasts look more upright, youthful and round, while rendering the prosthesis outline intangible. Importantly, no mesh is needed to cover the prosthesis, which reduces the overall procedure cost, making it accessible to more patients. In contrast, this new endoscopic method requires no special equipment or artificial mesh; therefore, it is much more inexpensive than robotic surgery or traditional open surgery of prosthesis plus mesh breast reconstruction and also carries a lower risk of implant extrusion.

Lastly, the absence of a wound on the breast dome reduces the possibility of wound rupture due to tension. Instead, the incision is designed at the strainless axilla; consequently, the incision does not affect the vasculature of the breast flap, which in turn reduces the risk of flap and nipple-areolar necrosis, improves flap viability and allows

for earlier recovery. Due to the reasons mentioned above, the risk of graft loss due to incision complications or ischemic necrosis of the nipple-areola complex can also be lowered. Compared to the scar along the extension of the axillary fold to the lateral breast border [13], our new method has no obvious wound scar on breast dome of later breast side. This has extremely improved the aesthetic appearance of the breast.

There were no incidences of flap ischemia and hemorrhage during the postoperative care of both conventional method and optimized method, and only one patient presented with infection. This patient’s postoperative dressing changes were delayed due to the ongoing COVID-19 pandemic, which resulted in retrograde infection of the drainage tube. She insisted on prosthesis removal due to concerns regarding her oncological disease and her eagerness for chemotherapy, even though the infection was well controlled after anti-inflammatory therapy. So far, there was no incidence that our transaxillary approach had to be converted to open technique or complete dissection. Only one patient was performed nipple dissection and reconstruction due to the tumor invasion of tumor according to the biopsy during surgery.

The possibility of capsule contracture is relatively high in patients who present lymph node metastasis and need radiotherapy. In order to lower the possibility of capsular contracture, we generally adopt three solutions: 1. properly expand the prosthesis cavity, choose a slightly smaller prosthesis and strengthen postoperative massage; 2. biplane method of subpectoral prosthesis and mesh breast reconstruction; 3. prepectoral implant-based breast reconstruction.

The experience from our center has shown promising results. In our opinion, if patients are suitable candidates for simple subcutaneous resection (i.e., tumor size <5 cm that does not invade the subcutaneous tissue or pectoralis major muscle, and without breast ptosis), this new method could be a suitable first choice. However, there are barriers to implementing this innovation more broadly. The first barrier is that the subpectoral insertion method is not suitable for patients with ptosis. Aiming at this, we developed an alternative endoscopic method for patients with ptosis using a prosthesis and mesh that covers the prosthesis evenly. We already have implemented this method to our patients and gained encouraging postoperative results. The second barrier is that although subpectoral implant reconstruction reduces expenses, it is true that several patients complained of muscle-related discomfort, such as chest pain, dragging sensation of the chest muscle and difficulty breathing, a short time after surgery. Although median follow-up time 10.85 months is limited for oncological safety verification which needs to be

continuedly updated, it is relatively sufficient to observe the aesthetic result of breast reconstruction.

Conclusions

Here we have described some of the technical pearls and pitfalls that we have identified when performing video-assisted transaxillary nipple-sparing mastectomy and immediate implant-based breast reconstruction in 24 patients during the past 3 years. Based on our experience, this method is a safe, reliable and easy to learn technique and provides an extraordinary single-stage breast reconstruction after mastectomy.

Funding This study was supported by grants from projects of the Science and Technology Department, Sichuan province, China under Grant 2019YFH0146, 2020YFS0199 and Health Commission of Sichuan Province under Grant Research Project on Healthcare in Sichuan Province, 2019-107. None of the authors has a financial interest in any of the products, devices or drugs mentioned in this manuscript.

Declarations

Conflict of interest The authors declare that they have no conflicts of interest to disclose.

Ethical approval All procedures performed in studies involving human participants were in accordance with the ethical standards of the institutional and/or national research committee.

Informed consent Informed consent is not required for this type of study.

References

- Chen Z, Xu L, Shi W et al (2020) Trends of female and male breast cancer incidence at the global, regional, and national levels, 1990–2017. *Breast Cancer Res Treat* 180:481–490
- Jagsi R, Jiang J, Momoh AO et al (2014) Trends and variation in use of breast reconstruction in patients with breast cancer undergoing mastectomy in the United States. *J Clin Oncol* 32:919–926
- Leff DR, Vashisht R, Yongue G et al (2011) Endoscopic breast surgery: where are we now and what might the future hold for video-assisted breast surgery? *Breast Cancer Res Treat* 125:607–625
- Angarita FA, Castelo M, Englesakis M et al (2020) Robot-assisted nipple-sparing mastectomy: systematic review. *Br J Surg* 107(12):1580–1594
- Wang Y, Wu JX, Guan S (2017) A technique of endoscopic nipple-sparing mastectomy for breast cancer. *JSLs* 21:e2017.00028
- Satake T, Narui K, Muto M et al (2018) Endoscopic nipple-sparing mastectomy with immediate multistage fat grafting for total breast reconstruction: a new combination for minimal scar breast cancer surgery. *Plast Reconstr Surg* 142:816e–818e
- Friedlander LD, Sundin J, Bakshandeh N (1995) Endoscopy mastectomy and breast reconstruction: endoscopic breast surgery. *Aesthetic Plast Surg* 19:27–29
- Toesca A, Peradze N, Galimberti V et al (2017) Robotic nipple-sparing mastectomy and immediate breast reconstruction with implant: first report of surgical technique. *Ann Surg* 266:e28–e30
- Ahn SJ, Song SY, Park HS et al (2019) Early experiences with robot-assisted prosthetic breast reconstruction. *Arch Plast Surg* 46:79–83
- Toesca A, Invento A, Massari G et al (2019) Update on the feasibility and progress on robotic breast surgery. *Ann Surg Oncol* 26:3046–3051
- Owaki T, Kijima Y, Yoshinaka H et al (2015) Present status of endoscopic mastectomy for breast cancer. *World J Clin Oncol* 6:25–29
- Ross HM, Simmang CL, Fleshman JW et al (2008) Adoption of laparoscopic colectomy: results and implications of ASCRS hands-on course participation. *Surg Innov* 15:179–183
- Tukenmez M, Ozden BC, Agcaoglu O et al (2014) Videoendoscopic single-port nipple-sparing mastectomy and immediate reconstruction. *J Laparoendosc Adv Surg Tech A* 24:77–82
- Franceschini G, Visconti G, Garganese G et al (2020) Nipple-sparing mastectomy combined with endoscopic immediate reconstruction via axillary incision for breast cancer: a preliminary experience of an innovative technique. *Breast J* 26:206–210
- Park HS, Lee J, Lee DW et al (2019) Robot-assisted nipple-sparing mastectomy with immediate breast reconstruction: an initial experience. *Sci Rep* 9:15669
- Lai HW, Chen ST, Tai CM et al (2020) Robotic- versus endoscopic-assisted nipple-sparing mastectomy with immediate prosthesis breast reconstruction in the management of breast cancer: a case-control comparison study with analysis of clinical outcomes, learning curve, patient-reported aesthetic results, and medical cost. *Ann Surg Oncol* 27:2255–2268

Publisher's Note Springer Nature remains neutral with regard to jurisdictional claims in published maps and institutional affiliations.