

This is an Open Access article licensed under the terms of the Creative Commons Attribution-NonCommercial-NoDerivs 3.0 License (www.karger.com/OA-license), applicable to the online version of the article only. Distribution for non-commercial purposes only.

Video Capsule Retention in a Zenker Diverticulum

A. Horiuchi^a Y. Nakayama^{a, b} M. Kajiyama^a N. Kato^a
T. Kamijima^a Y. Ichise^a N. Tanaka^{a, c}

^aDigestive Disease Center, Showa Inan General Hospital, Komagane;

^bDepartment of Pediatrics, Shinshu University School of Medicine, and

^cDepartment of Metabolic Regulation, Shinshu University Graduate School of Medicine, Matsumoto, Japan

Key Words

Video capsule · Retention · Zenker diverticulum

Abstract

We report the case of a video capsule endoscope lodged within a Zenker diverticulum. The system that was equipped with a real-time viewer showed an unchanging image unlike esophageal or gastric mucosa, suggesting that the capsule was elsewhere. The presence of cervical discomfort suggested video capsule retention in a Zenker diverticulum. The capsule was removed endoscopically and reinserted using a hood-assisted endoscope and the procedure was completed.

Introduction

Since the technology introducing video capsule endoscopy was for the first time presented during Digestive Disease Week in May 2000 and the first brief communication was published in Nature [1], video capsule endoscopy has been widely used in clinical practice. To date more than 600,000 capsules have been deployed worldwide [2]. Video capsule endoscopy is a useful tool for evaluating small bowel disease, but appropriate indications and rates of detection, completion, and retention vary. Video capsule endoscopy is based on gastrointestinal motility allowing the swallowed capsule to record the mucosa of the gastrointestinal mucosa as the capsule travels, usually uneventfully, down the gastrointestinal tract.

In this case, the patient felt discomfort in the cervical portion shortly after swallowing the capsule. The equipped real-time viewer continued to show the unchanged image that was different from an ordinary image of the mucosa of the esophagus or stomach. Using upper endoscopy video capsule retention in a Zenker diverticulum was clarified and the capsule was safely removed endoscopically. This report describes the case of a video

capsule endoscope lodged within a Zenker diverticulum, including the usefulness of the equipped real-time viewer and hood-assisted upper endoscope.

Case Report

A 66-year-old man underwent evaluation for intermittent melena. His family history was unremarkable. His past history showed no significant illness except for appendectomy. Physical examination revealed no abnormality. The white blood cell count was 4,720/ μ l (normal 3,800–8,600). However, a slight iron deficiency anemia was found as follows: red blood cell count 4.47×10^6 (normal $4.1\text{--}5.3 \times 10^6$), hemoglobin 12.1 g/dl (normal 14.0–18.0 g/dl), hematocrit 38.7% (normal 39.0–52.0%), serum iron 36 μ g/dl (normal 80–200 μ g/dl), total iron binding capacity 349 μ g/dl (normal 271–469 μ g/dl), and ferritin 6.4 ng/ml (normal 27.0–211.0 ng/ml). All other standard laboratory tests were within normal ranges. Plain chest radiograph and electrocardiogram were normal. Upper endoscopy and colonoscopy did not show any potential cause.

Immediately after swallowing a capsule endoscope (Olympus, Tokyo, Japan) the patient complained of discomfort in the cervical region. The system was equipped with a real-time viewer that showed an unchanging image different from the expected images of the mucosa of the esophagus or stomach. The presence of discomfort in the cervical portion and the image of the capsule endoscopy led to the suspicion that the capsule might be lodged within a cervical diverticulum. Upper endoscopy (GIF-XQ260, Olympus, Tokyo, Japan) under propofol sedation confirmed the retention of the capsule along with food within a Zenker diverticulum ([fig. 1](#)). The capsule was retrieved using a Roth net ([fig. 2](#)). A hood-fitted upper endoscope was used to examine the Zenker diverticulum and upper esophagus ([fig. 3](#), [fig. 4](#)). Endoscope-assisted capsule placement was done to allow completion of the study.

Discussion

There are several reports of capsule retention in various types of duodenal, small bowel and large bowel diverticula [3, 4]. Not very many reports exist describing retention in a Zenker diverticulum, hopefully because the capsule is placed with endoscopic guidance in these patients [5]. Zenker diverticulum was first described by Ludlow in 1769 [6]. However, it was Friedrich von Zenker who recognized Zenker diverticulum results from increased intrapharyngeal pressure [7]. Zenker diverticulum is located proximal to the upper esophageal sphincter usually on the posterior hypopharyngeal wall and is thought to result from increased intrapharyngeal pressure [8].

Zenker diverticulum usually occurs between the seventh and eighth decades of life, and rarely before the age of 40 years [9]. It occurs predominately in men. The prevalence of Zenker diverticulum among the general population is believed to be between 0.01 and 0.11% [10]. The incidence varies based on region, but it has been described more frequently in the US, Canada and Australia than in Japan and Indonesia [11]. In the UK, the incidence of Zenker diverticulum is about 2 per 100,000 people per year [12]. However, the true incidence of Zenker diverticulum is difficult to establish since the number of asymptomatic patients is unknown.

In this case, retention of the capsule endoscope was the first suggestion of the existence of a heretofore asymptomatic Zenker diverticulum, although the patient did have an initial upper endoscopy which should have noted the presence of the diverticulum. The presence of the real-time viewer proved useful for quickly allowing retention of the capsule within a diverticulum to be considered. Whenever a Zenker diverticulum is suspected, the capsule should probably be placed using

some nonendoscopic method where it is attached to a holder that could be used, hopefully because the capsule is being placed with endoscopic guidance in these patients [5, 13].

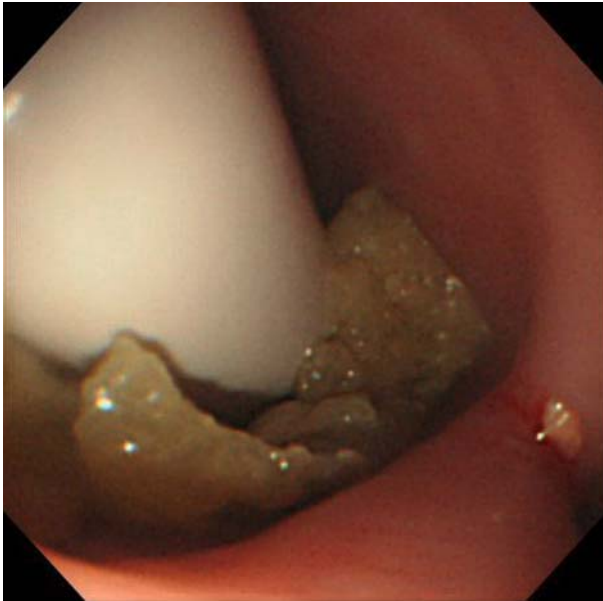


Fig. 1. Upper endoscopy under propofol sedation confirmed the retention of the capsule along with food within a Zenker diverticulum.

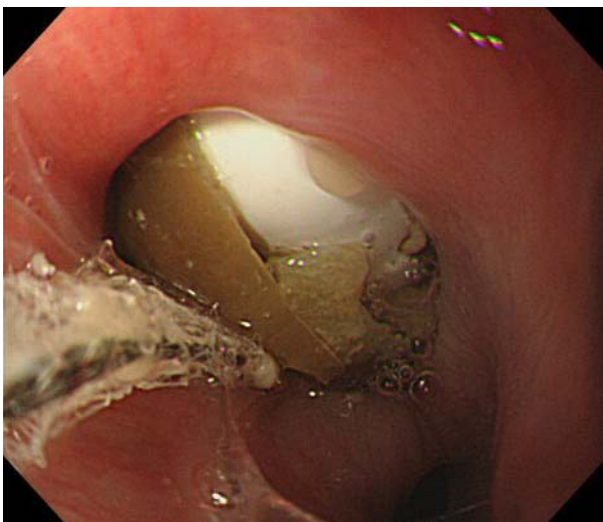


Fig. 2. The capsule was grasped using a Roth net.

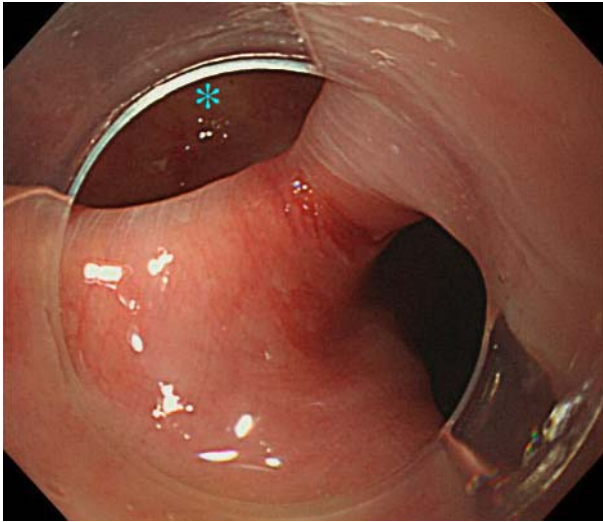


Fig. 3. Hood-assisted upper endoscopy clarified the border of Zenker diverticulum (asterisk) and upper esophagus.

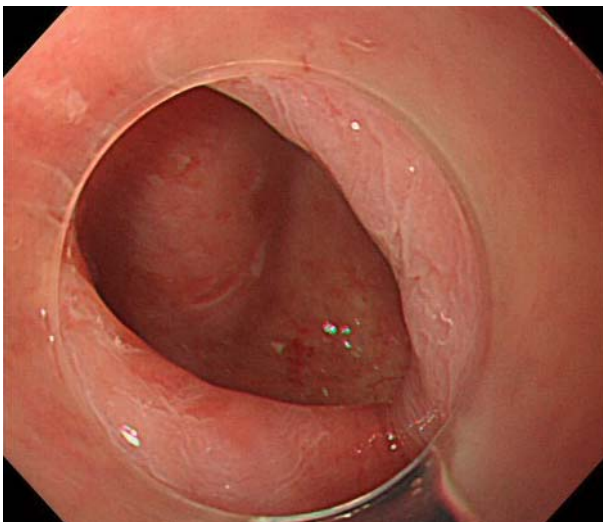


Fig. 4. The whole Zenker diverticulum was shown by hood-assisted upper endoscopy.

References

- 1 Iddan G, Meron G, Glukhovsky A, Swain P: Wireless capsule endoscopy. *Nature* 2000;405:417.
- 2 Waterman M, Eliakim R: Capsule enteroscopy of the small intestine. *Abdom Imaging* 2009;34:452–458.
- 3 Ordubadi P, Blaha B, Schmid A, Krampla W, Hinterberger W, Gschwantler M: Capsule endoscopy with retention of the capsule in a duodenal diverticulum. *Endoscopy* 2008;40:E247–E248.
- 4 Giday SA, Pickett-Blakely OE, Buscaglia JM, Mullin GE: Capsule retention in a patient with small-bowel diverticulosis. *Gastrointest Endosc* 2009;69:384–386.
- 5 Ferreira LE, Simmons DT, Baron TH: Zenker's diverticula: pathophysiology, clinical presentation, and flexible endoscopic management. *Dis Esophagus* 2008;21:1–8.
- 6 Ludlow A: A case of obstructed deglutition from a prenatal dilatation of a bag formed in the pharynx. *Med Observ Inq Soc Phys* 1769;3:85–101.
- 7 Zenker FA, von Ziemssen H: Krankheiten des Oesophagus: in von Ziemssen H (ed): *Handbuch der Speciellen Pathologie and Therapie*. Leipzig, FCW Vogel, 1877, pp 1–87.
- 8 Wouters B, Van Overbeek JJM: Pathogenesis and endoscopic treatment of the hypopharyngeal (Zenker's) diverticulum. *Acta Gastroenterol Belg* 1990;53:323–329.
- 9 Maran AGD, Wilson JA, Al Muhanna AH: Pharyngeal diverticula. *Clin Otolaryngol* 1986;11:219–225.
- 10 Watemberg S, Landau O, Avrahami R: Zenker's diverticulum: reappraisal. *Am J Gastroenterol* 1996;91:1494–1498.
- 11 van Overbeek JJ, Groote AD: Zenker's diverticulum. *Curr Opin Otolaryngol Head Neck Surg* 1994;2:55–58.
- 12 Siddiq MA, Sood S, Strachan D: Pharyngeal pouch (Zenker's diverticulum). *Postgrad Med J* 2001;77:506–511.
- 13 Simmons DT, Baron TH: Endoscopic retrieval of a capsule endoscope from a Zenker's diverticulum. *Dis Esophagus* 2005;18:338–339.