



Spinal Infections

Advances in diagnosis and management of atypical spinal infections: A comprehensive review



Glenn A. Gonzalez, MD^{a,*}, Guilherme Porto, MD^a, Eric Tecce^a, Yazan Shamli Oghli, MSc^a, Jingya Miao^a, Matthew O'Leary^a, Daniela Perez Chadid^b, Michael Vo^a, James Harrop, MD, MSHQS^a

^a Department of Neurosurgery, Thomas Jefferson University and Jefferson Hospital for Neuroscience, 909 Walnut St, Philadelphia, PA 19107, United States

^b Universidad CES, Faculty of Medicine, Medellín, Antioquia, Colombia

ARTICLE INFO

Keywords:

Atypical spine infections
Blastomycosis
Brucellosis
Coccidioides
Cryptococcus
Epidural abscess/Empyema
Histoplasma capsulatum
Intradiscal abscess
Subdural empyema

ABSTRACT

Atypical spinal infections (ASIs) of the spine are a challenging pathology to management with potentially devastating morbidity and mortality. To identify patients with atypical spinal infections, it is important to recognize the often insidious clinical and radiographic presentations, in the setting of indolent and smoldering organism growth. Trending of inflammatory markers, and culturing of organisms, is essential.

Once identified, the spinal infection should be treated with antibiotics and possibly various surgical interventions including decompression and possible fusion depending on spine structural integrity and stability. Early diagnosis of ASIs and immediate treatment of debilitating conditions, such as epidural abscess, correlate with fewer neurological deficits and a shorter duration of medical treatment. There have been great advances in surgical interventions and spinal fusion techniques for patients with spinal infection. Overall, ASIs remain a perplexing pathology that could be successfully treated with early diagnosis and immediate, appropriate medical, and surgical management.

Background

Atypical spinal infections (ASIs) are significant, yet relatively rare diseases that occur when a pathogen invades the spinal apparatus, which includes bony elements, surrounding paraspinal tissues, epidural, or intradiscal spaces. On imaging, patients may exhibit vertebral endplate destruction and abscesses. Clinically, they may experience symptoms such as pain, paralysis, incontinence, fever, and other manifestations. Infections can vary in terms of type, location, pathogenesis, clinical presentation, severity, and risk factors. Consequently, the approach to managing and treating spine infections must be tailored to these aforementioned factors, particularly when dealing with atypical infections. The occurrence and nature of spinal infections exhibit significant disparities between developed and developing countries. The definition of an “atypical” spinal infection primarily relies on the prevailing understanding of what is considered “typical” within a specific clinical setting. In contrast, developing countries face distinctive challenges characterized by limited access to healthcare facilities, inadequate sanitation, and prevalent socioeconomic factors.

Non-tuberculous mycobacteria (NTM) spinal infections have been linked to past outbreaks [1,2], affecting both individuals with intact immune systems and those with compromised immune function. While NTM infections can occur in immunocompetent individuals, they are more commonly observed in individuals with immunosuppression, including those with autoimmune diseases or Acquired immunodeficiency syndrome (AIDS), as well as those with other chronic conditions [3]. In this review, we will initiate a comprehensive discussion on the epidemiology of spinal infections, with a specific focus on atypical cases. Subsequently, we will delve into an in-depth exploration of pathogenesis, clinical presentation, and diagnosis, including atypical microorganisms. Lastly, we will address the various aspects of treatment and management.

Epidemiology and types of spine infection

Spinal infections account for up to 7% of all cases of osteomyelitis [4]. The most common levels of infection are the lumbar vertebrae

FDA device/drug status: Not applicable.

Author disclosures: **GAG**: Nothing to disclose. **GP**: Nothing to disclose. **ET**: Nothing to disclose. **YSO**: Nothing to disclose. **JM**: Nothing to disclose. **ML**: Nothing to disclose. **DPC**: Nothing to disclose. **MV**: Nothing to disclose. **JH**: Nothing to disclose.

* Corresponding author. Department of Neurosurgery, Thomas Jefferson University, 909 Walnut St, Philadelphia, PA 19107, USA. Tel.: 215-955-6440.

E-mail address: glennarturo.gonzalezozuna@jefferson.edu (G.A. Gonzalez).

<https://doi.org/10.1016/j.xnsj.2023.100282>

Received 30 May 2023; Received in revised form 28 July 2023; Accepted 24 September 2023

Available online 28 September 2023

2666-5484/© 2023 The Author(s). Published by Elsevier Inc. on behalf of North American Spine Society. This is an open access article under the CC BY-NC-ND license (<http://creativecommons.org/licenses/by-nc-nd/4.0/>)

(58%), followed by the thoracic (33%) and cervical (11%). In developing countries, the limited healthcare infrastructure, lack of access to diagnostic tools, and challenges in accurate case reporting can contribute to underestimating the prevalence rates of NTM. Additionally, regional variations in environmental exposure to NTM species and differences in population demographics and immune status can further influence the prevalence rates [5]. In recent years, NTM have garnered significant attention due to their propensity to infect individuals with compromised immune systems, such as those with human immunodeficiency virus (HIV) infection, cystic fibrosis or those who have undergone organ transplants [6–8]. While the respiratory system serves as the primary site of NTM infection, it is also noteworthy that infections can occur in the skin and skeletal muscle following injection or trauma [9,10].

Furthermore, certain patient populations require special consideration, including those who have recently undergone spinal surgery or received intravascular devices, individuals who have traveled to regions with high endemicity [11]. It is crucial to remain attentive to the possibility of pediatric spine infections, which, although less prevalent, can manifest subtly and may be associated with potential bacteremia originating from ear, nose, or throat infections [12]. Early recognition of ASIs is crucial because standard antibiotics will not work to clear mycobacterium species, fungal, and viral pathogens, and the treatment course is much longer and intensive for atypical organisms [13].

There are differences based on the type of spinal infection that patients develop. Spondylodiscitis, which is an infection of the spinal cord disc and the adjacent VB, is the most common type of spinal infection [14]. Epidural abscess can also occur through bacterial contiguous spread through the medullary canal, and it often presents with abscesses in other locations of the body. Subdural empyema is less common and is often secondary to osteomyelitis elsewhere in the spine [15]. Subdural empyema in the cervical or thoracic spine presents with a rapid decline in medical and neurological well-being due to cord compression, and drainage of pus is crucial to reduce morbidity and long-term complications [16]. Other spinal infections include spinal meningitis, which often occurs due to *Neisseria meningitidis*, an atypical gram-negative bacterium that can lead to life-threatening sepsis [17].

Pathogenesis

The development of spinal infections can have various causes, but taking a comprehensive approach to investigation through history, clinical, imaging, and lab findings is crucial for determining the appropriate treatment and prognosis for patients. Neurosurgical, radiological, and infectious disease specialists often collaborate to determine the pathogenesis of ASIs. There are 3 ways that pathogens can invade the spine: (1) hematogenous spread from a distant infection site, which is the most common cause; (2) direct external inoculation after surgery; or (3) dissemination from contiguous tissues such as the aorta, esophagus, or abdominopelvic structures [18].

To understand hematogenous spread, it is important to consider the vasculature of the spine. The subclavian artery, coming off the aortic arch, branches into vertebral arteries which join to form the anterior spinal artery [19]. The anterior spinal artery supplies the anterior two-thirds of the spine and travels down the spinal cord through the anterolateral sulcus. A pair of posterior spinal arteries also travel down the cord and supply the posterior one-third. At each vertebral segment, the spinal arteries branch into segmental spinal arteries, which then become anterior and posterior radicular arteries.

It is thought that, through hematogenous spread, pathogens (mainly bacteria) become lodged in the arteriolar end-plate arcades [13]. Additionally, it was demonstrated by Batson in 1967 that venous backflow through the pelvic venous plexus to the vertebral venous plexus can occur, which may explain why most spine infections occur in the lumbar region [18,20]. Hematogenous spread has been documented to occur through remote infections across many sites, with 30% of all

hematological spine infections being associated with bacterial endocarditis [18,21]. Urinary tract infections also increase the predisposition to lumbar spine infections, with nearby structures such as the psoas major muscle being affected [22]. Hematogenous spread to the spine is also associated with spread from the respiratory tract, gastrointestinal system, the skin, and even tooth brushing, although most cases of sepsis-related spinal infection are difficult to isolate to a single remote site [14].

Surgical site infections (SSI) are another cause of pathogenesis, with a reported risk of up to 16% postoperatively, depending on the type of procedure, duration, length of stay, and patient factors such as age and medical history [23]. The risk is increased when devices such as interbody cages, screws and rods are implanted, as they can act as breeding grounds for micro-organisms to proliferate and develop a polysaccharide biofilm, hampering antibiotic effectiveness and host immune function. SSIs of the spine are associated with prolonged hospitalization and mortality for the patient, as well as a significant financial burden on the healthcare system.

Finally, direct dissemination of pathogens from contiguous tissue is possible, with reports of infection spreading from the esophagus, aorta, pelvis, pressure sores, and even directly from adjacent vertebral bodies being documented [4,14,22,24,25].

Clinical presentation

Neck or back pain is usually the first and major clinical manifestation of vertebral osteomyelitis. The location of pain is typically localized to the infected region, but it may radiate to other areas such as the abdomen, hip, leg, scrotum, groin, and/or perineum. Pain usually begins insidiously and may initially be absent or non-focal, but then worsens over several weeks to months. Most studies have reported that around 95% of cases present with pain [11,26] but a retrospective study reported up to 30% of cases can present without pain [27]. It is therefore imperative to perform a full workup if there is suspicion of a spinal infection, even without pain. Pain is often worse during physical activity and at night and may be accompanied by reduced spinal mobility [28]. Palpation or percussion of the area can exacerbate spinal pain, and palpation of paravertebral muscles can cause tenderness and spasm. Severe and sharp pain may indicate an epidural abscess, which occurs when infections extend posteriorly into the epidural space. Fever is inconsistently present, with only 36% to 60% of all cases and up to 45% of bacterial-caused vertebral osteomyelitis [29,30].

Neurological impairment is reported in 20% to 30% of cases. Motor weakness is the most common presentation, while other neurological signs include sensory loss, radiculopathy, sphincter dysfunction, or paralysis in severe situations [11,29]. However, new neurological symptoms can occur in a median of 11 days after diagnosis, with an interquartile range of 4 to 24 in a retrospective study and a range of 1 to 45 in a prospective study [11,31]. Risk factors for progressing to severe neurological deficits include epidural abscess, cervical and/or thoracic involvement, and a C-Reactive Protein (CRP) test level greater than 150 mg/L. The eventual prognosis was mostly favorable, despite neurological deterioration occurring in 30% of patients with severe neurological deficits [11].

Importantly, vertebral osteomyelitis is often a secondary complication due to hematogenous spread, and manifestations of the primary infection may initially dominate the clinical presentation. About 3-quarters of cases are found to be associated with bacteremia, and up to 20% of cases are associated with endocarditis [31]. Therefore, a careful general physical examination is essential to detect potential sources, such as injection sites, recent urinary tract infection, or skin or soft tissue infection. The physical examination may also find a distended bladder due to spinal cord compression, flank pain, or pain with hip extension. ASIs may have atypical clinical symptoms. Rarely, cat scratch disease-associated vertebral osteomyelitis, for example, may present with atlantoaxial instability, torticollis, or fever [32,33].

Diagnosis

Initial diagnostic tests

The initial assessment tests for suspected spinal infection consist of 3 parts: inflammatory markers (CRP, erythrocyte sedimentation rate (ESR), and white blood cell count), microbiology culture (2 sets of blood culture and serologic tests), and spine imaging (usually magnetic resonance imaging [MRI]). All patients with suspected spinal infection should have baseline CRP and ESR levels collected. CRP is a critical parameter for diagnosis and treatment monitoring due to its high sensitivity for detecting inflammation and short half-life (24 hours). While a high CRP level is not specific to any disease or organ, it can be highly specific in diagnosing spinal osteomyelitis when coupled with positive clinical symptoms and/or positive MRI findings. A high CRP level (>150 mg/L) [11] has also been identified as an independent risk factor for progressing to severe neurologic deficits and has been associated with higher mortality (when CRP \geq 100 mg/L.³⁴ However, normal CRP values (\leq 10 mg/L) cannot rule out spinal infection [26].

In addition to CRP, serum procalcitonin level, which is sensitive in monitoring bacterial infections such as pneumonia and sepsis, may be a useful diagnostic biomarker in an emergency setting or for postoperative spinal infection [27,35]. Trending of inflammatory markers can be used to ensure appropriate response to antibiotic therapy over time. Microbiological culture of blood (and urine) is the primary diagnostic test for identifying pathogens, and samples should be cultured to detect aerobic, anaerobic, mycobacterial, and fungal microbes. Serology tests can provide valuable additional information due to the limitations of traditional culture methods, which include slow or intracellular bacterial growth. For instance, targeting serologic tests is important to confirm the presence of intracellular bacteria such as Brucella, Coxiella, and Bartonella.

Spine MRI is considered to be the most sensitive imaging technique for diagnosing vertebral osteomyelitis and epidural abscess and should include at least 3 images: T1-weighted, T2-weighted, and T1-contrast enhanced [36–38]. Typical findings that are associated with each include hypointensity of the vertebral bodies and disc with loss of endplate definition in T1-weighted images, hyperintense disc, and less commonly, hyperintense VB in T2-weighted or STIR images; and contrast enhancement of the affected vertebral bodies and disc [36–38]. Additionally, MRI can help examine the progression of the disease (such as paravertebral abscess, intraductal collection, vertebral collapse), and identify other causes of inflammatory spinal pain (such as spondyloarthropathy, neoplasia) [30,31]. In cases where MRI is contraindicated, computed tomography (CT), plain radiography, radionuclide scanning, or bone scintigraphy can be used as an alternative imaging technique. Fludeoxyglucose (FDG)-positron emission tomography (PET)/CT is highly sensitive for diagnosing spinal infection and paraspinal soft-tissue infection. FDG-PET is superior to gallium (Ga-67) imaging and bone scintigraphy (eg, Technetium-99m) in detecting soft-tissue infections and differentiating them from degenerative arthritis. However, the specificity of FDG-PET is considerably reduced by the presence of tumors, degenerative changes, and/or spinal implants [39–41].

Further diagnostic tests

In patients with at least 2 sets of positive blood cultures, which suggests the presence of bacteria, biopsy is not necessary. However, in all other cases, a percutaneous needle biopsy is recommended to confirm the microbiological and histological diagnosis before starting antimicrobial therapy [31]. It is important to note that prior exposure to antibiotics can reduce the biopsy's accuracy, so a 14-day washout period may be ideal before performing the biopsy. In cases of severe sepsis or neurological deficits, empirical antibiotic therapy should be initiated regardless of the risk of biopsy's negative result. If the initial biopsy is negative, a second biopsy is recommended to establish the microbiolog-

ical diagnosis if serology from blood, urine or other target organ systems fail to identify a causative organism. In those cases, a second biopsy can be successful in up to 80% of cases [42,43].

The microbiological yield is highly dependent on the sites of biopsy and affected regions. Cultures of affected soft tissues (eg, disc, epidural abscess) have higher sensitivity ranging from 65% to 90%, whereas bone biopsies have lower sensitivity ranging from 30% to 40% [44–47]. Biopsy samples should be sent for microbiology cultures to detect responsible pathogens. Histological and serology tests are particularly useful in identifying slow-growing or intracellular pathogens (eg, Mycobacterium tuberculosis, Brucella) and/or chronic inflammation conditions (eg, the presence of caseous granulomas indicating chronic tuberculosis).

Nucleic-acid amplification testing (NAAT) or whole genome sequencing (WGS) can be used to search for known but rare pathogens for the diagnosis of atypical infections [48]. Particularly, 16S rRNA PCR combined with culture can be useful for detecting rare pathogens [49,50]. Unlike WGS, which matches the sample to the whole genome of a given organism, metagenomic next-generation sequencing (mNGS) can detect both known and unexpected pathogens in a target-independent way [51,52]. Therefore, mNGS is especially helpful in cases infected by atypical pathogens, when management can often be complicated and prolonged [53–55].

Differential diagnosis

ASIs may exhibit a variety of symptoms, posing challenges in distinguishing them from other conditions. The absence of prior infection signs in 30% to 70% of patients makes early diagnosis difficult [56]. The pain usually has a gradual onset and worsens at night. Neurologic deficits are present in about a third of patients, usually in advanced stages of the disease. Differential diagnoses should consider various conditions [57].

To differentiate ASIs from a neoplastic process, the involvement of the disc space must be considered. Although both conditions can cause bony destruction and osteolysis, disc involvement is highly uncommon in tumor spread but is a hallmark of infection. Thus, a well-defined vertebral end plate with a normal signal within the disc suggests a neoplastic process. Additionally, infection-related edema tends to obscure fat planes in the paravertebral soft tissues, whereas a neoplastic process often leaves the fat planes intact or only partially obscured [58]. Involvement of a single VB is rare in both pyogenic infections and can sometimes mimic tumor involvement, with evidence of marrow edema and cortical disruption present [59]. Moreover, infective processes can extend from the VB to involve the posterior element [60–62]. Differentiating between spinal tumors and infections can be challenging, as both conditions may present with insidious onset back pain that may worsen at night. MR imaging and laboratory tests can often be nonspecific, requiring blood cultures, open biopsy, or CT-guided percutaneous needle aspiration biopsy to differentiate the 2 conditions reliably [63,64].

Imaging differentiation among micro-organisms

Pyogenic infections primarily affect the lumbar region, while tuberculous infections involve the thoracic/thoracolumbar junction. Brucellar infections are more prevalent in the lower lumbar region, and fungal infections primarily affect the lumbar region [65–69]. In the case of pyogenic infections, the early stage is characterized by T1 hypointensity and T2 hyperintensity in the anterior aspect of the VB. In the late stage, there is VB destruction, along with T2 hyperintensity and homogeneous enhancement, accompanied by adjacent VB involvement. Tuberculous infections exhibit 3 patterns in the early stage: para-discal involvement with contiguous spread to adjacent VB, anterior scalloping of VB with large subligamentous abscesses, and central involvement resulting in vertebral plana deformity without intervertebral disc (IVD)

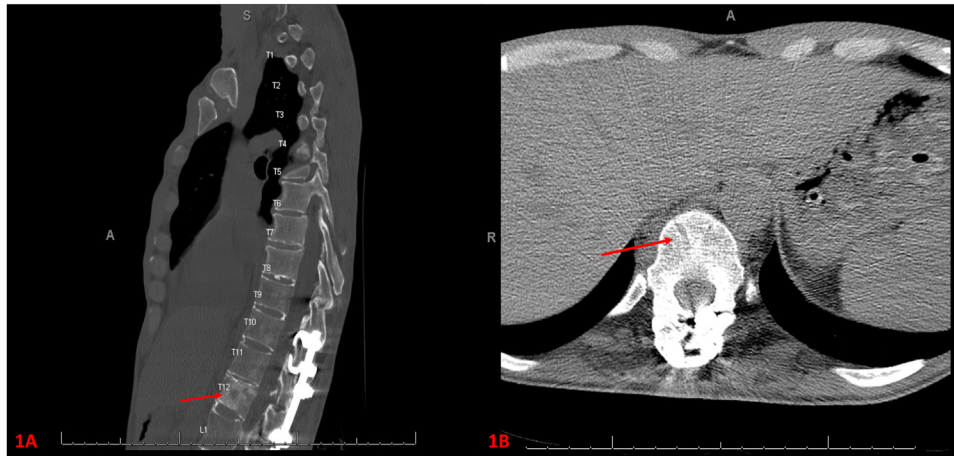


Figure. Imaging showed a patient with a history of recurrent lumbar infection status post washout. The patient was on dalbavancin and fluconazole for MRSA and *Candida* in cultures. **Figure A/B:** A CT scan without contrast shows the pedicles and body of the T12 vertebra exhibiting a heterogeneous, mixed lytic sclerotic appearance with mild anterior wedging.

involvement. Late-stage tuberculous infections display variable T1 intensity with bone healing and relatively preserved VB.

Brucellar infections often present with serrated margins of vertebral endplates without severe VB destruction. Disc space involvement is present in all etiologies except for brucellar infections, showing varying degrees of T2 hyperintensity and irregular rim enhancement. Paraspinal/epidural space involvement is absent in brucellar infections, while other etiologies demonstrate inflammation and/or small abscesses with thick and irregular rim enhancement. Posterior elements, such as rib heads, are typically unaffected, except in cases of tuberculous and fungal infections. Adjacent vertebral level involvement and skip lesions are common. Anterior subligamentous spread is uncommon, except in tuberculous infections where it can be more extensive than the vertebral involvement. Adjacent vertebral level involvement is observed in pyogenic and tuberculous infections with endplate destruction, but it is uncommon in brucellar and fungal infections. Multilevel involvement is infrequent, except in tuberculous and fungal infections where skip lesions are commonly observed [65–70]. (Figure).

Micro-organisms

ASIs are caused by 3 major classes of micro-organisms: bacterial infections, fungal infections, and parasitic infections. Mycobacterium tuberculosis was previously associated with up to 50% of patients with spine infections, but it is no longer the most common microorganism in developed countries [71]. *Staphylococcus aureus* is responsible for 20% to 84% of spine infections, while 5% to 20% are caused by streptococci and enterococci, and less than 4% are caused by anaerobic micro-organisms [34,72,73].

On the contrary, nontuberculous mycobacteria (NTM) have emerged as pathogens that impact individuals with both compromised and intact immune systems [74]. NTM encompass a diverse group of more than 150 mycobacterial species, with the exception of those classified within the *Mycobacterium tuberculosis* complex and *Mycobacterium leprae* [75]. Human diseases resulting from NTM are classified into 4 distinct clinical syndromes: chronic pulmonary disease, lymphadenitis, cutaneous disease, and disseminated disease [76]. Disseminated NTM infection is recognized as a fatal opportunistic disease in individuals with acquired immunodeficiency syndrome (AIDS), leading to notable mortality rates. The prevalence of any NTM species among people living with HIV was determined to be 49% (96 out of 196) [77].

Furthermore, *Escherichia coli* is responsible for 7% to 33% of pyogenic infections. Different organisms have associated risk factors. For instance, the risk of spinal infection with *Pseudomonas aeruginosa*

is increased in patients who use intravenous drugs, while the risk of *Staphylococcus epidermidis* is elevated in patients with prosthetic joint replacements [78]. Salmonellosis affecting the spine is often observed in children with sickle cell disease [79].

One of the more atypical etiologies of bacterial spine infections is *Brucella*. Brucellosis is the most common bacterial zoonosis, with over 500,000 worldwide cases annually.[80] A majority of cases come from endemic areas in Mediterranean countries and the Middle East.[81] *Brucella* is often found in infected farm animals, with transmission through animal contact. It is estimated that 2% to 54% of brucella infections involve the spine, particularly in the lumbar region [82–84] Diagnosis can be difficult, as many other etiologies that are more common can present similarly, and thus often requires core-needle biopsy.

Another atypical culprit of bacterial spinal infection is *Cutibacterium acnes*. *C. acnes* is anaerobic, nonspore forming, Gram-positive rod [85]. It is part of normal skin and oral flora, with heavy concentration in the back and neck, which has been theorized as a potential reason for its involvement in shoulder and spine pathology [86]. Reported bone infections attributed to *C acnes* varies, and is estimated between 2% and 18% [87]. Studies have reported positive cultures for *C acnes* in disc material from herniated discs, leading to a potential association with nucleus pulposus herniations [87]. *Kingella kingae* is a gram-negative organism that is often implicated in spondylodiscitis in children, and is believed to be one of the most common causes in those between the age of 4 months and 48 months [88]. *K. kingae* colonizes the oropharynx, and it is theorized that damage to the mucosal layer by a previous or concurrent viral illness can lead to entry into the bloodstream and thus hematogenous spread to IVDs [89,90]. Clinical presentation is often mild, and history often demonstrates a recent upper respiration infection [91]. Isolation of *K. kingae* is difficult, however the use of aerobic blood culture vials or NAAT can lead to identification, as traditional culture is often negative [14].

Fungal infections of the spine are rare and are typically caused by opportunistic fungi in immunocompromised patients. A case series of 11 patients with fungal spine infections found that nine of eleven patients experienced some type of immune deficiency [92]. A meta-analysis of the literature on fungal infections of the spine found that aspergillus and candida species were the most common fungal organisms (38.2% and 22.9% of total patients, respectively) [25]. All other organisms were isolated far less frequently, and included *coccidioides* (13.5%), *Blastomycosis* (8.3%), *Cryptococcus* (6.4%), *Histoplasma capsulatum* (1.3%), *Pseudallescheria boydii* (2.5), and *Zygomycosis* (1.3%) [25]. In patients with spinal aspergillosis, 71.4% also had lung involvement, and 50% of the patients had recently undergone surgery [25]. Twenty-two percent of

patients with spinal candidiasis also had a malignancy, and 75% had recently undergone surgery [93]. Diagnosis of fungal spine infections requires a high index of suspicion, imaging studies, and fungal cultures.

Parasitic infections of the spine are uncommon and are typically caused by protozoa and helminths. Patients infected with these infections often have a history of travel to endemic areas or have compromised immune systems. Cysticercosis, caused by *Taenia solium*, is the most common parasitic infection of the central nervous system. Infection occurs through ingestion of parasitic eggs, allowing the parasite to travel through the bloodstream to distal sites. Worldwide prevalence is estimated to be between 3% and 6% [94]. Amongst those diagnosed with neurocysticercosis, only 1% and 6% of patients have spinal cord involvement, as leptomeningeal involvement is more common [95]. Neurocysticercosis lesions may be found in the VB, may occur as drop-lesions in the extramedullary spaces, or may present within the spinal cord itself [96]. Schistosomiasis is an infection from the genus *Schistosoma*, and affects over 230 million people worldwide [96]. It is most commonly reported in endemic areas throughout Africa, but is also found in Asia and South America.

Lesions affecting the spinal cord are typically caused by *Schistosoma mansoni* and *Schistosoma haematobium*. The lower spinal cord is usually affected, with early signs including low-back radicular pain, bladder dysfunction, and abnormalities in deep tendon reflexes [96]. It can present as acute myelopathy or conus medullaris syndrome [96]. Diagnosis is made through tissue biopsy via surgery [96]. Toxoplasmosis is one of the most common opportunistic infections in patients with AIDS and affects around 500 million people globally [96]. In a literature review by Garcia-Garcia et al. [97], 26 cases of spinal cord toxoplasmosis were reported, and although it is uncommon, it should be considered in immunocompromised patients presenting with myelopathy. Echinococcal disease caused by *Echinococcus granulosus* is acquired through ingestion of eggs in dog feces. It is most common in South America, Eastern Europe, Africa, and Western China [98]. The liver is typically affected in the form of hydatid cysts. Spinal cord involvement is rare and typically affects the thoracic spine [99]. Symptoms arise from compression and are nonspecific. Diagnosis can be made by visualizing cystic lesions on imaging.

Treatment

Nonoperative treatment

The goals of nonoperative treatment with antibiotics are to eliminate the infection, alleviate pain, maintain spinal stability, and prevent further neurological dysfunction. This approach boasts a success rate of approximately 90% and involves appropriate antibiotic therapy with a focus on stewardship practices, pain medication, bed rest, spinal brace immobilization, and physical therapy. During the initial period following a confirmed infection, bed rest is recommended to relieve pain and prevent further spinal deformity. This period should last for 1 to 2 weeks or until pain subsides, followed by ambulation with a spinal brace and support from physical therapy. Depending on the level of infection, immobilization of the spine should be sustained with a neck collar or halo-vest for cervical spine infections, an extension brace for thoracic spine infections, and a lower thoracolumbar or lumbosacral brace for thoracolumbar or lumbar spine infections. Empirical treatment typically involves dual administration of a third-generation cephalosporin or fluoroquinolone plus clindamycin or vancomycin, with another beta-lactam sometimes replacing commonly used fluoroquinolones like ciprofloxacin.

Based on culture results, definitive therapy will be determined according to the identified pathogen. Surgical treatment is recommended in cases of failed non-operative treatment or worsening of the patient's condition after 6 weeks of conservative treatment. In serious infections, discontinuation of antibiotic therapy is recommended for patients with imaging evidence of progressive destruction of the spinal column or

with progressive neurological deficits. Atypical pathogens require a specific treatment course and cannot be treated with standard empiric or definitive therapy [100]. Fungal spinal infections, such as *Candida* or *Aspergillus*, should be treated with appropriate antifungals, with Amphotericin B being a first-line agent [101]. Azoles are alternative treatments for patients infected with resistant strains of blastomycosis or when amphotericin nephrotoxicity poses a significant effect on patient wellness (refer to Table 1).

Surgical management

The management of spinal lesions through surgical intervention is a complex process that involves several factors. The location, size, and type of the lesion are crucial in determining the appropriate surgical approach, ranging from minimally invasive techniques to more invasive surgical interventions. Achieving an accurate diagnosis and creating a comprehensive surgical plan is critical for achieving favorable outcomes and mitigating potential complications. There are 3 fundamental principles in managing spinal infections through surgical intervention: thorough debridement of infected tissue, maintenance of adequate blood flow to facilitate tissue healing, and preservation or restoration of spinal stability in instances where it has been compromised [102]. Nevertheless, the recommendations regarding the surgical strategy itself are still controversial [103,104]. Any standard approach, including anterior, posterior, combined, or minimally invasive approaches, can be utilized. The choice of approach is mainly dependent on factors such as the presence of neurological deficits, the location of the infection, and the degree of associated bone destruction and instability [70].

The primary objectives of surgery for spinal infection are to remove the infectious focus, identify the causative microorganism, stabilize the affected spinal segment, and promote bone fusion. Additionally, surgery allows for quick postoperative mobilization and more reliable treatment of pseudarthrosis and kyphotic deformity. In cases where an epidural abscess is present in the cervical or thoracic spine, surgery is strongly recommended, even in the absence of neurological impairment, due to concern for rapid progression of potential neurologic deficits. Lumbar spine epidural abscess may be managed non-operatively, depending on the patient's comorbid conditions, symptoms, extent of infection, and overall clinical status. Urgent surgical intervention is required in instances of spinal cord compression and neurologic impairment, as delay in treatment beyond 24 to 36 hours from onset of neurological deficit may lead to worse outcomes and permanent neurologic compromise [105–108].

When managing liquid space-occupying lesions, such as dorsally accessible abscesses, it is feasible to use minimally invasive drainage techniques utilizing laminotomy and irrigation. This approach provides access to the lesion with minimal disruption to surrounding tissues, effectively mitigating the risk of potential complications. In contrast, solid space-occupying lesions such as granulation tissue may necessitate more extensive surgical intervention. For dorsally located granulation tissue, multisegmental decompression and/or resection is typically recommended, which involves partial removal of the vertebral bone to access and excise the lesion. Ventrally located granulation tissue associated with spondylodiscitis, on the other hand, may require corpectomy, reconstruction, and instrumentation.

This surgical procedure entails the excision of the VB and adjacent discs, followed by reconstruction using bone grafts and instrumentation to stabilize the spine [38]. *Epidural abscess/Empyema*: Surgical drainage has historically been recognized as a pillar in the management of spinal epidural abscesses, especially for patients with neurological deficits [106]. In recent years, non-surgical management has gained popularity, particularly in patients with comorbidities [109,110]. The timing in which abscess evacuation should be performed is unclear. Studies have shown that early evacuation of epidural abscesses (within 24 hours) improves discharge neurological grade [111]. *Subdural empyema*: Subdural empyemas are medical emergencies that require urgent surgery and

Table 1
Atypical pathogenic infections.

Type	Micro-organism	Antibiotic choice	Duration of therapy	Clinical characteristics
Bacterial Infections	Anaerobic micro-organisms	Gram-positive (eg, Cutibacterium, Peptostreptococcus, Finegoldia magna) Penicillin G or Ceftriaxone Followed by Rifampin and Levofloxacin or Amoxicillin Gram-negative (eg, Bacteroides) Ampicillin/sulbactam Followed by Metronidazole	Gram-positive (eg, Cutibacterium, Peptostreptococcus, Finegoldia magna) 2-3 wk FOLLOWED BY 4-10 wk Gram-negative (eg, Bacteroides) 2 wk FOLLOWED BY 4-10 wk [125]	Caused by less than 4% of spine infections
	<i>Pseudomonas aeruginosa</i>	Piperacillin/tazobactam or Meropenem Followed by Ciprofloxacin	2-3 wk Followed by 4-10 wk	Increased risk in patients who use intravenous drugs
	<i>Staphylococcus epidermidis</i>	Methicillin-susceptible Nafcillin or Oxacillin [126] Methicillin-resistant Intravenous vancomycin or linezolid	Methicillin-susceptible 2 wk OR Up to 6 wk if there are complications such as osteomyelitis. Methicillin-Resistant 2 wk OR 4+ weeks if complicated [127]	Increased risk in patients with prosthetic joint replacements
	<i>Salmonellosis</i>	Susceptible ampicillin, chloramphenicol, and trimethoprim-sulfamethoxazole [128] Multi-drug resistance Quinolones and third generation cephalosporins [129]	Susceptible 3-7 d Multi-Drug Resistance 5-7 d [130]	Seen in children with sickle cell disease
	<i>Brucella</i>	Doxycycline and streptomycin (or gentamicin)	Debatable some say 4-6 wk others says up to 12 wk [6]	Atypical etiology; often found in infected farm animals; involved in 2-54% of spine infections
	<i>Cutibacterium acnes</i>	Beta-lactams, quinolones and rifampicin [131]	2+ weeks	Anaerobic, non-spore forming, Gram-positive rod; involved in 2%-18% of bone infections
	<i>Kingella kingae</i>	Beta-lactams, macrolides, and tetracyclines	2-3 wk 3-12 wk with complications such as spondylodiscitis [132]	Implicated in spondylodiscitis in children; common in those between 4 mo and 48 mo
Fungal Infections	Opportunistic fungi			Rare and typically seen in immunocompromised patients
	<i>Aspergillus</i> and <i>Candida</i> species	<i>Aspergillus</i> Voriconazole <i>Candida</i> spp. Fluconazole-susceptible Caspofungin or Anidulafungin Followed by Fluconazole Fluconazole-resistant Voriconazole OR Consider implant removal or long-term suppression.	<i>Aspergillus</i> >3 mo ¹³³ <i>Candida</i> spp. Fluconazole-susceptible 2 wk Followed by 4-10 wk Fluconazole-resistant 4-10 wk [125]	Most common fungal organisms
	Other less frequent organisms	Coccidioides Fluconazole Blastomycosis Amphotericin B Cryptococcus Amphotericin B and flucytosine FOLLOWED BY Fluconazole Histoplasma capsulatum Amphotericin B Pseudallescheria boydii Surgical resection Zygomycosis Amphotericin B ¹³⁴	Coccidioides 6-12 mo ¹³⁵ Blastomycosis >2 wk Cryptococcus 2 wk FOLLOWED BY 10 wk ¹³⁵ Histoplasma capsulatum >2 wk Pseudallescheria boydii Surgical Resection Zygomycosis >2 wk ¹³⁶	Coccidioides, Blastomycosis, Cryptococcus, Histoplasma capsulatum, Pseudallescheria boydii, Zygomycosis

(continued on next page)

Table 1 (continued)

Type	Micro-organism	Antibiotic choice	Duration of therapy	Clinical characteristics
Parasitic Infections	Protozoa and helminths			Uncommon and typically seen in patients with a history of travel to endemic areas or compromised immune systems
	Taenia solium (Cysticercosis)	Praziquantel OR Albendazole	15 d OR 7-15 d ¹³⁷	Most common parasitic infection of the central nervous system; 1%-6% of patients have spinal cord involvement
	Schistosoma	Praziquantel	4-6 wk ¹³⁸	Affects over 230 million people worldwide; affects lower spinal cord; may present as acute myelopathy
	Toxoplasmosis	Pyrimethamine, sulfadiazine, and folinic acid	6 wk ¹³⁹	Common opportunistic infection in patients with AIDS; can affect the spinal cord
	Echinococcosis granulosis	Albendazole	3-6 mo ¹⁴⁰	Rare involvement of the spinal cord; affects the thoracic spine; symptoms arise from compression

Table 2

Comparison of spinal fusion techniques and outcomes.

Procedure/technique	Outcome(s)
Tricortical iliac autograft [116–118] Structural bone allograft [119]	Safe procedure with excellent and consistent outcomes Alternative to tricortical iliac autograft, reduces operative time and avoids donor site morbidity Improved fusion rates
Structural bone graft + recombinant human bone morphogenetic protein-2 (rhBMP-2) [120–122] Metallic implants [119]. ¹⁴¹⁻¹⁴⁶	Improved fusion rates
Anterior interbody fusion using titanium mesh cage (for tuberculous spondylitis) [123]	Safe to use in spinal infections Solid fusion, maintenance of kyphosis correction, no recurrence of tuberculosis infection
Anterior column reconstruction using expandable titanium cage filled with morselized autologous bone graft (for pyogenic spondylodiscitis) [124]	100% fusion rate, infection eradication

antibiotic therapy since treatment timing has been proven to be directly tied to patient outcomes. [112] The surgical technique used will vary according to the size of the lesion. Laminectomy at one or more levels may be necessary, and larger laminectomies at several levels may be required [113]. *Intradural abscess*: Abscesses in this location are a rare yet serious medical condition. Management of this condition involves prompt diagnosis and aggressive treatment. Administration of IV antibiotics and early (preferably within 5 days of symptom onset) drainage are necessary to prevent further neurological deficit [114,115].

To summarize, the recommended approach for managing spinal infections depends on the location of the infection in the spine. In the cervical spine, an anterior approach with appropriate debridement, decompression, and fusion with bone graft and anterior plate stabilization, along with posterior instrumentation for multilevel intervention, is typically recommended [116]. For epidural involvement without severe destruction of the VB, a posterior approach may be acceptable [117]. Depending on patient's clinical status, a staged operation is reasonable, with initial operative goal to remove infection nidus and decompress the neural elements, with further surgical intervention delayed by days for permanent stabilization.

In the thoracic spine, a posterior approach is recommended for epidural involvement without anterior disc or bony destruction, whereas an anterior approach is reserved for mono-segmental lesions without involvement of posterior elements. For extensive anterior bone destruction and collapse with segmental kyphosis at the thoracolumbar juncture, it is recommended to perform an anterior debridement and interbody fusion in conjunction with posterior instrumentation [118].

Patients treated with a 1-stage posterior approach generally showed good clinical outcomes, including good infection control, back pain relief, kyphotic angle correction, and either partial or solid union for fusion status. They also had shorter surgical times, fewer postoperative complications, and shorter hospital stays than patients who underwent anterior debridement with posterior instrumentation. Thus, single-stage

posterior approaches are recommended for thoracic spine infections, especially for patients with medical comorbidities. Although anterior approaches allow direct exposure for disc space debridement and ventral column reconstruction, they have many drawbacks, including the possibility of vascular injury, the difficulty of dura repair, and a relatively high risk of intercostal muscle atrophy, pneumothorax, pneumonia, pleural effusion, chylothorax, and prolonged hospital stays, especially in the setting of thoracotomies for access to midthoracic spine [119,120]. In cases where 2-stage procedures are necessary, initial antibiotic treatment is followed by a second-stage posterior instrumentation and fusion procedure with internal fixation [102]. For monosegmental spondylodiscitis with moderate anterior bone involvement and minimal kyphosis deformity, a posterior lumbar interbody fusion is recommended.

Minimally invasive spine surgery (MISS) has had a significant impact on the management of spinal infections, offering a range of promising benefits for patients. In certain medical centers, the thoracoscopic approach has proven to be an effective method for treating spinal infections located in the thoracic segment. In patients with single-level thoracolumbar pyogenic spondylodiscitis and high functional demands, percutaneous screw rod instrumentation has been described as an alternative to bracing [121,122], or as a standard procedure after anterior debridement [70]. Additionally, percutaneous drainage of paravertebral and intradiscal abscesses has been reported as an alternative to surgery [123].

Fusion with instrumentation after infection

There are various surgical procedures available for treating spinal infections, each tailored to the specific needs of the patient. Patients with pyogenic discitis and vertebral osteomyelitis may be treated with a single-stage debridement, arthrodesis, and internal fixation, using both

anterior and posterior approaches. Autologous grafts are preferred for arthrodesis, but allografts may also be used [102].

The use of bone grafting in spinal surgeries has evolved over time, with different techniques and materials being developed to improve outcomes. Tricortical iliac autograft, a classical bone grafting technique, is recognized as a safe procedure with consistent and excellent outcomes, and is the gold standard to optimize bony fusion [124–126]. An alternative to this technique is the use of structural bone allograft, which reduces operative time and avoids donor site morbidity [127]. Recent publications have shown that combining structural bone graft with recombinant human bone morphogenetic protein-2 (rhBMP-2) can improve fusion rates [128–130] rhBMP-2 has the potential risk profile of seroma accumulation, radiculitis and wanted cell growth, therefore patients with history of cancer, CSF leaks, or undergoing cervical or thoracic spine operations, should be specially counseled on the risks of using this product.

Metallic implants, which were previously a concern due to the potential risk of introducing hardware into an infected area, have been demonstrated to be safe for use in spinal infections. Several studies have reported positive outcomes with the use of metallic implants, including titanium mesh cage for anterior interbody fusion in tuberculous spondylitis [131] and expandable titanium cage filled with morselized autologous bone graft for anterior column reconstruction in pyogenic spondylodiscitis, resulting in solid fusion, maintenance of kyphosis correction, and infection eradication [132]. (Refer to Table 2.)

Conclusions

ASIs pose a significant health threat, resulting in both morbidity and mortality. The clinical presentation of these infections can be subtle, and initial radiographs may not fully depict the extent of the problem, leading to false reassurance. Effective treatment protocols require the involvement of a multidisciplinary team of physicians, including infectious disease specialists, neuroradiologists, and spine surgeons. Early diagnosis is crucial, and a high level of clinical suspicion is essential. These measures are vital for improving long-term outcomes and preventing permanent neurological impairments. Microbiological and histological diagnoses play a pivotal role in determining the most appropriate treatment plan. Surgery is strongly recommended for patients who present with neurological deficits or sepsis, spinal instability and/or deformity, epidural abscesses, and cases where conservative treatment has proven ineffective.

Declaration of Competing Interest

None.

Funding

None.

References

- [1] Petitjean G, Fluckiger U, Schären S, Laifer G. Vertebral osteomyelitis caused by non-tuberculous mycobacteria. Elsevier; 2004. p. 951–3.
- [2] Astagneau P, Desplaces N, Vincent V, et al. Mycobacterium xenopi spinal infections after discovertebral surgery: investigation and screening of a large outbreak. *Lancet* 2001;358(9283):747–51. doi:10.1016/s0140-6736(01)05843-3.
- [3] Wagner D, Young LS. Nontuberculous mycobacterial infections: a clinical review. *Infection* 2004;32(5):257–70. doi:10.1007/s15010-004-4001-4.
- [4] Govender S. Spinal infections. *J Bone Joint Surg Br Vol* 2005;87(11):1454–8.
- [5] Sharma SK, Upadhyay V. Epidemiology, diagnosis & treatment of non-tuberculous mycobacterial diseases. *Indian J Med Res* 2020;152(3):185.
- [6] Arend SM, Janssen R, Gosen JJ, et al. Multifocal osteomyelitis caused by nontuberculous mycobacteria in patients with a genetic defect of the interferon-gamma receptor. *Neth J Med* 2001;59(3):140–51. doi:10.1016/s0300-2977(01)00152-8.
- [7] Kim C-J, Kim U-J, Kim HB, et al. Vertebral osteomyelitis caused by non-tuberculous mycobacteria: predisposing conditions and clinical characteristics of six cases and a review of 63 cases in the literature. *Infect Dis* 2016;48(7):509–16.

- [8] Bryant JM, Grogono DM, Rodriguez-Rincon D, et al. Emergence and spread of a human-transmissible multidrug-resistant nontuberculous mycobacterium. *Science* 2016;354(6313):751–7.
- [9] Chan ED, Kong PM, Fennelly K, Dwyer AP, Iseman MD. Vertebral osteomyelitis due to infection with nontuberculous mycobacterium species after blunt trauma to the back: 3 examples of the principle of locus minoris resistentiae. *Clin Infect Dis* 2001;32(10):1506–10. doi:10.1086/320155.
- [10] Zosso C, Lienhard R, Siegrist HH, Malinverni R, Clerc O. Post liposuction infections by rapidly growing mycobacteria. *Infect Dis (Lond)* 2015;47(2):69–72. doi:10.3109/00365548.2014.968865.
- [11] Lemaignen A, Ghout I, Dinh A, et al. Characteristics of and risk factors for severe neurological deficit in patients with pyogenic vertebral osteomyelitis: a case-control study. *Medicine (Baltimore)* 2017;96:e6387.
- [12] Saleh ES, Vasileff CC, Omari AM, Khalil JG, Omari A, Khalil J. The diagnosis and management of pediatric spine infections. *Cureus* 2021;13(7).
- [13] Tay BK, Deckey J, Hu SS. Spinal infections. *JAAOS-J Am Acad Orthop Surg* 2002;10(3):188–97.
- [14] Tsantes AG, Papadopoulos DV, Vrioni G, et al. Spinal infections: an update. *Microorganisms* 2020;8(4):476.
- [15] Basheer A, Macki M, Buraimoh M, Mahmood A. Chronic thoracolumbar subdural empyema: case report and surgical management. *Surg Neurol Int* 2017;8.
- [16] Greenlee JE. Subdural empyema. *Curr Treatment Options Neurol* 2003;5(1):13–22.
- [17] Stephens DS, Greenwood B, Brandtzaeg P. Epidemic meningitis, meningococcaemia, and neisseria meningitidis. *Lancet* 2007;369(9580):2196–210.
- [18] Cornett CA, Vincent SA, Crow J, Hewlett A. Bacterial spine infections in adults: evaluation and management. *JAAOS-J Am Acad Orthop Surg* 2016;24(1):11–18.
- [19] Gofur EM, Singh P. Anatomy, back, vertebral canal blood supply. StatPearls [Internet] 2021. <https://www.ncbi.nlm.nih.gov/books/NBK541083/>.
- [20] Batson O. The vertebral system of veins as a means for cancer dissemination. *Progress in clinical cancer* 1967;3:1–18.
- [21] Luo W, Yin Y, Liu W, Ren H. Intramedullary spinal cord abscess with brain abscess due to subacute infective endocarditis. *BMC neurology* 2023;23(1):18.
- [22] Tsiodras S, Falagas ME. Clinical assessment and medical treatment of spine infections. *Clin Orthop Relat Res* 2006;444:38–50.
- [23] Parchi PD, Evangelisti G, Andreani L, et al. Postoperative spine infections. *Orthop Rev* 2015;7(3):63–7.
- [24] Balcescu C, Odeh K, Rosinski A, et al. High prevalence of multifocal spine infections involving the cervical and thoracic regions: a case for imaging the entire spine. *Neurospine* 2019;16(4):756.
- [25] Megaloikonon PD, Antoniadou T, Dimopoulos L, et al. Spondylitis transmitted from infected aortic grafts: a review. *J Bone Joint Infect* 2017;2(2):96–103.
- [26] Bernard L, Dinh A, Ghout I, et al. Antibiotic treatment for 6 weeks versus 12 weeks in patients with pyogenic vertebral osteomyelitis: an open-label, non-inferiority, randomised, controlled trial. *Lancet* 2015;385(9971):875–82.
- [27] Santagada D, Perna A, Tullo G, et al. Could serum procalcitonin play a role in an emergency setting for patients with pyogenic spondylodiscitis? *Eur Rev Med Pharmacol Sci* 2022;26(1 Suppl):66–77.
- [28] Priest D, Peacock jr J. studies on haematogenous vertebral osteomyelitis due to *Staphylococcus aureus* in adults. *South Med J* 2006;9:853.
- [29] Zimmerli W. Clinical practice. Vertebral osteomyelitis. *N Engl J Med* 2010;362(11):1022–9. doi:10.1056/NEJMcip0910753.
- [30] Berbari EF, Kanj SS, Kowalski TJ, et al. 2015 Infectious Diseases Society of America (IDSA) Clinical Practice Guidelines for the diagnosis and treatment of native vertebral osteomyelitis in adults. *Clin Infect Dis* 2015;61(6):e26–46. doi:10.1093/cid/civ482.
- [31] Lacasse M, Derolez S, Bonnet E, et al. 2022 SPILF - Clinical practice guidelines for the diagnosis and treatment of disco-vertebral infection in adults. *Infect Dis Now* 2023;53(3):104647. doi:10.1016/j.idnow.2023.01.007.
- [32] Mathkour M, Chu J, Scullen T, et al. Atlantoaxial instability secondary to Bartonella henselae osteomyelitis managed surgically by atlantoaxial instrumentation: a case report and systematic review. *J Craniovertebr Junction Spine* 2022;13(3):224–32. doi:10.4103/jcvjs.jcvjs_206_20.
- [33] Rafferty JR, Janopaul-Naylor E, Riese J. Torticollis and fever in a young boy: a unique presentation of cat-scratch disease with vertebral osteomyelitis and epidural phlegmon. *Pediatr Emerg Care* 2017;33(12):e164–6. doi:10.1097/pec.0000000000001330.
- [34] Loibl M, Stoyanov L, Doenitz C, et al. Outcome-related co-factors in 105 cases of vertebral osteomyelitis in a tertiary care hospital. *Infection* 2014;42(3):503–10. doi:10.1007/s15010-013-0582-0.
- [35] Zhu X, Li K, Zheng J, et al. Usage of procalcitonin and sCD14-ST as diagnostic markers for postoperative spinal infection. *J Orthop Traumatol* 2022;23(1):25. doi:10.1186/s10195-022-00644-9.
- [36] An HS, Seldomridge JA. Spinal infections: diagnostic tests and imaging studies. *Clin Orthop Relat Res* 2006;444:27–33. doi:10.1097/01.blo.0000203452.36522.97.
- [37] Saeed K, Esposito S, Ascione T, et al. Hot topics on vertebral osteomyelitis from the International Society of Antimicrobial Chemotherapy. *Int J Antimicrob Agents* 2019;54(2):125–33. doi:10.1016/j.ijantimicag.2019.06.013.
- [38] Lener S, Hartmann S, Barbagallo GMV, Certo F, Thomé C, Tschugg A. Management of spinal infection: a review of the literature. *Acta Neurochir (Wien)* 2018;160(3):487–96. doi:10.1007/s00701-018-3467-2.
- [39] Love C, Palestro CJ. Nuclear medicine imaging of bone infections. *Clin Radiol* 2016;71(7):632–46. doi:10.1016/j.crad.2016.01.003.
- [40] Stumpe KD, Zanetti M, Weishaupt D, Hodler J, Boos N, Von Schulthess GK. FDG positron emission tomography for differentiation of degenerative and infectious

- endplate abnormalities in the lumbar spine detected on MR imaging. *AJR Am J Roentgenol* 2002;179(5):1151–7. doi:10.2214/ajr.179.5.1791151.
- [41] Tacy C, Patel V, Perez J. An isolated radiographic finding of spontaneous vertebral osteomyelitis. *Cureus* 2022;14(5):e24646. doi:10.7759/cureus.24646.
- [42] Gras G, Buzele R, Parienti JJ, et al. Microbiological diagnosis of vertebral osteomyelitis: relevance of second percutaneous biopsy following initial negative biopsy and limited yield of post-biopsy blood cultures. *Eur J Clin Microbiol Infect Dis* 2014;33(3):371–5. doi:10.1007/s10096-013-1965-y.
- [43] Terreaux W, Geoffroy M, Ohl X, et al. Diagnostic contribution of a second percutaneous needle biopsy in patients with spontaneous diskitis and negative blood cultures and first biopsy. *Joint Bone Spine* 2016;83(6):715–19. doi:10.1016/j.jbspin.2016.02.006.
- [44] Chew FS, Kline MJ. Diagnostic yield of CT-guided percutaneous aspiration procedures in suspected spontaneous infectious diskitis. *Radiology* 2001;218(1):211–14. doi:10.1148/radiology.218.1.r01ja06211.
- [45] Heyer CM, Brus LJ, Peters SA, Lemburg SP. Efficacy of CT-guided biopsies of the spine in patients with spondylitis—an analysis of 164 procedures. *Eur J Radiol* 2012;81(3):e244–9. doi:10.1016/j.ejrad.2011.02.007.
- [46] Kim CJ, Kang SJ, Choe PG, et al. Which tissues are best for microbiological diagnosis in patients with pyogenic vertebral osteomyelitis undergoing needle biopsy? *Clin Microbiol Infect* 2015;21(10):931–5. doi:10.1016/j.cmi.2015.06.021.
- [47] Chang CY, Simeone FJ, Nelson SB, Taneja AK, Huang AJ. Is biopsying the paravertebral soft tissue as effective as biopsying the disk or vertebral endplate? 10-year retrospective review of CT-guided biopsy of diskitis-osteomyelitis. *AJR Am J Roentgenol* 2015;205(1):123–9. doi:10.2214/ajr.14.13545.
- [48] Choi SH, Sung H, Kim SH, et al. Usefulness of a direct 16S rRNA gene PCR assay of percutaneous biopsies or aspirates for etiological diagnosis of vertebral osteomyelitis. *Diagn Microbiol Infect Dis* 2014;78(1):75–8. doi:10.1016/j.diagmicrobio.2013.10.007.
- [49] Jacquier H, Fihman V, Amarsy R, et al. Benefits of polymerase chain reaction combined with culture for the diagnosis of bone and joint infections: A prospective test performance study. *Open Forum Infect Dis* 2019;6(12):ofz511. doi:10.1093/ofid/ofz511.
- [50] Itoh N, Akazawa N, Tanaka T. A mixed infection involving *Bacteroides denticanum*, *Lactobacillus salivarius*, and *Streptococcus anginosus* as causative agents of abscess around a pharyngo-esophageal anastomosis and acute vertebral osteomyelitis: identification by ribosomal RNA sequencing of bacterial isolates. *J Infect Chemother* 2023;29(8):816–19. doi:10.1016/j.jiac.2023.04.017.
- [51] Purushothaman S, Meola M, Egli A. Combination of whole genome sequencing and metagenomics for microbiological diagnostics. *Int J Mol Sci* 2022;23(17). doi:10.3390/ijms23179834.
- [52] Zhu Y, Xu M, Ding C, et al. Metagenomic next-generation sequencing vs. Traditional microbiological tests for diagnosing varicella-Zoster virus Central nervous system infection. *Front Public Health* 2021;9:738412. doi:10.3389/fpubh.2021.738412.
- [53] Peng M, Li W, Li F, et al. Mycobacterium xenopi related spine infections: a case report and systematic literature review. *One health* 2023;16:100502. doi:10.1016/j.onehlt.2023.100502.
- [54] de Nettancourt A, Derdevet J, Dahmane L, et al. [A vertebral polymicrobial osteomyelitis with atypical microorganisms: a case report]. *Rev Med Interne* 2023;44(4):190–4 Spondylodiscite, une bactérie peut en cacher une autre. Actualisation de la stratégie diagnostique et de suivi. doi:10.1016/j.revmed.2023.01.009.
- [55] Smimmo A, Perna A, Fantoni M, et al. Non tuberculous mycobacteria related spondylodiscitis: a case report and systematic literature review. *Infez Med* 2020;28(3):425–35.
- [56] Duarte RM, Vaccaro AR. Spinal infection: state of the art and management algorithm. *Eur Spine J* 2013;22:2787–99.
- [57] Mylona E, Samarkos M, Kakalou E, Fanourgaki P, Skoutelis A. Seminars in arthritis and rheumatism. *Semin Arthritis Rheum* 2009;39(1):10–17.
- [58] An HS, Vaccaro AR, Dolinskas CA, Cotler JM, Balderston RA, Bauerle WB. Differentiation between spinal tumors and infections with magnetic resonance imaging. *Spine (Phila Pa 1976)* 1991;16(8 Suppl):S334–8.
- [59] Mellado JM, Pérez del Palomar L, Camins A, Salvadó E, Ramos A, Saurí A. MR imaging of spinal infection: atypical features, interpretive pitfalls and potential mimickers. *Eur Radiol* 2004;14(11):1980–9. doi:10.1007/s00330-004-2310-8.
- [60] Dagirmanjian A, Schils J, McHenry MC. MR imaging of spinal infections. *Magn Reson Imaging Clin N Am* 1999;7(3):525–38.
- [61] Stähler A, Reiser MF. Imaging of spinal infection. *Radiol Clin North Am* 2001;39(1):115–35. doi:10.1016/s0033-8389(05)70266-9.
- [62] Varma R, Lander P, Assaf A. Imaging of pyogenic infectious spondylodiskitis. *Radiol Clin North Am* 2001;39(2):203–13. doi:10.1016/s0033-8389(05)70273-6.
- [63] Francis IM, Das DK, Luthra UK, Sheikh Z, Sheikh M, Bashir M. Value of radiologically guided fine needle aspiration cytology (FNAC) in the diagnosis of spinal tuberculosis: a study of 29 cases. *Cytopathology* 1999;10(6):390–401. doi:10.1046/j.1365-2303.1999.00206.x.
- [64] Wirtz DC, Genius I, Wildberger JE, Adam G, Zilkens KW, Niehard FU. Diagnostic and therapeutic management of lumbar and thoracic spondylodiscitis—an evaluation of 59 cases. *Arch Orthop Trauma Surg* 2000;120(5-6):245–51. doi:10.1007/s004020050457.
- [65] Currie S, Galea-Soler S, Barron D, Chandramohan M, Groves C. MRI characteristics of tuberculous spondylitis. *Clin Radiol* 2011;66(8):778–87. doi:10.1016/j.crad.2011.02.016.
- [66] James SL, Davies AM. Imaging of infectious spinal disorders in children and adults. *Eur J Radiol* 2006;58(1):27–40. doi:10.1016/j.ejrad.2005.12.002.
- [67] Turunc T, Demiroglu YZ, Uncu H, Colakoglu S, Arslan H. A comparative analysis of tuberculous, brucellar and pyogenic spontaneous spondylodiscitis patients. *J Infect* 2007;55(2):158–63. doi:10.1016/j.jinf.2007.04.002.
- [68] Diehn FE. Imaging of spine infection. *Radiol Clin North Am* 2012;50(4):777–98. doi:10.1016/j.rcl.2012.04.001.
- [69] Jung NY, Jee WH, Ha KY, Park CK, Byun JY. Discrimination of tuberculous spondylitis from pyogenic spondylitis on MRI. *AJR Am J Roentgenol* 2004;182(6):1405–10. doi:10.2214/ajr.182.6.1821405.
- [70] Duarte RM, Vaccaro AR. Spinal infection: state of the art and management algorithm. *Eur Spine J* 2013;22(12):2787–99. doi:10.1007/s00586-013-2850-1.
- [71] Lund P, Chan K, Unger E, Gagliani T, Pitt M. Magnetic resonance imaging in coccioidal arthritis. *Skeletal radiology* 1996;25:661–5.
- [72] Legrand E, Flipo R, Guggenbuhl P, et al. Management of nontuberculous infectious discitis. Treatments used in 110 patients admitted to 12 teaching hospitals in France. *Joint Bone Spine* 2001;68(6):504–9.
- [73] Cebrían Parra JL, Saez-Arenillas Martín A, Urda Martínez-Aedo AL, Soler Ivañez I, Agreda E, Lopez-Duran Stern L. Management of infectious discitis. Outcome in one hundred and eight patients in a university hospital. *Int Orthop* 2012;36:239–44.
- [74] Piersimoni C, Scarparo C. Extrapulmonary infections associated with nontuberculous mycobacteria in immunocompetent persons. *Emerging Infect Dis* 2009;15(9):1351.
- [75] Shinnick TM, Good RC. Mycobacterial taxonomy. *Eur J Clin Microbiol Infect Dis* 1994;13(11):884–901. doi:10.1007/bf02111489.
- [76] Koh W-J. Nontuberculous mycobacteria—overview. *Microbiol Spectrum* 2017;5(1):349–66 tnm17-0024-2016. doi:10.1128/microbiolspec.
- [77] Lapinel N, Jolley S, Ali J, Welsh D. Prevalence of non-tuberculous mycobacteria in HIV-infected patients admitted to hospital with pneumonia. *Int J Tuberculosis Lung Dis* 2019;23(4):491–7.
- [78] D'agostino C, Scorzolini L, Massetti A, et al. A seven-year prospective study on spondylodiscitis: epidemiological and microbiological features. *Infection* 2010;38:102–7.
- [79] Broner FA, Garland DE, Zigler JE. Spinal infections in the immunocompromised host. *Orthop Clin N Am* 1996;27(1):37–46.
- [80] Reşorlu H, Saçar S, Inceer BŞ, et al. Cervical spondylitis and epidural abscess caused by *brucellosis*: a case report and literature review. *Folia Med (Plovdiv)* 2016;58(4):289–92.
- [81] Chelli Bouaziz M, Ladeb MF, Chakroun M, Chaabane S. Spinal brucellosis: a review. *Skeletal Radiol* 2008;37(9):785–90.
- [82] Esmailnejad-Ganji SM, SMR Esmailnejad-Ganji. Osteoarticular manifestations of human brucellosis: a review. *World J Orthop* 2019;10(2):54.
- [83] Smailnejad Gangi SM, Hasanjani Roushan MR, Janmohammadi N, Mehraeen R, Soleimani Amiri MJ, Khalilian E. Outcomes of treatment in 50 cases with spinal brucellosis in Babol, Northern Iran. *J Infect Develop Countries* 2012;6(9):654–9.
- [84] Lim K-B, Kwak Y-G, Kim D-Y, Kim Y-S, Kim J-A. Back pain secondary to *Brucella spondylitis* in the lumbar region. *Ann Rehabil Med* 2012;36(2):282–6.
- [85] Jahns AC, Lundskog B, Ganceviciene R, et al. An increased incidence of *Propionibacterium acnes* biofilms in acne vulgaris: a case-control study. *Br J Dermatol* 2013;167(1):50–8.
- [86] Khaiil JG, Gandhi SD, Park DK, Fischgrund JS. Cutibacterium acnes in spine pathology: pathophysiology, diagnosis, and management. *JAAOS-J Am Acad Orthop Surg* 2019;27(14):e633–40.
- [87] Hadjipavlou AG, Mader JT, Necessary JT, Muffoletto AJ. Hematogenous pyogenic spinal infections and their surgical management. *Spine* 2000;25(13):1668–79.
- [88] Ceroni D, Cherkaoui A, Kaelin A, Schrenzel J. *Kingella kingae* spondylodiscitis in young children: toward a new approach for bacteriological investigations? A preliminary report. *J Children's Orthop* 2010;4:173–5.
- [89] Yagupsky P. *Kingella kingae*: carriage, transmission, and disease. *Clin Microbiol Rev* 2015;28(1):54–79.
- [90] Basmaci R, Bonacorsi S. *Kingella kingae*: from carriage to infection. *CMAJ* 2017;189(35):E1105–6.
- [91] Samara E, Lutz N, Zambelli P-Y. *Kingella kingae* spinal infections in children. *Children* 2022;9(5):705.
- [92] Frazier DD, Campbell DR, Garvey TA, Wiesel S, Bohlman HH, Eismont FJ. Fungal infections of the spine: report of eleven patients with long-term follow-up. *JBSJ* 2001;83(4):560.
- [93] Ganesh D, Gottlieb J, Chan S, Martinez O, Eismont F. Fungal infections of the spine. *Spine* 2015;40(12):E719–28.
- [94] do Amaral LLF, Nunes RH, da Rocha AJ. Parasitic and rare spinal infections. *Neuroimaging Clinics* 2015;25(2):259–79.
- [95] Torabi AM, Quiceno M, Mendelsohn DB, Powell CM. Multilevel intramedullary spinal neurocysticercosis with eosinophilic meningitis. *Arch Neurol* 2004;61(5):770–2.
- [96] Majmundar N, Patel PD, Dodson V, Tran A, Goldstein I, Assina R. Parasitic infections of the spine: case series and review of the literature. *Neurosurg Focus* 2019;46(1):E12. doi:10.3171/2018.10.Focus18472.
- [97] García-García C, Castillo-Álvarez F, Azcona-Gutiérrez JM, Herráiz MJ, Ibarra V, Oteo JA. Spinal cord toxoplasmosis in human immunodeficiency virus infection/acquired immunodeficiency syndrome. *Infect Dis (Lond)* 2015;47(5):277–82. doi:10.3109/00365548.2014.993421.
- [98] Jenkins DJ, Romig T, Thompson RC. Emergence/re-emergence of echinococcus spp—a global update. *Int J Parasitol* 2005;35(11-12):1205–19. doi:10.1016/j.ijpara.2005.07.014.
- [99] Neumayr A, Tamarozzi F, Goblirsch S, Blum J, Brunetti E. Spinal cystic echinococcosis—a systematic analysis and review of the literature: part 1. Epidemiology and anatomy. *PLoS Negl Trop Dis* 2013;7(9):e2450. doi:10.1371/journal.pntd.0002450.
- [100] Varatharajah S, Charles YP, Buy X, Walter A, Steib JP. Update on the surgical management of Pott's disease. *Orthop Traumatol Surg Res* 2014;100(2):229–35. doi:10.1016/j.otsr.2013.09.013.

- [101] Kim CW, Perry A, Currier B, Yaszemski M, Garfin SR. Fungal infections of the spine. *Clin Orthop Relat Res* 2006;444:92–9. doi:10.1097/01.blo.0000203451.36522.4c.
- [102] Quiñones-Hinojosa A, Jun P, Jacobs R, Rosenberg WS, Weinstein PR. General principles in the medical and surgical management of spinal infections: a multidisciplinary approach. *Neurosurg Focus* 2004;17(6):E1. doi:10.3171/foc.2004.17.6.1.
- [103] Frangen TM, Källicke T, Gottwald M, et al. [Surgical management of spondylodiscitis. An analysis of 78 cases]. *Unfallchirurg* 2006;109(9):743–53 Die operative Therapie der Spondylodiscitis. Eine Analyse von 78 Patienten. doi:10.1007/s00113-006-1084-7.
- [104] Schinkel C, Gottwald M, Andress HJ. Surgical treatment of spondylodiscitis. *Surg Infect (Larchmt)*. Winter 2003;4(4):387–91. doi:10.1089/109629603322761445.
- [105] Gouliouris T, Aliyu SH, Brown NM. Spondylodiscitis: update on diagnosis and management. *J Antimicrob Chemother* 2010;65(Suppl 3):11–24 iii11-24. doi:10.1093/jac/dkq303.
- [106] Darouiche RO. Spinal epidural abscess. *N Engl J Med* 2006;355(19):2012–20. doi:10.1056/NEJMra055111.
- [107] Hadjipavlou AG, Mader JT, Necessary JT, Muffoletto AJ. Hematogenous pyogenic spinal infections and their surgical management. *Spine (Phila Pa 1976)* 2000;25(13):1668–79. doi:10.1097/00007632-200007010-00010.
- [108] Karadimas EJ, Bungler C, Lindblad BE, et al. Spondylodiscitis. A retrospective study of 163 patients. *Acta Orthop* 2008;79(5):650–9. doi:10.1080/17453670810016678.
- [109] Schwab JH, Shah AA. Spinal epidural abscess: diagnosis, management, and outcomes. *J Am Acad Orthop Surg* 2020;28(21):e929–38. doi:10.5435/jaaos-d-19-00685.
- [110] Babic M, Simpfendorfer CS, Berbari EF. Update on spinal epidural abscess. *Curr Opin Infect Dis* 2019;32(3):265–71. doi:10.1097/qco.0000000000000544.
- [111] Ghobrial GM, Beygi S, Viereck MJ, et al. Timing in the surgical evacuation of spinal epidural abscesses. *Neurosurg Focus* 2014;37(2):E1. doi:10.3171/2014.6.FOCUS14120.
- [112] Schäfer F, Mattle HP. Neurologic manifestations of *Staphylococcus aureus* infections. Analysis of 43 patients. *Schweiz Arch Neurol Psychiatr* (1985) 1994;145(1):25–9.
- [113] Lange M, Tiecks F, Schielke E, Yousry T, Haberl R, Oeckler R. Diagnosis and results of different treatment regimens in patients with spinal abscesses. *Acta Neurochir (Wien)* 1993;125(1-4):105–14. doi:10.1007/bf01401836.
- [114] Iwasaki M, Yano S, Aoyama T, Hida K, Iwasaki Y. Acute onset intramedullary spinal cord abscess with spinal artery occlusion: a case report and review. *Eur Spine J* 2011;20(Suppl 2(Suppl 2)):S294–301. doi:10.1007/s00586-011-1703-z.
- [115] Simon JK, Lazareff JA, Diament MJ, Kennedy WA. Intramedullary abscess of the spinal cord in children: a case report and review of the literature. *Pediatr Infect Dis J* 2003;22(2):186–92. doi:10.1097/01.inf.0000048910.19136.49.
- [116] Pola E, Rossi B, Nasto LA, Colangelo D, Logroscino CA. Surgical treatment of tuberculous spondylodiscitis. *Eur Rev Med Pharmacol Sci* 2012;16(Suppl 2): 79–85.
- [117] Zarghooni K, Röllinghoff M, Sobottke R, Eysel P. Treatment of spondylodiscitis. *Int Orthop* 2012;36(2):405–11. doi:10.1007/s00264-011-1425-1.
- [118] Lee JS, Suh KT. Posterior lumbar interbody fusion with an autogenous iliac crest bone graft in the treatment of pyogenic spondylodiscitis. *J Bone Joint Surg Br* 2006;88(6):765–70. doi:10.1302/0301-620x.88b6.17270.
- [119] Pettiford BL, Schuchert MJ, Jeyabalan G, et al. Technical challenges and utility of anterior exposure for thoracic spine pathology. *Ann Thorac Surg* 2008;86(6):1762–8. doi:10.1016/j.athoracsur.2008.07.087.
- [120] Xu R, Garcés-Ambrossi GL, McGirt MJ, et al. Thoracic vertebrectomy and spinal reconstruction via anterior, posterior, or combined approaches: clinical outcomes in 91 consecutive patients with metastatic spinal tumors. *J Neurosurg Spine* 2009;11(3):272–84. doi:10.3171/2009.3.Spine08621.
- [121] Deininger MH, Unfried MI, Vougioukas VI, Hubbe U. Minimally invasive dorsal percutaneous spondylolysis for the treatment of adult pyogenic spondylodiscitis. *Acta Neurochirurgica* 2009;151:1451–7.
- [122] Pola E, Autore G, Formica V, et al. New classification for the treatment of pyogenic spondylodiscitis: validation study on a population of 250 patients with a follow-up of 2 years. *Eur Spine J* 2017;26:479–88.
- [123] Staatz G, Adam GB, Keulers P, Vorwerk D, Günther R. Spondylodiskitische abszesse: CT-guided percutaneous catheter drainage. *Radiology* 1998;208(2):363–7.
- [124] Korovessis P, Repantis T, Hadjipavlou AG. Hematogenous pyogenic spinal infection: current perceptions. *Orthopedics* 2012;35(10):885–92.
- [125] Schuster JM, Avellino AM, Mann FA, et al. Use of structural allografts in spinal osteomyelitis: a review of 47 cases. *J Neurosurg: Spine* 2000;93(1):8–14.
- [126] Dimar JR, Carreon LY, Glassman SD, Campbell MJ, Hartman MJ, Johnson JR. Treatment of pyogenic vertebral osteomyelitis with anterior debridement and fusion followed by delayed posterior spinal fusion. *Spine* 2004;29(3):326–32.
- [127] Lu DC, Wang V, Chou D. The use of allograft or autograft and expandable titanium cages for the treatment of vertebral osteomyelitis. *Neurosurgery* 2009;64(1):122–30.
- [128] Rihn JA, Makda J, Hong J, et al. The use of RhBMP-2 in single-level transforaminal lumbar interbody fusion: a clinical and radiographic analysis. *Eur Spine J* 2009;18:1629–36.
- [129] Allen RT, Lee Y-P, Stimson E, Garfin SR. Bone morphogenetic protein-2 (BMP-2) in the treatment of pyogenic vertebral osteomyelitis. *Spine* 2007;32(26):2996–3006.
- [130] O'Shaughnessy BA, Kuklo TR, Ondra SL. Surgical treatment of vertebral osteomyelitis with recombinant human bone morphogenetic protein-2. *Spine* 2008;33(5):E132–9.
- [131] Erturer E, Tezer M, Aydogan M, Mirzanlı C, Ozturk I. The results of simultaneous posterior-anterior-posterior surgery in multilevel tuberculosis spondylitis associated with severe kyphosis. *Eur Spine J* 2010;19(12):2209–15. doi:10.1007/s00586-010-1481-z.
- [132] Liljenqvist U, Lerner T, Bullmann V, Hackenberg L, Halm H, Winkelmann W. Titanium cages in the surgical treatment of severe vertebral osteomyelitis. *Eur Spine J* 2003;12(6):606–12. doi:10.1007/s00586-003-0614-z.