

## CASE REPORT

## Leukemic mature B-cell neoplasm observed during the treatment with romiplostim in patient with thrombocytopenia and liver cirrhosis

Marina Osawa, Hideki Akiyama , Sunao Mae, Yuko Fujiwara & Michio Yamane

Department of Medicine, Nitobe Memorial Nakano General Hospital, 4-59-16, Chuou, Nakano, Tokyo 164-8607, Japan

### Correspondence

Hideki Akiyama, Department of Medicine, Nitobe Memorial Nakano General Hospital, 4-59-16, Chuou, Nakano, Tokyo 164-8607, Japan.  
Tel: 81-3-3382-1231; Fax: 81-3-3381-4799;  
E-mail: hakiyama@nakanosogo.or.jp

### Funding Information

No sources of funding were declared for this study.

Received: 9 January 2018; Revised: 27 February 2018; Accepted: 24 March 2018

*Clinical Case Reports* 2018; 6(6): 1087–1089

doi: 10.1002/ccr3.1530

Attention: The term “Nitobe Memorial Nakano General Hospital” is the official name of “Nitobe Kinen Nakano Sogo Byoin.”

### Introduction

Romiplostim is one of the newly accepted thrombopoietin (TPO) agonist and had been widely used in the treatment of idiopathic thrombocytopenic purpura (ITP), thrombocytopenia secondary due to myelodysplastic syndrome (MDS), and recently aplastic anemia [1]. TPO agonist had been also used in many situations of thrombocytopenia including liver cirrhosis [2, 3]. Accordingly, list of adverse events has been accumulated still and their safety profile has been re-evaluated. We report here the new adverse event, leukemic mature B-cell neoplasm, observed during the usage of romiplostim in patient with thrombocytopenia and liver cirrhosis.

### Case Report

A 66-year-old female was referred to hematology division because of sudden onset of severe thrombocytopenia. She

### Key Clinical Message

We report here a new adverse event of romiplostim which is a protein analog of thrombopoietin. Leukemic mature B-cell neoplasm was observed during the treatment of thrombocytopenia in a patient with liver cirrhosis. Their relationship was suggested clinically but the mechanism of leukemic expansion of lymphoma cells was not clarified.

### Keywords

Cirrhosis, mature B-cell neoplasm, romiplostim.

was found to have liver dysfunction due to HCV 16 years ago, and liver biopsy revealed chronic hepatitis with stage A2, F2 (Inuyama classification). She lost follow-up and re-appeared with esophageal varices and ascites in March 2017. She underwent endoscopic variceal ligation and was referred to hematology division in June because of pancytopenia. One year ago, her blood count revealed white blood cell (WBC) count  $2.68 \times 10^9/L$ , hemoglobin (Hb) level 109 g/L, and platelet count of  $58 \times 10^9/\mu L$ .

At the time of evaluation, she was noticed to have ascites and splenomegaly and WBC  $1.56 \times 10^9/L$ , Hb 89 g/L, and platelet count  $24 \times 10^9/L$  that subsequently decreased to  $6 \times 10^9/L$  with bleeding tendency in a month. Bone marrow aspiration study revealed hypocellular marrow but megakaryocyte was observed and chromosomal study showed 46, XX[20]. The possibilities of drug-induced thrombocytopenia were excluded, and serum antibody against *Helicobacter pylori* was negative.

Although antinuclear antibody was positive, romiplostim was proceeded from 1  $\mu\text{g}/\text{body weight}$  (BW) under the diagnosis of idiopathic thrombocytopenic purpura. Prednisolone was deferred considering the risk of infection and gastrointestinal bleeding on top of liver cirrhosis. After several weekly injections with increasing dose without any significant effect, the dose was increased up to 200  $\mu\text{g}$  (4  $\mu\text{g}/\text{BW}$ ) for four times and then 250  $\mu\text{g}$  (5  $\mu\text{g}/\text{BW}$ ) (Fig. 1).

One week after the last dose, her WBC count jumped to  $11.2 \times 10^9/\text{L}$  and Hb level was 94 g/L with reticulocyte 8.4%. Her platelet count increased to  $84 \times 10^9/\text{L}$ , and LDH level was 760 IU/L. Romiplostim was stopped, and bone marrow examination was performed that revealed many erythroblasts, smudge cells, and blastic lymphocyte with fine chromatin and prominent nucleoli (Fig. 2A and B). Surface marker study of CD45-gated blastic cells was CD5<sup>-</sup>, CD10<sup>-</sup>, CD19<sup>+</sup>, CD20<sup>+</sup>, CD22<sup>+</sup>, CD23<sup>-</sup>, and  $\lambda$ + (Fig. 2C). Cyclin D1 staining was negative.

Chromosomal study revealed 46, X, add(X)(p11.2), add(3)(q21), add(8)(q11.2), add(11)(q13), add(11)(q13), del(13)(q?), add(14)(q32), add(19)(p13)[16]/46, XX[1], and FISH test showed MYC:3/IGH:3 cells in 11%. FISH tests for BCL1, BCL2, and TP53 reported two signals, and no splitting was observed on MYC. Rearrangement of following genes was also evaluated with negative results: major BCR-ABL, minor BCR-ABL, ETV6-AML1, E2A-PBX1, SIL/TAL1, MLL-AF4, MLL-AF, and MLL-ENL. PCR assay for EBV was negative, and antibody against EBNA was positive.

Lymph nodes were not palpable, and abdominal CT showed ascites and splenomegaly without mass. No lymphadenopathy was observed. Culture of peritoneal fluid was positive for *Klebsiella ozxytoca*, consisting of spontaneous bacterial peritonitis.

She was diagnosed as leukemic mature B-cell neoplasm, and prednisolone 40 mg/day was given for 5 days without any significant effect. Her general condition deteriorated

with ECOG performance status 4 and WBC count increased up to  $44.7 \times 10^9/\text{L}$  with LDH 1955 IU/L. Smear revealed smudge cell in almost 50% with around 10% blastic cells on countable cells. Lastly, CHOP (cyclophosphamide, doxorubicin, vincristine, and prednisolone) was initiated with 50% dose reduction. WBC count responded quickly with  $0.7 \times 10^9/\text{L}$  on 5th postchemotherapy day without evidence of tumor lysis syndrome, but she expired because of metabolic acidosis on the same day. Autopsy was not performed.

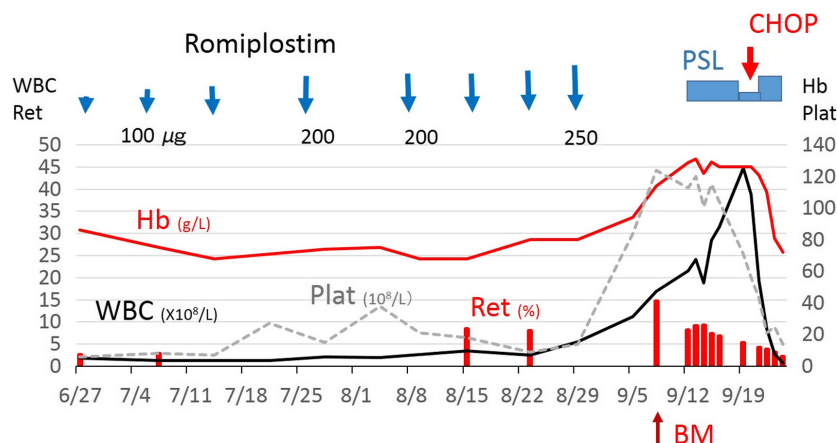
## Discussion

Romiplostim is a small peptide to stimulate TPO receptor and had been used in patients with ITP and recently with myelodysplastic syndrome. Reported adverse events were epistaxis, cough, arthralgia, hematoma, and others [4].

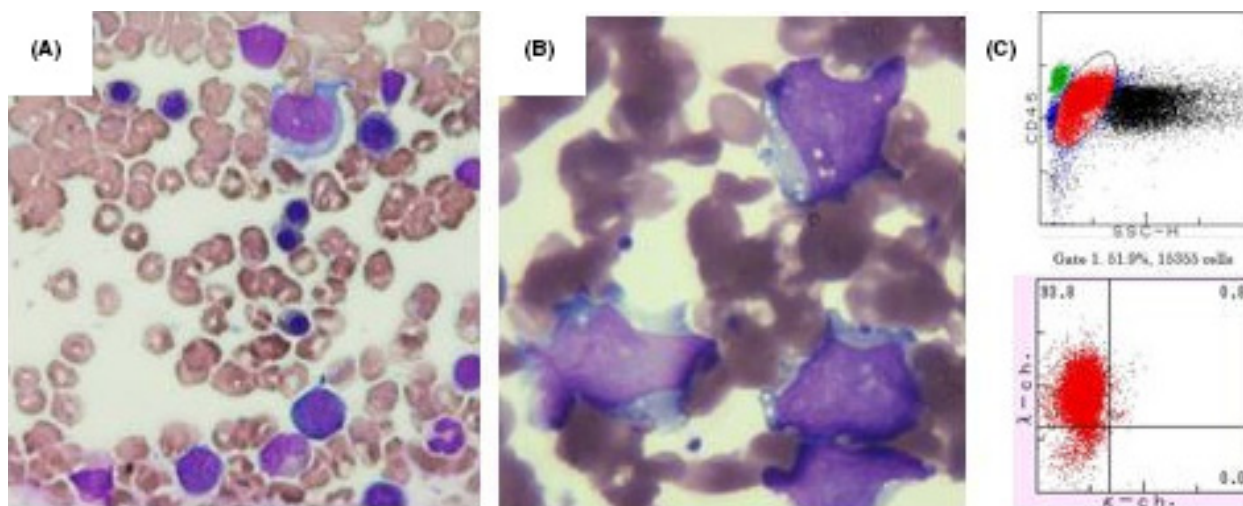
Among the patients with MDS, transient increase in myeloblasts and appraisal of acute myelogenous leukemia had been reported and were known adverse events (AE) of romiplostim [1]. However, developing or expansion of lymphoma cells has not been reported as a related AE in the literature. B-cell lymphoma had been described as an unrelated AE in several reports without any detailed information.

Cines et al. reported safety data of 994 patients with ITP treated with romiplostim that included each single case of lymphoma and non-Hodgkin's lymphoma without any detail [4]. In Fenaux's paper, single case of B-cell lymphoma was reported but was considered not related to romiplostim [1]. In 2008, FDA advisory committee searched for hematological malignancies secondary to romiplostim in several phase 3 studies and ITP safety dataset and described another single case of B-cell lymphoma without any detail [5].

In the present case, it is rather difficult to speculate that romiplostim induced these chromosomal abnormalities and



**Figure 1.** Time course of white blood cell count, hemoglobin level, and platelet count after the usage of romiplostim. WBC, white blood cell count ( $\times 10^9/\text{L}$ ); Hb, hemoglobin level (g/L); Plat, platelet count ( $\times 10^9/\text{L}$ ); Ret, reticulocyte (%); PSL, prednisolone.



**Figure 2.** (A) Bone marrow showed erythroblastosis (Wright–Giemsa stain, 100x). (B) Blastic lymphocyte in peripheral blood (Wright–Giemsa stain, 400x oil) and (C) flow cytometry data of CD45-gated peripheral blood cells.

subsequent leukemic lymphocyte burst. It would be more plausible that present patient may have lymphoma or leukemic cells from the first point and romiplostim had some effect on activating and releasing those cells into peripheral blood. Flow cytometry showed those blastic cells to be mature B-cell, and clinical pictures suggest splenic diffuse large B-cell lymphoma with MYC gene abnormality as a most likely diagnosis. It is impossible to show the exact mechanism but blastic lymphocyte clearly increased parallel to the recovery of platelet count that indicates a possible relationship between romiplostim and subsequent lymphocytosis.

Another striking clinical aspect in this case is the increase in red cell production at the same time with thrombocytosis. In previous reports, effect of romiplostim on erythroid series was not observed [4]. However, TPO was shown to expand erythroid progenitors and increase red cell production in some circumstances in the presence of erythropoietin [6]. Erythropoietin level at the time of increased reticulocytes in this patient revealed 41.5 mIU/mL (normal range, 4.2–23.7) that may affect the erythrocytosis in this case.

## Conclusion

This case may suggest rather new adverse event of romiplostim, leukemic mature B-cell neoplasm, and give a warning to observe more closely while using this medication.

## Authorship

MO and HA: conceptualized original article and writers. SM, YF, and MY: participated in the delivery of patient care and correction of the text.

## Conflict of Interest

None declared.

## References

- Fenaux, P., P. Muus, H. Kantarjian, R. M. Lyons, R. A. Larson, M. A. Sekeres, et al. 2017. Romiplostim monotherapy in thrombocytopenic patients with myelodysplastic syndromes: long-term safety and efficacy. *Br. J. Haematol.* 178:906–913.
- Khellaf, M., M. Michel, P. Quittet, J. F. Viillard, M. Alexis, F. Roudot-Thoraval, et al. 2011. Romiplostim safety and efficacy for immune thrombocytopenia in clinical practice: 2-year results of 72 adults in a romiplostim compassionate-use program. *Blood* 118:4338–45.
- Maan, R., R. J. de Knegt, and B. J. Veldt. 2015. Management of thrombocytopenia in chronic liver disease: focus on pharmacotherapeutic strategies. *Drugs* 75:1981–1992.
- Cines, D. B., T. Gernsheimer, J. Wasser, B. Godeau, D. Provan, R. Lyons, et al. 2015. Integrated analysis of long-term safety in patients with chronic immune thrombocytopenia (ITP) treated with the thrombopoietin (TPO) receptor agonist romiplostim. *Int. J. Hematol.* 102:259–270.
- Oncologic drugs advisory committee. FDA advisory committee briefing document. Biological License Application (BLA) 125268: Romiplostim for the treatment of thrombocytopenia in certain adult patients with chronic immune idiopathic thrombocytopenia purpura. Available at: <https://www.fda.gov/ohrms/dockets/ac/08/briefing/2008-4345b1-01-FDA>.
- Kaushansky, K., V. C. Broudy, A. Grossmann, J. Humes, N. Lin, H. P. Ren, et al. 1995. Thrombopoietin expands erythroid progenitors, increases red cell production, and enhances erythroid recovery after myelosuppressive therapy. *J. Clin. Invest.* 96:1683–1687.