

tumor, a low-degree sarcoma that can simulate more aggressive sarcomas or imitate an inflammatory process through an extreme scarcity or clear absence of characteristic lesional cells. However, regardless of the histological findings, a complete excision, preferably with free margins, is the most efficient approach to reduce the incidence of the local recurrence of the disease, which is the main cause of morbidity associated with the tumor. In addition, adjuvant therapy, such as radiation, can be considered for those patients with positive surgical margins, especially if the tumor contains atypical histological characteristics.<sup>1,3,5</sup> □

## REFERENCES

1. Agusti-Mejias A, Sabater V, Messeguer F, García R, Ballester R, Marín S, et al. Inflammatory Myxohyaline Tumor of the Distal Extremities. *Actas Dermosifiliogr*. 2011;102:456-62.
2. Montgomery E. Inflammatory Myxohyaline Tumor. *Pathology Case Reviews*. 2002;7: 133-138.
3. Alkuwari E, Gravel DH. A 30-Year-Old Man With a Soft Tissue Mass on the Right Elbow. *Arch Pathol Lab Med*. 2006;130:e35-6.
4. Laskin WB, Fetsch JF, Miettinen M. Myxoinflammatory Fibroblastic Sarcoma - A Clinicopathologic Analysis of 104 Cases, with Emphasis on Predictors of Outcome. *Am J Surg Pathol*. 2014;38:1-12.
5. Naqvi A, Mukhopadhyay S, de la Roza G, Damron T. Little-Finger Mass in a 29-Year-Old Man. *Arch Pathol Lab Med*. 2005;129:1343-4.

## MAILING ADDRESS:

Elaine Cristine Vieira de Paiva  
Rua Pedro I, 1.033  
Centro  
60035-101 - Fortaleza - CE - Brazil  
E-mail: elainecva@hotmail.com

**How to cite this article:** Paiva ECV, Bezerra NT, Valença Júnior JT, Sousa ARD. Inflammatory mixo-hyaline tumor of distal extremities - a rare sarcoma simulating benign diseases. *An Bras Dermatol*. 2017;92(2):292-4.

### Multiple adult-onset xanthogranuloma, an uncommon diagnosis\*

Bárbara Roque Ferreira<sup>1</sup>  
José Pedro Reis<sup>1</sup>

José Carlos Cardoso<sup>1</sup>  
Óscar Tellechea<sup>1,2</sup>

DOI: <http://dx.doi.org/10.1590/abd1806-4841.20176216>

Received on 07.07.2016

Approved by the Advisory Board and accepted for publication on 15.07.2016

\* Study conducted at Serviço de Dermatologia e Venereologia, Centro Hospitalar e Universitário de Coimbra  
Financial support: None.  
Conflict of interest: None.

<sup>1</sup> Department of Dermatology and Venereology of the Hospital and University Center of Coimbra (CHUC, EPE) - Coimbra, Portugal.

<sup>2</sup> Department of Dermatology of the Medical School of the University of Coimbra - Coimbra, Portugal.

©2017 by Anais Brasileiros de Dermatologia

Dear Editor,

A 77-year-old Caucasian male patient was referred to our Service for presenting brownish and erythematous-violet papules (4 to 8 mm), located bilaterally in arms, armpits, lower abdominal quadrants and thighs (Figure 1). There was no involvement of the face, dorsal surface of the joints or mucous membranes. The lesions, which were always asymptomatic, had evolved progressively for ten months.

At the general objective examination, there were no significant alterations, namely ophthalmologic, cardiopulmonary and neurological. No systemic semiology or relevant family history coexisted. Among the patient's personal antecedents were major depression and anxiety disorder. Diagnoses of histiocytosis, particularly generalized eruptive histiocytoma, multiple adult xanthogranuloma (XGA), Erdheim-Chester disease and cutaneous metastases, were considered.

The histopathological study of a lesion showed infiltration of the dermis and, in particular, of the hypodermis by histiocytes with foamy cytoplasm, accompanied by Touton cells, occasional lymphocytes and rare eosinophils (Figure 2). Infiltrate cells were CD68 positive and protein S100 and CD1a negative (Figure 3).

No alterations were observed in the complementary evaluation, which included: hemogram with leukogram; blood biochemistry; electrophoretic proteinogram and serum immunofixation; urinalysis, diuresis monitoring and pituitary hormone study; skeletal radiography; electrocardiogram; respiratory function tests; cranio-encephalic and thoraco-abdominopelvic tomodensitometry studies.

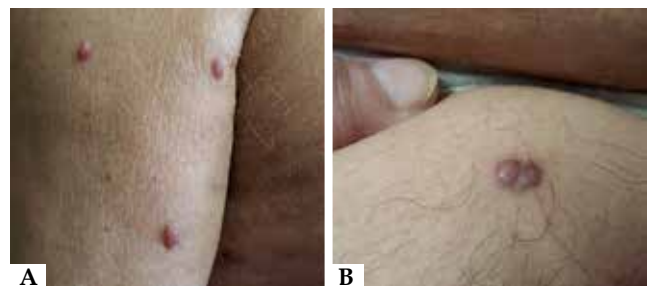

FIGURE 1: Adult multiple xanthogranuloma. A. Detail of papule-nodular, brown and erythematous-violaceous lesions, asymptomatic, in the right arm. B. Detail of lesions on the right thigh

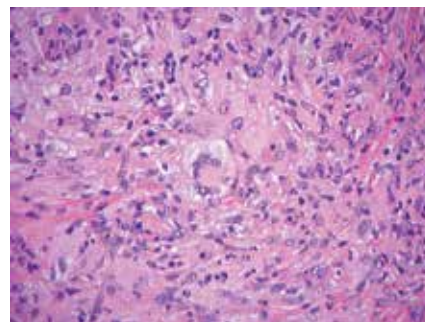
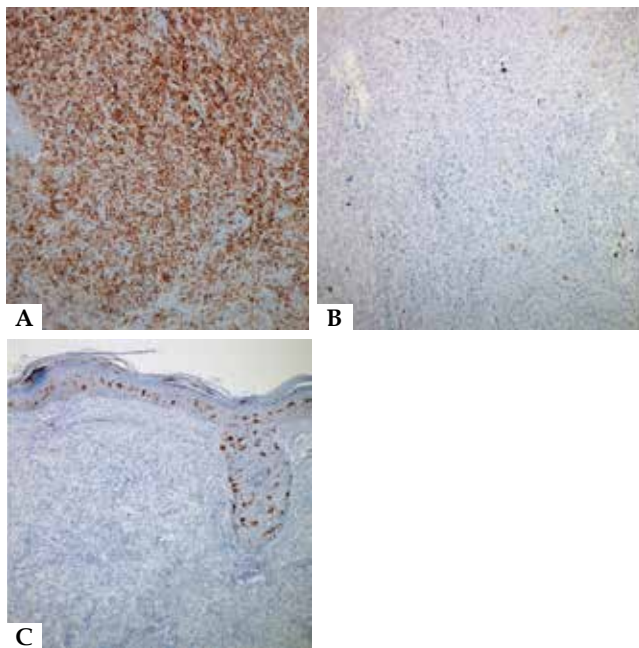


FIGURE 2: Histopathology - hematoxylin-eosin, original magnification 400x. Infiltration of the entire thickness of the dermis by histiocytes with foamy cytoplasm, accompanied by multinucleated Touton giant cells



**FIGURE 3:** Immunohistochemistry - original magnification 100x. A: CD68 positive. B: S100 protein negative. C: CD1a negative

The diagnosis of multiple XGA was retained. In view of the asymptomatic character of the lesions and the patient's psychiatric history, we opted for therapeutic abstention with periodic observation.

Histiocytoses correspond to a set of proliferative diseases of the mononuclear phagocytic system and are grouped into Langerhans cell histiocytosis, malignant histiocytosis and non-Langerhans cell histiocytosis.<sup>1</sup>

Xanthogranuloma (XG) is the most common non-Langerhans cell histiocytosis,<sup>1</sup> but 71% of cases occur in children under one year of age.<sup>2</sup> In adults, it is rare, usually occurring in the third and fourth decades of life.<sup>2</sup> XG usually corresponds to an orange or erythematous-brown papule-nodule,<sup>3</sup> varying the tonality with the age of the lesions.<sup>1</sup> Contrary to what is observed in our patient and in juvenile XG (JXG), XGA usually occurs as a single lesion in 2/3 of cases located on the face, but may be seen in the trunk or limbs.<sup>2,4</sup> Multiple XGA, defined as more than five XG lesions, appears to be more common among men.<sup>4</sup>

JXG and XGA lesions present identical histopathology<sup>2</sup> and immunohistochemistry.<sup>5</sup> In older lesions, xanthomized cells and, characteristically, Touton cells are observed.<sup>4</sup> Immunohistochemistry confirms the presence of CD68 positive histiocytes; S100 protein and CD1a are negative, with variability of expression of factor XIIIa immunoreactivity.<sup>3</sup>

From the histopathological and immunohistochemical point of view, the findings observed in our patient could be classified as Erdheim-Chester disease. However, this can be excluded in the present case by the absence of extracutaneous changes, especially skeletal. It should be emphasized that, in generalized eruptive histiocytoma, non-Langerhans cell histiocytosis which should also be distinguished from XGA, no Touton cells are observed. These can, however, occur in disseminated xanthoma, which may form part of

the lesion spectrum of XG, but is characterized by the perilesional distribution. In multicentric reticulocyte histiocytosis, lesions are usually acral, accompanied by arthropathy, characterized by large multinucleated cells with voluminous ground-glass cytoplasm, findings that contrast with those observed in our patient.<sup>3</sup>

The etiopathogenesis of XGA is unknown. It was suggested the association with trauma, infections and neoplasias.<sup>3</sup> The association between JXG and hematological neoplasms is classic.<sup>2,5</sup> Cases of XGA, particularly multiple XGA, associated with thrombocytosis, chronic lymphocytic leukemia and monoclonal gammopathy have also been described,<sup>3</sup> not found in the patient described.

XGA lesions may appear before, concurrently or after the development of hematological pathology, and XG may be considered a cutaneous marker of hematological pathology. In other cases, the described evolution was benign.<sup>3</sup> The presence of concomitant extracutaneous lesions was reported in JXG, but not in XGA.<sup>2,4</sup> However, cases of solitary extractive XGA have been reported, with no coexisting skin lesions.<sup>2</sup> As noted in the present case, spontaneous regression is less likely in XGA than in JXG.<sup>4</sup>

The treatment of XGA is justified by numerous, uncomfortable or unsightly lesions. Surgical excision,<sup>2,5</sup> CO<sub>2</sub> laser and the systemic retinoids, with emphasis on isotretinoin,<sup>2,5</sup> are described.

In conclusion, XGA is a rare and poorly understood form of non-Langerhans cell histiocytosis, with extensive differential diagnosis and the possibility of important systemic associations. Thus, patients should undergo a thorough evaluation, with histopathological and immunohistochemical study, making possible, on the one hand, the diagnosis and, on the other hand, the exclusion of the presence of associations. Regardless of the therapeutic option, the evolution of this pathology being not understood and its benign nature being uncertain, surveillance is recommended. □

#### REFERENCES

1. Luz FB, Gaspar AP, Kalil-Gaspar N, Ramos-e-Silva M. Histiocytes and non-Langerhans cell histiocytoses in dermatology. *An Bras Dermatol*. 2003;78:99-118.
2. Achar A, Naskar B, Mondal PC, Pal M. Multiple generalized xanthogranuloma in adult: case report and treatment. *Indian J Dermatol*. 2011;56:197-9.
3. Chisolm SS, Schulman JM, Fox LP. Adult Xanthogranuloma, Reticulohistiocytosis, and Rosai-Dorfman Disease. *Dermatol Clin*. 2015;33:465-72
4. Saad N, Skowron F, Dalle S, Forestier JY, Balme B, Thomas L. Multiple adult xanthogranuloma: case report and literature review. *Dermatology*. 2006;212:73-6.
5. Tan LC, Tan KB, Aw CW. Unusual presentation of adult xanthogranuloma. *Singapore Med J*. 2014;55:e25-7.

#### MAILING ADDRESS:

Barbara Isabel Roque Cunha Ferreira  
Centro Hospitalar e Universitário de Coimbra  
Praceta Prof. Mota Pinto  
3000-075 - COIMBRA -Portugal  
Email: barbara.roqueferreira@gmail.com

**How to cite this article:** Ferreira BR, Cardoso JC, Reis JP, Tellechea O. Multiple adult-onset xanthogranuloma, an uncommon diagnosis. *An Bras Dermatol*. 2017;92(2):294-5.