

Available online at [www.sciencedirect.com](http://www.sciencedirect.com)

ScienceDirect

journal homepage: [www.elsevier.com/locate/radcr](http://www.elsevier.com/locate/radcr)

## Case Report

# Oculomotor nerve palsy in neurofibromatosis type 2 <sup>☆</sup>

Aymen Shahab, MBBS<sup>a</sup>, Hafsa Sardar, MBBS<sup>a</sup>, Samaa Akhtar, MD, MSc<sup>b</sup>, Anam Safdar, MBBS, FCPS<sup>a</sup>, Muhammad Ismail Safi, MD<sup>c,\*</sup>, Izaz Ahmad<sup>d</sup>, Faheemullah Khan, MBBS, MD<sup>e</sup>

<sup>a</sup> Department of Radiology, Hayatabad Medical Complex, Peshawar, Pakistan

<sup>b</sup> Department of Health Sciences, City, University of London, London, United Kingdom

<sup>c</sup> Department of Radiology, Nashter National Kidney Hospital, Jalalabad, Afghanistan

<sup>d</sup> Pak International Medical College, Peshawar, Pakistan

<sup>e</sup> Department of Radiology, Aga Khan University Hospital, Karachi, Pakistan

## ARTICLE INFO

## Article history:

Received 15 July 2022

Revised 29 July 2022

Accepted 3 August 2022

## Keywords:

NF2

Radiology

Manchester criteria

Schwannoma

Cranial nerves

Neurology

## ABSTRACT

Neurofibromatosis (NF) type 2 is a rare neurological, autosomal dominant and genetic disorder. It is caused by a mutation in the tumor suppressor gene, called NF2 gene. The disorder results in several benign tumors of the nervous system. These typically include vestibular schwannomas, meningiomas, and ependymomas. Multiple cranial nerve abnormalities affect the brain, spinal cord, nerves, and skin and cause significant morbidity in patients. We describe a 20-year-old patient, with a family history of brain tumors, with symptoms of left sided third nerve palsy. Magnetic Resonance Imaging (MRI) of the brain and orbits revealed a small sized cavernous sinus meningioma and bilateral vestibular schwannomas. As per the differential diagnosis and optimal resolution brain imaging, NF2 was diagnosed. The patient was referred for specific treatment to the neuro-oncology unit. The case is distinct as the patient presented with a parasellar meningioma leading to third nerve palsy besides bilateral vestibular schwannomas. Manchester criteria and high contrast MR imaging proved more beneficial in our patient for the diagnosis of a wider clinical spectrum of NF2.

© 2022 The Authors. Published by Elsevier Inc. on behalf of University of Washington.

This is an open access article under the CC BY-NC-ND license

(<http://creativecommons.org/licenses/by-nc-nd/4.0/>)

## Introduction

Neurofibromatosis 2 (NF2) is a genetic, autosomal dominant disorder. It is a rare central nervous system (CNS) disorder

with an incidence of 1:40,000 [1]. It results in the formation of multiple benign tumors along the nerves [1]. The NF2 gene is called neurofibromin 2 (NF2) or the 'Merlin' gene. A mutation in this NF2 gene, located in the long arm of chromosome 22 (22q12.2), results in the NF2 pathology [2]. Despite being ge-

Abbreviations: CC, Craniocaudal; ICA, Internal carotid artery; T1WI, T1 weighted imaging; T2WI, T2 weighted imaging; GAD, Gadolinium.

<sup>☆</sup> Competing Interests: None.

\* Corresponding author.

E-mail address: [ismailsafi0254@gmail.com](mailto:ismailsafi0254@gmail.com) (M.I. Safi).

<https://doi.org/10.1016/j.radcr.2022.08.003>

1930-0433/© 2022 The Authors. Published by Elsevier Inc. on behalf of University of Washington. This is an open access article under the CC BY-NC-ND license (<http://creativecommons.org/licenses/by-nc-nd/4.0/>)

netic, in a few cases, it can also be caused by a de novo mutation in the NF2 gene. As the disease is autosomal dominant, the defective gene is inherited from either parent, making the risk of inheritance 50%. The most common clinical feature of NF2 is bilateral vestibular schwannomas, occurring in approximately 90%-95% of patients. However, other cranial nerves can also develop schwannomas, with the most frequent being III and V [3].

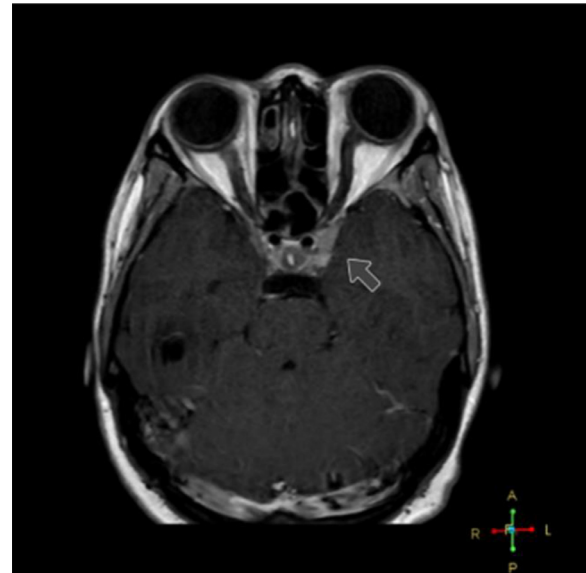The age of presentation and diagnosis are usually in the second to third decade of life [1]. Clinical symptoms include dizziness, headaches, tinnitus, hearing loss, facial weakness, and difficulties with balance and walking [4]. The most common site for the tumors is in the CNS, and the most common types are ependymomas, meningiomas, and gliomas. Multiple meningiomas usually occur in 50%-60% of patients [4] spinal ependymomas involve approximately 90% of patients with NF2 [5]. One-third of patients with spinal ependymomas are at risk for spinal cord compression [5]. Patients with NF2 can also have cutaneous neurofibromas, though much less compared to NF1.

Magnetic resonance (MR) imaging for the brain and spine is a crucial investigation for NF2 due to the high prevalence of CNS tumors in the condition. Contrast-enhanced MR imaging for NF2 with gadolinium with thin sections through the brain stem is optimal for identifying vestibular schwannomas [5]. Cervical spine MR imaging is also suggested for evaluating spinal tumors, most commonly ependymomas [5].

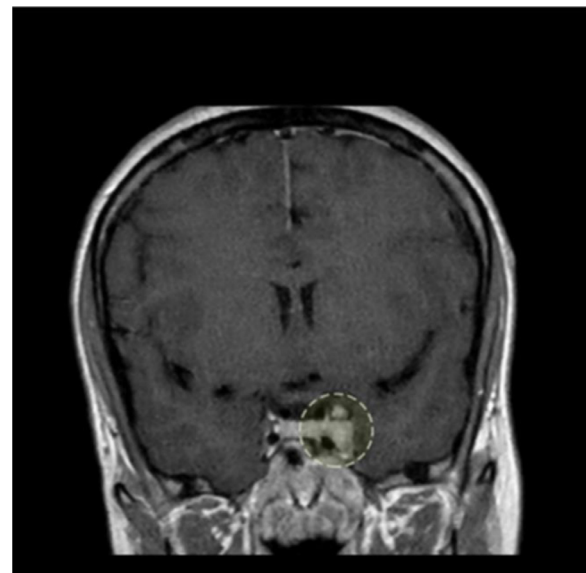
## Case presentation

A 20-year-old female patient presented to the ophthalmology outpatient department with complaints of mild left-sided ptosis, ipsilateral decreased vision, and diplopia for the last year. She had a family history of brain tumors. Her mother died of an undiagnosed neurological disorder, and her sister had a brain tumor which caused deafness, blindness, and muteness. The patient's eye examination revealed ptosis of the left eye, left dilated pupil, left-sided exotropia, reduced visual acuity in the left eye, and left-sided diplopia. These were all suggestive of left-sided third cranial nerve palsy. The patient was referred for a 3 Tesla (T) MR imaging of the brain with contrast. However, the patient underwent an open scanner MR imaging or 0.3T scan instead. This scan did not reveal any abnormality. Despite a routine scan, there was a high clinical suspicion of cranial nerve lesions due to the presenting complaints, so the patient was referred for a high field or 1.5T MR imaging scan with contrast of the brain and orbits in a tertiary care setup.

Radiological findings in this scan included an extra-axial altered signal intensity lesion in the left cavernous sinus extending into the left orbital apex. The lesion was iso-intense to grey matter on T1W1 and T2WI with homogeneous enhancement on post-contrast images. The lesion was closely abutting the left optic nerve; however, the optic nerve was of standard caliber and showed no altered signals (Figs. 1 and 2). An altered signal intensity extra-axial lesion was also seen in bilateral cerebellopontine angles appearing isointense on T1WI and T2WI with homogenous post-contrast enhancement. It measured 15 × 8 mm on the left side and 12 × 5.5 mm on the



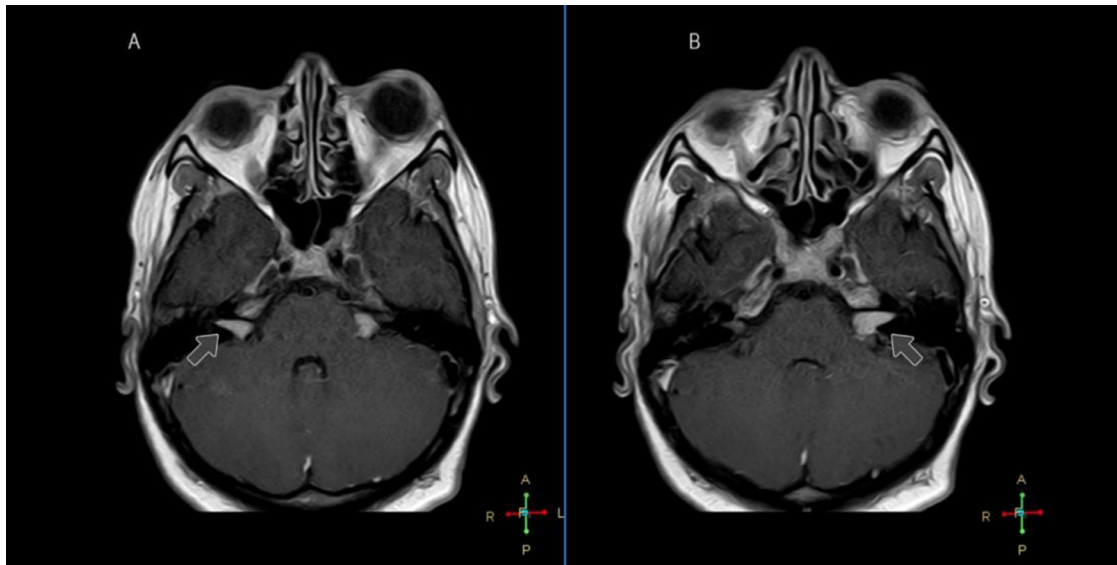
**Fig. 1 – Post GAD TIWI MRI orbits axial section reveals a homogeneously enhancing lesion in the lateral wall of the left cavernous sinus reaching the left orbital apex (as depicted by arrow).**



**Fig. 2 – Post GAD TIWI MRI orbits coronal section reveals the same lesion in CC plane, which is filling the left cavernous sinus with partial encasement of cavernous portion of left ICA (as depicted by a dotted circle); however, an average loss of flow void is noted within the vessel.**

right side. The lesions were extending into, but not infiltrating, the ipsilateral internal acoustic meatus with a widening of the respective porous acoustics (Fig. 3).

In conclusion, the MR imaging findings suggested a left parasellar meningioma and bilateral schwannomas. These findings are rare in the spectrum of NF2 for 4 reasons. First, the most common ocular finding in NF2 is a subcapsular cataract,



**Fig. 3 – (A and B) Two sequential Post GAD T1WI MRI brain axial sections show homogeneously enhancing bilateral cerebellopontine angle lesions extending into the respective internal auditory meatus (as depicted by arrows).**

which was absent in our patient. Second, auditory symptoms are the primary presenting complaints due to tumors of the eighth cranial nerve. Our patient, however, presented with third nerve palsy. Third, this unusual presentation is more likely to occur in younger people. Fourth, there were no associated ependymomas, which are common in NF2. Finally, the patient was referred to the ophthalmologist for chromosomal evaluation. After confirmation of the disease, the patient was referred to a neurosurgeon for curative resection. Due to the small size of the lesion, the patient was subsequently referred to radiation oncology for gamma knife surgery.

## Discussion

There has been some debate that the current diagnostic criteria for NF2 might be too narrow. Baser et al. described 4 sets of diagnostic systems that vary for people without bilateral vestibular schwannoma, which are pathognomonic for NF2 [6]. Patients diagnosed with NF2 are highly likely to develop meningiomas in addition to vestibular schwannomas. Meningiomas are a common primary brain tumor, and many NF2 patients suffer from multiple meningiomas. Unfortunately, even though these tumors are benign, they are associated with significant morbidity and the potential for early mortality [7]. In the case of Lan WC et al., NF2 patients may present with an isolated, solitary cutaneous schwannoma with no other associated clinical findings [8]. However, further assessment is warranted in young patients presenting with a peripheral schwannoma with no other clinical findings [8]. Subsequently, Baser et al. conducted a large-scale study in 2006. They concluded that the Manchester criteria is the most sensitive for diagnosing NF2. The diagnostic checklist for NF2 using the Manchester criteria is met when an individual has one of the following: bilateral vestibular schwannomas; a first-degree relative with NF2, unilateral vestibular schwannoma or multi-

ple meningiomas (at least 2), gliomas, or posterior subcapsular lenticular opacities [9]. It should be noted that the clinical diagnosis of NF2 is a continuous process that can change as new tumors arise [10].

In our case, the patient had a family history of brain tumors, leading to morbidity and mortality. The clinical presentations were limited to the CNS. No peripheral nerves were affected according to systemic examination. Therefore, radiological findings of bilateral vestibular schwannomas and a cerebral meningioma assist in diagnosing even an unusual case presentation of NF2 using the Manchester criteria.

## Conclusion

This case highlights the enhanced spectrum of NF2 clinical presentation. For this reason, the Manchester criteria played an essential role in establishing the diagnosis as the patient was exhibiting no common auditory clinical symptoms and systemic manifestations of NF2. Essential factors to consider are a family history of brain tumors in the patient and the patient's age. A timely diagnosis, as in our patient's case, who displayed no symptoms of 8 cranial nerve infiltration, can assist in a better prognosis. Considering there were no significant radiological findings in our patient's first radiological report, it is pertinent to do a high field MR imaging. Finally, an interdisciplinary approach can prove more beneficial in timely NF2 diagnosis and management.

## Patient consent

The patient has given consent for the publication of identifiable details, which can include photograph(s) and/or videos

and/or case history and/or details within the text to be published in any medical journal. The patient confirmed to having seen and been given the opportunity to read both the material and the article (as attached) to be published.

---

#### REFERENCES

---

- [1] Lee H-H, Lian S-L, Huang C-J, Huang M-Y. Tomotherapy for neurofibromatosis type 2: case report and review of the literature. *Br J Radiol* 2010;83(988):e74–8.
- [2] Gürsoy S, Erçal D. Genetic evaluation of common neurocutaneous syndromes. *Pediatr Neurol* 2018;89:3–10.
- [3] Chan JW. Neuro-ophthalmic features of the neurocutaneous syndromes. *Int Ophthalmol Clin* 2012;52(3):73–85.
- [4] Ferner RE. The neurofibromatoses. *Pract Neurol* 2010;10(2):82–93.
- [5] Borofsky S, Levy LM. Neurofibromatosis: types 1 and 2. *Am J Neuroradiol* 2013;34(12):2250–1.
- [6] Baser ME, Friedman JM, Evans DGR. Increasing the specificity of diagnostic criteria for schwannomatosis. *Neurology* 2006;66(5):730–2.
- [7] Bachir S, Shah S, Shapiro S, Koehler A, Mohammadi A, Samy RN, et al. Neurofibromatosis type 2 (NF2) and the implications for vestibular schwannoma and meningioma pathogenesis. *Int J Mol Sci* 2021;22(2):690.
- [8] Lan W-C, Aoh Y, Chen R-Y, Tien H-C, Lin C-D. Neurofibromatosis type 2 initially presenting as a preauricular mass: a case report. *J Otolaryngol Head Neck Surg* 2020;49(1):45.
- [9] Evans DG, Mostaccioli S, Pang D, Fadzil O Connor M, Pittara M, Champollion N, et al. ERN GENTURIS clinical practice guidelines for the diagnosis, treatment, management, and surveillance of people with schwannomatosis. *Eur J Hum Genet* 2022;30:812–17.
- [10] Chen AF, Samy RN, Gantz BJ. Cerebellopontine angle tumor composed of Schwann and meningeal proliferations. *Arch Otolaryngol Neck Surg* 2001;127(11):1385.