

# Management of device-related malignant sarcoma



Arash Khamooshian, MD,<sup>\*</sup> Theo J. Klinkenberg, MD,<sup>\*</sup> Alexander H. Maass, MD, PhD,<sup>†</sup> Massimo A. Mariani, MD, PhD<sup>\*</sup>

From the <sup>\*</sup>Department of Cardio-Thoracic Surgery, Thorax Center, University of Groningen, University Medical Center Groningen, Groningen, The Netherlands, and <sup>†</sup>Department of Cardiology, Thorax Center, University of Groningen, University Medical Center Groningen, Groningen, The Netherlands.

## Introduction

With the globally increasing life expectancy and improved outcome of congenital heart disease, the number of cardiac device implantations is increasing steadily.<sup>1,2</sup> A prolonged pacemaker (PM) therapy period is associated with potential long-term complications. Thereby battery and electrode longevity have not improved in the past decades, leading to recurrent device and electrode replacements. The combination of an increased PM indication and life expectancy possibly aggravates this effect.<sup>3</sup> An increased frequency of device and electrode replacements leads to higher complication rates than de novo implantations.<sup>4</sup> A rare complication after PM implantation is the development of malignant sarcomas. Previous studies demonstrated a slightly higher risk of cancer in PM recipients.<sup>5</sup> In this report we present a case of an undifferentiated pleomorphic sarcoma surrounding PM electrodes during prolonged PM therapy and recurrent replacements. To our knowledge, this has not been reported so far.

## Case report

A 43-year-old man presented 8 months after PM upgrade with a growing mass located below his PM pocket scar tissue. A DDD PM (dual-chamber atrioventricular [AV] sequential pacing) was implanted in 1989 for treatment of intermittent AV block of unknown origin. The PM was inserted in the left deltopectoral groove, and the electrodes were introduced via the left subclavian vein. The leads were revised after 1 week owing to atrial lead dislodgement. End of life necessitated PM device replacement in 1999 and 2005, combined with atrial lead repair owing to an isolation defect. In October 2012 device replacement was again indicated. Preoperative examination revealed a diminished left ventricular (LV) function of 35%, most likely caused by permanent right ventricular

pacing. The patient was treated according to the institutional heart failure protocol, which failed to improve his cardiac function. The patient was planned for biventricular pacing therapy according to the ESC guidelines (class I indication).<sup>6</sup> During evaluation for additional lead placement, no signs of coronary artery disease were present on the coronary angiogram and venous levophase demonstrated a suitable coronary sinus anatomy. A total occlusion of the left brachiocephalic vein on venous angiogram prevented placement of a right-sided coronary sinus lead, owing to the high risk of vena cava superior syndrome. Extraction of the left-sided system with placement of new leads through the existing canal was considered. All therapeutic options were discussed with the patient. The risk-to-benefit ratio of epicardial LV lead placement was found superior to total system extraction and an epicardial LV lead was placed by video-assisted thoracic surgery.<sup>7</sup> The postoperative recovery was uneventful and the LV ejection fraction increased to 45% at 6 months follow-up.

Swelling of the PM pocket was first noticed in the summer of 2013. A large, firm mass was palpable cephalad of the PM pocket (Figure 1A). No signs of infection were present and the patient experienced no noticeable discomfort. Ultrasonography revealed a lobulated, hypoechogenic, solid lesion of 23 × 15 × 78 mm with sharply defined edges, encasing the PM leads. Needle biopsy revealed pleomorphic malignant cells with hyperchromatic, polymorphic nuclei. Immunohistochemistry demonstrated an undifferentiated pleomorphic sarcoma. A computed tomography scan was performed for staging purposes and demonstrated a 30-mm round nodule in the left shoulder region without pulmonary metastasis or mediastinal/hilar lymphadenopathy (Figure 1B). Radical tumor resection was feasible according to the multidisciplinary sarcoma team, although it yielded some challenges: (1) tumor spill had to be prevented; (2) the patient's rhythm had to be secured because he was PM dependent; and (3) a large defect after resection had to be reconstructed. To prevent tumor spill, the PM pocket was approached caudally and a successful PM removal was performed. Conventional PM replacement and lead disconnection would have caused tumor damage and spill. The advantage of the recently placed epicardial LV lead was the intrathoracic approach for the PM connection; hence no signs of tumor involvement on the epicardial LV lead were present.

**KEYWORDS** Sarcoma; Pacemaker; Resynchronization therapy; Malignancy; Pacemaker leads (Heart Rhythm Case Reports 2017;3:373–376)

Drs Khamooshian and Klinkenberg contributed equally to this work.  
**Address reprint requests and correspondence:** Dr Arash Khamooshian, Department of Cardiothoracic Surgery, University Medical Center Groningen, P.O. Box 30001, Groningen 9700 RB, The Netherlands.  
E-mail address: [a.khamooshian@umcg.nl](mailto:a.khamooshian@umcg.nl).

### KEY TEACHING POINTS

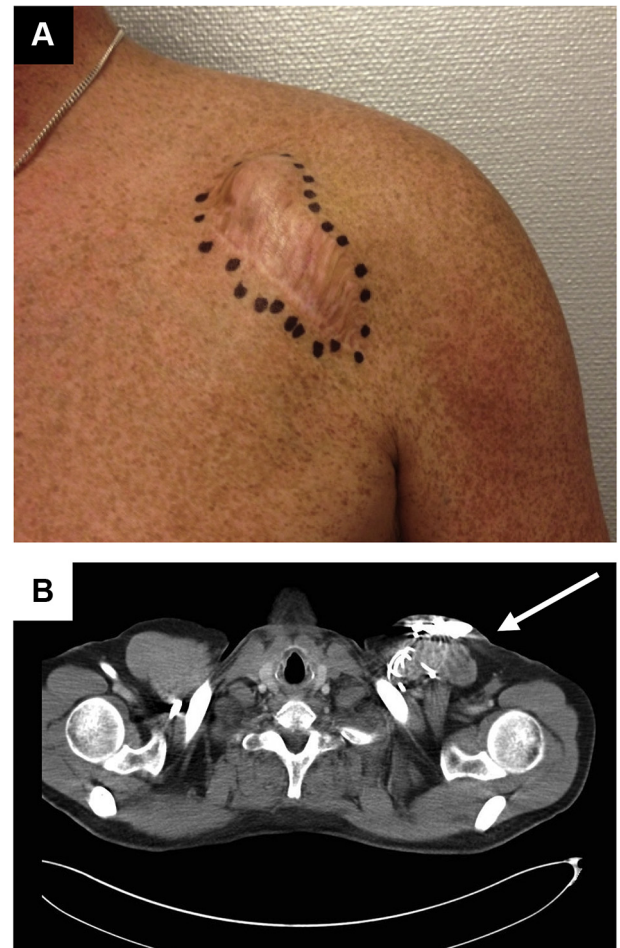
- Sarcomas around pacemaker sites are a rare finding.
- One should be aware of possible malignancies when swelling occurs in the proximity of pacemakers.
- Sarcoma treatment in dedicated centers with a multidisciplinary approach is highly recommended.

To keep the patient's rhythm stable, a pacing solution was needed. As stated earlier, introduction of a new right-sided transvenous PM lead was considered hazardous. A new single-chamber PM was placed in the rectus abdominis muscle with a lead extension subcutaneously tunneled to the epicardial LV lead. The device was programmed to VVI-R mode. The old right atrial and ventricular leads were cut off and capped. A radical tumor resection including the encaged old PM leads and part of the greater pectoral and deltoid muscle was carried out without tumor spill (Figure 2A–C). The caudal incision was extended by a 12 × 8-cm horseshoe-like incision containing a skin flap for reconstruction purposes (Figure 2D). The defect was reconstructed using the remaining greater pectoral muscle. Pathology confirmed undifferentiated pleomorphic sarcoma with tumor-free margins. Postoperative recovery was uneventful and the patient was discharged on the third postoperative day. A 60-Gy adjuvant radiotherapy was provided because a marginal resection was performed.

### Discussion

In this report we describe a rare case of malignant sarcoma surrounding a frequently renewed PM. Some challenges had to be overcome for safe resection. A multidisciplinary team determined treatment strategy. The latest (epicardial) PM lead and a new PM in the rectus abdominis position were used to secure the patient's rhythm prior to resection. Old PM leads were cut off and capped. The tumor was resected successfully and the defect reconstructed using a rotation flap. Epicardial LV leads are a safe alternative for intravascular leads. In patients with sinus rhythm, PM syndrome is a possible complication of single-chamber pacing. This is, however, not common in patients with congenital AV block or acquired AV block in young patients, as they are used to AV dyssynchrony. LV-only pacing might cause reverse dyssynchrony compared with right ventricular-only pacing. However, evidence on LV-only vs biventricular pacing suggests equality if not superiority of LV-only pacing. In our patient, no symptoms of PM syndrome were observed and LV function is preserved at long-term follow-up.

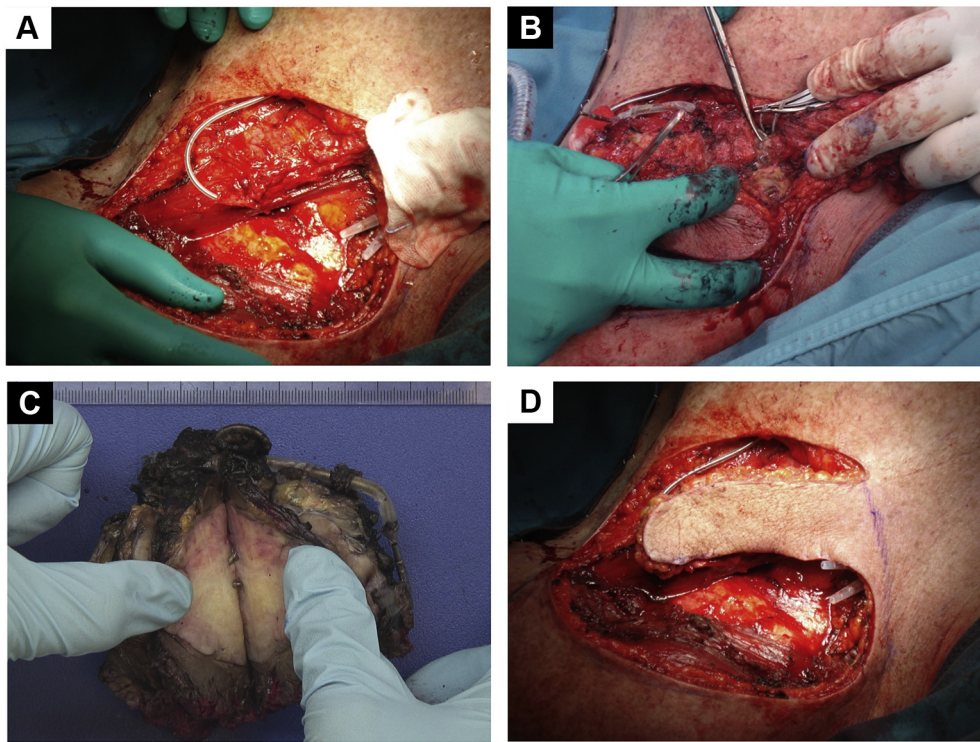
Sarcomas are a rare and heterogeneous group of malignant tumors of mesenchymal origin; they comprise less than 1% of all adult malignancies.<sup>8,9</sup> The majority (approximately 80%) originate from soft tissue of the extremities.<sup>10</sup> In a large retrospective registry a higher incidence of malignancies was detected in patients with PM implants, although no excess risk



**Figure 1** A: A large, firm mass situated beneath the scar tissue, cranially of the pacemaker pocket. No signs of infection were present. The tumor is marked prior to surgery. B: Computed tomography scan demonstrating a 30-mm round nodule in the left shoulder region without pulmonary metastasis or mediastinal or hilar lymphadenopathy.

was found for sarcomas.<sup>5</sup> The most common clinical presentation is a gradually enlarging, painless mass. Owing to tumor progression, pain and paresthesia are frequently present, caused by compression. Although associated or predisposing factors have been identified, most sarcoma cases have no clearly defined etiology and are thought to arise de novo. Possible influencing factors are radiation or chemotherapy, chemical carcinogens, chronic irritation, and genetic predisposition.<sup>11</sup> Also, silicone implants accompanied by chronic inflammation have been linked to sarcomas.<sup>12</sup> This possibly suggests a causal relationship between inflammation or injury and sarcomas, especially in patients with long-term PM dependency and multiple lead or PM device revisions. The mechanism of tumor formation owing to chronic irritation or tissue–metal contact has not yet been clarified. The relationship between titanium compounds and malignancies has been reported earlier, however. In rat models, inhaled titanium dioxide has the potential to enhance lung malignancies.<sup>13</sup> However, this is based on titanium nanoparticles either inhaled or from wear and tear of metal-on-metal prosthesis. This is not the case in pacemakers.





**Figure 2** A, B: Radical tumor resection including the encaged pacemaker leads and part of the greater pectoral and deltoid muscle. Tumor spill was avoided. C: Tumor with encaged pacemaker leads post resection. D: Extension of the caudal incision by a 12 × 8-cm horseshoe-like incision containing a skin flap for reconstruction purposes.

Another hypothesis is that there is a possible mutagenic effect of electromagnetic fields caused by PM devices. This is speculative, since large studies of long-term and high-power magnetic fields in mice did not show an increase in incidence of malignancy.<sup>14</sup> Despite the lack of evidence in animal studies, a weak promoting effect in humans under specific conditions cannot be ruled out.<sup>15</sup>

Modern medical practice is composed of high-end care with state-of-the-art treatment strategies based on evidence-based medicine. Specialized multidisciplinary teams are required to provide the best possible care for rare conditions. To ensure correct diagnosis and optimize treatment planning and outcome, sarcomas should be treated in dedicated sarcoma centers with a multidisciplinary approach. Radical resection of sarcomas is complex and technically demanding. Treatment in an expert center is safe and markedly improves patient survival. In this present case, a significant amount of time was spent on safety planning: (1) ensuring cardiac pacing, (2) performing a radical resection and preventing tumor spill, and (3) surgically reconstructing the defect to ensure primary wound healing and to prevent delay in adjuvant radiotherapy.

In conclusion, sarcomas surrounding pacemakers are incidental findings. Literature provides no significant association between pacemakers and malignant sarcomas. Nevertheless, physicians should be aware of possible malignancies when swelling occurs in the proximity of pacemakers, especially because PM implantation and replacements are becoming more frequent. Postoperative follow-up after implantation

should therefore include careful inspection of PM pockets. In addition, the authors emphasize the benefit of dedicated and specialized care for patients with neoplasms near PM pockets. Referral to a dedicated center is highly recommended.

## References

1. Mond HG, Proclemer A. The 11th world survey of cardiac pacing and implantable cardioverter-defibrillators: calendar year 2009—a World Society of Arrhythmia's project. *Pacing Clin Electrophysiol* 2011;34:1013–1027.
2. Maass AH, van Veldhuisen DJ. Device therapy in patients with heart failure and preserved ejection fraction (HFPEF): a new frontier? *Eur J Heart Fail* 2010;12:527–529.
3. Maass AH, van Veldhuisen DJ. Contemporary use of devices in heart failure. *Clin Pharmacol Ther* 2013;94:433–435.
4. Kirkfeldt RE, Johansen JB, Nohr EA, Jorgensen OD, Nielsen JC. Complications after cardiac implantable electronic device implantations: an analysis of a complete, nationwide cohort in Denmark. *Eur Heart J* 2014;35:1186–1194.
5. Lipworth L, Johansen C, Arnsbo P, Moller M, McLaughlin JK, Olsen JH. Cancer risk among pacemaker recipients in Denmark, 1982–1996. *J Long Term Eff Med Implants* 2002;12:263–270.
6. The Task Force on cardiac pacing and resynchronization therapy of the European Society of Cardiology (ESC). Developed in collaboration with the European Heart Rhythm Association (EHRA), Brignole M, Auricchio A, et al. 2013 ESC Guidelines on cardiac pacing and cardiac resynchronization therapy. *Rev Esp Cardiol* 2014;67:58.
7. Schouwenburg JJ, Klinkenberg TJ, Maass AH, Mariani MA. Video-assisted thoracic placement of epicardial leads. *J Cardiovasc Surg* 2014;29:286–289.
8. Siegel RL, Miller KD, Jemal A. Cancer statistics, 2015. *CA Cancer J Clin* 2015;65:5–29.
9. Jo VY, Fletcher CD. WHO classification of soft tissue tumours: an update based on the 2013 (4th) edition. *Pathology* 2014;46:95–104.
10. Lawrence W Jr, Donegan WL, Natarajan N, Mettlin C, Beart R, Winchester D. Adult soft tissue sarcomas. A pattern of care survey of the American College of Surgeons. *Ann Surg* 1987;205:349–359.

11. Martins-Green M, Boudreau N, Bissell MJ. Inflammation is responsible for the development of wound-induced tumors in chickens infected with Rous sarcoma virus. *Cancer Res* 1994;54:4334–4341.
12. Bondurant S, Ernster V, Herdman R. Safety of Silicone Breast Implants. Washington DC: National Academies Press; 1999.
13. Xu J, Futakuchi M, Iigo M, et al. Involvement of macrophage inflammatory protein 1alpha (MIP1alpha) in promotion of rat lung and mammary carcinogenic activity of nanoscale titanium dioxide particles administered by intrapulmonary spraying. *Carcinogenesis* 2010;31:927–935.
14. National Toxicology Program. NTP Studies of Magnetic Field Promotion (DMBA Initiation) in Female Sprague-Dawley Rats (Whole-body Exposure/Gavage Studies). Natl Toxicol Program Tech Rep Ser 1999;489:1–148.
15. World Health Organization. Environmental Health Criteria Monograph, Extremely Low Frequency Fields. Geneva, Switzerland: World Health Organization Press; 2007.