

Received: 2016.01.18
Accepted: 2016.02.24
Published: 2016.05.25

ISSN 1941-5923
© Am J Case Rep, 2016; 17: 352-356
DOI: 10.12659/AJCR.897642

Total Laparoscopic Treatment of an Adult Gastric Duplication Cyst with Intrapancreatic Extension

Authors' Contribution:
Study Design A
Data Collection B
Statistical Analysis C
Data Interpretation D
Manuscript Preparation E
Literature Search F
Funds Collection G

ABDEF **Theodoros Thomopoulos**
ABE **Coppelia Farin**
AD **Benoit Navez**

Oesogastroduodenal and Bariatric Unit, Department of Abdominal Surgery and Transplantation, Cliniques Universitaires Saint-Luc, Brussels, Belgium

Corresponding Author: Theodoros Thomopoulos, e-mail: teothomopoulos@yahoo.com
Conflict of interest: None declared

Patient: Female, 28
Final Diagnosis: Gastric duplication
Symptoms: —
Medication: —
Clinical Procedure: Resection of the duplication
Specialty: Surgery

Objective: Rare disease





Background: Gastric duplication is a rare malformation mostly diagnosed during childhood. Symptoms in adults are atypical, rare, or may be completely absent. The diagnosis is suggested after a morphological and histological assessment. The treatment is a complete surgical resection.

Case Report: We report on a case of a 28-year-old woman referred to our unit for a surgical assessment of a gastric duplication of the antropyloric area associated with paraduodenal and pancreatic extensions, diagnosed by several image tools and histological confirmation. She had undergone a total laparoscopic resection of the duplication without violation of the gastric lumen or any other splanchnic injury. The postoperative course was uneventful and the patient was discharged on postoperative day seven without any complains.

Conclusions: The present report illustrates that complete resection of a distal gastric duplication is feasible by a laparoscopic minimal invasive procedure and therefore is considered to be a safe therapeutic modality. Our case is the first distal gastric duplication cyst with pancreatic and paraduodenal extension reported in the literature completely resected by laparoscopic approach.

MeSH Keywords: Adult • Laparoscopy • Stomach Diseases

Full-text PDF: <http://www.amjcaserep.com/abstract/index/idArt/897642>

 1566  —  6  19



Background

Gastric duplication is a rare malformation mostly diagnosed during childhood. Symptoms in adults are atypical, rare, or may be completely absent [1,2]. This pathology, which is associated in a third of cases with congenital malformations such as pancreatic heterotopias or esophageal atresia, is rarely associated with complications and the risk of malignant transformation is extremely rare [2,3]. The diagnosis is suggested after a morphological and histological assessment. The treatment applied is a complete surgical resection [4, 5]. This is a case report of a 28-year-old woman diagnosed with an antro-pyloric duplication cyst with an intrapancreatic and paraduodenal extension that was treated by a laparoscopic total surgical excision.

Case Report

A 28-year-old woman with a history of asymptomatic gastric duplication cyst identify one year earlier, and who was treated with antibiotics six months later for an infection of this cyst by the gastroenterologists of our hospital, was referred to our unit for a surgical assessment.

The patient was admitted to the emergency department with recurrent epigastric pain associated with nausea, vomiting, total food intolerance, and weight loss. Abdominal clinical examination revealed epigastric and hypochondriac sensitivity.

The preoperative evaluation was extensive to exclude a complication of the cyst already superinfected, and subsequently to exclude other pathology.

The patient's blood test showed a mild inflammation (CRP 19 mg/L, normal range <5 mg/L), no hyperleukocytosis (WBC $5,160 \times 10^9/L$, normal range $4.0-10.0 \times 10^9/L$); a normal renal function (creatinine 0.81 mg/dL, normal range 0.56–1.0 mg/dL), ion status (sodium 142 mmol/L, normal range 135–145 mmol/L; potassium 4.12 mmol/L, normal range 3.5–5.0 mmol/L); and normal lipase test (50 UI/L, normal range 1–100 UI/L). The abdominal ultrasound revealed a 5 cm wide structure contiguous to the horizontal portion of the gastric wall.

The abdominal computed tomography (CT) showed a gastric duplication with a diameter of 8×5 cm, along with signs of a reactionary uncomplicated chronic cephalic pancreatitis by proximity (Figure 1). The magnetic resonance cholangiopancreatography (MRCP) showed no communication between the duplication cyst and the stomach (Figure 2). Finally, the upper gastrointestinal opacification confirmed the absence of communication between the duplication and the gastrointestinal tract as well as the biliary and the pancreatic tract.

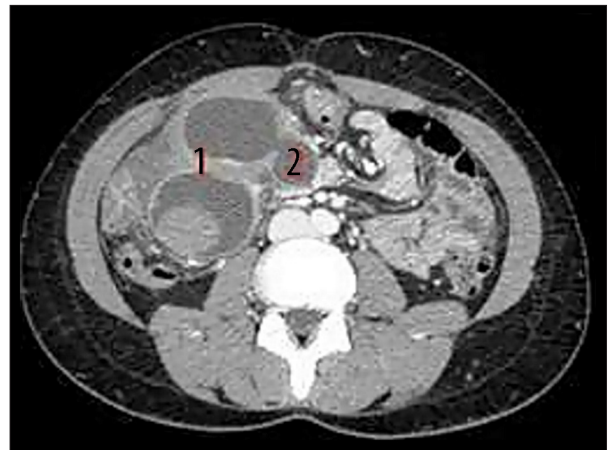

Figure 1. Computed tomography 2014: Antro-pyloric gastric duplication (1): Diabolo, (2): Pancreatic extension).

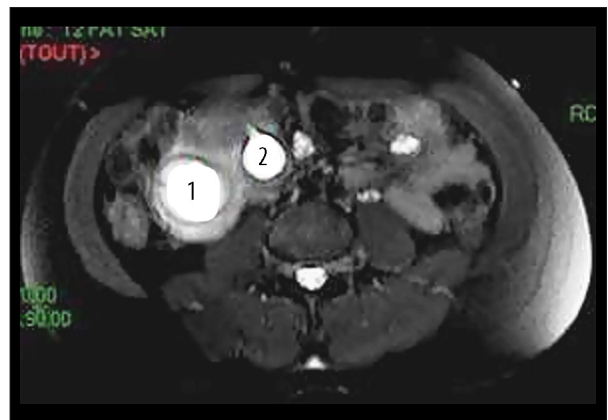


Figure 2. MRI T2-weighted 2015: Gastric duplication cyst (1): Diabolo, (2): Pancreatic extension).

A decision was made to proceed to a laparoscopic resection of the duplication. The abdominal exploration revealed a cystic lesion under the antro-pyloric area. Cystic extensions towards the transverse mesocolon, close to the first and second duodenum and inside the head of the pancreas, were observed (Figure 3). A delicate dissection of the whole cyst was performed either with ultracision or a coagulation hook, as needed, in order to avoid any injury of the gastric mucosa, the duodenum, or the pancreas. The dissection was laborious because there was no clear demarcation zone between the antral wall and the cystic lesion, requiring continuous contact with the cyst wall so as not to penetrate into the pancreatic parenchyma.

Finally, a 6 cm antral longitudinal suture of the seromuscular layer was performed with absorbable material to reinforce the gastric wall at the location of the removed cyst. The absence of leakage was checked with a methylene blue test. The specimen was sent for histopathological analysis, which showed the resection was total and free of any violation of the gastric lumen (Figure 4).

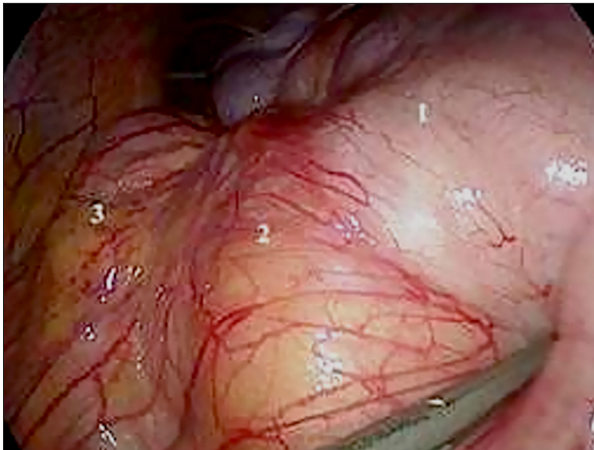

Figure 3. Laparoscopic photography 2015: Antropyloric gastric duplication (1): Stomach, (2): Duplication cyst, (3): Duodenum).

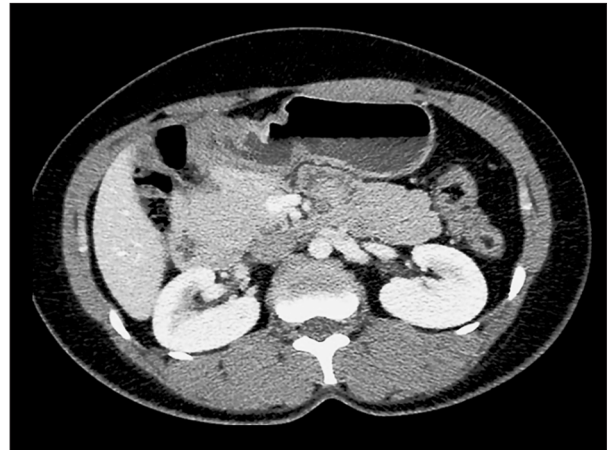


Figure 5. 6 months postoperative computed tomography: No recurrent gastric lesion (nonspecific pyloric thickening).

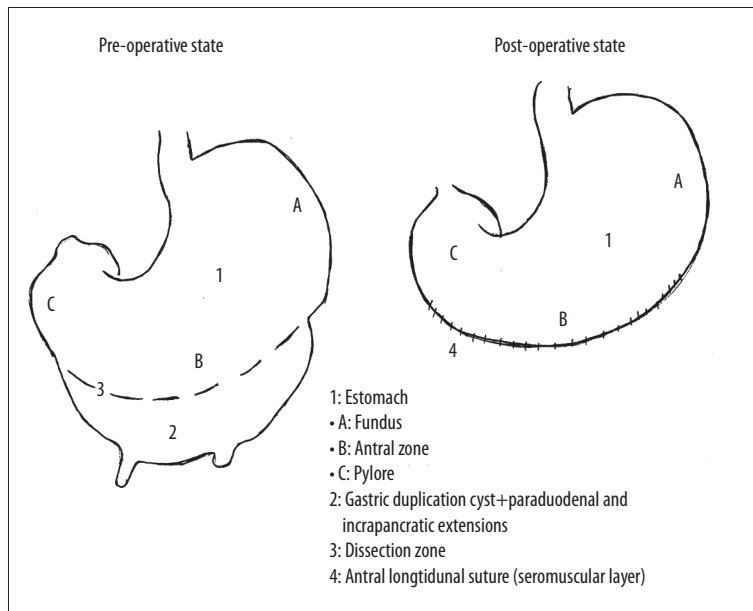


Figure 4. Schematic drawing of the resected antro-pyloric gastric duplication.

Histopathological analysis of the cyst (8×5×5 cm) confirmed the diagnosis of a non-communicating short tubular gastric duplication. The diagnosis was based on the following criteria: i) the wall of the cyst was contiguous to the stomach wall, ii) the cyst was surrounded by smooth muscle, which was in continuity with the muscle of the stomach; and iii) the internal cyst wall was lined by epithelium of gastric mucosa [6]. No evidence of malignancy was found. The initial postoperative follow-up, including clinical examination and blood tests, was uneventful. A postoperative oeso-gastro-duodenal opacification confirmed the absence of leakage.

Six months after the operation the patient remained asymptomatic, regained her lost weight, and a CT scan showed no sign of recurrence (Figure 5).

Discussion

Duplication of the alimentary tract is commonly defined by the following three characteristics: epithelial lining of gastrointestinal mucosa, presence of well-developed smooth muscle in the wall, and association with the gastrointestinal tract [6]. Gastric duplication is a rare congenital malformation representing 2–4% of all alimentary tract duplications; 70% of cases are diagnosed before 12 years of age (mostly identified because of an epigastric palpable mass). [1] In adults, it is often asymptomatic or with non-specific symptoms such as abdominal pain, vomiting, weight loss, hematemesis, or melena [2].

The main locations for gastric duplications are the greater curvature and the gastric antrum (pre-pyloric area). Two anatomical

shapes are possible: long tubular (25%), and short tubular or cystic (75%) [2]. Gastric duplications are frequently associated with pancreatic heterotopia, or in 30% of the cases, with esophageal atresia, duodenal duplication, or urogenital organ duplications. Complications such as compression of the surrounding organs, communication with the biliary tract, gastrocolic fistula, bleeding, or infections induced by stasis, are rarely seen. The possibility of carcinogenesis is extremely rare [3].

Other causes of lesions must be considered in the differential diagnosis of a gastric duplication. Especially, cystic degeneration of solid tumors (e.g., gastrointestinal stromal tumors, neurogenic tumors, adenocarcinomas), which can result from central necrosis of a large mass due to an inadequate blood supply. Other benign neoplasms such as lymphangiomas or leiomyomas, cystic adrenal lesions, pancreatic heterotopia or pseudocysts, epithelial inclusion cysts, or parasitic cysts of the spleen can also mimic gastric duplications and challenge the final diagnosis.

Diagnosis of gastric duplication is mainly achieved by endoscopic ultrasonography (EUS). The role of EUS is crucial for the diagnosis and classification of submucosal lesions. It allows exact visualization of the limits of the cyst wall with the adjacent gastrointestinal structures. It helps also to distinguish between solid and cystic lesions and to guide tissue sampling for cytohistological examination, which is essential for the differential diagnosis with other lesions and to rule out malignant transformation of the cyst [7]. EUS is also used in conjunction with gastroscopy, gastroduodenal opacification, and magnetic resonance imaging (MRI) for morphological exploration.

Total resection of the gastric duplication is the gold standard. Other surgical options are: (a) simple excision of the common wall, (b) bypass, and (c) a partial or total gastrectomy. For a malignant transformation of the duplication, a radical gastrectomy with lymphadenectomy is needed [4,5].

There were six cases of gastric duplications treated by minimally invasive techniques identified in the literature. The locations were antral in two cases, close to the cardia for two other cases, fundic in one case, and finally the posterior wall of the stomach in another case. Five cases were resected laparoscopically with one conversion into laparotomy and one resected by endoluminal techniques. All those interventions allowed complete resection of the gastric duplication through different surgical techniques such as antral gastrectomy, wedge resection, or endoscopic resection [1,4,7].

Before the first case treated laparoscopically in 2003, most authors described open procedures for the treatment of gastric duplications, which were mostly located in the proximal part of the stomach (fundus, lesser curvature); procedures included complete resection of the cyst [8], endoscopic [9],

surgical [10,11], or wide communication between the gastric duplication and the gastric cavity and total or partial gastrectomy [12].

Minimally invasive treatment can be important in terms of postoperative morbidity (such as pulmonary infection), earlier bowel function recovery, earlier diet start time, or less blood loss. Moreover, it allows a shorter hospital stay. Finally, it offers an identical survival rate compared to open surgery for the treatment of malignant gastric disease [13–16].

A review of the literature found no precise mortality rate for adults for gastric duplication cyst laparoscopic resection, and no reports related to the pathology itself. Only one article concerning children was found that mentioned a mortality rate of 10% associated with surgical treatment [17].

In our opinion, the mortality rate for this pathology remains difficult to assess because of the asymptomatic character and evolution of the duplication cyst, which could include malignant transformation or extension of the cyst to other organs, and which could provoke severe complications such as severe pancreatitis, gastrocolic fistulas, gastric or duodenal stenosis, or biliary communications.

In the present case study, as in the other case reports, patient symptoms were not specific (nausea, vomiting, epigastric pain). Most cases of cysts mentioned in the literature, were less than 5 cm [18].

However, in our case, the cyst diameter was 8×5 cm. This size was probably responsible for symptoms such as vomiting, anorexia, and weight loss in our patient.

Concerning the preoperative work-up, a MRCP was conducted in order to visualize the biliary tract and the pancreatic duct and detect possible communications or compressions [19]. This is rarely described in the literature. In our case study, the gastric duplication was located in the antropyloric region with important cephalic pancreatic and paraduodenal extension.

The chosen treatment for this case matches the gold standard: a complete laparoscopic surgical resection of the lesion without the need of intraoperative gastroscopy or conversion to an open surgery [1,2,7].

Conclusions

In conclusion, the present case study is the first distal gastric duplication cyst with pancreatic and paraduodenal extension reported in the literature that was completely resected using a laparoscopic approach.

Statements

No source of financial support.

The authors declare that they have no competing interests.

References:

1. Deesomsak M, Aswakul P, Junyangdikul P, Prachayakul V: Rare adult gastric duplication cyst mimicking a gastrointestinal stromal tumor. *World J Gastroenterol*, 2013; 19(45): 8445–48
2. Tayar C, Brunetti F, Tantawi B, Fagniez PL: [Laparoscopic treatment of an adult gastric duplication cyst.] *Ann Chirur*, 2003; 128: 105–8 [in French]
3. Etienne S, Pilette C, Prophette B, Serre-Maudet V: [Gastric duplication in the adult: A case report presenting as recurring acute edematous pancreatitis.] *Ann Chirur*, 2002; 127: 641–44
4. Machado MA, Santos VR, Martino RB et al: Laparoscopic resection of gastric duplication: Successful treatment of a rare entity. *Surg Laparosc Endosc Percutan Tech*, 2003; 13(4): 268–70
5. Fisher J, Bland K, Gallery M et al: *Mastery of Surgery*, 5th edition. USA: Ed Lippincott Williams and Wilkins, 2007; 857–71
6. Singh JP, Rajdeo H, Bhuta K, Savino JA: Gastric duplication cyst: Two case reports and review of the literature. *Case Rep Surg*, 2013; 2013: 605059
7. Kim SM, Ha MH, Seo JE et al: Gastric duplication in adult: A report of three cases. *J Gastric Cancer*, 2015; 15(1): 58–63
8. Gupta S, Sleeman D, Alsumait B, Abrams L: Duplication cyst of the antrum: A case report. *Can J Surg*, 1998; 41: 248–50
9. Woolfolk G, McClave S, Jones W et al: Use of endoscopic ultrasound to guide the diagnosis and endoscopic management of a large gastric duplication cyst. *Gastrointest Endosc*, 1998; 47: 76–79
10. Blinder G, Hiller N, Adler S: A double stomach in an adult. *Am J Gastroenterol*, 1999; 94: 1100–2
11. Geller A, Wang KK, DiMango EP: Diagnosis of foregut duplication cysts by endoscopic ultrasound. *Gastroenterology*, 1995; 109: 832–37
12. Takahara T, Torigoe T, Haga H et al: Gastric duplication cyst: Evaluation by endoscopic ultrasonography and magnetic resonance imaging. *J Gastroenterol*, 1996; 31: 420–24
13. Kuraoka K, Nakayama H, Kagawa T et al: Adenocarcinoma arising from a gastric duplication cyst with invasion to the stomach: A case report with literature review. *J Clin Pathol*, 2004; 57(4): 428–31
14. Li Q, Wang J, Zhang G et al: Feasibility and safety comparison of laparoscopy-assisted versus open gastrectomy for advanced gastric carcinoma with D2 lymphadenectomy. *Jpn J Clin Oncol*, 2016 [Epub ahead of print]
15. Cai J, Wei D, Gao CF et al: A prospective randomized study comparing open versus laparoscopy-assisted D2 radical gastrectomy in advanced gastric cancer. *Dig Surg*, 2011; 28: 331–37
16. Yu-Ling H, Hai-Guan L, Jian-Wu Y et al: Laparoscopy-assisted versus open gastrectomy with D2 lymph node dissection for advanced gastric cancer: A meta-analysis. *Int J Clin Exp Med*, 2014; 7(6): 1490–99
17. Carachi R, Azmy A: Foregut duplications. *Pediatr Surg Int*, 2002; 18(5–6): 371–74
18. Chen JJ, Lee HC, Yeung CY et al: Meta-analysis: the clinical features of the duodenal duplication cyst. *J Pediatr Surg*, 2010; 45(8): 1598–606
19. Gossage J, Modarai B, Sahai A, Worth R: 100 Cases in Surgery, Great Britain: Ed Hachette Livre UK Compagny, 100 Cases Series Ed, 2008; 45–47, 65–66

Consent

Written informed consent was obtained from the patient for publication of this case report and any accompanying images.