

## Oncology

## Complete remission with immunotherapy: Case report of a patient with metastatic bladder cancer to the humerus

D. Abdelhakam<sup>a,b,\*,1</sup>, P.R. Young<sup>c</sup>, M.K. Jain<sup>d</sup>, A. Nassar<sup>e</sup>, J.A. Copland<sup>a</sup>, W. Tan<sup>f</sup>

<sup>a</sup> Department of Cancer Biology, Mayo Clinic, Jacksonville, FL, USA

<sup>b</sup> Department of Clinical Pathology, Faculty of Medicine, Ainshams University, Cairo, Egypt

<sup>c</sup> Department of Urology, Mayo Clinic, Jacksonville, FL, USA

<sup>d</sup> Department of Radiology, Mayo Clinic, Jacksonville, FL, USA

<sup>e</sup> Department of Pathology and Laboratory Medicine, Mayo Clinic, Jacksonville, FL, USA

<sup>f</sup> Division of Hematology-Oncology, Mayo Clinic, Jacksonville, FL, USA



## ARTICLE INFO

## Keywords:

Metastatic urothelial cancer  
Cisplatin chemotherapy  
Atezolizumab  
Checkpoint inhibitors  
PD-1/PD-L1

## ABSTRACT

Bladder cancer is the sixth most common malignancy in the United States. Cisplatin combination regimens are first line therapy for patients with metastatic urothelial bladder cancer who are eligible candidates and no treatments have shown to improve outcome compared to chemotherapy for the past 20 years. Significant advances were made in past 2–3 years and the most significant was the introduction of checkpoints inhibitors in bladder cancer treatment. We present a patient diagnosed with metastatic urothelial carcinoma who progressed while on cisplatin/gemcitabine chemotherapy in the form of oligometastasis to the bone. He has achieved a durable complete response with atezolizumab.

## Introduction

The management of urothelial cancer had been challenging due to multiple co-morbidities and the few available treatment options. Over the past few years, significant therapeutic advances were achieved through better understanding of the molecular mechanisms involved in pathogenesis and treatment. We present a case of a male patient diagnosed with metastatic urothelial cancer (mUC) who had developed complete response after treatment with atezolizumab.

## Case presentation

A 53 year old male presented with gross hematuria. Further workup including cysto-urethroscopy, bilateral ureteroscopy, right ureteral tumor biopsy, right ureteral tumor laser ablation, and right ureteral stent placement was done. Pathology showed high-grade transitional cell carcinoma of his right ureteral tumor. He then underwent robotic-assisted laparoscopic right radical nephroureterectomy with right extended pelvic lymphadenectomy, cystoscopy, and stent extraction. Initial oncology consultation was done to discuss adjuvant chemotherapy but surveillance was favored. Three months later, CT scans

showed polypoid filling defect in the right side of the bladder posteriorly and laterally suspicious for recurrent UC. A month later he underwent cysto-urethroscopy, transurethral resection of bladder tumor, left ureteroscopy, left ureteral tumor biopsy and transurethral resection of the prostate. Pathology showed evidence of a recurrence around his right ureteral stump with muscle wall invasion. He received neoadjuvant Cisplatin/Gemcitabine (GC) chemotherapy for 4 cycles. After completion of treatment, a metastatic lesion in the right proximal humerus was detected on his bone scan and a biopsy done was consistent with mUC (Fig. 1). Between December 2016 and February 2017 the patient received 4 cycles of GC chemotherapy. In March 2017, no significant interval change in the biopsy-proven right proximal humeral diaphyseal metastatic lesion was detected by MRI (Fig. 2 a, b). In addition, follow-up bone scans revealed a focus of increased radiotracer activity in the right proximal humerus consistent with patient's known metastatic disease. The patient was started on atezolizumab in April 2017, as second-line treatment. After 4 cycles, restaging scans were done and the patient was considered to have a stable disease with continued response to atezolizumab. April 2019, MR right humerus demonstrated no residual osseous tumor (Fig. 2 c,d). The bone scan showed no suspicious foci of increased radiotracer activity to suggest new osteoblastic skeletal

\* Corresponding author. Department of Cancer Biology, Mayo Clinic, Jacksonville, FL, USA.

E-mail addresses: [dinaam@med.asu.edu](mailto:dinaam@med.asu.edu), [Abdelhakam.dina@mayo.edu](mailto:Abdelhakam.dina@mayo.edu) (D. Abdelhakam).

<sup>1</sup> Present address: 3709 San Pablo Rd s, Jacksonville, Florida 32224 USA.

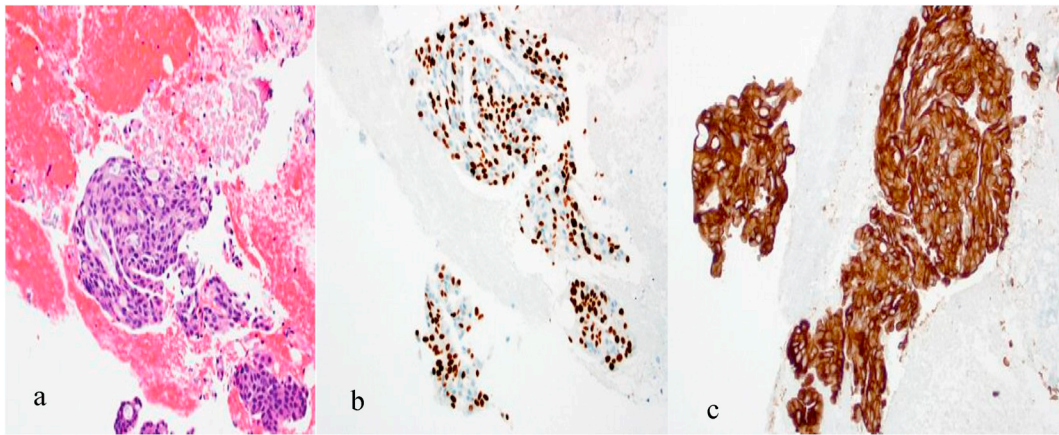


Fig. 1. (a) Bone biopsy showing microscopic features of urothelial cancer, (b) Positive staining p63 urothelial carcinoma, and (c) Positive stain cytokeratin 7.

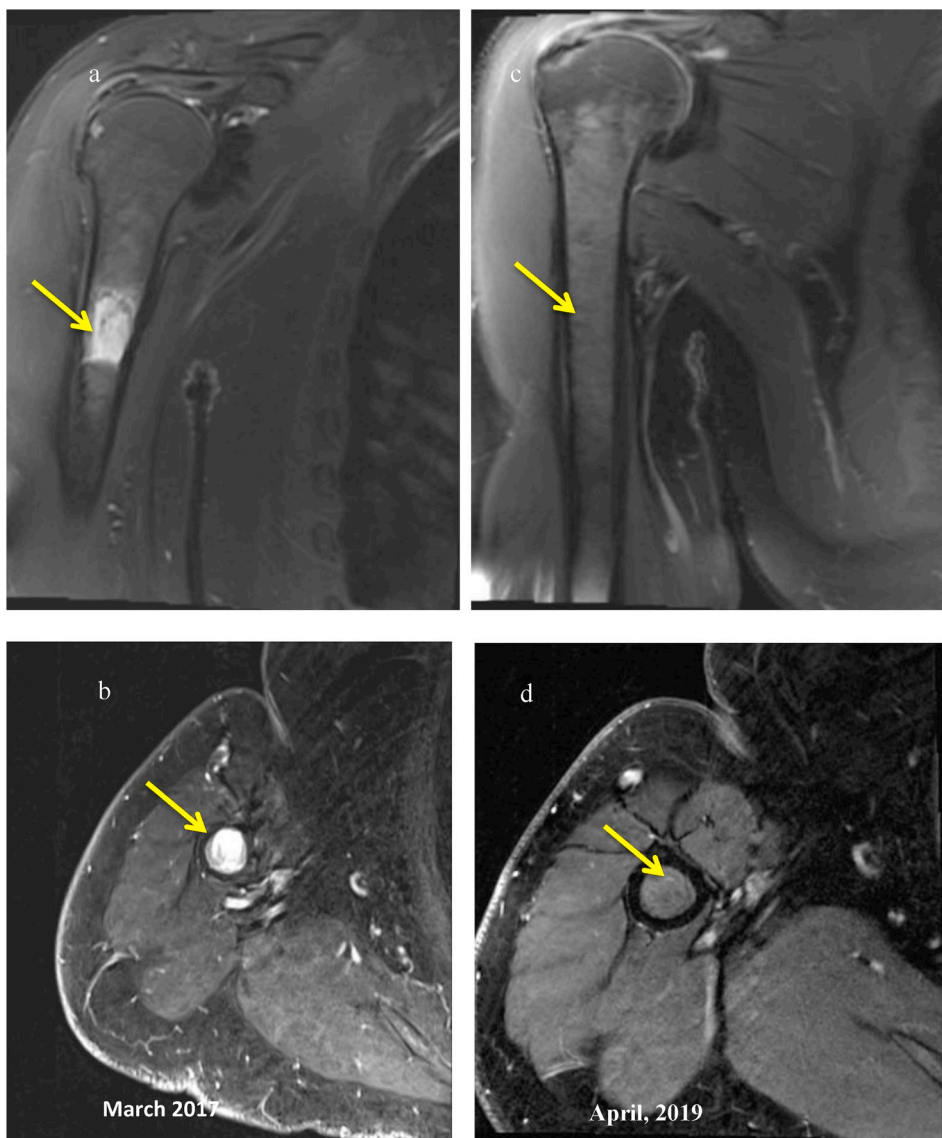
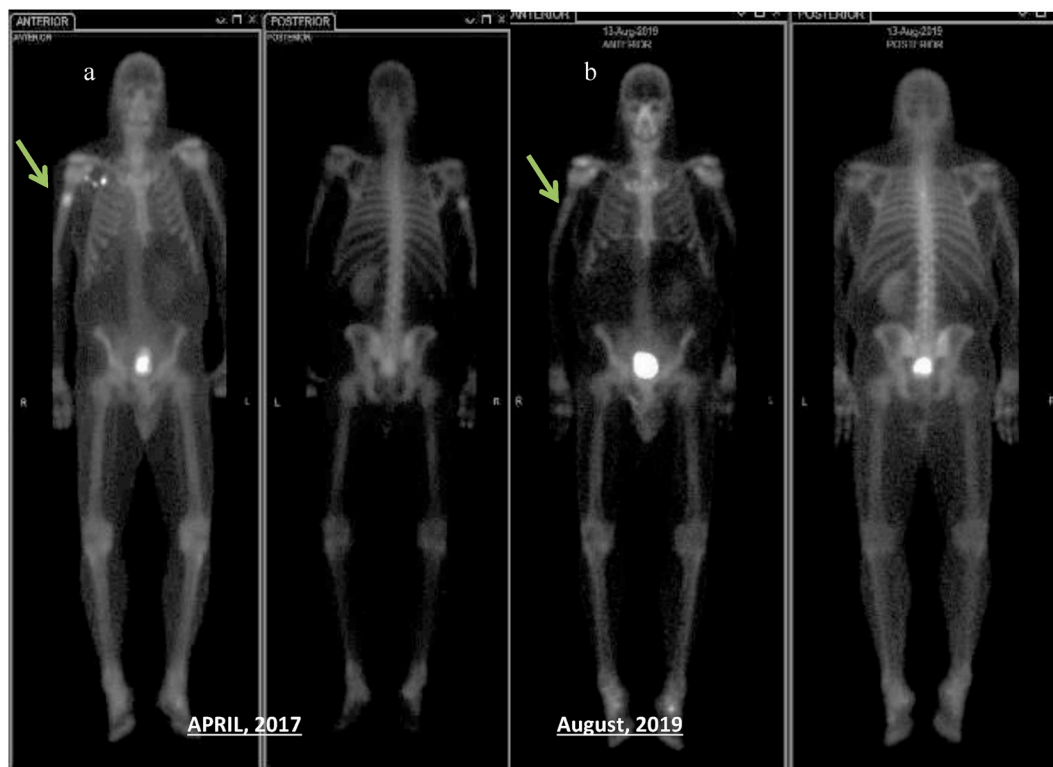


Fig. 2. Coronal T2 weighted images (a) show increased signal in diaphysis of the right humerus, (b) Axial subtraction MR images (post contrast– precontrast T1-weighted images) before treatment (March 2017), (c) shows the resolved lesion after therapy (d) show interval resolution of enhancement after treatment (April 2019).



**Fig. 3.** Whole body anterior and posterior images (a) dated April 2017 shows focal increased radiotracer activity in the right proximal humerus. Image (b) post-treatment whole body anterior and posterior images show resolution of focal increased radiotracer activity in the right proximal humerus.

metastasis. Last dose of atezolizumab was in May 2019 where the patient completed 2 years of treatment. After discussion he decided to discontinue treatment and had to be followed up every 3 months, last time was August 2019 the patient is still in complete remission (Fig. 3).

### Discussion

Cisplatin combination regimens are the standard first line therapy for mUC of the bladder and urinary tract in patients who are cisplatin candidates.<sup>1</sup> The overall response rates (ORRs) are 60–70% with cisplatin-based chemotherapy and an overall survival of 14–15 months.<sup>2</sup> Cisplatin related toxicity makes a large proportion of patients ineligible to this treatment option. The advent of checkpoint inhibition has changed the treatment landscape in this disease; given the significant percentage of patients who have progressive disease on platinum-based therapy or who are cisplatin ineligible.

PD-1/PD-L1 are members of the Ig superfamily. PD-L1/PD-1 interaction leads to T-cell exhaustion and impaired cytotoxic activity, thus inhibiting the immune-response and allowing tumors to grow unchecked. Blocking this inhibitory pathway can help overcome one of the cancer evasive mechanisms allowing for increased immune surveillance.<sup>3</sup> Immunotherapy has emerged as a novel option for patients with various advanced cancers who had limited treatment options and poor outcomes. Checkpoint inhibitors (CPIs) are approved by FDA in several solid tumors. These agents are well tolerated, and may even show durable complete responses (CR) offering a novel therapeutic approach in the treatment of diseases that lacks significant options especially in metastatic settings.

FDA approved five immunotherapy agents for use in the treatment of patients with locally advanced or mUC since May 2016 including atezolizumab, pembrolizumab, nivolumab durvalumab and avelumab. Of these, only atezolizumab and pembrolizumab are approved as first-line therapy for patients ineligible to receive cisplatin chemotherapy, while all the agents are approved in previously treated patients.<sup>4</sup>

Atezolizumab (Tecentriq) is an Fc-engineered, monoclonal antibody that targets PD-L1, inhibiting the interaction with PD-1 and B7.1 receptors. Approval of the drug by FDA in 2016 for use in patients with advanced or mUC of the bladder who progressed during or after a platinum-based regimen based on the results of the Phase (II) IMvigor 210 study, administered as a 1200 mg IV infusion on day 1 of each 3-week cycle. The primary end point of the study was over all response rate which was 14.8% at a median follow-up of 14.4 months. CR was seen in 5.5% (17 patients). Treatment-related adverse effects included fatigue (52%), nausea (25%), anorexia (26%), and constipation (21%). Atezolizumab was also evaluated in the front-line setting for metastatic patients who were cisplatin ineligible and was approved by the FDA in April 2017.<sup>4,5</sup>

Clinical trials involving CPIs in UC included a fraction of patients who achieved durable CR but results from most of the trials are over limited treatment duration. This case presents a patient with mUC who progressed while on cisplatin/gemcitabine chemotherapy in the form of oligometastasis to the bone. The patient manifested an obvious clinical response to atezolizumab in the form of stable disease followed by CR in a two years period of treatment without any major adverse effects and is still in complete remission after discontinuation of treatment.

### Conclusion

Our case is a presentation of mUC in complete remission on immunotherapy, in addition to the promising results of ongoing clinical trials demonstrating that immunotherapy is a realistic hope for patients in different settings of this disease. Moreover, it can be a treatment option offered to patients ineligible to platinum therapy due to its overall acceptable safety profile. Ongoing studies are working on prediction of patient's response, as well combination strategies able to increase the number of responders and to improve clinical outcomes. The treatment of UC is rapidly evolving and immunotherapy revolution has just begun.

## Declaration of competing interest

The authors have stated that they have no conflicts of interest.

## References

1. von der Maase H, Sengelov L, Roberts JT, et al. Long-term survival results of a randomized trial comparing gemcitabine plus cisplatin, with methotrexate, vinblastine, doxorubicin, plus cisplatin in patients with bladder cancer. *J Clin Oncol.* 2005;23(21):4602–4608. <https://doi.org/10.1200/JCO.2005.07.757>.
2. Sternberg CN, de Mulder PH, Schornagel JH, et al. Randomized phase III trial of high-dose-intensity methotrexate, vinblastine, doxorubicin, and cisplatin (MVAC) chemotherapy and recombinant human granulocyte colony-stimulating factor versus classic MVAC in advanced urothelial tract tumors: European Organ. *J Clin Oncol.* 2001;19(10):2638–2646. <https://doi.org/10.1200/JCO.2001.19.10.2638>.
3. Schepisi G, Santoni M, Massari F, et al. Urothelial cancer: inflammatory mediators and implications for immunotherapy. *BioDrugs.* 2016;30(4):263–273. <https://doi.org/10.1007/s40259-016-0176-3>.
4. Dietrich B, Srinivas S. Urothelial carcinoma: the evolving landscape of immunotherapy for patients with advanced disease. *Res Rep Urol.* 2018;10:7–16. <https://doi.org/10.2147/RRU.S125635>.
5. Rosenberg JE, Hoffman-Censits J, Powles T, et al. Atezolizumab in patients with locally advanced and metastatic urothelial carcinoma who have progressed following treatment with platinum-based chemotherapy: a single-arm, multicentre, phase 2 trial. *Lancet.* 2016;387(10031):1909–1920. [https://doi.org/10.1016/S0140-6736\(16\)00561-4](https://doi.org/10.1016/S0140-6736(16)00561-4).