

Cefixime versus prulifloxacin as a prophylactic treatment for prostate biopsy: a randomized study

Michael Samarinas¹, Konstantinos Skriapas¹, Iraklis Mitsogiannis², Stavros Gravas², Anastasios Karatzas¹, Vasileios Tzortzis³

¹General Hospital of Larissa, Department of Urology, Larissa, Greece

²National and Kapodistrian University of Athens, Sismanoglio Hospital, 2nd Department of Urology, Marousi, Greece

³University Hospital of Larissa, Department of Urology, Mezourlo, Larissa, Greece

Citation: Samarinas M, Skriapas K, Mitsogiannis I, Gravas S, Karatzas A, Tzortzis V. Cefixime versus prulifloxacin as a prophylactic treatment for prostate biopsy: a randomized study. Cent European J Urol. 2020; 73: 544-550.

Article history

Submitted: March 30, 2020

Accepted: July 16, 2020

Published online: Oct. 10, 2020

Corresponding author

Michael Samarinas
General Hospital of Larissa
Department of Urology
Tsakalof Street
Larissa, Greece
phone: +30 694 600 6798
mikesamih@hotmail.com

Introduction Urinary tract infections may be a severe complication after prostate biopsy. The aim of our study is to investigate the efficacy of cefixime versus prulifloxacin, as a prophylactic treatment in the era of fluoroquinolone resistance.

Material and methods In this prospective randomized trial, patients were allocated into two groups. In Group A, patients received cefixime 400 mg p.o./day, while in Group B, prulifloxacin 600 mg p.o./day, both for three days, starting the day before procedure. Eligible for the study were men with a high prostate-specific antigen (PSA) and/or a positive rectal examination. Exclusion criteria were allergy to cefixime or fluoroquinolones, low glomerular filtration rate and drug-resistance to these antibiotics. Patients were followed-up for seven days.

Results Finally, 120 patients were divided into 2 groups of 60 patients with a mean age of 68.6 years. A total of 16 (13.3%) men had already undergone another biopsy in the past, while 18 (15%) had received prulifloxacin and 8 (6.67%) cefixime, at least once in the last three months. During follow-up, hospital admission due to a severe urinary tract infection (UTI) was required in 2 of 60 (1.3%) and 1 of 60 (1.67%) patients from Group B and A respectively. The bacterial specimens detected in those urine cultures were resistant to prulifloxacin or cefixime. Among the remaining 117 patients (97.5%), nobody presented with a UTI.

Conclusions Prophylactic cefixime could be suggested as effective in preventing severe UTIs after prostate biopsy in the era of high bacterial resistance to fluoroquinolones.

Key Words: prostate biopsy ◊ urinary tract infection ◊ antibiotics ◊ fluoroquinolone

INTRODUCTION

Transrectal ultrasound (TRUS) guided biopsy of the prostate, introduced by Hodge et al. [1], is a frequently performed urological procedure in daily practice. It is generally considered a safe modality, nonetheless complications, such as anxiety, pain and anal discomfort, haemospermia, rectal bleeding and urinary retention may occur [2, 3]. Bacterial sepsis is the most severe complication requiring hospitalization, supportive care and intravenous antibiotics. Chemopro-

phylaxis, using various antibiotic protocols, has been proven to reduce prostate infection following transrectal biopsy [3, 4, 5]. Because of their high bioavailability, broad spectrum coverage and high concentrations within the prostate, fluoroquinolones (FQs) are effective in decreasing the incidence of post-biopsy infections and are therefore considered the drugs of choice. However, no consensus has been reached with regard to the optimal prophylactic scheme duration [6, 7]. On the other hand, several studies have demonstrated that the widespread use of ciprofloxacin is

associated with the emergence of resistant pathogens; this in turn is considered to be one of the main factors responsible for the recent increase in the incidence of post-transrectal biopsy infections [4, 7–11]. Given the constant increase in *Escherichia coli* strains which are resistant to ciprofloxacin, novel approaches for TRUS-guided biopsy antibacterial prophylaxis are necessary and are currently under thorough investigation [12]. Prulifloxacin, an oral fluoroquinolone which is the lipophilic pro-drug of ulifloxacin, has been reported to possess a broader antimicrobial spectrum in vitro than that of ciprofloxacin against several Gram-positive and Gram-negative bacteria such as *E. coli*, *Proteus mirabilis*, *Providencia* spp., *Klebsiella* spp., *Haemophilus* spp., *Moraxella catarrhalis* and *Morganella* spp. [13, 14]. Cefixime is an orally administered third-generation cephalosporin which, for several years, was considered to be an ideal alternative for patients with acute pyelonephritis switching from intravenous to oral therapy [15].

The aim of our study was to compare the efficacy and safety of cefixime with that of prulifloxacin in patients undergoing TRUS-guided prostate biopsy and to determine whether cefixime might serve as an alternative to prulifloxacin in the era of high fluoroquinolone-resistance.

MATERIAL AND METHODS

This is a prospective randomized controlled trial, including patients undergoing transrectal ultrasound guided biopsy of the prostate, taking place throughout 2019. All of the patients had an elevated serum prostate-specific antigen (PSA) and/or abnormal digital rectal examination (DRE) and completed an informed consent form. Patients were allocated into two groups using a research randomizer (www.randomizer.org). The sample size has been estimated according to a specific calculator (DSS Research: Statistical Power Calculator, <https://www.dssresearch.com>), using an alpha error level of 5%. The procedure included an initial application of local anaesthetic 10 minutes before the biopsy, as well as a rectal cleansing with povidone-iodine the night before. Twelve systematic biopsy cores were obtained. Regarding patients with a prior biopsy, all previous biopsies had been performed in our centre under the same methodological process and none of the patients had undergone a previous biopsy in the 6 months preceding the study. Participants in Group A received a prophylactic three-day regimen of oral cefixime 400 mg once daily, whereas those in Group B received a three-day regimen of oral prulifloxacin 600 mg once daily. Prophylaxis was initiated a day before the biopsy. Exclusion criteria were known

allergy or drug-resistance to fluoroquinolones or cefixime and low glomerular filtration rate (GFR). Additionally, subjects with a known factor of a possible immunosuppression, such as diabetes mellitus, an indwelling catheter or ureteral stent and those with a medical history of repetitive urinary tract infections (UTIs) or a chronic prostate inflammation were regarded as not eligible for the study. Patients were followed up for 7 days post-biopsy, obtaining a urine culture in the final day and all complications were recorded.

A severe UTI was defined as occurrence of fever, chills, leukocytosis or hemodynamic instability requiring hospital admission and intravenous administration of antibiotics. Criteria for patients with sepsis were based on the Third International Consensus Definitions for Sepsis and Septic Shock, using the quick Sequential (sepsis-related) Organ Failure Assessment (qSOFA) scale for a possible evaluation. Patients were hospitalized in our urological department and administered intravenous broad-spectrum antibiotics for at least 7 days with the support of the intensive care unit if needed.

The study was approved by both the Ethical Committee of our Hospital, and the Australian and New Zealand Clinical Trial Registry (Trial Id: ACTRN12616001344482). All participants were fully aware of the aim of the study.

The population data were tested for a parametric basis, following the curve of Gauss-Laplace, proven to be a non-parametric one. Data were analyzed using the statistical software SPSS v. 21.0 and the main analysis was performed by Wilcoxon and t-test statistical methods for a non-parametric sample. A p value less than 0.05 was regarded as statistically significant.

RESULTS

A total of 128 patients were regarded as eligible for the study, 8 of whom refused to participate. Of the remaining 120 patients, 60 were randomized into Group A and 60 into Group B (Figure 1). The mean age of patients was 68.6 years (range: 51–87) and the mean PSA was 13.8 ng/ml (range: 5.08–100). There was no statistically significant difference in the mean age and the mean PSA level of patients between the two groups (Group A: 65.6 years and 15.8 ng/ml, Group B: 69.3 years and 11.9 ng/ml) (Table 1). Sixteen patients (13.3%) had already undergone another biopsy in the past (Group A: 3, Group B: 13). In addition, 8 patients in Group A (6.67%) and 18 patients of Group B (15%) had already received cefixime or prulifloxacin respectively, at least once during the last three months. Dur-



CONSORT

TRANSPARENT REPORTING of TRIALS

CONSORT Flow Diagram

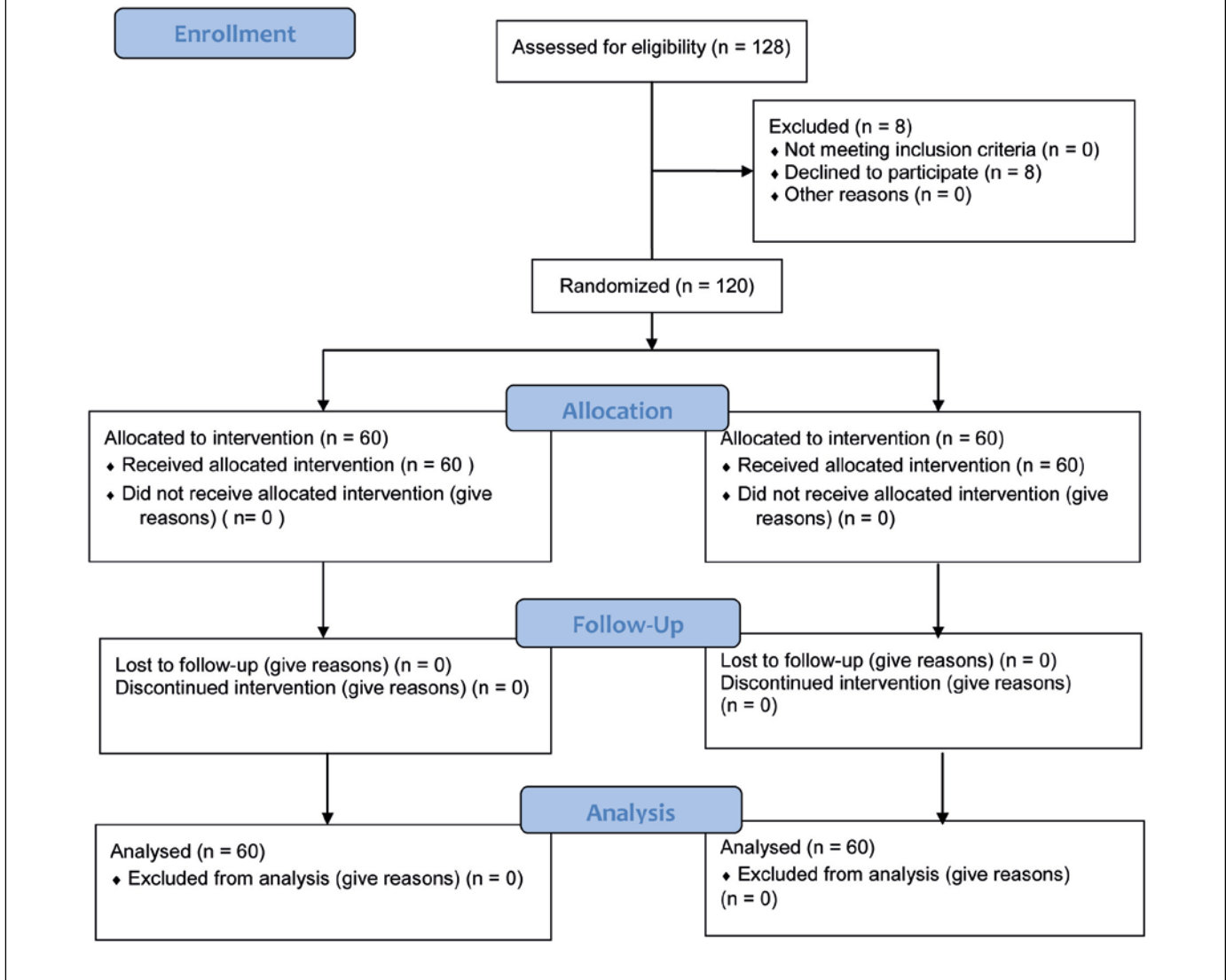


Figure 1. CONSORT Flow Diagram.

ing the follow-up period, hospital admission due to a severe urinary tract infection with fever $>38^{\circ}\text{C}$, lower urinary tract symptoms and hematuria, was required for a total of 3 patients (2.78%) (Group A: 1, Group B: 2). Urine and blood cultures obtained from these patients demonstrated septicaemia to be due to cefixime-resistant or prulifloxacin-resistant *E. coli* isolates, while a qSOFA scale evaluation showed that

there was no need for an intensive care unit hospitalization. Two of these patients (one in each group) had undergone prostate biopsy 6 months before but had to be re-biopsied due to a re-elevated PSA or atypical small acinar proliferation (ASAP). Interestingly, all 3 patients who developed a UTI had received these medications for various reasons over the last three months. The difference in the appearance of a severe

Table 1. Baseline characteristics for the randomized patients

	Age (years) (mean, range)	PSA (ng/ml) (mean, range)	Previous biopsy	Previous antibiotics
Group A (cefixime)	65.6 51–85	15.8 8.1–100	3	8
Group B (prulifloxacin)	69.3 55–87	11.9 5.08–85	13	18
p value	0.744	0.612	n/a	n/a

PSA – prostate-specific antigen

UTI between the two groups was not statistically significant ($p = 0.965$), but it can be assumed that a medical history of receiving cefixime and prulifloxacin or a previous biopsy could be suggested as risk factors for a possible post-performance severe UTI (OR 7.0, 95%CI 0.2548 to 192.2727 and OR 5.0, 95% CI 0.1705 to 146.6506 respectively).

In the remaining 117 patients, no post-biopsy UTI had been recorded, however, minor complications were observed, which did not differ significantly between the two groups with a p value over 0.05 for each comparison (Table 2).

DISCUSSION

TRUS-guided biopsy of the prostate is a common procedure performed on an outpatient basis and antibiotic prophylaxis with various drug protocols to reduce the biopsy-related risk of genitourinary tract infection is a well-established and indicated practice [16]. Several professional organizations recommend routine antibiotic prophylaxis for TRUS-guided prostate biopsy [17]. Recent research suggests that obtaining rectal cultures, in order to identify the Enterobacteriaceae resistant to fluoroquinolones, could be effective so as to select an appropriate prophylaxis [18]. Additionally, in order to acquire the cleanest possible way through the rectum, AUA guidelines and a Cochrane Database systematic review have investigated the use of enema alone or with antibiotics before the prostatic biopsy [17, 19]. The rate of emergency hospital admissions following prostate biopsy varies in the literature from 0.8 to 6.9% [2, 20, 21]. Currently, there is no consensus on the optimal duration of antibiotic prophylaxis for TRUS-guided biopsy with several investigators suggesting a scheme of over 24 hours [22]. According to the EAU guidelines, the one-day scheme is recommended while regional and local antibiotic resistance patterns should be considered when deciding on the choice of antibiotic. We follow a three-day protocol due to our local conditions of antibiotic resistance [23]. Cefixime is a third-generation cephalosporin, with the special characteristic of oral use that allows

Table 2. Complications after prostate biopsy

	Group A (cefixime)	Group B (prulifloxacin)	p value
Major			
Severe UTI	1 (1.67%)	2 (3.3%)	0.965
Minor			
Low fever (<37.5°C) without LUTS	6 (10%)	7 (11.7%)	0.317
Rectal bleeding, recovered in <24 hours	4 (6.7%)	2 (3.3%)	0.157
Hematuria, recovered in <24 hours	9 (15%)	5 (8.3%)	0.146
Mild to moderate LUTS	14 (23.3%)	10 (16.7%)	0.146
Severe LUTS, recovered in <24 h hours	2 (3.3%)	1 (1.7%)	0.965

LUTS – lower urinary tract symptoms, UTI – urinary tract infection

a more comfortable way of treatment administration. Considering its pharmacokinetics, it is known that about 20% of the drug is excreted by the kidneys. Consequently, this antibiotic may be a good alternative for the treatment of acute pyelonephritis and prostatitis [24].

Fluoroquinolones have been the most commonly used antimicrobial agents for antibiotic prophylaxis prior to TRUS-guided prostate biopsy for many years, due to their broad-spectrum activity against most Gram-negative microorganisms [25]. The efficacy and safety of fluoroquinolones has been demonstrated in several randomized controlled studies [26, 27, 28], nonetheless, fluoroquinolone-resistant *E. coli* strains are constantly increasing. As men undergoing TRUS-guided prostate biopsy have a 2.26-fold risk for hospitalization [2], the need for developing novel approaches to prevent biopsy-related UTIs becomes mandatory. Until now, several alternative prophylactic regimens have been tested, including fluoroquinolones and other treatments, in order to avoid urinary tract infections and sepsis after prostate biopsy [19, 29].

In the present study, we focused on the role of cefixime in this field, as it remains the only third generation cephalosporin without the need of intravenous administration and could be suggested as an effective

tive alternative against Enterobacteriaceae in the urine, particularly in case of ciprofloxacin-resistance pathogens [30].

In a study by Minamida et al., fecal cultures obtained 1 month prior to prostate biopsy revealed that the incidence of fluoroquinolone-resistant *E. coli* was 13%; thirty-one percent of these patients developed acute bacterial prostatitis compared to none of those with fluoroquinolone-sensitive strains [31]. Hence, antibiotic prophylaxis for transrectal biopsy could theoretically be based on pre-biopsy stool cultures; however, this is not a common practice worldwide. Similarly, in our study, severe UTI occurred only in patients with either cefixime or prulifloxacin resistant strains; although the incidence was lower (2.5%). These findings may imply that prior use of antibiotics may be a risk factor for post-biopsy severe UTI and/or sepsis, potentially through the development of resistant strains. Risk factors for fluoroquinolone-resistant strains seem to be a previous TRUS-guided biopsy, current indwelling catheter, urogenital infection, international travel and hospital admission during the past 6 months. In our study, 2 out of 3 patients who developed severe UTI had undergone a prostate biopsy in the past and this is in accordance to the results of a study by Shigehara et al., who reported significantly increased incidence of post-biopsy prostatitis in patients undergoing re-biopsy, compared to those having biopsy for the first time. This was deemed to be due to the development of fluoroquinolone-resistant strains following administration of levofloxacin [32].

In addition to prior antibiotic therapy with fluoroquinolones appearing to be a well-established factor for a UTI associated with a prostatic biopsy, there is evidence that a pre-existence of colonized microorganisms in the prostate has a possible role, especially in those patients with biopsy-related local inflammation. In the study by Sfanos et al., where prostatic specimens have been obtained after transurethral prostatectomy, most of the samples contained bacterial DNA, without those microorganisms to be 'culturable' [33]. In another study, *Propionibacterium acnes*, a prominent member of the skin microbiota, was found to invade prostate epithelial cells and was detectable intracellularly 7 days post prostatic infection. Researchers concluded that this invasion may be associated with and persistence of local infection and chronic prostatic inflammation. However, the contribution of the human microbiota to prostatic disease is still poorly understood [34]. Also, strategies for minimizing antimicrobial resistance should be considered evaluating the resistance mechanism, microorganisms, antimicrobial drugs, host and context [35].

Apart from fluoroquinolones and cephalosporins,

there are studies suggesting other alternatives as prophylactic treatment for prostate biopsy. More specifically, and despite that there are only a few data in the literature about the preventive role of fosfomycin in the urological procedures, some authors investigated its efficacy as a prophylactic treatment before prostatic biopsy, suggesting fosfomycin as an effective alternative [36]. Additionally, a post-biopsy infection with bacteria resistant to cephalosporins, such as *Enterococcus faecalis*, has to be considered with ampicillin and gentamycin suggested as appropriate treatments [37].

However, acute prostatitis is not the only kind of UTI that may appear as a complication after prostatic biopsy, as acute pyelonephritis could occur through the infection spreading to the upper urinary tract and kidneys. In these cases, antimicrobial resistance seems to also be an issue, with fluoroquinolones becoming less effective than more wide-spectrum antibiotics, such as carbapenems, linezolid or daptomycin [38, 39].

Considering the side effects of the antibiotics used in our study, cefixime could cause stomach pain, diarrhea, nausea, headache, or dizziness, while prulifloxacin may induce abnormal liver function tests, stomach pain, nausea, and diarrhea. In our study, there have been no references for any kind of these side effects. The selection of prulifloxacin instead of any other fluoroquinolone has been made due to its routine use as a prophylactic treatment for prostate biopsy in our country and because the comparable price to cefixime.

The main limitation of our study is that the use of prulifloxacin and cefixime as comparative prophylactic antibiotics for prostatic biopsies has very few literature references to our knowledge and the values assumed for the sample calculation promoted a rather smaller sample than a maybe ideal. However, this is a prospective randomized controlled trial with results that may show a preliminary trend for future research with bigger recruitment.

In our study, investigating cefixime for prostate biopsy prophylaxis, this antibiotic proved to be safe and associated with a low rate of post-biopsy urinary tract infections. It can, therefore, serve as another effective prophylactic measure in this field.

CONCLUSIONS

In the era of emerging *E. coli* resistance to fluoroquinolones, our study results suggest cefixime to be an effective and safe alternative for TRUS-guided biopsy prophylaxis.

CONFLICTS OF INTEREST

The authors declare no conflicts of interest.

References

- Hodge KK, McNeal JE, Terris MK, Stamey TA. Random systematic versus directed ultrasound guided transrectal core biopsies of the prostate. *J Urol.* 1989; 142: 71-75.
- Loeb S, Carter HB, Berndt SI, Ricker W, Schaeffer EM. Complications after prostate biopsy: data from SEER-Medicine. *J Urol.* 2011; 186: 1830-1834.
- Samarinas M, Dimitropoulos K, Zachos I, et al. A single dose of meropenem is superior to ciprofloxacin in preventing infections after transrectal ultrasound-guided prostate biopsies in the era of quinolone resistance. *World J Urol.* 2016; 34:1555-1559.
- Kehinde EO, Al-Maghrebi M, Sheikh M, Anim JT. Combined ciprofloxacin and amikacin prophylaxis in the prevention of septicemia after transrectal ultrasound guided biopsy of the prostate. *J Urol.* 2013; 189: 911-915.
- Lorber G, Benenson S, Rosenberg S, Gofrit ON, Pode D. A single dose of 240 mg gentamicin during transrectal prostate biopsy significantly reduces septic complications. *Urology.* 2013; 82: 998-982.
- Wagenlehner FM, van Oostrum E, Tenke P, et al. Infective complications after prostate biopsy: outcome of the Global Prevalence Study of Infections in Urology (GPIU) 2010 and 2011, a prospective multinational multicenter prostate biopsy study. *Eur Urol.* 2013; 63: 521-527.
- Carignan A, Roussy JF, Lapointe V, et al. Increasing risk of infectious complications after transrectal ultrasound-guided prostate biopsies: time to reassess antimicrobial prophylaxis? *Eur Urol.* 2012; 62: 453-459.
- Al-Hasan MN, Lahr BD, Eckel-Passow JE, Baddour LM. Antimicrobial resistance trends of *Escherichia coli* bloodstream isolates: a population-based study, 1998-2007. *J Antimicrob Chemother.* 2009; 64: 169-174.
- Peralta G, Sánchez MB, Garrido JC, et al. Impact of antibiotic resistance and of adequate empirical antibiotic treatment in the prognosis of patients with *Escherichia coli* bacteraemia. *J Antimicrob Chemother.* 2007; 60: 855-863.
- Williamson DA, Roberts SA, Paterson DL, et al. *Escherichia coli* bloodstream infection after transrectal ultrasound-guided prostate biopsy: implications of fluoroquinolone-resistant sequence type 131 as a major causative pathogen. *Clin Infect Dis.* 54: 1406-1412.
- Hernandez-Graulau JM. Sepsis due to fluoroquinolone-resistant *Escherichia coli* after transrectal ultrasound-guided prostate needle biopsy. *Urology.* 74: 338-339.
- Gajdács M, Ábrók M, Lázár A, Burián K. Comparative Epidemiology and Resistance Trends of Common Urinary Pathogens in a Tertiary-Care Hospital: A 10-Year Surveillance Study. *Medicina.* 2019, 55: 356.
- Keam SJ, Perry CM. Prulifloxacin. *Drugs.* 2004; 64: 2221-2234.
- Prats G, Roig C, Miro E, Navarro F, Mirelis B. In vitro activity of the active metabolite of prulifloxacin (AF 3013) compared with six other fluoroquinolones. *Eur J Clin Microbiol Infect Dis.* 2002; 21: 328-334.
- Hamilton-Miller JM. Overview of cefixime use in community-acquired infections. *Clin Microbiol Infect.* 2000; 6 (Suppl 3):79-81.
- Bootsma AMJ, Laguna Pes MP, Geerlings SE, Goossens A. Antibiotic prophylaxis in urologic procedures: a systematic review. *Eur Urol.* 2008; 54: 1270-1286.
- American Urological Association. Best practice policy statement on urologic surgery antimicrobial prophylaxis. American Urological Association Web site. <https://www.auanet.org/common/pdf/education/clinical-guidance/Antimicrobial-Prophylaxis.pdf>. Accessed February 22, 2013.
- Duplessis CA, Bavaro M, Simons MP, et al. Rectal cultures before transrectal ultrasound-guided prostate biopsy reduce post-prostatic biopsy infection rates. *Urology.* 2012; 79: 556-563.
- Zani EL, Clark OA, Rodrigues Netto N Jr. Antibiotic prophylaxis for transrectal prostate biopsy. *Cochrane Database Syst Rev.* 2011; 5: CD006576.
- Loeb S, van Den HS, Zhu X, Bangma CH, Schröder FH, Roobol MJ. Infectious complications and hospital admissions after prostate biopsy in a European randomized trial. *Eur Urol.* 2012; 61: 1110-1114.
- Ganeswaran D, Sweeney C, Yousif F, Lang S, Goodman C, Nabi G. Population-based linkage of health records to detect urological complications and hospitalization following transrectal ultrasound-guided biopsies in men suspected of prostate cancer. *World J Urol.* 2014; 32: 309-315.
- Petteffi L, Toniazzo GP, Sander GB, Stein AC, Koff WJ. Efficiency of short and long term antimicrobial therapy in transrectal ultrasound-guided prostate biopsies. *Int Braz J Urol.* 28: 526-532.
- Chaniotaki S, Giakouppi P, Panagiotakos D, Kozanitou M, Petrikos G, Avlami A. Quinolone resistance among *Escherichia coli* strains from community-acquired urinary tract infections in Greece. *Clin Microbiol Infect.* 2004; 10: 75-78.
- Naber KG. Cefixime in Urinary Tract Infections. (Specific Studies and Literature Review). *Infection.* 1990; (18 Suppl 3): S132-139.
- Gajdács M, Batori Z, Ábrók M, et al. Characterization of Resistance in Gram-Negative Urinary Isolates Using Existing and Novel Indicators of Clinical Relevance: A 10-Year Data Analysis. *Life (Basel).* 2020; 10: 16.
- Crawford ED, Haynes Jr AL, Story MW, Borden TA. Prevention of urinary tract infection and sepsis following transrectal prostatic biopsy. *J Urol.* 1982; 127: 449-451.
- Kapoor DA, Klimberg IW, Malek GH, et al. Single-dose oral ciprofloxacin versus placebo for prophylaxis during transrectal prostate biopsy. *Urology.* 1998; 52: 552-558.
- Aron M, Rajeev TP, Gupta NP. Antibiotic prophylaxis for transrectal needle biopsy of the prostate: a randomized controlled study. *BJU Int.* 2000; 85: 682-685.
- Yaghi MD, Kehinde EO. Oral antibiotics in trans-rectal prostate biopsy and its efficacy to reduce infectious complications: Systematic review. *Urol Ann.* 2015; 7: 417-427.
- Pistiki A, Tsaganos T, Galani I, Evangelos J, Giamarellos-Bourboulis EJ. In Vitro Activity of Oral Cephalosporins (Cefprozil and Cefixime) Against Ciprofloxacin-Resistant Enterobacteriaceae from Community-Acquired Urinary-Tract Infections. *Infect Dis Ther.* 2015; 4:425-432.
- Minamida S, Satoh T, Tabata K, et al. Prevalence of fluoroquinolone-resistant *Escherichia coli* before and incidence of acute bacterial prostatitis after prostate biopsy. *Urology.* 2011; 78: 1235-1239.

32. Shigehara K, Miyagi T, Nakashima T, Shimamura M. Acute bacterial prostatitis after transrectal prostate needle biopsy: clinical analysis. *J Infect Chemother.* 2008; 14: 40-43.
33. Sfanos KS, Sauvageot J, Fedor HL, James DD, De Marzo AM, Isaacs WB. A molecular analysis of prokaryotic and viral DNA sequences in prostate tissue from patients with prostate cancer indicates the presence of multiple and diverse microorganisms. *Prostate.* 2008; 68: 306-320.
34. Mak TN, Fischer N, Laube B, et al. *Propionibacterium acnes* host cell tropism contributes to vimentin-mediated invasion and induction of inflammation. *Cell Microbiol.* 2012; 14: 1720-1733.
35. Holmes AH, Moore LS, Sundsfjord A, et al. Understanding the mechanisms and drivers of antimicrobial resistance. *Lancet.* 2016; 387: 176-187.
36. Ongün S, Aslan G, Avkan-Oguz V. The effectiveness of single-dose fosfomycin as antimicrobial prophylaxis for patients undergoing transrectal ultrasound-guided biopsy of the prostate. *Urol Int.* 2012; 89: 439-444.
37. Seo Y, Lee G. New Bacterial Infection in the Prostate after Transrectal Prostate Biopsy. *J Korean Med Sci.* 2018; 33: e126.
38. Pasiechnikov S, Buchok O, Sheremeta R, Banyra O. Empirical treatment in patients with acute obstructive pyelonephritis. *Infect Disord Drug Targets.* 2015; 15: 163-170.
39. Lee HN, Yoon H. Management of Antibiotic-Resistant Acute Pyelonephritis. *Urogenit Tract Infect.* 2017; 12: 95-102. ■