

Available online at www.sciencedirect.com

ScienceDirect

journal homepage: www.elsevier.com/locate/radcr

Case Report

Primary true enterolithiasis: A rare cause of acute small bowel obstruction ☆

Abdelhamid Jadib, MD*, Houria Tabakh, MD, Lamiaa Chahidi El Ouazzani, MD, Keltoum Boumlik, MD, Romaissaa Boutachali, MD, Abdellatif Siwane, MD, Najwa Touil, MD, Omar Kacimi, MD, Nabil Chikhaoui, MD

Emergency Radiology Division, Faculty of Medicine and Pharmacy of Casablanca, Ibn Rochd University Hospital, 1, quartiers des hôpitaux, Casablanca, 20100, Morocco

ARTICLE INFO

Article history:

Received 7 November 2021

Accepted 12 November 2021

Keywords:

Primary true enterolithiasis

Idiopathic

Acute small bowel obstruction

Imaging

ABSTRACT

Enterolithiasis is an uncommon medical condition. It's defined by the formation of gastrointestinal concretion in the setting of intestinal stasis. Enteroliths are typically incidentally discovered during imaging and are a rare cause of acute small bowel obstruction. We report the case of acute small bowel obstruction, secondary to primary true enterolithiasis, in a 73-year-old male, with unremarkable medical history. He presented with clinical features in keeping with acute small bowel obstruction, for 2 days. An abdominal contrast-enhanced CT scan suggested a small bowel obstruction caused by a 32mm diameter enterolith located in the terminal ileum. The surgical management was successful and consisted of the removal of the enterolith after enterotomy.

© 2021 The Authors. Published by Elsevier Inc. on behalf of University of Washington.

This is an open access article under the CC BY-NC-ND license

(<http://creativecommons.org/licenses/by-nc-nd/4.0/>)

Introduction

Enterolithiasis correspond to the presence of stone concretions in the gastrointestinal tract. It is an important but relatively uncommon clinical condition. Primary enteroliths arise in areas of intestinal stasis, such as in the setting of diverticular disease, surgical enteroanastomosis, blind pouches, and intestinal stenosis or strictures seen in infectious or inflammatory bowel diseases. Presentation is often nonspecific but

typically includes “tumbling” abdominal pain, nausea, and vomiting related to the bowel obstruction [1].

Enteroliths are typically incidentally discovered during imaging and are a rare cause of small bowel obstruction [1,2].

We report the case of acute small bowel obstruction, secondary to true primary enterolithiasis, in a 73-year-old male, with unremarkable medical history. An abdominal contrast-enhanced CT scan suggested the diagnosis. The surgical management was successful and consisted of the removal of the enterolith after enterotomy.

☆ Competing Interests: The authors have declared that no competing interests exist.

* Corresponding author. A. Jadib.

E-mail address: jadibabdelhamid@gmail.com (A. Jadib).

<https://doi.org/10.1016/j.radcr.2021.11.032>

1930-0433/© 2021 The Authors. Published by Elsevier Inc. on behalf of University of Washington. This is an open access article under the CC BY-NC-ND license (<http://creativecommons.org/licenses/by-nc-nd/4.0/>)

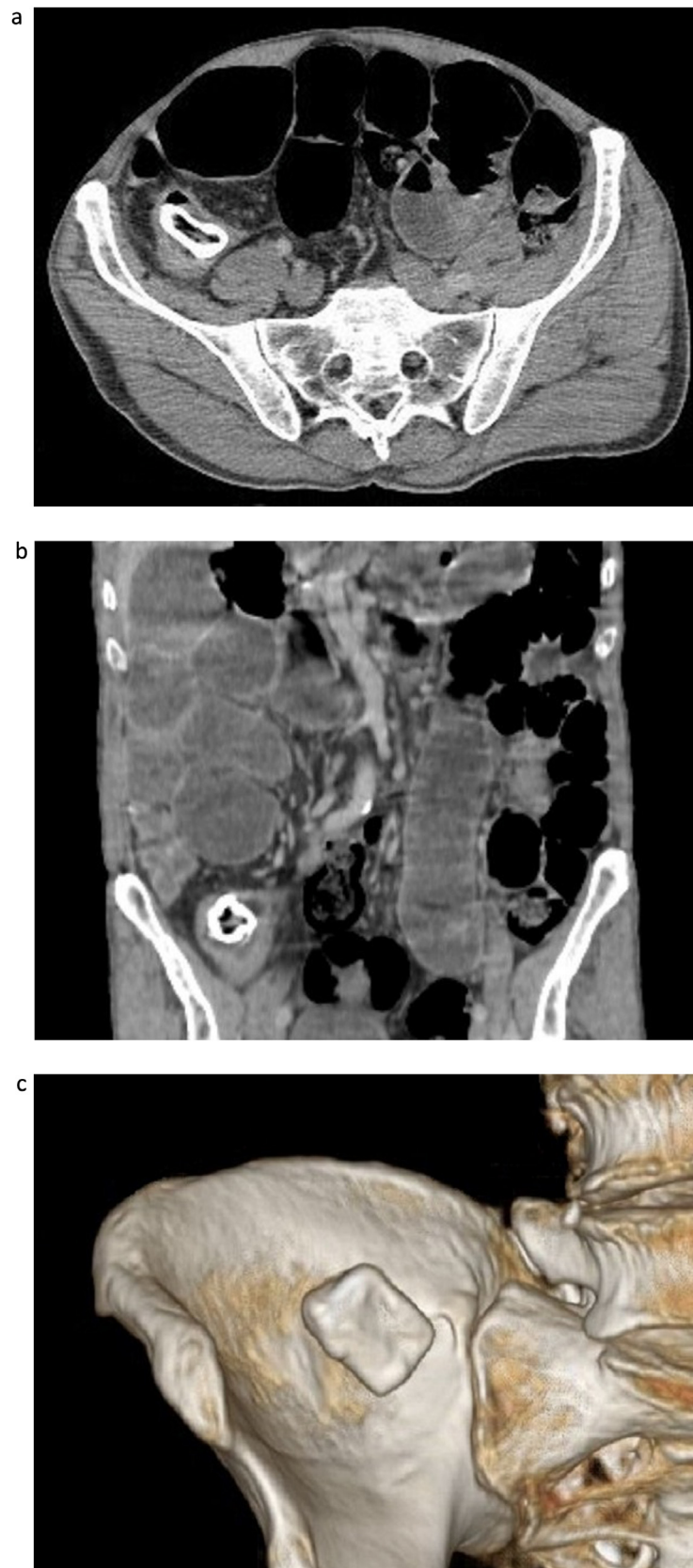


Fig. 1 – Abdominal contrast-enhanced CT scan, in the axial (A) and coronal (B) planes, with volume rendering (C), showing dilated small bowel loops proximal to intraluminal rectangular structure, peripherally calcified with a hypodense core, impacted in the distal ileum, in keeping with small bowel obstruction secondary to calcium salts enterolith.

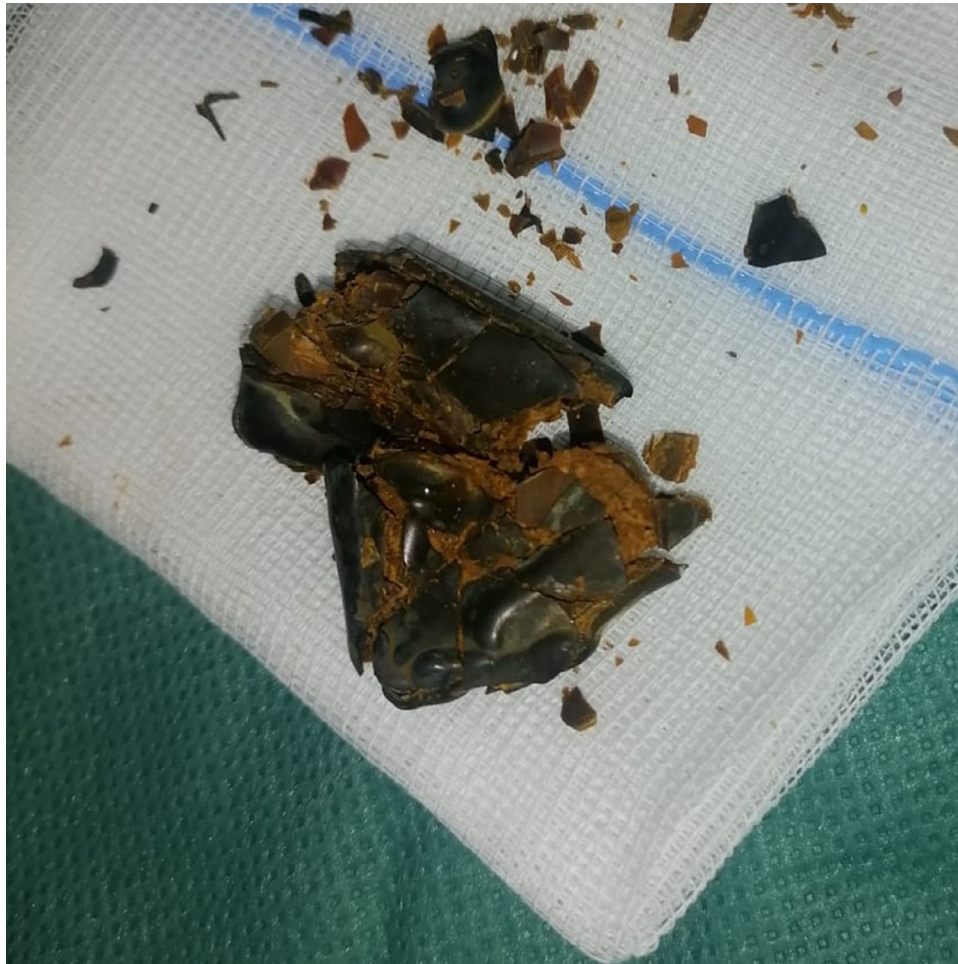

Fig. 2 – Photography of the fragmented enterolith.

Case presentation

A 73-year-old male presented to the surgical admissions unit with a 3-day history of worsening abdominal pain and distension, nausea, and vomiting. He had not passed flatus for 2 days. His past medical history was unremarkable, particularly no history of previous abdominal surgery.

Abdominal distension and tenderness were present on physical examination. All serum blood results were in the normal range.

Abdominal contrast-enhanced CT scan showed diffuse fluid distention of the small bowel loops proximal to a 32 mm large intraluminal rectangular structure, peripherally calcified with a hypodense core, impacted in the distal ileum, in keeping with acute small bowel obstruction secondary to calcium salts true primary enterolith (Fig. 1).

A laparotomy was indicated since the size of the enterolith was greater than 20mm. Intra-operatively, an attempt to digital fragmentation of the enterolith and manual milk the smaller parts into the colon was unsuccessful. Therefore, an enterotomy was performed to remove the enterolith (Fig. 2). The postoperative period was uneventful.

The enterolithiasis was termed idiopathic because no underlying cause was identified on contrast-enhanced CT scan and laparotomy.

Discussion

The first imaging diagnosis of enteroliths was in 1915 by Pfahler and Stamm. They are typically incidentally discovered during imaging [2]. The reported prevalence of primary and secondary enterolithiasis range widely from 0.3–10% [1].

True primary enteroliths are formed from substances found in chyme under normal alimentary conditions. They are subdivided into the choleic acid and calcium salts enteroliths [3].

Choleic acid enteroliths require lower pH and are typically found in the proximal small bowel. On the other hand, calcium salts primary enteroliths require an alkaline pH to precipitate and thus are most often formed in the terminal ileum [1].

False primary enteroliths are formed from insoluble foreign substances in the bowel, secondary to exogenous particle ingestion such as bezoars. Mixed concretions may result from

external calcification of false enteroliths in the distal small bowel [3].

Secondary enteroliths are formed outside the gastrointestinal tract and then migrate into the bowel, causing an obstruction. They include gallstone or renal stone ileus [1].

Numerous factors predisposing to the development of primary enterolithiasis includes congenital and acquired diverticular diseases, stricturing or stenosing diseases such as tuberculosis and Crohn's disease, surgical entero-anastomoses, afferent loops, blind pouches, radiation or eosinophilic enteritis, mucosal diaphragmatic disease, intestinal duplication, fistula, malignancy, intra-abdominal adhesions, external compressions, incarcerated hernias, intestinal aganglionosis, intestinal amoebiasis, and ischemic enteritis [1].

Enterolithiasis manifest clinically with abdominal pains, distention, nausea, and vomiting of occasionally sudden but often fluctuating subacute nature which occurs as a result of the enterolith tumbling through the bowel lumen [4–6].

Imaging development has improved the early diagnosis and treatment of this disorder [1].

Abdominal radiography is, traditionally, the first step in identifying enteroliths. It can detect stones in up to a third of the cases [7]. The visibility of the enterolith depends on the calcium content. Calcium salts enteroliths are more radiopaque than choleic acid enteroliths [6,8,9].

They appear oval, round, or rectangular with dense rim, pale core, and mobile on serial examinations [10].

CT scan may help in identifying the culprit enteroliths, their number, and their location. Oral contrast may increase the yield of detection of radiolucent enteroliths. Imaging may assist in diagnosing underlying pathology of the intestinal tract that leads to enteroliths formation or trapping and clinical obstruction. The gallbladder and bile duct should also be examined to rule out secondary enterolithiasis [1].

An enterolith is labeled as idiopathic only after excluding an underlying cause. In most cases, an idiopathic enterolith is solitary, larger than 25mm in diameter, composed of calcium salts predominantly, and located in the terminal ileum. Idiopathic cases must be followed-up postoperatively, given the possibility of recurrence, as was in our case [11].

Enterolithiasis is a rare cause of acute small bowel obstruction [2]. Enteroliths may cause acute, subacute, or chronic, intermittent, partial, or complete intestinal obstruction [12].

Enteroliths smaller than 20mm in diameter would typically be cleared by the propagation of the endoluminal contents. They may also be retained and become a nidus for additional calcification and growth, to cause pathogenic obstruction. Enteroliths larger than 25mm in diameter may cause intestinal obstruction in the absence of an underlying luminal compromise [13].

Other complications includes intestinal gangrene, intussusception of the small bowel, acute obstructive ascending cholangitis due to periampullary duodenal stone, afferent loop syndrome, diverticulitis, iron deficiency anemia, gastrointestinal hemorrhage, and perforation [1].

Optimal treatment of enterolithiasis consists of enterolith removal and correction of underlying pathology to prevent the future formation of additional enteroliths [1].

Surgical management is the base of therapy in case of small bowel obstruction secondary to enterolithiasis. Digi-

tal fragmentation of the enterolith followed by manual milking of its smaller parts into the colon could be successful in nearly 50% of the cases. Alternatively, proximal enterotomy with enterolith removal may be performed, as was in our case [14,15].

Segmental small bowel resection should be performed in case of Meckel's diverticulum, long complicated strictures, diverticulitis, significant inflammation, intestinal necrosis, perforation, and enteral duplication [10,16].

Expectant management with serial abdominal examinations, hydration, electrolyte correction, and nasogastric tube suctioning may be considered for acute small bowel obstruction with enteroliths smaller than 20mm in diameter in absence of underlying luminal compromise [17].

Mortality of uncomplicated primary enterolithiasis is very low but may reach 3% in patients with poor condition, significant obstruction, and delay in diagnosis [15].

Patient consent

Written and informed consent for publication of the case was obtained from the patient.

REFERENCES

- [1] Gurvits GE, Lan G. Enterolithiasis. *World J Gastroenterol* 2014;20:17819–29. doi:10.3748/wjg.v20.i47.17819.
- [2] Klingler PJ, Seelig MH, Floch NR, Branton SA, Metzger PP. Small-intestinal enteroliths—unusual cause of small-intestinal obstruction: report of three cases. *Dis Colon Rectum* 1999;42:676–9. doi:10.1007/BF02234149.
- [3] Atwell JD, Pollock AV. Intestinal calculi. *Br J Surg* 1960;47:367–74. doi:10.1002/bjs.18004720405.
- [4] Gupta NM, Pinjla RK, Talwar BL. Calcific enterolithiasis. *Indian J Gastroenterol* 1986;5:29–30.
- [5] Mendes Ribeiro HK, Nolan DJ. Enterolithiasis in Crohn's disease. *Abdom Imaging* 2000;25:526–9. doi:10.1007/s002610000085.
- [6] Tewari A, Weiden J, Johnson JO. Small-bowel obstruction associated with Crohn's enterolith. *Emerg Radiol* 2013;20:341–4. doi:10.1007/s10140-013-1107-y.
- [7] Athey GN. Unusual demonstration of a Meckel's diverticulum containing enteroliths. *BJR* 1980;53:365–8. doi:10.1259/0007-1285-53-628-365.
- [8] Paige ML, Ghahremani GG, Brosnan JJ. Laminated radiopaque enteroliths: diagnostic clues to intestinal pathology. *Am J Gastroenterol* 1987;82:432–7.
- [9] Yuan JG, Sachar DB, Koganei K, Greenstein AJ. Enterolithiasis, refractory anemia, and strictures of Crohn's disease. *J Clin Gastroenterol* 1994;18:105–8. doi:10.1097/00004836-199403000-00004.
- [10] Singhal BM, Kaval S, Kumar P, Singh CP. Enterolithiasis: an unusual cause of small intestinal obstruction. *Arch Int Surg* 2013;3:137. doi:10.4103/2278-9596.122936.
- [11] Gupta R, Andley M, Saha S, Kumar A. True primary "Idiopathic" enterolithiasis as an unusual cause of bowel perforation. *Trop Gastroenterol* 2020;39:223–5. doi:10.7869/tg.511.
- [12] Jones RP, McWhirter D. Intermittent small bowel obstruction caused by Meckel's enterolith. *Ann R Coll Surg Engl* 2010;92:W16–17. doi:10.1308/147870810X12699662980079.

-
- [13] Nakao A, Okamoto Y, Sunami M, Fujita T, Tsuji T. The oldest patient with gallstone ileus: report of a case and review of 176 cases in Japan. *Kurume Med J* 2008;55:29–33. doi:[10.2739/kurumemedj.55.29](https://doi.org/10.2739/kurumemedj.55.29).
- [14] Leow CK, Lau WY. Treatment of small bowel obstruction by jejunal enterolith. *Surgery* 1997;122:977–8. doi:[10.1016/s0039-6060\(97\)90349-4](https://doi.org/10.1016/s0039-6060(97)90349-4).
- [15] Steenvoorde P, Schaardenburgh P, Viersma JH. Enterolith ileus as a complication of jejunal diverticulosis: two case reports and a review of the literature. *Dig Surg* 2003;20:57–60. doi:[10.1159/000068852](https://doi.org/10.1159/000068852).
- [16] Gadhia U, Raju D, Kapoor R. Large enterolith in a meckels diverticulum causing perforation and bowel obstruction: an interesting case with review of literature. *Indian J Surg* 2013;75:177–9. doi:[10.1007/s12262-012-0558-9](https://doi.org/10.1007/s12262-012-0558-9).
- [17] Ihara E, Ochiai T, Yamamoto K, Kabemura T, Harada N. A case of gallstone ileus with a spontaneous evacuation. *Am J Gastroenterol* 2002;97:1259–60. doi:[10.1111/j.1572-0241.2002.05715.x](https://doi.org/10.1111/j.1572-0241.2002.05715.x).