




Endovascular surgery for the treatment of purulent and necrotic complications in diabetic foot syndrome

Murat K. Jakanov^{1*}  Bazylbek S. Zhakiev², Uteugaly G. Karsakbayev², Bulat A. Kurmanbayev², Kairat R. Taishibayev¹, Serik K. Sagynganov¹

Received: 12 Mar 2020

Published: 18 Aug 2021

Abstract

Background: Diabetic foot syndrome (DFS) causes damage to the peripheral arteries in 50% of patients with diabetes mellitus (DM). The purpose of this study was to evaluate the efficacy of endovascular interventions, stenting, and balloon angioplasty for the treatment of patients with purulent and necrotic lesions in DFS.

Methods: This was a retrospective study. During 2019-2020, stenting and balloon angioplasty were performed in 51 patients (study group) with purulent and necrotic complications of diabetic foot with limb ischemia. There were 32 women (62.7%) and 19 men (37.3%). The age of the patients varied from 45 to 81 years. Endovascular interventions were performed in combination with conservative therapy and topical treatment on 2 to 3 days after the debridement of the purulent lesions. To assess the outcomes of endovascular interventions, we studied the nature of changes in arterial circulation in the lower extremities. The mean blood flow velocity was calculated using the Doppler ultrasonography. The study was performed on the popliteal artery (PA), the posterior tibial artery (PTA), and on the dorsalis pedis artery. In this study, patients were divided into 2 groups: the study group— those who received endovascular intervention— and the control group— those who received only conservative therapy, which included local treatment without surgery.

Results: The weightbearing function of the foot at discharge from the hospital was preserved in 94.2% (48 patients) of the study group and in 73.4% (22 patients) of the control group. During the next 6 months, repeated small foot surgeries were required in 7.3% (3 patients) of patients from the study group and in 20% (4 patients) of patients from the control group. Six months after discharge, the weightbearing function of the foot was preserved in all the patients from the study group available for follow-up and in 85% of the patients from the control group.

Conclusion: The results of the study demonstrate the positive corrective effects of endovascular interventions, stenting, and balloon angioplasty on the clinical course of ischemic and neuroischemic forms of DFS.

Keywords: Diabetes Mellitus, Revascularizing Surgery, Weightbearing Function of The Foot, Purulent Complications, Wound Healing

Conflicts of Interest: None declared

Funding: The study was performed within the framework of a scientific and technical project using a grant No. 13/2-18-55/4 from West Kazakhstan Marat Ospanov Medical University.

*This work has been published under CC BY-NC-SA 1.0 license.

Copyright© Iran University of Medical Sciences

Cite this article as: Jakanov MK, Zhakiev BS, Karsakbayev UG, Kurmanbayev BA, Taishibayev KR, Sagynganov SK. Endovascular surgery for the treatment of purulent and necrotic complications in diabetic foot syndrome. *Med J Islam Repub Iran.* 2021 (18 Aug);35:106. <https://doi.org/10.47176/mjiri.35.106>

Introduction

Diabetes mellitus (DM) is the most common human endocrine disease with a constant tendency towards an in-

Corresponding author: Dr Murat K. Jakanov, m.jakanov6309@murdoch.in

¹ Department of General Surgery, West Kazakhstan Marat Ospanov Medical University, Aktobe, Republic of Kazakhstan

² Department of Surgical Diseases No. 2, West Kazakhstan Marat Ospanov Medical University, Aktobe, Republic of Kazakhstan

↑What is “already known” in this topic:

Progressive deterioration of blood supply to the lower extremities with simultaneous infections associated with wounds and cracks due to microtraumas of the foot results in the development of purulent and necrotic complications in the feet, which together with the progression of concomitant diseases, increases the risk of high amputations of the limbs.

→What this article adds:

A decrease in ischemia of the lower extremities, achieved with direct surgical endoscopic interventions on the vascular bed, has positive effects on the course of purulent and necrotic processes in the affected foot, which ultimately makes it possible to reduce the number of high amputations and preserve the weightbearing function of the foot in a significant number of patients.

crease in complications. One of the severe, formidable complications of DM is diabetic foot syndrome (DFS), together with diabetic retinopathy, nephropathy, neuropathy, and damage to the cardiovascular system. Foot problems occur in a significant number of patients with diabetes, while peripheral arterial lesions occur in 50% of patients with DFS, which is the main cause of poor outcomes in this category of patients (1, 2). Progressive deterioration of blood supply to the lower extremities with simultaneous infections associated with wounds and cracks due to various microtraumas of the foot, and insignificant and invisible even for the patient, results in the development of purulent and necrotic complications in the feet, which together with the progression of concomitant diseases, further increases the risk of negative outcomes by increasing the frequency of high amputations of the limbs due to gangrene at the level of the foot, lower leg, and thigh (3-5). Naturally, after a high amputation of a limb, the quality of life of a patient is significantly lower, which is an important criterion for the assessment of the treatment efficacy.

Therefore, reducing the percentage of high amputations and preserving a weightbearing function of the foot is the main goal of treatment in patients with DFS. To reduce the frequency of amputations, treatment methods aimed at the improvement of blood supply to the lower extremities is pathogenetically justified. To date, along with conservative therapy for ischemia of the lower extremities, indirect revascularization procedures, vascular bypass procedures as well as endovascular interventions are used, which are of the greatest interest, as they are not traumatic for the patient. There are studies showing that endovascular interventions provide a significant improvement in treatment outcomes in patients with DFS (6). At the same time, there are studies presenting treatment outcomes in patients for whom revascularization procedures were not technically possible or not indicated due to concomitant diseases; nevertheless, the developed ulcers resolved within a year without revascularization (7).

Therefore, we performed a study of the effects of revascularization procedures on treatment outcomes in patients with DFS. The purpose of the study was to assess the efficacy of endovascular interventions, stenting, and balloon angioplasty for the treatment of patients with purulent and necrotic lesions in DFS.

Methods

This study was conducted on patients with purulent and necrotic complications of DFS who were treated at the surgical department of the Medical Center in Aktobe (Republic of Kazakhstan) in 2019-2020. Treatment algorithms for the patients included conservative therapy and surgical interventions. Conservative therapy of the neuroischemic form of DFS in both clinical groups included the following: compensation of glycemia with short- and long-acting insulin drugs (actrapid, protaphane, humulin, and lantus); antispasmodics (halidor), and antiplatelet agents (thrombo-ASS, clopidogrel); anticoagulant therapy (heparin, fraxiparine), and broad-spectrum antibiotics until the results of bacteriological studies were obtained; drugs

that improve blood rheological properties (rheopolyglucin, trental); prostaglandin E products (vazaprostan); alpha lipoic acid products (thioctacid); metabolic therapy (actovegin, solcoseryl); antioxidant therapy (vitamins A and E); and symptomatic therapy of concomitant diseases.

Surgical treatment of the patients included minor interventions on the feet for debridement of a purulent focus: phlegmon opening, necrectomy, exarticulation of the fingers, and Chopart and Lisfranc amputation with further local treatment. Local treatment consisted of various antiseptic solutions, enzymes, ointments, and oils, according to the phases of the wound healing process. Endovascular interventions in the study group were performed 2 to 3 days after debridement of a purulent focus, provided there was a tendency towards positive changes in the purulent and necrotic process, most often under spinal anesthesia.

To assess the outcomes of endovascular interventions, we studied the nature of changes in arterial circulation in the lower extremities. The mean blood flow velocity (V_{mean}) was calculated using the Doppler ultrasonography; the study was performed on the popliteal artery (PA), posterior tibial artery (PTA), and the dorsalis pedis artery (DPA). The ankle-brachial index (ABI) was determined; the measurements were performed using a tonometer and an ultrasonic transducer. To assess microcirculatory disorders, the percutaneous determination of oxygen tension in the tissues (T_{meanO_2}) was used. The study was performed using the TSM-222 Radiometer gas analyzer. The measurements were performed in a horizontal position of the limb, both on the back of the foot in the area of the first interdigital space and on other parts of the foot. These studies were performed immediately after admission, on days 10 and 20, and 6 months after endovascular interventions.

The most significant criterion for treatment efficacy assessment in purulent and necrotic complications of DFS is wound healing and, as a consequence, preservation of a larger area of the tissues for the weight-bearing function of the foot. Therefore, to assess the changes in wound healing process over time, such parameters as time (in days) to disappearance of edema, wound cleaning from purulent exudate, appearance of granulations, and disappearance of infiltration in the wound area were used.

The study did not include patients with a neuropathic form of DFS, patients with wet or dry gangrene of the foot with the transition to the lower leg who underwent urgent high amputation of the limb (grade 5 according to F. Wagner). Statistical analysis was performed using the Statistica 8.0 software (StatSoft Inc). The normality of data distribution in the sample was determined using the Shapiro-Wilk test. Taking into account the fact that the distribution in the samples was not normal, to compare more than 2 dependent populations, the nonparametric Friedman test was used. A post hoc analysis was performed using the Wilcoxon test to assert that the level of significance for the dependent variables in a compared sample was higher or lower. To detect statistical relationships between the studied parameters, correlation analysis was done using the Spearman's test. Differences in the obtained values were considered significant at $P < .05$.

Quantitative parameters are presented as mean \pm SD, where M is arithmetic mean, SD is standard deviation, and qualitative parameters (rates, proportions) are presented as absolute values and percentages.

Results

Endovascular surgical interventions, stenting, and balloon angioplasty of the lower extremities (study group) were performed in 51 patients with ischemic and neuro-ischemic forms of DFS. There were 32 women (62.7%) and 19 men (37.3%). The age of the patients varied from 45 to 81 years. The mean age was 64.2 ± 7.5 . At the same time, the most common age-related frequency was observed in 38 (74.5%) patients between 55 and 70 years.

All the patients had noninsulin dependent DM. The mean duration of diabetes was 11.5 ± 2.2 years (from 8 to 17 years). Disease duration up to 14 to 17 years was observed in 7 (13.7%) patients. The majority of patients experienced the first signs of DFS 10 years after diagnosing with DM, which manifested themselves in the form of ischemic and neuropathic symptoms in the lower extremities with further addition of destructive changes in the feet. A significant part of patients was admitted to the hospital within a few months from the onset of DFS manifestations with widespread purulent and necrotic processes. At admission, DM was sub- and decompensated in all the patients, as evidenced by the very fact of the occurrence of purulent and necrotic lesions of the feet. Patients with moderate and severe DM prevailed. The number of bed-days was 15 ± 2.9 (from 11 to 21 days).

Changes in the arteries were mainly unilateral and single-level lesions. Unilateral lesions in the tibial arteries were most common, 19 (37.2%) patients. Bilateral lesions in the tibial arteries were observed in 6 (11.8%) patients and unilateral lesions in the femoral arteries in 11 (21.6%). Unilateral combined lesions in the femoral and tibial arteries were found in 14 (27.4%) patients, bilateral biarterial femoral-tibial lesions were found in 1 (2%) patient only. The majority of patients had comorbidities, among which hypertensive disease and ischemic heart disease (IHD) were diagnosed in 30 (58.8%) patients, which were the most common; 2 or more concomitant diseases were seen in 1 patient, particularly hypertension; and IHD and obesity of varying degrees, were observed in

13 (25.5%) patients. These concomitant diseases, together with diabetes mellitus, resulted in a high risk of surgery and anesthesia. All the patients had a combination of purulent and necrotic lesions: foot phlegmon in 31 (60.6%) patients, foot osteomyelitis in 4 (8%), gangrene of the toes in 25 (49%), 3 of whom developed gangrene of the distal foot because of ischemia progression in the hospital; and 4 (7.8%) were initially admitted with gangrene of the foot. The spread and depth of the purulent and necrotic processes in the feet were assessed according to the F. Wagner's classification (1979), according to which all patients had lesions of grades 2 to 4.

The results obtained after the treatment of the wounds following endovascular interventions were compared with similar data on wound healing in 30 patients with ischemic and neuroischemic DFS (control group) who received conservative therapy only, similar to therapy in the study group, which included topical treatment, without any surgical interventions to improve blood supply to the lower extremities. As the value of $T_{\text{mean}}\text{O}_2$ was considered a key parameter of the local blood circulation, a comparative assessment of changes in the blood flow in the lower extremities during the treatment in the study and control groups was done based on this parameter. The compared groups had no differences in age ($p=0.252$), gender ($p=0.158$), frequency of concomitant pathologies, levels of glycemia ($p=0.145$), types of purulent and necrotic foot lesions ($p=0.963$) (Table 1), or initial oxygenation in the lower extremities ($p=0.227$).

After endovascular interventions, an increase in ABI by 57.4% on day 10 and by 68.5% on day 20 was observed, compared to baseline ($p<0.001$) (Table 2). Among the blood flow parameters, the greatest changes were observed in the V_{mean} on the PTA with an increase by 53.6% and 83.8% on days 10 and 20, respectively ($p<0.001$). The value of $T_{\text{mean}}\text{O}_2$ also increased by 57% and 65% on days 10 and 20 of observation, respectively ($p<0.001$). As shown in the Table 2, the tendency towards an improvement in blood flow in the study group was observed in other studied parameters. In the control group, the value of $T_{\text{mean}}\text{O}_2$ increased only by 9.2% on day 10 and by 22.3% on day 20; that is, an increase in this group was 3 times lower than in the study group, although changes in this parameter reached the level of significance of differences

Table 1. Types of Purulent and Necrotic Lesions And Their Rates

Types, %	Study Group (n=51)	Control Group (n=51)
Foot phlegmon	31 (60.6)	21 (70)
Gangrene of the toes	25 (49)	12 (40)
Gangrene of the distal foot	7 (13.7)	4 (13.3)
Gangrene progression	2 (3.9)	7 (23.3)
Foot osteomyelitis	4 (8)	2 (6.7)

Table 2. Changes in the Parameters of Blood Circulation in the Lower Extremities^a

Group	Parameter	Baseline	Day 10	Day 20
Study	ABI	0.54 ± 0.02	$0.85 \pm 0.03/57.4$	$0.91 \pm 0.01/68.5$
	V_{mean} , cm/s, PA	24.84 ± 0.41	$30.69 \pm 0.33/23.5$	$34.71 \pm 0.37/39.7$
	V_{mean} , cm/s, PTA	13.21 ± 0.38	$20.29 \pm 0.38/53.6$	$24.28 \pm 0.35/83.8$
	V_{mean} , cm/s, DPA	12.08 ± 0.87	$18.8 \pm 0.38/55.6$	$20.91 \pm 0.38/73.1$
	$T_{\text{mean}}\text{O}_2$	29.18 ± 0.56	$45.82 \pm 0.48/57$	$48.15 \pm 0.67/65$
Control	$T_{\text{mean}}\text{O}_2$	28.3 ± 1.13	$30.9 \pm 1.63/9.2$	$34.6 \pm 2.62/22.3$

^aABI, ankle-brachial index; DPA, dorsalis pedis artery; PTA, posterior tibial artery.

Table 3. Changes in Wound Healing

Parameters of wound healing, d	Study Group (n=51)	Control Group (n=30)
Disappearance of edema	6.42±0.45	10.3±2.4
Wound cleansing	6.09±0.37	10.8±1.8
Appearance of granulations	9.14±0.41	11.8±1.63
Disappearance of infiltration of wound area	8.75±0.22	12.9±2.7

Table 4. Early Treatment Outcomes and outcomes After 6 Months^a

Outcome Criteria	Study Group		Control Group	
	Early (n=51)	6 Months Later (n=41)	Early (n=30)	6 Months Later (n=20)
Number of patients with repeated minor interventions and foot amputations, %	9 (17.6)	3 (7.3)	20 (66.6)	4 (20)
Lower leg and thigh amputations, %	2 (3.9)	0	7 (23.3)	2 (10)
Preserved support function of the foot, %	48 (94.2)	41 (100)	22 (73.4)	17 (85)
Mortality, %	1 (1.9)	0	1 (3.3)	1 (5)

^aP < .001 as statistically significant differences based on the Pearson’s chi-square test.

in this group.

A comparative assessment of changes in wound healing showed the disappearance of edema in the area of foot wounds 3.9 days earlier (p<0.001), wound cleansing 4.7 days earlier (p<0.001), appearance of granulations 2.6 days earlier (p<0.001), and disappearance of infiltration of wound edges 4.1 days earlier (p<0.001) in the patients of the study group after endovascular interventions compared to the patients from the control group (Table 3).

The analysis of the early treatment outcomes after endovascular interventions showed that the weightbearing function of the foot was preserved in 1.3 times more patients in this group than in the control group, in 94.2% and 73.4%, respectively (Table 4). There was no suppuration of postoperative wounds or thrombosis after endovascular procedures.

Despite obvious clinical dependence of changes in wound healing on the blood supply to the lower extremities, a statistical correlation between the studied parameters was analyzed. A low inverse correlation of mean time was observed between the V_{mean} values on the DPA on day 10 in terms of time to wound cleansing ($r=-0.24$; $p<0.05$) and time to granulation appearance ($r=-0.13$;

$p<0.05$), and on day 20 of the study in terms of time to granulation appearance ($r=-0.22$; $p<0.05$). In terms of ABI, time to granulation appearance ($r=-0.13$; $p<0.05$) and time to disappearance of infiltration in the wound area ($r=-0.14$; $p<0.05$), a low inverse correlation was also observed on day 20 of the study. Regarding oxygenation of the tissues of the foot, no correlation with the studied parameters of wound healing was found.

The study of tissue oxygenation 6 months after endovascular interventions showed that the value of this parameter on day 20 decreased only in 7 (17.1%) patients to the level of day 10 of the study, 45.9 ± 0.6 , while in the remaining 34 (82.9%) patients, it remained at the level of day 20 of the study, 47.5 ± 0.7 . In the control group, after 6 months of observation, there was a decrease in the $T_{mean}O_2$ almost to baseline of 29.9 ± 1.56 in all patients (Fig. 1).

Within 6 months after intervention and discharge from the hospital, repeated surgical interventions for the topical treatment of purulent and necrotic wounds due to the progression of the local processes were required in 7.3% (3 patients) of the patients from the study group and in 20% (4 patients) of the patients from the control group; that is, 2.7 times more patients. After 6 months, among 41 pa-

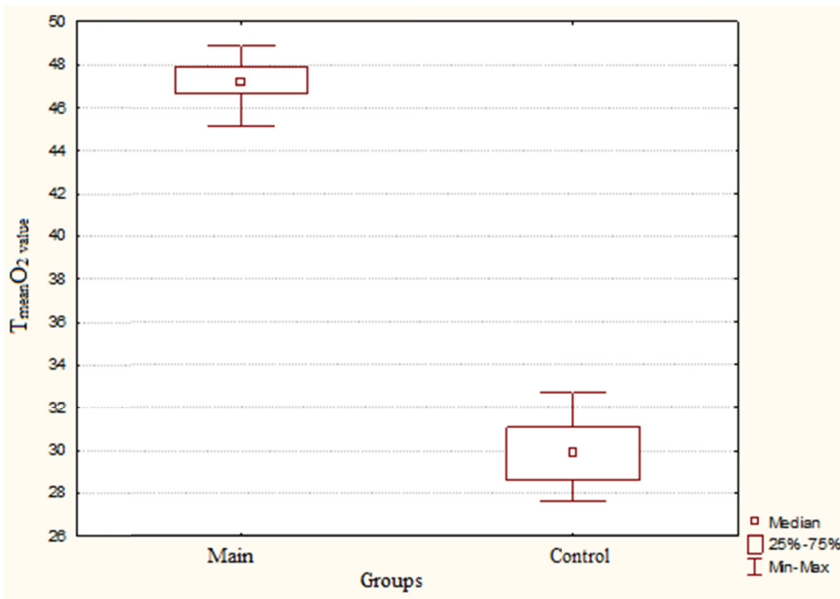


Fig. 1. The Values of $T_{mean}O_2$ in the Study and Control Groups After 6 Months

tients (available for follow-up) from the study group, the weightbearing function of the foot, despite minor interventions on the foot on an outpatient basis in 3 patients, was preserved in all the patients compared to 85% in the control group (n= 20 patients).

Discussion

The obtained study results show clinically and statistically significant efficacy of minimally invasive intraluminal vascular techniques during surgical interventions for the treatment of patients with purulent and necrotic lesions of the feet in DFS compared to conservative therapy. The effects on the vascular bed following direct surgical improvement of adequate arterial inflow with the maximum opening of the distal bed due to a permanent stent and mechanical expansion of the vessel lumen, predictably reduce the level of ischemia and restore soft tissue defects more quickly and effectively compared to pharmacotherapy. However, the following questions required answers: How faster is the wound healing? What is the risk of wound complications of surgical wounds after endovascular interventions? What is the duration of the effect?

In our study, a more rapid improvement of ischemia and an improvement in blood flow parameters immediately after surgery were clearly observed after endovascular interventions compared to conservative therapy, the effects of which occurred later or might have insufficient duration to create conditions for wound healing. We believe that for the treatment of purulent and necrotic wounds, it is important to create conditions with good blood supply to the lower extremity within a certain period of time; in our case, during hospital treatment so that the topical treatment would lead to wound healing or to a stable tendency to their healing. As a consequence, the subsequent natural deterioration of blood supply in the nearest, especially distant future, would not have negative effects, as the wounds would already be healed. This is consistent with the opinion that interventions aimed at a long-term full patency of the treated vessel are less useful, as even temporary recanalization improves blood flow in the foot, and this promotes healing of wounds or ulcers (8). It is known that oxygen demand of the healed tissues decreases and normally lower blood flow is required to keep the tissue intact (9). Taking into account the fact that repeated stenting and balloon angioplasty can be performed, they have an undoubted advantage over bypass and prosthetic vascular interventions.

The main conclusion of our study is that stenting and balloon angioplasty provide a high percentage of limb sparing and preservation of its weightbearing ability. As mentioned before, the improvement in peripheral blood flow allowed limb sparing in 94.2% of our patients. Ferraresi et al (10) reported that the rate of limb sparing in their study was 93%, which coincides with the data of our study. One of the main advantages of endovascular interventions is the ability to intervene on multiple vessels, which may imply better clinical outcomes. In our study, we performed interventions on one of the tibial arteries only, which, nevertheless, made it possible to obtain the

above-mentioned results. Ahmed K Allam et al (8) in their study found that the overall rate of limb sparing was 89.1% in all examined patients (N=46). At the same time, 28 (60.9%) patients who underwent recanalization of several vessels had the rate of limb sparing of 92.9%, which was higher than the rate (83.3%) achieved in 18 patients (39.1%) with revascularization of 1 vessel but statistically insignificant, which was because of a small sample of patients. At the same time, Acin et al (11) reported that endovascular interventions on more than 1 tibial artery showed the same results, in particular, improved ABI compared to interventions on 1 tibial artery only.

In our study, we did not investigate this particular issue, as endovascular interventions were performed on 1 artery but we believe that good clinical outcomes were achieved. We did not compare treatment outcomes between stenting and balloon angioplasty. Testing the hypothesis of possible statistical correlation between the parameters of peripheral blood flow and the parameters of wound-healing only showed a weak correlation between some of the studied parameters, which was not consistent with the obvious clinically observed relationship between the status of blood flow and wound healing. Our results can probably be explained with a small sample of the study participants. Nevertheless, it can also be assumed that a statistical relationship between certain parameters may not always be observed. For example, no correlation with the studied parameters of wound-healing was observed for the key parameter of the circulation: oxygenation of the foot tissues.

Regarding the possibility of the development of purulent complications of surgical wounds and vascular thrombosis in preexisting purulent and necrotic processes in the foot during endovascular interventions, as mentioned above, we did not observe a single case of postoperative wound suppuration or arterial thrombosis. This is probably because surgical interventions were performed with concomitant conservative therapy, which included anticoagulant and antibacterial therapy. Endovascular surgery was performed in the patients after mandatory correction of the glycemic status, normally with a decrease in blood glucose to 11 mmol/L, and after patient transition from the state of decompensated DM to sub- and compensated DM. An obligatory step before endovascular surgery, which excluded suppuration of postoperative wounds and arterial thrombosis in our patients, was a complete surgical debridement of a purulent focus in the foot; that is, phlegmon opening, necrectomy, exarticulation of the toes, and distal amputations.

The main criteria for efficacy evaluation in the patients with purulent and necrotic complications of DFS were the following: changes in wound healing and a possibility of preservation of its function, as these are key parameters of the clinical picture in this pathology, and this is what really worries the patient. According to the data presented, the weightbearing function of the foot was preserved in 94.2% of the patients in the study group, compared to 73.4% patients in the control group.

Of note, there are relatively few studies that included patients with purulent and necrotic processes in the form

of phlegmon who underwent endovascular interventions. In some studies, the authors performed endovascular interventions for DFS but mainly in patients with trophic ulcers, without extensive purulent or necrotic wounds, as was the case in our study (12, 13). We believe that the surgeons hold off from such interventions, which require aseptic conditions, for the fear of postoperative purulent complications in the wounds, soft tissues, and vessels of the lower extremities as well as other DM complications, which could worsen the patient's condition after surgery and anesthesia.

The main conclusion based on the analysis of the study results is that stenting and balloon angioplasty of the arteries of the lower extremities in cases of purulent and necrotic complications of DFS can reduce the number of repeated minor interventions and foot amputations 3.8 times and the frequency of hip disarticulations 6 times as well as preserve the weightbearing ability of the feet in 94.2% of patients (14, 15). Endovascular interventions, stenting, and balloon angioplasty, on 1 of the tibial arteries only show encouraging positive treatment outcomes, and therefore is sufficient in terms of the number of arteries required for the intervention to obtain the expected result. This is consistent with modern trends in the development of any surgical interventions and minimally traumatic approach followed by the surgeons in all patients (16, 17). The obligatory implementation of adequate and complete surgical debridement of a purulent focus in the foot prevents the development of postoperative wound suppuration and thrombosis of the peripheral arteries in patients after endovascular interventions on the lower extremities. This is also facilitated by the fact that endovascular interventions should be performed with concomitant conservative therapy, mandatory components of which should be anticoagulant, and antibacterial treatments. The statistical correlation between the parameters of blood flow in the peripheral arteries of the lower extremities and the healing process of purulent and necrotic wounds was not determined. However, an evident clinical relationship between the improvement of peripheral blood circulation in the lower extremities and improvement in wound healing was observed.

Conclusion

The results of the study demonstrate positive corrective effects of endovascular interventions, stenting, and balloon angioplasty on the clinical course of ischemic and neuroischemic forms of DFS. As shown in this study, a decrease in ischemia of the lower extremities, achieved with direct surgical endoscopic interventions on the vascular bed, has positive effects on the course of purulent and necrotic processes in the affected foot, which ultimately makes it possible to reduce the number of high amputations and preserve the weightbearing function of the foot in a significant number of patients, thereby improving treatment outcomes in this category of patients. Endovascular interventions in patients with DFS, distal ischemia of the lower extremities, and purulent necrotic lesions in the feet are safe interventions in terms of infection control and the risk of thromboembolic complications.

Acknowledgement

The study was performed within the framework of a scientific and technical project using a grant No. 13/2-18-55/4 from West Kazakhstan Marat Ospanov Medical University. The authors would like to acknowledge the staff of the Department of Science at West Kazakhstan Marat Ospanov Medical University and the Aktobe Medical Centre for their assistance in this study.

Conflict of Interests

The authors declare that they have no competing interests.

References

- Schiffer D, Blokhuis-Arkes M, Van Der Palen J, Sigl E, Heinzle A, Guebitz GM. Assessment of infection in chronic wounds based on the activities of elastase, lysozyme and myeloperoxidase. *Br J Dermatol*. 2015;173(6):1529-31.
- Bender C, Cichosz SL, Pape-Haugaard L, Hartun Jensen M, Bermark S, Laursen AC, et al. Assessment of simple bedside wound characteristics for a prediction model for diabetic foot ulcer outcomes. *J Diabetes Sci Technol*. 2020.
- Belozertseva YP, Kurlaev PP, Esipov VK, Gritsenko VA. Experience in the treatment of purulent-necrotic complications of diabetic foot syndrome using an original surgical technique against the background of targeted antibiotic therapy. *Creat Surg Oncol*. 2014;3:67-9.
- Bensman VM. Surgery of purulent-necrotic complications of diabetic foot. Moscow: Medpraktika, 2015.
- Galstyan GR, Tokmakova AY, Egorova DN, Mitish VA, Paskhalova YuS, Antsiferov MB, Komelyagina EYu, Udovichenko OV, Guryeva IV, Beregovsky VB, Eroshkin IA, Eroshenko AV. Clinical practice guidelines for the diagnosis and treatment of diabetic foot syndrome. *Wounds Wound Infect*. 2015;3:63-83.
- Elgzyri T, Larsson J, Nyberg P, Thörne J, Eriksson KF, Apelqvist J. Early revascularization after admittance to a diabetic foot center affects the healing probability of ischemic foot ulcer in patients with diabetes. *Eur J Vasc Endovasc Surg*. 2014;48(4):440-6.
- Elgzyri T, Larsson J, Thörne J, Eriksson KF, Apelqvist J. Outcome of ischemic foot ulcer in diabetic patients who had no invasive vascular intervention. *Eur J Vasc Endovasc Surg*. 2013;46(1):110-7.
- Allam AK, Moamen AEA, El-Habbaa GI. Endovascular tibial arteries revascularization and its outcome on wound healing with split-thickness skin grafts for limb salvage in patients with below-the-knee vascular disease. *Egypt J Surg*. 2019;38(4):627-37.
- Bagdasarov VV, Bagdasarova EA, Chernookov AI, Atayan AA, Karchevsky EV, Bagdasarova DV. Endovascular arterial embolization for duodenal bleeding as an alternative to surgical approach. *Khirurgiia*. 2016;2:45-50.
- Giannopoulos S, Varcoe RL, Lichtenberg M, Rundback J, Brodmann M, Zeller T, et al. Balloon angioplasty of infrapopliteal arteries: A systematic review and proposed algorithm for optimal endovascular therapy. *J Endovasc Ther*. 2020;27(4):547-64.
- Maslak K, Favara-Scacco C, Barchitta M, Agodi A, Astuto M, Scalisi R, Italia S, Bellia F, Bertuna G, D'Amico S, La Spina M, Licciardello M, Lo Nigro L, Samperi P, Miraglia V, Cannata E, Meli M, Puglisi F, Parisi GF, Russo G, Di Cataldo A. General anesthesia, conscious sedation, or nothing: Decision-making by children during painful procedures. *Pediatr Blood Cancer*. 2019;66(5):e27600.
- Ivanova YV, Klimova OM, Prasol VO, Korobov AM, Mushenko YV, Kiriienko DO, et al. Plastic closure of wounds in patients with ischemic form of diabetic foot syndrome. *Med Persp* 2018;23(4):71-5.
- Rajendran S, Thottiyil SM, Karatparambil AA, Nadakkavil MRM, Thamaran R, Kattoor TT. Evaluation of angiosome based revascularization in diabetic foot ulcers. *Int Surg J*. 2016;3(2):721-8.
- Mugazov M, Turgunov Y, Kaliyeva D, Matyushko D, Koishibayev Z, Omertayeva D, Nurbekov A, Koishibayeva L, Alibekov A. The role of prepsin in patients with acute surgical diseases. *Open Access Maced J Med Sci*. 2019;7(8):1282-6.
- Tasbulatova GS, Umbetov AU, Sadykova BS, Uzakova BZ, Abdrahmanova MT. Comparative characteristics of the cardiovascular parameters in 7-11-year-old boys residing in northern

- and southern Kazakhstan. *Z. Gefassmed.* 2020;17(2):13-5.
16. Seidinova A, Ishigov I, Peyami C, Seidinov S. Effectiveness of pump insulin therapy in the treatment of type 2 diabetes mellitus (review). *Georgian Med News.* 2018;284:51-5.
17. Lipatov VA, Lazarenko SV, Betz AN, Severinov DA. Changes of physico-mechanical properties of vascular patches in conditions of chronic experiment in vivo. *Novost Khirurgii.* 2019;27(3):249-55.