



Endoscopic Gluteus Medius and Minimus Repair With Allograft Augmentation Using Acellular Human Dermis

Jovan Laskovski, M.D., and Ryan Urchek, M.D.

Abstract: Recently, attention has been given to recalcitrant lateral hip pain, also known as greater trochanteric pain syndrome. Although, historically, this has been attributed to greater trochanteric bursitis, the literature has shown that many patients will have a lesion of the gluteus medius and minimus tendons. Endoscopic hip abductor tendon repair has been shown to provide good outcomes with decreasing overall morbidity and is becoming more popular. However, failure rates have been reported to be as high as 35%, likely due to the poor tissue quality in this older population. Acellular human dermal allograft has been used to augment rotator cuff repairs in an attempt to improve tendon healing. The technique described in this Technical Note shows endoscopic gluteus medius and minimus repair with acellular human dermal allograft augmentation focusing on graft preparation, implantation, and fixation in a safe and reproducible manner.

Recently, attention has been given to recalcitrant lateral hip pain, also known as greater trochanteric pain syndrome.¹ Although, historically, this has been attributed to greater trochanteric bursitis, the literature has shown that many patients will have a lesion of the gluteus medius and minimus tendons. Tendinitis and tendinopathy are common and will oftentimes respond to conservative measures such as physiotherapy and corticosteroid injections. Both partial and full thickness tears of the gluteus medius and minimus tendons can cause significant disability and can be commonly misdiagnosed both clinically and radiographically.

Because of this disability, more attention has been given to the repair of the gluteus medius and minimus tendons. Open repair has been well described in the literature, and endoscopic repair of the tendons has increased in its frequency.^{2,3} Although technically demanding, endoscopic repair has been shown to provide good outcomes with decreased overall morbidity when compared with open repair.⁴ In many cases, poor tendon quality can be an issue and options are being investigated to address this issue. Bovine xenograft has been used in the shoulder to augment rotator cuff repairs via open and arthroscopic techniques, and recently, in endoscopic gluteus medius repair, but it also has limitations that include the following: it cannot be used if a patient has bovine hypersensitivity, it does not provide immediate structural stability, and there may be the possibility of the graft tearing during implantation.⁵ The use of nonirradiated acellular human dermis (Allopatch HD; Conmed Linvatec, Largo, FL) has been described in certain shoulder procedures that provide a scaffold of human collagen type 1, collagen type 3, elastin, hyaluronan, and vitronectin that promotes cell attachment and growth as well as cell infiltration and neovascularization.⁶ It provides superior tensile strength compared with xenografts and is nonimmunogenic and non-crosslinked.⁷

We describe an endoscopic technique using nonirradiated human acellular dermis, which has excellent biocompatibility as well as providing immediate structural

From the Sports Medicine Department, Crystal Clinic Orthopaedic Center (J.L.); and Orthopaedic Department, Summa Health System (R.U.), Akron, Ohio, U.S.A.

The author reports the following potential conflicts of interest or sources of funding: J.L. reports personal fees from Conmed Linvatec and Smith & Nephew during the conduct of the study. Full ICMJE author disclosure forms are available for this article online, as [supplementary material](#).

Received August 15, 2017; accepted August 28, 2017.

Address correspondence to Jovan Laskovski, M.D., Crystal Clinic Orthopaedic Center, 3975 Embassy Parkway, Suite 102, Akron, OH 44333, U.S.A. E-mail: Jovan023@gmail.com

© 2017 by the Arthroscopy Association of North America. Published by Elsevier. This is an open access article under the CC BY-NC-ND license (<http://creativecommons.org/licenses/by-nc-nd/4.0/>).

2212-6287/17994

<https://doi.org/10.1016/j.eats.2017.08.073>

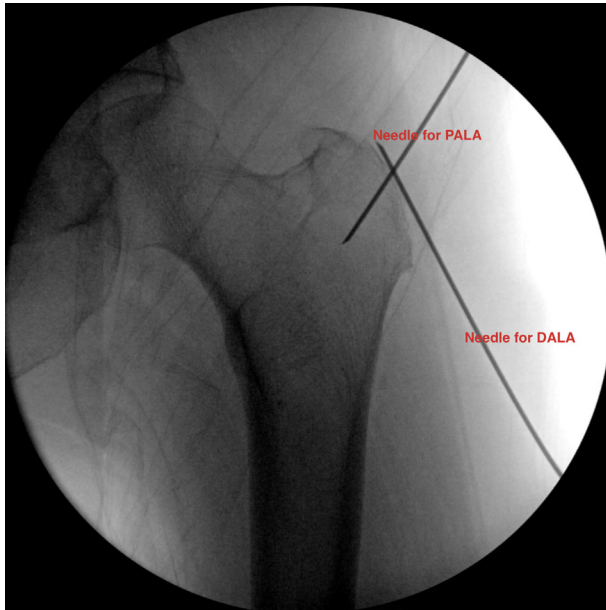


Fig 1. Fluoroscopic guidance with needle localization of distal anterolateral (DALA) and proximal anterolateral (PALA) portals. The patient is in the supine position.

support to the repaired tendon tissue. Acellular human dermis provides the ability to be customized to the footprint to provide ideal coverage to match the patients' greater trochanter and can be applied by this technique in a reproducible and straightforward manner.

Surgical Technique

Patient Setup

We describe a detailed technique of the procedure shown in [Video 1](#). The patient is brought into the

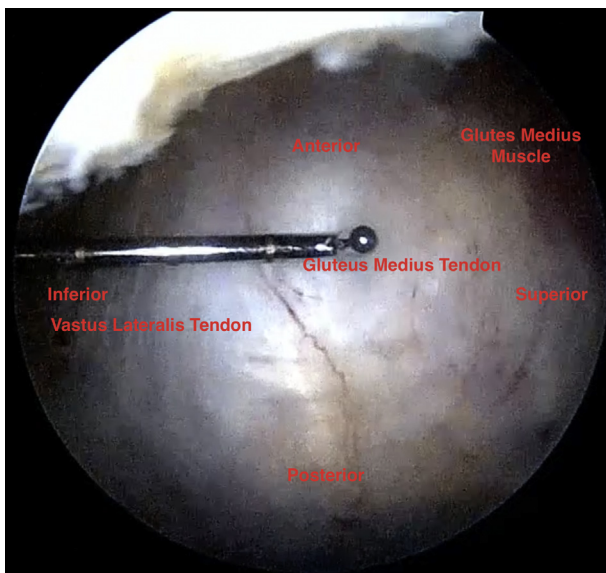


Fig 2. Probe palpating soft spot localizing the partial gluteus medius and minimus tear. The picture is labeled for orientation in the supine position.

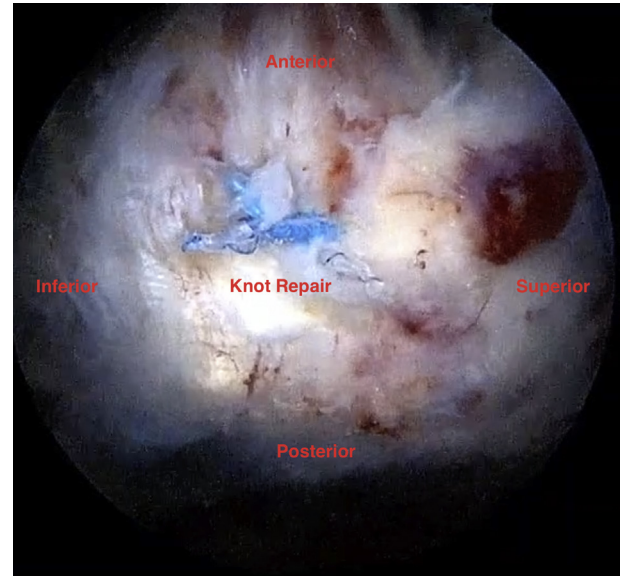


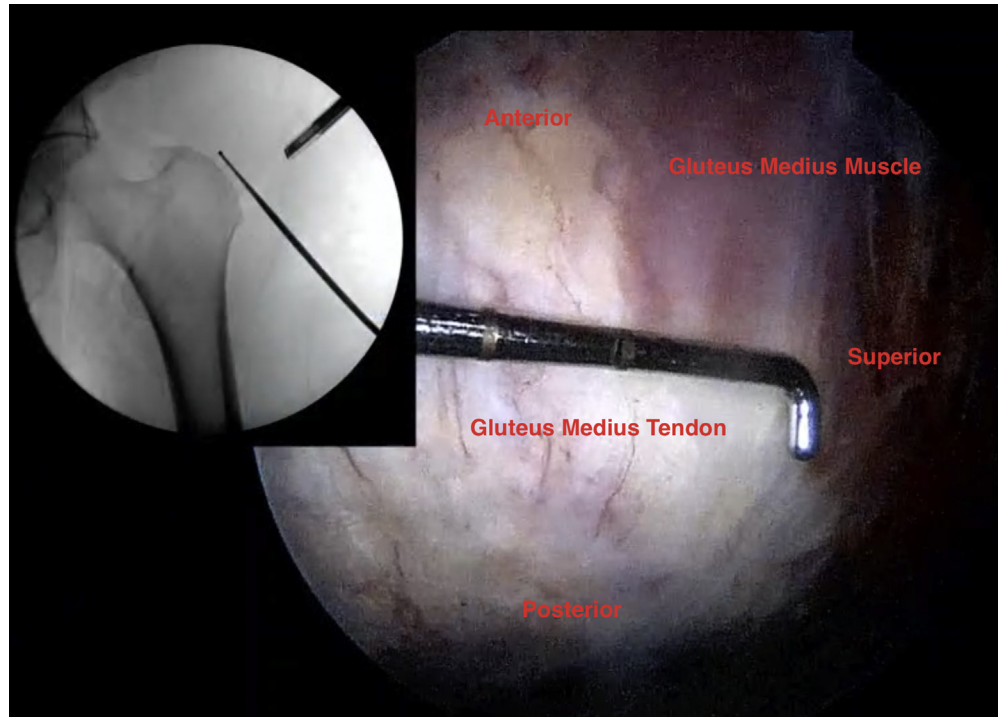
Fig 3. After completion of the partial gluteus medius tear, multiple 2.8-mm anchors are placed with sutures passed in a horizontal mattress fashion and tied after all sutures are passed as necessary.

operating room and placed under general anesthesia. The patient is then placed supine on the hip arthroscopy table and positioned in the boots with the foot internally rotated 20° and adducted to neutral. Care is taken to ensure that no traction is applied because this may close the peritrochanteric space and make access more difficult. The patient is then prepped and draped in the standard orthopaedic fashion and a time-out is performed. We use fluoroscopy to plan our proximal anterolateral (PALA) portal and our distal anterolateral (DALA) portal using a 17-gauge spinal needle to localize the portals to the proximal femur ([Fig 1](#)). The PALA portal is placed proximal to the greater trochanter and in line with the femur so the needle is perpendicular to the footprint of the greater trochanter ([Fig 1](#)). This will allow for both ideal visualization and ideal anchor placement for both the primary repair and the allograft augmentation. The DALA portal is also placed in line with the femur, at an angle parallel to the footprint of the gluteal tendons ([Fig 1](#)). Once both portals are established, the approach to the peritrochanteric space can begin.

Approach

The arthroscope is placed in the PALA portal and a coblation wand (HipVac2; Smith & Nephew, Andover, MA) is placed in the DALA portal. The iliotibial band (ITB) is exposed and hemostasis is achieved. Next, a longitudinal incision, in line with the long axis of the femur, is made in the ITB to expose the peritrochanteric space. At this point, 20° to 30° of abduction is placed on the operative limb to provide

Fig 4. After repair of the tendon, fluoroscopic guidance and a calibrated probe with 5-mm markings are used to measure the length and width of the footprint to help size the graft required.



better access and more volume to the peritrochanteric space. The trochanteric bursa is encountered, and the coblation wand and a reciprocating shaver (Ultracut 4.2 mm; Conmed MTF, Largo, FL) is used to remove the trochanteric bursa in its entirety. The tendons of the gluteus medius, gluteus minimus,

vastus lateralis, and gluteus maximus are then identified and examined. Once the partial or full thickness tear has been identified (Fig 2), the footprint is debrided using the reciprocating shaver to expose cancellous bone and provide a biologic milieu for tendon to bone healing.

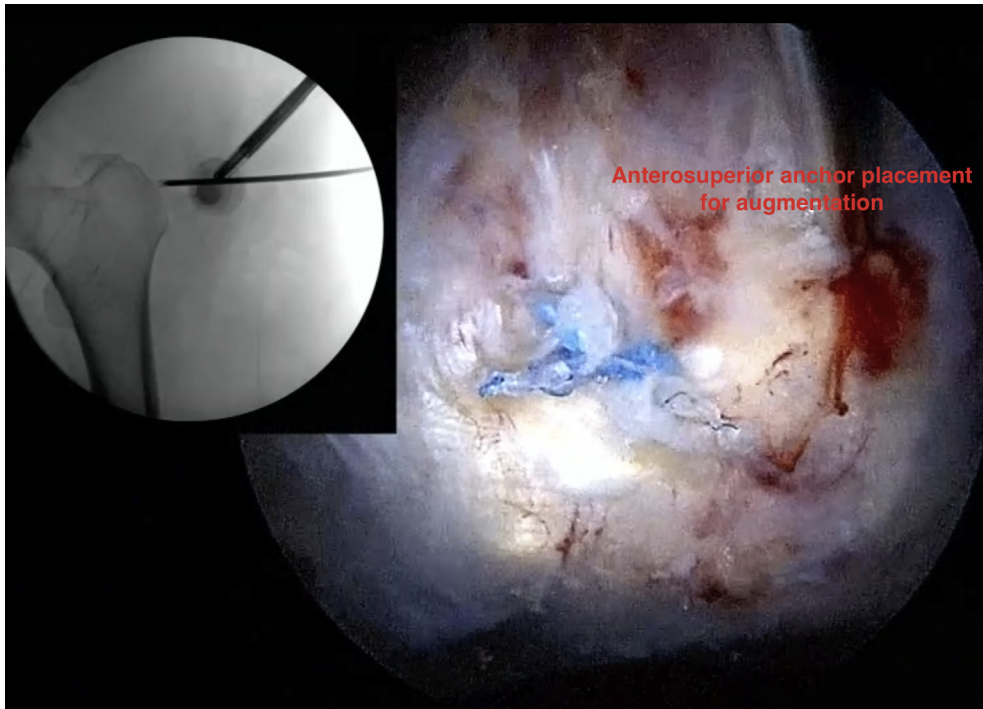


Fig 5. Placement of a 1.3-mm percutaneous anchor, single loaded, under fluoroscopic guidance.

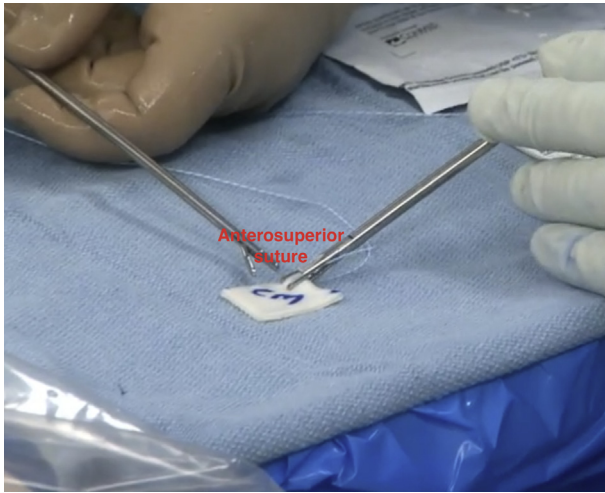


Fig 6. The graft is marked to help with the orientation of the graft during placement. The epidermal side of the graft should face superficial during fixation. An antegrade suture passer device is used to pass the suture from deep to superficial, and a grasper is used to retrieve the suture. A mulberry knot is then tied so it lies on the superficial (epidermal) surface of the graft.

Tendon Repair

A 17-gauge needle is then placed anteriorly, parallel to the greater trochanter to allow for suture passing and suture management. An accessory percutaneous PALA portal is also established for anchor placement. Between 1 and 5 triple-loaded all-suture anchors (Y-Knot RC 2.8 mm; Conmed Linvatec) are placed through the accessory percutaneous PALA portal depending on the size of the tear. Retrograde suture passers (Accupass Direct; Smith & Nephew) (Slim Raven; Conmed Linvatec) and antegrade suture passers (Spectrum Autopass; Conmed Linvatec) (Expressw 3, Depuy Mitek, Raynham, MA) are used to primarily repair the gluteus medius and minimus tendons back down to the footprint (Fig 3). Once all the sutures are tied and cut, the allograft can then be placed.

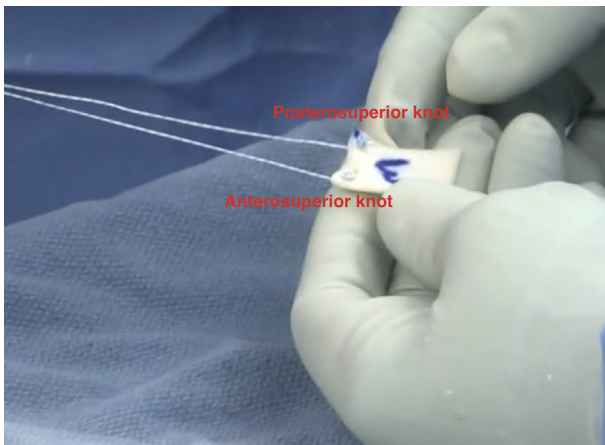


Fig 7. The graft is then oriented appropriately to the cannula with the anterosuperior and posterosuperior mulberry knots previously placed.

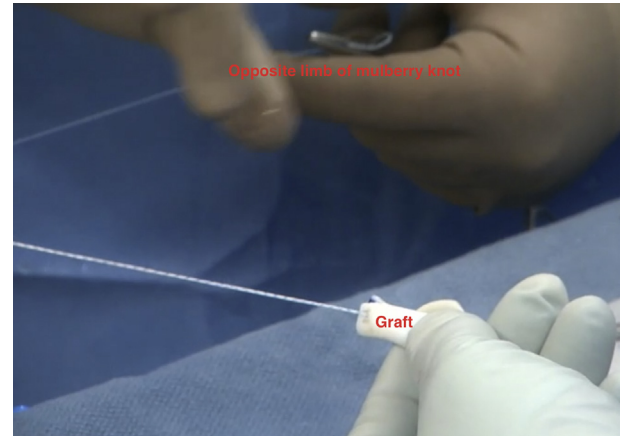


Fig 8. The graft is then folded longitudinally to ease delivery, and the opposite limbs of the previously placed anchors are used to shuttle the graft to the footprint.

Allograft Preparation, Delivery, and Initial Fixation

The footprint of the tendons is measured using a calibrated right angle probe with 5-mm markings (Fig 4). Superior to inferior as well as anterior to posterior measurements are made, and the graft is prepared on a separate Mayo stand. The graft should be fashioned into a rectangle based on the intraoperative measurements. Care should be taken to mark the epidermal surface of the graft using a surgical marker to ensure proper graft orientation. When implanted, the epidermal side of the graft should be superficial, whereas the dermal side should be deep and in contact with the tendon.

Two percutaneous anchors (Y-Knot Flex 1.3-mm Disposable Percutaneous Pack with T-Guide; Conmed

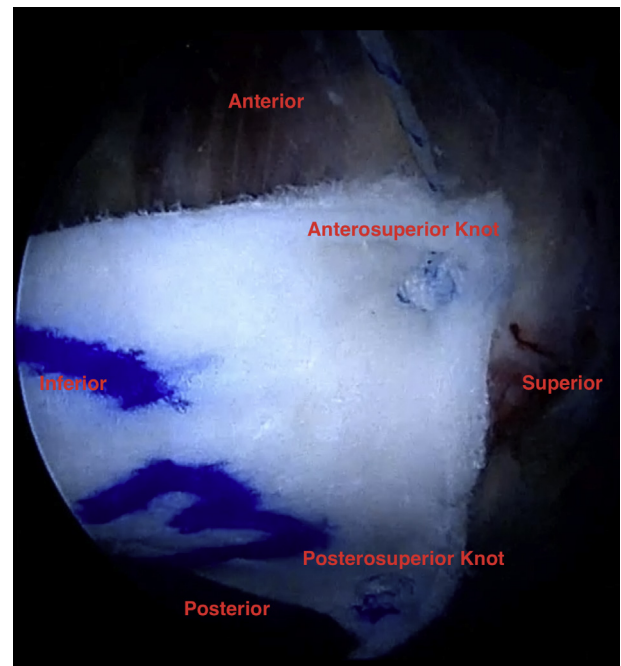


Fig 9. Fluoroscopic guided placement of the anteroinferior and posteroinferior 1.3-mm percutaneous anchors.

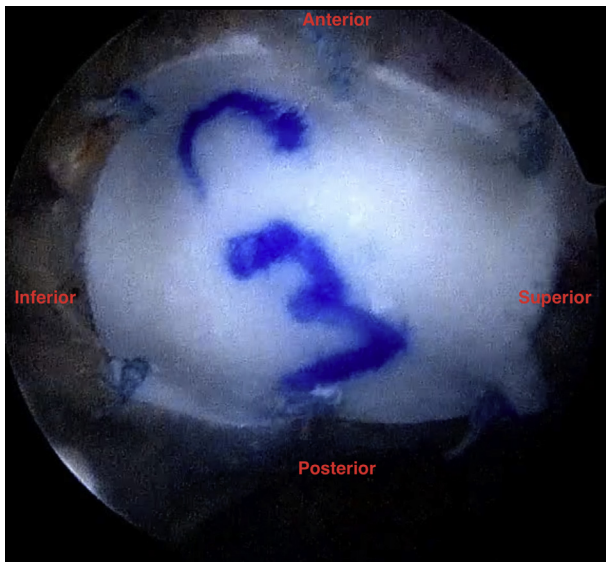


Fig 10. The final graft fixation with 6 knots tied compressing the graft to the footprint.

Linvatec) are placed transtendinously at the anterosuperior and posterosuperior portions of the footprint (Fig 5). One limb from each suture is then shuttled through the DALA portal, taking care to ensure no entanglement of the suture limbs. The anterosuperior suture is shuttled through the anterosuperior portion of the allograft with a free needle or antegrade suture passer, and a mulberry knot is tied (Fig 6). The posterosuperior suture limb is then passed through the posterosuperior portion of the graft, and another mulberry knot is tied (Fig 7). The graft is then placed at the aperture of the DALA cannula and folded in half along the longitudinal axis of the graft (Fig 8). The opposite limbs of the suture anchors are then pulled simultaneously, and an arthroscopic knot pusher is used to help the allograft traverse the cannula. The allograft is then unfurled onto the footprint, and the sutures are individually tied, securing the superior aspect of the allograft to the tendon.

Final Allograft Fixation

A looped suture grasper is used to hold the inferior portion of the allograft to the tendon and estimate the anteroinferior and posteroinferior placement of the

following 2 anchors (Fig 9). An additional anteroinferior and posteroinferior anchors are placed using the percutaneous guide through the DALA portal site at the level of the vastus lateralis tubercle. One limb of each suture anchor is then passed through the anteroinferior and posteroinferior aspects of the graft using an antegrade suture passer and then are tied. The graft is then stably attached to the footprint and additional fixation may be considered. Two additional suture anchors can be placed in the midportion of the graft, one anterior and one posterior, to provide rigid fixation of the allograft (Fig 10). Alternatively, if tissue quality is good, 2 free sutures can be passed through the allograft and native tendon if desired. Once the allograft is fully secured, testing of the native repair and allograft can be assessed by internally and externally rotating the limb, abducting and adducting, and flexing and extending while observing the graft and repair. As this is a technically demanding procedure, a knowledge of the pearls and pitfalls is invaluable (Table 1).

ITB Repair

The limb is then placed into internal rotation and neutral adduction. The anterior and posterior portions of the ITB are identified and using a self-retrieving suture passer (SpeedStitch; Smith & Nephew) are used to pass No. 2 Vicryl (Ethicon, Somerville, NJ) through the edges of the ITB. Three to five sutures are used to close the ITB anatomically.

Postoperative Rehabilitation

The patient is placed in an abduction brace (T-Scope Hip Brace; Breg, Carlsbad, CA) after surgery for 6 weeks and is made foot flat touch-down weight bearing for 5 weeks. Physiotherapy is initiated at the 2-week postoperative visit, focusing initially on gentle range of motion and isometrics. Progressive weight bearing as tolerated is initiated at week 6 postoperatively, with the goal of full weight bearing without an assistive device by postoperative week 8 to 10. Strengthening is initiated at that time point with the goal of full strength to be achieved by 24 weeks postoperatively.

Table 1. Pearls and Pitfalls of Allograft Augmentation of Gluteus Medius Tendon Repair

Pearls	Pitfalls
Proper patient position, minimal traction, and abduction of the leg to increase peritrochanteric space	Failing to establish portals in proper orientation and trajectory
Maintain adequate visualization and hemostasis throughout the case	Failing to obtain adequate visualization of footprint
Establish footprint for adequate sizing of the graft after repair	Failing to orient the graft appropriately while delivering to the footprint through the cannula
Use of mulberry knots and longitudinal fold of graft to “pull” the graft to the footprint properly	Failing to maintain suture management while fixating the graft
Good knot and loop security to compress the graft to the repair site	
Compliance of postoperative instructions while the graft is healing	

Table 2. Advantages and Disadvantages of Allograft Augmentation of Gluteus Medius Tendon Repair

Advantages	Disadvantages
Augments tendon repair in thin and attenuated tendons	Graft and anchor expense
Reproducible technique for a complex procedure	Strict patient compliance with postop restrictions required during the healing phase
Acellular human dermis provides immediate strength to repair while healing	Technically demanding for inexperienced hip arthroscopists
Can be used in patients with hypersensitivities	

Discussion

In 1997, the term “rotator cuff tear of the hip” was coined by Bunker et al.,⁸ and many of our principles for endoscopic gluteus medius and minimus repair are derived from the arthroscopic shoulder literature. The population of patients who have sustained a tear of the abductors is similar to the population of patients who sustain rotator cuff tears with respect to age and gender, with the incidence peaking between the fourth and sixth decades and being more common in females.⁴ Failure after rotator cuff repair have ranged from 11% to 94%, and gluteus medius retears have been shown to be from 16% to 35%.⁹⁻¹¹ Clearly, these numbers show the limited healing potential of these repairs. Because of this, augmenting the repair of the gluteus medius and minimus may lower the re-tear rate and provide improved outcomes for patients by providing immediate structural stability.

Unlike xenograft, allograft acellular dermis provides immediate structural strength to the repair as well as a biologic milieu for better tendon to bone healing (Table 2). The superior tensile strength as well as the non-crosslinked nature of the type 1 and 3 collagen, elastin, hyaluronin, and vitronectin provides an avenue for cellular infiltration and neovascularization of the graft with a stress shielding effect to the native repair. Acellular human dermal allograft has been shown to improve healing rates and outcomes in large rotator cuff tears in a safe and effective manner in multiple studies.^{7,12}

In conclusion, acellular human dermal allograft has been shown to be safe and effective in augmenting tendon repairs. We present augmentation of an endoscopic repair of a gluteus medius tear focusing on preparing, delivering, and fixation of the graft in a reproducible and safe manner.

References

1. Strauss EJ, Nho SJ, Kelly BT. Greater trochanteric pain syndrome. *Sports Med Arthrosc* 2010;18:113-119.
2. Davies JF, Stiehl JB, Davies JA, Geiger PB. Surgical treatment of hip abductor tendon tears. *J Bone Joint Surg Am* 2013;95:1420-1425.
3. Domb BG, Botser I, Giodano BD. Outcomes of endoscopic gluteus medius repair with minimum 2 year follow up. *Am J Sports Med* 2013;41:988-997.
4. Chandrasekaran S, Lodhia P, Gui C, Vemula SP, Martin TJ, Domb BG. Outcomes of open versus endoscopic repair of abductor muscle tears of the hip: A systemic review. *Arthroscopy* 2015;31:2057-2067.
5. Kaplan DJ, Dold AP, Fralinger DJ, Meislin RJ. Endoscopic gluteus medius repair augmented with bioinductive implant. *Arthrosc Tech* 2016;5:e821-e825.
6. Barber FA, Burns JP, Deutsch A, Labbé MR, Litchfield RB. A prospective randomized evaluation of acellular human dermal matrix augmentation for arthroscopic rotator cuff repair. *Arthroscopy* 2012;28:8-15.
7. Barber FA, Aziz-Jacobo J. Biomechanical testing of commercially available soft-tissue augmentation materials. *Arthroscopy* 2009;25:1233-1239.
8. Bunker TD, Esler CN, Leach WJ. Rotator-cuff tear of the hip. *J Bone Joint Surg Br* 1997;79:618-620.
9. Le BT, Wu XL, Lam PH, Murrell GA. Factors predicting rotator cuff retears: An analysis of 1000 consecutive rotator cuff repairs. *Am J Sports Med* 2014;42:1134-1142.
10. McGonagle L, Haebich S, Breidahl W, Fick DP. MRI and clinical analysis of hip abductor repair. *Hip Int* 2015;25:24-27.
11. Makridis KG, Lequesne M, Bard H, Djian P. Clinical and MRI results in 67 patients operated for gluteus medius and minimus tendon tears with a median follow-up of 4.6 years. *Orthop Traumatol Surg Res* 2014;100:849-853.
12. Agrawal V. Healing rates for challenging rotator cuff tears utilizing an acellular human dermal reinforcement graft. *Int J Shoulder Surg* 2012;6:36-44.