

Case Report

Removal of a Metallic Stent after 9 Years of Placement That Caused Tracheal Stenosis: A Rare Case Report

Torahiko Nakashima^a Koji Yamazaki^b Ryutaro Uchi^a Hideoki Uryu^a

^aDepartment of Otorhinolaryngology, Head and Neck Cancer Center, National Hospital Organization Kyushu Medical Center, Fukuoka, Japan; ^bDepartment of Thoracic Surgery, National Hospital Organization Kyushu Medical Center, Fukuoka, Japan

Keywords

Tracheal stenosis · Metallic stent removal · Percutaneous cardiopulmonary support

Abstract

Introduction: Metallic stents are widely used to prevent airway obstruction for tracheal stenosis caused by malignant diseases. Although their efficacy has been recognized, there is no established evidence surrounding their long-term safety. We report a case of airway stenosis caused by a metallic tracheal stent. Removal of the stent to secure the airway was difficult and extremely complicated. **Case Presentation:** A 50-year-old male suffering from dyspnea caused by malignant lymphoma (diffuse large B-cell lymphoma) of the thyroid gland was treated with a metallic tracheal stent. After remission of the lymphoma, stenosis of the stent lumen developed gradually, and the patient complained of dyspnea. Tracheostomy could not be performed due to the metallic stent. Since the patient was unable to intubate, the stent was removed under general anesthesia with partial percutaneous cardiopulmonary support 9 years after the stent placement. **Conclusion:** Otolaryngologists should be aware of the possibility of severe stenosis following the long-term placement of a metallic tracheal stent.

© 2024 The Author(s).
Published by S. Karger AG, Basel

Introduction

Airway stenting is commonly used to dilate the stenotic tracheal lumen and maintain patency. Self-expandable metallic stents can be relatively easily placed under fiberoptic guidance and are commonly used for airway management of tracheal stenosis caused by

Correspondence to:
Torahiko Nakashima, nakashima.torahiko.es@mail.hosp.go.jp

malignant diseases; however, long-term placement is controversial because of severe complications such as stent migration and granulation formation. Once placed, metallic stents are very difficult to replace or remove.

Here, we report a case of airway obstruction caused by intraluminal granulation vegetation in a metallic tracheal stent that had been in place for 9 years. As the patient could not be intubated, the stent was removed by open tracheal surgery under general anesthesia with partial support of percutaneous cardiopulmonary support (PCPS). The CARE Checklist has been completed by the authors for this case report, attached as online supplementary material.

Case Presentation

A 50-year-old male suffering from dyspnea and diffuse anterior neck swelling was admitted to our hospital. Severe tracheal stenosis due to abnormal thyroid swelling was observed (Fig. 1a). Emergency management of the airway was required, and a self-expandable metallic tracheal stent was placed securing the tracheal lumen. Biopsy of the thyroid gland revealed malignant lymphoma (ML) (diffuse large B-cell lymphoma). The disease was treated by systemic chemotherapy, and complete remission was achieved (Fig. 1b).

Eight years later, the patient eventually developed dyspnea. Intraluminal granulation formation and stenosis were observed (Fig. 1c, 2). Laser dissection of the granulation tissue was performed multiple times without fundamental improvement, and removal of the stent was required. Tracheostomy could not be performed due to the presence of the metallic stent. Because the patient could not be intubated, the stent was removed under general anesthesia with partial support of PCPS, and tracheostomy was performed. As shown in Figure 3, the lumen of the metallic stent was obstructed by granulation tissue. One year after the primary surgery, the tracheal wall was reconstructed using a local skin flap, and the tracheostomy was closed. The patient has been free from respiratory symptoms for 5 years after the final surgery.

Discussion

Airway stents remain an important strategy for the management of tracheal stenosis. The two main types of tracheal stents are silicone and metallic; both have certain demerits, and stent selection should be carefully discussed based on the disease causing the stenosis.

Self-expandable metallic stents are widely used in emergencies because of their ease of insertion and resulting rapid improvement of symptoms compared to silicone stents. Although their efficacy has been recognized, there is no established evidence for long-term safety. Jeong et al. [1] have reported that 15 (75%) out of 20 patients who underwent metallic tracheal stent placement required stent replacement over a median of 65 months because of chronic complications. In contrast, silicone stents have demonstrated moderate efficacy for the long-term management of benign tracheal stenosis [2]. With metallic stents, once granulation tissue formation occurs, it is difficult to stop the development of luminal stenosis with conservative treatment. Endotracheal endoscopic metallic stent removal has been reported [3]; however, complete removal is extremely complicated. Hennessy et al. [4] reported a case of metallic stent removal by open tracheal surgery using veno-venous extracorporeal membrane oxygenation.

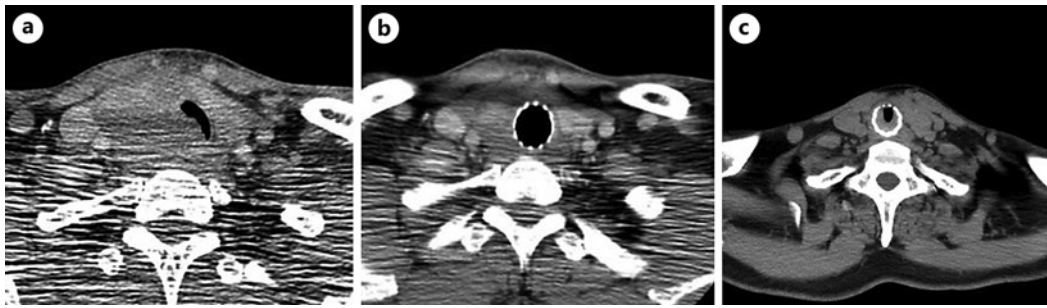


Fig. 1. **a** Computed tomography (CT) revealed enlargement of the right lobe of the thyroid gland causing severe compression and stenosis of the trachea. **b** A metallic stent was placed in the trachea. The size of the thyroid gland is normalized after drug therapy for malignant lymphoma. **c** CT revealed severe stenosis of the metallic stent 8 years after treatment.

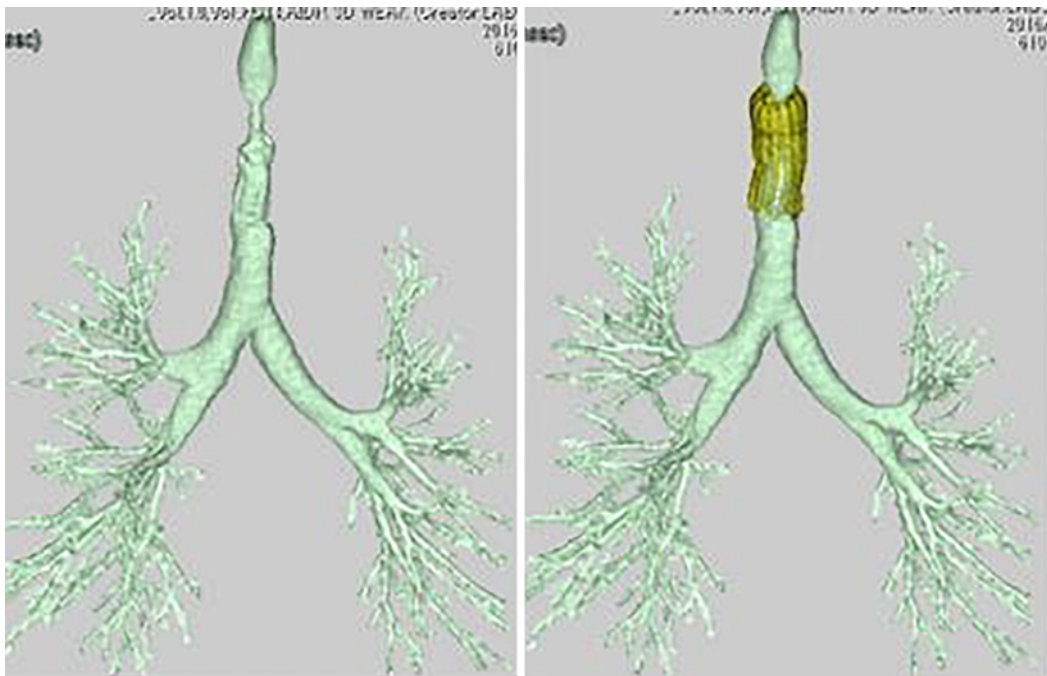


Fig. 2. A 3-D reconstructed image of the stenotic trachea caused by granulation in the metallic stent.

In our case, after 9 years of placement, the stent was completely buried and covered with granulation tissue. Endoscopic removal was impossible, and it was decided that the best approach to the removal of the stent was open surgery along with securing the circulation dynamics using PCPS. The stent was successfully removed, and the patient remained symptom free for 5 years without restenosis.

Several points of reflection should be considered from this case. Whether it was initially necessary to place a tracheal stent for ML of the thyroid case as well as whether the choice of a metallic stent was appropriate. Additionally, why the stent was not removed earlier after ML treatment would also be important to understand. This case demonstrated that the long-term placement of metallic stents is extremely inappropriate. Looking back at the initial emergent situation facing a patient requiring urgent airway control,

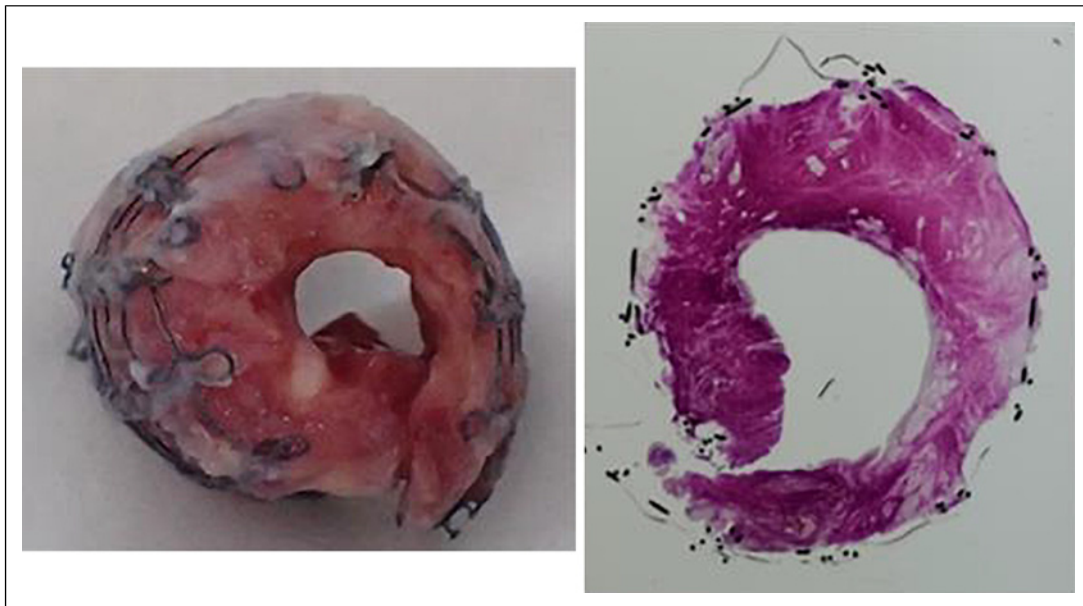

Fig. 3. Macroscopic and microscopic (HE staining) of the extracted metallic stent. Extreme granulation is observed in the lumen.

performing a tracheostomy and cutting into the tumor might have been a choice. However, the decision of placing a metallic tracheal stent seems to be an appropriate strategy. The major reflection of this case may be the delay of removing the stent which was no longer needed. It is important to determine the timing of stent removal once the primary disease causing the stenosis has been treated. Alazemi et al. [5] reported that endoscopic removal of a metallic stent is feasible with no major complications when removed within 30 days of insertion. Removal after long-term placement (over 30 days) was associated with complications including re-obstruction, ventilation problems, and airway re-stenting. Multidisciplinary team discussions including those with otolaryngologists, medical oncologists, and respiratory surgeons, are mandatory for managing tracheal stenosis. It is necessary to predict the long-term outcomes of the stenosis based on the pathology of the disease and to select an appropriate method to secure the airway.

Conclusion

Removal of a metallic tracheal stent after long-term placement is extremely difficult. The indication and selection of tracheal stents are important, and once placed, continuous observation is required to determine the correct time for stent removal. Otolaryngologists should be aware of the possibility of severe stenosis following long-term tracheal stent placement.

Statement of Ethics

This report was approved by the Institutional Ethics Review Board of the Kyushu Medical Center (23H109). Written informed consent was obtained from the patient for publication of this report and any accompanying images.

Conflict of Interest Statement

The authors have no conflicts of interest to declare.

Funding Sources

No financial support was obtained for this publication.

Author Contributions

T.N., K.Y., R.U., and H.U. have contributed to the study and manuscript. All of the authors approved the manuscript to be published.

Data Availability Statement

All data supporting the findings of this report are included in this article. Further inquiries can be directed to the corresponding author.

References

- 1 Jeong BH, Ng J, Jeong SH, Kim H, Kim H. Clinical outcomes of complications following self-expandable metallic stent insertion for benign tracheobronchial stenosis. *Medicina*. 2020;56(8):367.
- 2 Chen DF, Chen Y, Zhong CH, Chen XB, Li SY. Long-term efficacy and safety of the Dumon stent for benign tracheal stenosis: a meta-analysis. *J Thorac Dis*. 2021;13(1):82–916.
- 3 Chawla R, Madan A, Singh I, Mudoiya R, Chawla A, Gupta R, et al. Removal of self expandable metallic airway stent: a rare case report. *Lung India*. 2013;30(1):64–6.
- 4 Hennessy MM, Moorthy A, Frizelle H, Griffin M, Reidy B, Eaton D, et al. Complications of an uncovered metallic tracheal stent managed by veno-venous extracorporeal membrane oxygenation: a case report. *BJA Open*. 2022; 2:100011.
- 5 Alazemi S, Lunn W, Majid A, Berkowitz D, Michaud G, Feller-Kopman D, et al. Outcomes, health-care resources use, and costs of endoscopic removal of metallic airway stents. *Chest*. 2010;138(2):350–6.