

# Does CT help in reducing RT-PCR false negative rate for COVID-19?

Anirudh Kohli, Anagha Joshi<sup>1</sup>, Ankur Shah<sup>2</sup>, Richa D Jain<sup>3</sup>, Abhishek Gorlawar<sup>4</sup>, Amol Dhapare<sup>5</sup>, Jigar Desai<sup>6</sup>, Aditya Shetty, Chirag Shah<sup>7</sup>, Prachi Ostwal<sup>8</sup>, Anisha Talraja<sup>1</sup>

Department of Radiodiagnosis, Breach Candy Hospital, Mumbai, <sup>1</sup>Department of Radiodiagnosis, LTMMC Sion Hospital, Mumbai <sup>2</sup>Sadbhav Diagnostics, Ahmedabad, <sup>3</sup>Department of Radiodiagnosis, Aster CMI Hospital, Bengaluru, <sup>4</sup>Ravi Imaging and Jupiter Hospital, Mumbai, <sup>5</sup>Nivaran and Pulse Scan Centre, Mumbai, <sup>6</sup>NM Medical Centre, Mumbai, <sup>7</sup>Advance Radiolmaging Centre, Ahmedabad, <sup>8</sup>Pinnacle Imaging Centre, Mumbai, India

**Correspondence:** Dr. Richa D Jain, Department of Radiodiagnosis, Aster CMI Hospital, Bangalore, Karnataka, India.  
E-mail: drrichajain20@gmail.com

## Abstract

**Background:** Early detection is the key to contain the ongoing pandemic. The current gold standard to detect SARS CoV2 is RT-PCR. However, it has a high false negative rate and long turnaround time. **Purpose:** In view of the high sensitivity of CT in detection of lower respiratory tract pathologies, a study of 2581 patients comparing RT-PCR status with CT findings was undertaken to see if it augments the diagnostic performance. **Materials and Methods:** A multi centre prospective study of consecutive cases was conducted. All CT studies suggestive of COVID 19 pneumonia were collated and evaluated independently by three Radiologists to confirm the imaging diagnosis of COVID-19 pneumonia. The RT-PCR values were retrospectively obtained, based on the RT-PCR values, CT studies were categorised into three subgroups, positive, negative and unknown. CT features from all three groups were compared to evaluate any communality or discordance. **Results:** Out of the 2581 patients with positive CT findings for COVID pneumonia, 825 were females and 1,756 were males in a wide age group of 28-90 years. Predominant CT features observed in all the subgroups were Ground glass densities 94.8%, in mixed distribution (peripheral and central) (59.12%), posterior segments in 92% and multilobar involvement in 70.9%. The CT features across the three subgroups were statistically significant with a *P* value <0.001. **Conclusion:** There was a communality of CT findings regardless of RT-PCR status. In a pandemic setting ground glass densities in a subpleural, posterior and basal distribution are indicative of COVID 19. Thus CT chest in conjunction to RT PCR augments the diagnosis of COVID 19 pneumonia; utilization of CT chest may just be the missing link in closing this pandemic.

**Key words:** Coronavirus disease-2019; ground glass opacity; reverse transcriptase polymerase chain reaction; severe acute respiratory syndrome

## Introduction

The key to containment of COVID-19 has been to detect individuals positive for the SARS-CoV-2 virus, isolate them to prevent any further spread of the virus. SARS-CoV-2 virus has an affinity for ACE receptors, which are abundant in the alveoli. These induce diffuse alveolar damage, which

may progress to an acute respiratory syndrome. CT scan is very sensitive in demonstrating alveolar pathology. The current gold standard to detect SARS COV-2 is RT-PCR; however, numerous studies have demonstrated a high false

This is an open access journal, and articles are distributed under the terms of the Creative Commons Attribution-NonCommercial-ShareAlike 4.0 License, which allows others to remix, tweak, and build upon the work non-commercially, as long as appropriate credit is given and the new creations are licensed under the identical terms.

**For reprints contact:** WKHLRPMedknow\_reprints@wolterskluwer.com

**Cite this article as:** Kohli A, Joshi A, Shah A, Jain RD, Gorlawar A, Dhapare A, et al. Does CT help in reducing RT-PCR false negative rate for COVID-19? Indian J Radiol Imaging 2021;31:S80-6.

**Received:** 06-Sep-2020

**Revised:** 28-Oct-2020

**Accepted:** 24-Dec-2020

**Published:** 23-Jan-2021

### Access this article online

#### Quick Response Code:



**Website:**  
www.ijri.org

**DOI:**  
10.4103/ijri.IJRI\_739\_20

negative rate of 30-40%.<sup>[1-4]</sup> In view of high false negative rate of RT-PCR and high sensitivity of CT to detect lower respiratory tract pathological changes, we undertook a study to compare RT-PCR status with CT scan findings in a large cohort of 2581 patients.

## Materials and Methods

A multicentre prospective study of consecutive cases was conducted across seven centres in two large cities in Western India- Mumbai and Ahmedabad.

Two of the five centres in Mumbai were large hospitals, one private and one public hospital, and the other three were stand alone diagnostic centres, the two Ahmedabad centres were stand alone diagnostic centres. This provided a wide spectrum of patients. All CT studies suggestive of COVID-19 pneumonia based on well-documented features in literature were collated. These were evaluated independently by three radiologists with 30 years, 15-year and 8-year experience to confirm the imaging diagnosis of COVID pneumonia. The RT-PCR values were retrospectively obtained. Based on the RT-PCR values the CT studies were grouped into three groups – Positive, Negative and unknown. The unknown group were individuals who did not want to reveal their RT-PCR status or self-isolated based on CT results.

The CT features from all three groups were compared to evaluate any communality or discordance.

The CT features evaluated were as follows:

1. Lung opacity type:
  - A. Ground glass<sup>[5-8]</sup>
  - B. Consolidation<sup>[6,7]</sup>
  - C. Mixed pattern of consolidation/ground glass
2. Location of abnormality:
  - A. Subpleural, peribronchovascular, mixed<sup>[9]</sup>
  - B. Anterior, posterior<sup>[10]</sup>
  - C. Upper lobe, lower lobe, multi-lobar.
3. Morphology of opacity:
  - A. Crazy paving<sup>[5,11,12]</sup>
  - B. Atoll sign<sup>[13,14]</sup>
  - C. Halo sign<sup>[8,15]</sup>
  - D. Vacuolar sign<sup>[16]</sup>
  - E. Prominent vessels in opacity<sup>[7,8]</sup>
  - F. Dilated bronchioles in opacity<sup>[7,17,18]</sup>
  - G. Subpleural curvilinear fibrosis.<sup>[13]</sup>

## Results

### Patient characteristic

Totally, 2,581 patients with positive CT findings for COVID pneumonia were collated. Of them 825 were females and 1,756 were male patients. The age group included patients from 28 years to 90 years; mean age of 60 +/-30 years.

### CT evaluation in RT PCR Subgroups: [Table 1]

Group A - 1445 (56%) positive RT PCR.

Group B - 477 (18.5%) negative initial RT PCR.

Group C - 659 (25.5%) unknown RT PCR results.

### CT Features across subgroups: [Table 2]

Predominant CT features observed in all the patients were Ground glass densities (94.8%), in mixed distribution: peripheral and central (59.12%), in the posterior segments (92%) and multilobar involvement in 70.9% patients.

The ancillary features like Crazy Paving, Atoll sign, halo sign, prominent vessel, prominent bronchiole and vacuolar signs were seen in smaller groups of patients; Collectively seen in 17-45% of the patients.

## Discussion

COVID-19 is a highly infectious disease caused by a single-stranded RNA corona virus- SARS COV 2.<sup>[19]</sup> The main routes of spread are human to human via droplets as well as surface contamination. The key to control of COVID-19 is to break the human to human contact chain. To achieve this, early detection and prompt isolation is imperative. RT-PCR is the current gold standard to detect SARS-CoV-2; however, the false negative rate ranges from 30 to 40%.<sup>[1,2]</sup> There are numerous reasons for this high false negative rate, these are related to sampling, transportation and processing errors. RT-PCR may also be negative if the viral load is low, a second/third or fourth RT-PCR is positive.<sup>[3,4]</sup> Sensitivity of RT-PCR is maximum between 5<sup>th</sup> and 7<sup>th</sup> day, lower before day 5, and peters off after day 7 of contracting the infection.<sup>[9,20]</sup> Additionally in resource constrained regions RT-PCR may not be freely available, or if available with a significant turnaround time spanning from 24 to 48 hrs. The accuracy may be improved in certain centres with better training and facilities; however, COVID-19 being a global pandemic it is difficult to ensure uniform quality. Thus, the main concerns are the high false negative rate, in resource constrained environments where RT-PCR is not freely available or with long turn around times. Undetected individuals are infectious and unless isolated, will be mediums for transmission of SARS COV 2, thus perpetuating the pandemic.<sup>[21-23]</sup>

Symptomatology is also not a criteria. Numerous studies have documented asymptomatic individuals as well as symptomatic patients in the pre symptomatic phase are known to transmit the infection.<sup>[24]</sup> CT screening of asymptomatic RT-PCR positive individuals on the diamond princess cruise ship showed findings of pneumonia in 54%.<sup>[25]</sup> Numerous other studies have also supported this finding of asymptomatic with positive CT features.<sup>[26]</sup>

**Table 1: Subgroup features**

	Group A (n=1445)	Group B (n=477)	Group C (n=659)	Total (n=2581)	Statistical Significance P
-	56%	18.5%	25.5%	-	-
Mixed (Peripheral + Central)	923 63.9%	254 53.2%	349 53%	1526 59.12%	
Peripheral	499 34.5%	211 44.2%	285 43.2%	995 38.55%	<0.001
Central	23 1.6%	12 2.5%	25 3.8%	60 2.33%	
Posterior	1330 92%	438 91.8%	607 92.1%	2375 92.0%	
Anterior	115 7.9%	39 8.1%	52 7.9%	206 8.0%	0.001
GGO (Pure GGO)	1105 76.5%	392 82.2%	546 82.8%	2043 79.15%	
Consolidations	75 5.2%	10 2.1%	9 1.4%	94 3.64%	<0.001
Mixed (GGO + Consolidations)	265 18.3%	75 15.7%	104 15.8%	444 17.21%	
Upper	43 3%	17 3.5%	36 5.4%	96 3.7%	
Lower	246 17%	169 35.4%	242 36.7%	657 25.4%	<0.001
Multilobar	1156 80%	291 61%	381 57.9%	1828 70.9%	

**Table 2: CT features across subgroups**

Pattern	Percentage n=2581
Predominant GGO	94.8%
Predominant Peripheral distribution	38.55%
Mixed (Central and peripheral) distribution	59.12%
Subpleural lines	45.3%
Crazy Paving	17.7%
Halo/reverse halo sign	17.9%
Prominent vessels	24.7%
Atoll sign	5%
Vacuolar sign	14.4%

In view of these limitations of RTPCR there is need to increase the accuracy of RTPCR or supplement with another diagnostic technique to reduce the false negative rate thus increasing the accuracy of detection of SARS COV-2.

Corona viruses are characterised by spike proteins which are optimised to engage human ACE 2 receptors. Gaining entry into the cell via proteolytic action and membrane fusion. ACE 2 receptors are in abundance in type 2 alveolar epithelial cells, GI tract, heart, endothelium and kidney. The lungs are the most vulnerable because of their large surface area, as well as type 2 alveolar cells act as a reservoir for viral replication. After gaining entry into the cell, viral genome replication occurs triggering apoptosis, release of pro inflammatory cytokines, exudation into alveolar space with associated diffuse alveolar damage.<sup>[19,27,28]</sup> These appear as ground glass densities on imaging.<sup>[5-8]</sup> With increasing body immune response there is increasing exudation resulting in consolidation.<sup>[6,7,27]</sup> As a result a mixed appearance of ground glass densities and consolidation may be seen on imaging.<sup>[29-31]</sup> As the infectious process and body responses mount different features of progression and regression, a variety of internal appearances may be seen on imaging. The internal contents may be visualised such as central clearing of ground glass, known as Atoll sign.<sup>[13,14]</sup>

Progression of inflammation along the periphery of consolidation is seen as ground glass on the periphery of consolidation - Halo sign.<sup>[8,15]</sup> There may be interlobular septal thickening due to prominence of lymphatics superimposed on ground glass densities, appearing as a crazy paving<sup>[5,11,12]</sup> appearance.<sup>[32]</sup> Presence of ACE 2 receptors in endothelium result in inflammation of the vessels, vessels appear prominent in the affected areas.<sup>[19]</sup> There may be intravascular thrombosis with resultant hemorrhagic infarction. Most cases resolve with fibroblast proliferation which may leave a residue of organising pneumonia<sup>[33]</sup> or fibrosis particularly in the subpleural regions.<sup>[13]</sup>

In a small percentage the alveolar cell damage progresses to acute respiratory distress syndrome resulting in a white out appearance to the lungs.<sup>[27]</sup>

CT is extremely sensitive to early pathological changes in the alveoli as demonstrated with HRCT in interstitial lung disease over the last few decades. This high sensitivity of CT with relatively typical features for COVID-19 has been borne out by numerous studies.<sup>[1,2,5,34-36]</sup>

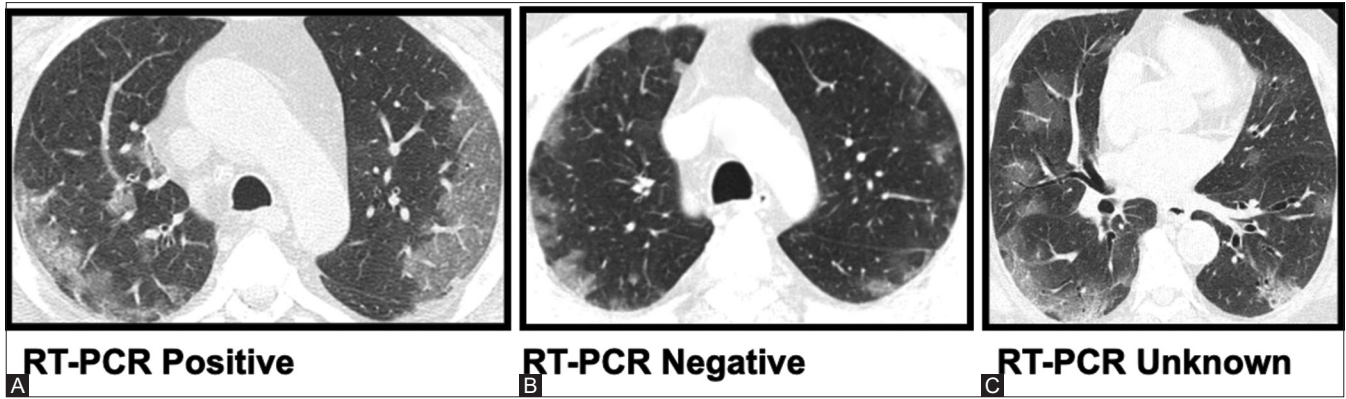
In our study we found similar findings. In a large cohort of 2,581 patients ground glass densities/consolidations in a posterior, peripheral location often with multilobar involvement were found in COVID 19 pneumonia regardless of the PCR status, positive, negative and unknown [Figures 1-3].

Indicating the specificity of CT features of COVID 19 in the setting of this pandemic. As well as the positivity of CT in the setting of negative RT-PCR.<sup>[36]</sup>

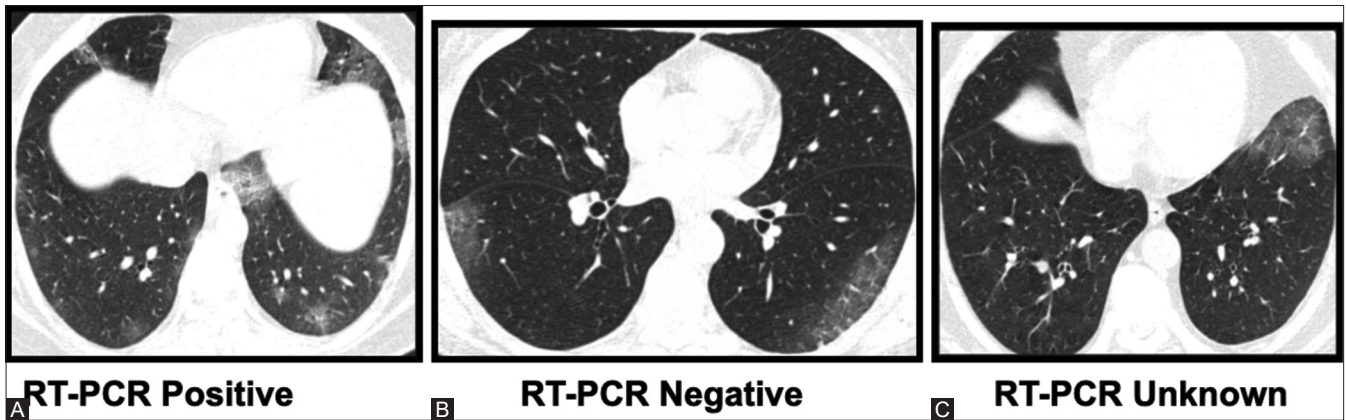
Ancillary findings such as crazy paving, Atoll sign, Halo sign, prominent vessel, prominent bronchiole and vacuolar sign as in other studies are seen in our study also regardless of RT PCR status, however, are not specific for COVID 19.

This is not surprising as RTPCR and CT scan evaluate different aspects of COVID 19.

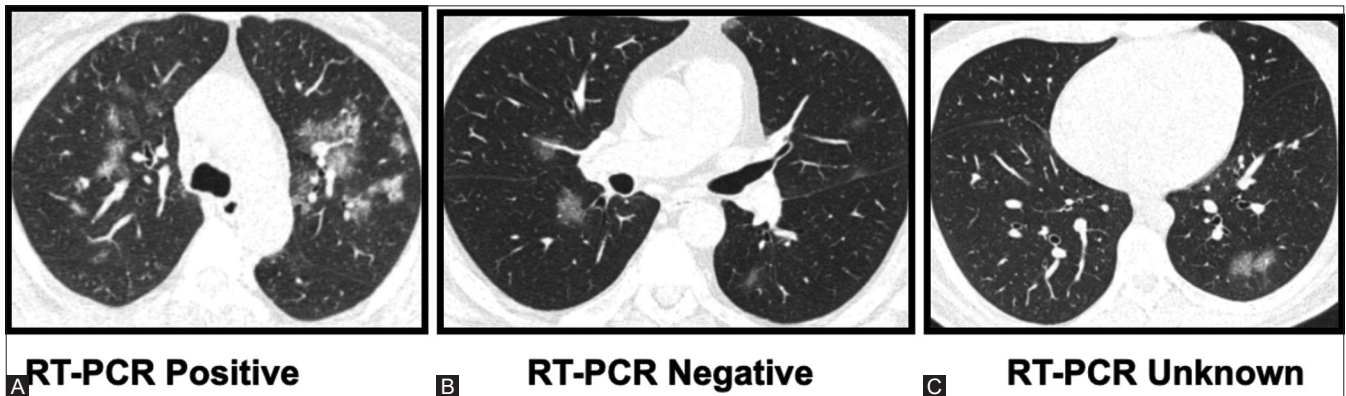




**Figure 1 (A-C):** Typical bilateral peripheral /sub pleural and central ground glass densities suggesting COVID-19 Pneumonia. These examples demonstrate communality of appearances irrespective of RT PCR status



**Figure 2 (A-C):** Subtle bilateral peripheral/sub pleural ground glass densities suggesting COVID-19 pneumonia in pandemic. Demonstrating communality of appearances in a pandemic irrespective of RT PCR status



**Figure 3 (A-C):** Peri- bronchovascular ground glass densities indicative of atypical appearance of COVID 19 pneumonia. These examples also demonstrate communality of appearances irrespective of RT PCR Status

Then why is CT not used to reduce the false negative rate thus helping curb the spread of SARS-CoV2.

Guidelines issued early during the pandemic dissuaded the usage of CT.<sup>[37]</sup> The main reasons for not advocating CT were<sup>[37-40]</sup>

1. Low specificity of CT,
2. Advocacy of CT may overwhelm existing resources as well as may reduce access of non covid patients to imaging suites,

3. CT may act as a potential disease transmitter via surface contamination, especially exposure to imaging department staff
4. Utilisation of ionising radiation.

Most of these guidelines were constituted in the early part of the pandemic, in fact coinciding with WHO declaration of a Pandemic. Five months have passed, the pandemic has raged on with no sign of abatement. The number of cases has increased from hundred thousand to 21.5 million- 250

x increase! As we reflect back, all these points of concern can be addressed hopefully with a fresh view for the future.

The specificity of CT though has been questioned especially in its ability to differentiate from other viral pneumonias and other chronic lung diseases such as small airway disease, chronic eosinophilic pneumonia, hypersensitivity pneumonitis. There are numerous publications which have helped differentiate between these different pathological processes.<sup>[41,42]</sup> SARS, H1N1 and Covid-19 have similar specific appearances of multi focal areas of ground glass density in a subpleural location with lower lobe preponderance.<sup>[14,32,43-51]</sup> Differentiation between these is difficult as the appearances overlap.

However, in a pandemic due to the sheer propensity of a number of cases, these typical patterns as well as atypical patterns point towards COVID-19, other diseases recede into the background due to sheer numbers. Sensitivity is the key, not specificity.<sup>[40]</sup> Social distancing has been advocated extensively through every medium possible, health care establishments have become hotspots for COVID 19. This has resulted in significant drop in non-Covid imaging volumes, thus lack of access to imaging suites for non-Covid patients does not really arise. In fact imaging facilities are extremely under utilised : in a recent study imaging volumes plummeted 75 to 90%. Imaging studies done for emergency medical conditions such as stroke etc., also reduced significantly.<sup>[52]</sup> Diseases actually disappeared in the pandemic providing health care establishments capabilities to cater to COVID 19 patients.<sup>[52-54]</sup>

Protocols for surface decontamination and infection control procedures are now very well documented. Personal protective equipment, surface decontamination of CT gantry and table as well as air exchanges<sup>[55,56]</sup> to remove any aerolisation are required to be practiced by all imaging facilities as asymptomatic COVID positive patients may be scanned for other symptoms, COVID pneumonia being incidentally detected.

There are also numerous means to reduce the radiation and achieve low dose CT studies minimising the utilisation of ionising radiation. Modulating tube current to body habitus, increasing the slice thickness to 1.5 mm, increasing the pitch to 1.5, collimating scan to cover apices to bases helps to reduce scan time and MA thus reducing MAs. The KV may be reduced in thinner individuals to 100Kv. Iterative reconstructions further help to reduce radiation dose. In a recent study utilising these parameters the CTDI vol was reduced significantly from 3.4mGy to 0.4 mGy.<sup>[57,58]</sup>

A number of studies from China, where the pandemic started, have advocated the utilisation of CT as a tool

to detect COVID-19, as well as also have alluded to the fact that CT features are independent of the RT PCR status.<sup>[1,2,44,58,59]</sup> China, the most populous country,<sup>[60]</sup> where the pandemic started has reported only 84,000 infections out of a world total of 21.5 million with a very low level of new infections.<sup>[61]</sup>

In this study we did not attempt to determine the sensitivity of CT vis a vis RT-PCR as all patients with positive RT-PCR were not scanned. Negative CT studies with positive RT-PCR is well documented. We also did not attempt to study the false positive rate of CT though most RT-PCR negative patients underwent respiratory panel for atypical pneumonia as co-infections between atypical pneumonia and SARS COV-2 has been documented.<sup>[62]</sup>

## Conclusion

SARS COV 2 is a highly infectious virus. Accurate diagnostic methods are required to identify and isolate individuals harbouring the virus regardless of symptomatology to reduce further human to human transmission and consequent public contamination. The gold standard is RT-PCR, this however has a significant false negative rate. Unless the false negative RT-PCR rate is reduced, disease transmission will continue. In a large cohort of 2,581 patients this study found a communality of CT findings regardless of RT-PCR status. Ground glass densities in a subpleural, posterior and basal distribution were indicative of COVID-19 in a pandemic setting. CT scan due to its high sensitivity, quick turnaround time is a very useful adjunct to RT-PCR. It cannot be used as a standalone tool, as a negative CT cannot rule out COVID-19. On the flip side, a negative RT-PCR does not rule out COVID-19. There is a symbiotic relationship between RT-PCR and CT scan because they evaluate different aspects of SARS COV-2. Thus, CT as an adjunct test can be very useful in reducing false negative RT-PCR, thus assisting in controlling the pandemic. Utilisation of CT scan may just be one of the missing keys in closing this pandemic.

## Financial support and sponsorship

Nil.

## Conflicts of interest

There are no conflicts of interest.

## References

1. Ai T, Yang Z, Hou H, Zhan C, Chen C, Lv W, *et al.* Correlation of chest CT and RTPCR testing in coronavirus disease 2019 (COVID-19) in China: A report of 1014 cases. *Radiology* 2020;296:E32-40.
2. Fang Y, Zhang H, Xie J, Lin M, Ying L, Pang P, *et al.* Sensitivity of chest CT for COVID-19: Comparison to RT-PCR. *Radiology* 2020;296:E115-7.
3. SUMMARY COVID-19 RT-PCR TEST – FDA. Available from: [www.fda.gov/media/136151/download](http://www.fda.gov/media/136151/download). [Last accessed on 2020 Apr 15].

4. Corman VM, Landt O, Kaiser M, Molenkamp R, Meijer A, Chu DK, *et al.* Detection of 2019 novel coronavirus (2019-nCoV) by real-time RT-PCR. *Euro Surveill* 2020;25:2000045.
5. Bernheim A, Mei X, Huang M, Yang Y, Fayad ZA, Zhang N, *et al.* Chest CT findings in coronavirus disease-19 (COVID-19): Relationship to duration of infection. *Radiology* 2020;295:200463.
6. Salehi S, Abedi A, Balakrishnan S, Gholamrezanezhad A. Coronavirus disease 2019 (COVID-19): A systematic review of imaging findings in 919 patients. *AJR Am J Roentgenol* 2020;215:87-93.
7. Parry AH, Wani AH, Yaseen M, Jehangir M, Choh NA, Dar KA. Spectrum of chest computed tomographic (CT) findings in coronavirus disease-19 (COVID-19) patients in India. *Eur J Radiol* 2020;129:109147.
8. Caruso D, Zerunian M, Polici M, Pucciarelli F, Polidori T, Rucci C, *et al.* Chest CT Features of COVID-19 in Rome, Italy. *Radiology* 2020;296:E79-85.
9. Kucirka LM, Lauer SA, Laeyendecker O, Boon D, Lessler J. Variation in false-negative rate of reverse transcriptase polymerase chain reaction-based SARS-CoV-2 tests by time since exposure. *Ann Intern Med* 2020;173:262-7.
10. Carotti M, Salaffi F, Sarzi-Puttini P, Agostini A, Borgheresi A, Minorati D, *et al.* Chest CT features of coronavirus disease 2019 (COVID-19) pneumonia: Key points for radiologists. *Radiol Med* 2020;125:636-46.
11. Han R, Huang L, Jiang H, Dong J, Peng H, Zhang D. Early clinical and CT manifestations of coronavirus disease 2019 (COVID-19) pneumonia. *AJR Am J Roentgenol* 2020;215:338-43.
12. Parry AH, Wani AH, Yaseen M, Jehangir M. Chest CT features of coronavirus disease-19 (COVID-19) pneumonia: Which findings on initial CT can predict an adverse short-term outcome? *BJR Open* 2020;2:20200016.
13. Pan Y, Guan H, Zhou S, Wang Y, Li Q, Zhu T, *et al.* Initial CT findings and temporal changes in patients with the novel coronavirus pneumonia (2019-nCoV): A study of 63 patients in Wuhan, China. *Eur Radiol* 2020;30:3306-9.
14. Wang Y, Dong C, Hu Y, Li C, Ren Q, Zhang X, *et al.* Temporal changes of CT findings in 90 patients with COVID-19 pneumonia: A longitudinal study. *Radiology* 2020;296:E55-64.
15. Ye Z, Zhang Y, Wang Y, Huang Z, Song B. Chest CT manifestations of new coronavirus disease 2019 (COVID-19): A pictorial review. *Eur Radiol* 2020;30:4381-9.
16. Zhou S, Wang Y, Zhu T, Xia L. CT Features of coronavirus disease 2019 (COVID-19) pneumonia in 62 patients in Wuhan, China. *AJR Am J Roentgenol* 2020;214:1287-94.
17. Zhang R, Ouyang H, Fu L, Wang S, Han J, Huang K, *et al.* CT features of SARS-CoV-2 pneumonia according to clinical presentation: A retrospective analysis of 120 consecutive patients from Wuhan city. *Eur Radiol* 2020;30:4417-26.
18. Bai HX, Hsieh B, Xiong Z, Halsey K, Choi JW, Tran TM, *et al.* Performance of radiologists in differentiating COVID-19 from viral pneumonia on chest CT. *Radiology* 2020;296:E46-54.
19. Mason RJ. Pathogenesis of COVID-19 from a cell biology perspective. *Eur Respir J* 2020;55:2000607.
20. Tahamtan A, Ardebili A. Real-time RT-PCR in COVID-19 detection: issues affecting the results. *Expert Rev Mol Diagn.* 2020 May; 20 (5):453-454. doi: 10.1080/14737159.2020.1757437.
21. Yu F, Yan L, Wang N, Yang S, Wang L, Tang Y, *et al.* Quantitative detection and viral load analysis of SARS-CoV-2 in infected patients. *Clin Infect Dis* 2020;71:793-8.
22. Winichakoon P, Chaiwarith R, Liwsrisakun C, Salee P, Goonna A, Limsukon A, *et al.* Negative nasopharyngeal and oropharyngeal swabs do not rule out COVID-19. *J Clin Microbiol* 2020;58:e00297-20.
23. Wu J, Liu J, Zhao X, Liu C, Wang W, Wang D, *et al.* Clinical characteristics of imported cases of Coronavirus disease 2019 (COVID-19) in Jiangsu province: A multicenter descriptive study. *Clin Infect Dis* 2020;71:706-12.
24. Ooi EE, Low JG. Asymptomatic SARS-CoV-2 infection. *Lancet Infect Dis.* 2020;20(9):996-998. doi: 10.1016/S1473-3099(20)30460-6.
25. Mizumoto K, Kagaya K, Zarebski A, Chowell G. Estimating the asymptomatic proportion of coronavirus disease 2019 (COVID-19) cases on board the Diamond Princess cruise ship, Yokohama, Japan, 2020. *Euro Surveill* 2020;25:2000180.
26. Chang MC, Lee W, Hur J, Park D. Chest computed tomography findings in asymptomatic patients with COVID-19. *Respiration* 2020;99:748-54.
27. Xu Z, Shi L, Wang Y, Zhang J, Huang L, Zhang C, *et al.* Pathological findings of COVID19 associated with acute respiratory distress syndrome. *Lancet Respir Med* 2020;84:420-2.
28. Fehr AR, Perlman S. Coronaviruses: An overview of their replication and pathogenesis. *Methods Mol Biol* 2015;1282:1-23.
29. Wang Y, Sun J, Zhu A, Zhao J, Zhao J. Current understanding of middle east respiratory syndrome coronavirus infection in human and animal models. *J Thorac Dis* 2018;10:S2260-71.
30. Du L, Yang Y, Zhou Y, Lu L, Li F, Jiang S. MERS-CoV spike protein: A key target for antivirals. *Expert Opin Ther Targets* 2017;21:131-43.
31. Du L, He Y, Zhou Y, Liu S, Zheng B, Jiang S. The spike protein of SARS-CoV—A target for vaccine and therapeutic development. *Nat Rev Microbiol* 2009;7:226-36.
32. Wu J, Wu X, Zeng W, Guo D, Fang Z, Chen L, *et al.* Chest CT findings in patients with Corona virus disease 2019 and its relationship with clinical features. *Invest Radiol* 2020;55:257-61.
33. Hani C, Trieu NH, Saab I, Dangeard S, Bennani S, Chassagnon G, *et al.* COVID-19 pneumonia: A review of typical CT findings and differential diagnosis. *Diagn Interv Imaging* 2020;101:263-8.
34. Guan WJ, Ni ZY, Hu Y, Liang WH, Ou CQ, He JX, *et al.* Clinical characteristics of coronavirus disease 2019 in China. *N Engl J Med* 2020;382:1708-20.
35. Lan L, Xu D, Ye G, Xia C, Wang S, Li Y, *et al.* Positive RT-PCR test results in patients recovered from COVID-19. *JAMA* 2020;323:1502-3.
36. Xie X, Zhong Z, Zhao W, Zheng C, Wang F, Liu J. Chest CT for typical 2019-nCoV pneumonia: Relationship to negative RTPCR testing. *Radiology* 2020;296:E41-5.
37. Rubin GD, Ryerson CJ, Haramati LB, Sverzellati N, Kanne JP, Raouf S, *et al.* The role of chest imaging in patient management during the COVID-19 pandemic: A multinational consensus statement from the Fleischner Society. *Radiology* 2020;296:172-80.
38. WHO/2019-nCoV/Clinical/Radiology\_imaging/2020.1.
39. ACR Recommendations for the use of Chest Radiography and Computed Tomography (CT) for Suspected COVID-19 Infection.
40. Kalra MK, Homayounieh F, Arru C, Holmberg O, Vassileva J. Chest CT practice and protocols for COVID-19 from radiation dose management perspective. *Eur Radiol* 2020;30:6554-60.
41. Elicker BM, Jones KD, Henry TS, Collard HR. Multidisciplinary approach to hypersensitivity pneumonitis. *J Thorac Imaging* 2016;31:92-103.
42. Parekh M, Donuru A, Balasubramanya R, Kapur S. Review of the Chest CT differential diagnosis of ground-glass opacities in the COVID Era. *Radiology* 2020;297:E289-302.
43. Li K, Wu J, Wu F, Guo D, Chen L, Fang Z, *et al.* The clinical and chest CT features associated with severe and critical COVID-19 pneumonia. *Invest Radiol* 2020;55:327-31.
44. Zu ZY, Jiang MD, Xu PP, Chen W, Ni QQ, Lu GM, *et al.* Coronavirus disease 2019 (COVID-19): A perspective from China. *Radiology* 2020;296:E15-25.



45. Chung M, Bernheim A, Mei X, Zhang N, Huang M, Zeng X, *et al.* CT imaging features of 2019 novel coronavirus (2019-nCoV). *Radiology* 2020;295:202-7.
46. Song F, Shi N, Shan F, Zhang Z, Shen J, Lu H, *et al.* Emerging 2019 novel coronavirus (2019-nCoV) pneumonia. *Radiology* 2020;295:210-7.
47. Tanaka N, Emoto T, Suda H, Kunihiro Y, Matsunaga N, Hasegawa S, *et al.* High-resolution computed tomography findings of influenza virus pneumonia: A comparative study between seasonal and novel (H1N1) influenza virus pneumonia. *Jpn J Radiol* 2012;30:154-61.
48. Deng J, Zheng Y, Li C, Ma Z, Wang H, Rubin BK. Plastic bronchitis in three children associated with 2009 influenza A (H1N1) virus infection. *Chest* 2010;138:1486-8.
49. Kim YN, Cho HJ, Cho YK, Ma JS. Clinical significance of pleural effusion in the new influenza A (H1N1) viral pneumonia in children and adolescent. *Pediatr Pulmonol* 2012;47:505-9.
50. Huang C, Wang Y, Li X, Ren L, Zhao J, Hu Y, *et al.* Clinical features of patients infected with 2019 novel coronavirus in Wuhan, China. *Lancet* 2020;395:497-506.
51. Altmayer S, Zanon M, Pacini GS, Watte G, Barros MC, Mohammed TL, *et al.* Comparison of the computed tomography findings in COVID-19 and other viral pneumonia in immunocompetent adults: A systematic review and meta-analysis. *Eur Radiol* 2020;30:6485-96.
52. Vagal A, Mahoney M, Allen B, Kapur S, Udstuen G, Wang L, *et al.* Rescheduling nonurgent care in radiology: Implementation during the coronavirus disease 2019 (COVID-19) pandemic. *J Am Coll Radiol* 2020;17:882-9.
53. Aguiar de Sousa D, Sandset EC, Elkind MSV. The curious case of the missing strokes during the COVID-19 pandemic. *Stroke* 2020;51:1921-3.
54. Impact of the Coronavirus Disease 2019 (COVID-19) Pandemic on Imaging Case Volumes. doi.org/10.1016/j.jacr.2020.05.004.
55. Nakajima K, Kato H, Yamashiro T, Izumi T, Takeuchi I, Nakajima H, *et al.* COVID-19 pneumonia: Infection control protocol inside computed tomography suites. *Jpn J Radiol* 2020;38:391-3.
56. Mossa-Basha M, Azadi J, Ko J, Klein J, Meltzer C, COVID-19 Task Force. RSNA COVID-19 task force.
57. Singh S, Kalra MK, Ali Khawaja RD, Padole A, Pourjabbar S, Lira D, *et al.* Radiation dose optimization and thoracic computed tomography. *Radiol Clin N Am* 2014;52:1-15.
58. Fan L, Liu S. CT and COVID-19: Chinese experience and recommendations concerning detection, staging and follow-up. *Eur Radiol* 2020;30:5214-6.
59. Yang Q, Liu Q, Xu H, Lu H, Liu S, Li H. Imaging of coronavirus disease 2019: A Chinese expert consensus statement. *Eur J Radiol* 2020;127:109008.
60. [worldometers.info/world-population/population-by-country](http://worldometers.info/world-population/population-by-country).
61. [worldometers.info/coronavirus/country/china](http://worldometers.info/coronavirus/country/china).
62. Lai CC, Wang CY, Hsueh PR. Co-infections among patients with COVID-19: The need for combination therapy with non-anti-SARS-CoV-2 agents? *J Microbiol Immunol Infect* 2020;53:505-12.