

Contents lists available at [ScienceDirect](https://www.sciencedirect.com)

International Journal of Surgery Case Reports

journal homepage: www.casereports.com

Recurrent renal cancer in Birt–Hogg–Dubé syndrome: A case report



Hammad Ather, Nida Zahid*

Department of Surgery, Aga Khan University, Karachi, Pakistan

ARTICLE INFO

Article history:

Received 13 October 2017

Received in revised form

14 November 2017

Accepted 16 November 2017

Available online 28 November 2017

Keywords:

Case report

Birth Hogg Dube syndrome

FLCN gene

Pneumothorax

Renal cell carcinoma

Radical nephrectomy

ABSTRACT

INTRODUCTION: Birt–Hogg–Dubé syndrome (BHDS) is a rare autosomal dominant disease. It is caused by constitutional mutations in the FLCN gene. Since BHDS is a rare syndrome therefore it is unknown to many physicians. However, it is important to identify this rare syndrome at early stages because incidence of renal cancer in BHD patients is very high and its detection at early stages can prevent its metastasis. Hence, we want to present a case of BHDS and draw the attention of the treating physician to this rare inherited disorder and discuss its appropriate diagnosis and management.

CASE PRESENTATION: We present a case of a 50-year old male presented to the consulting clinics of a University Hospital with right flank pain since the last 2 months. The Computed Tomography (CT) and biopsy on the right renal mass indicated clear cell type renal cell carcinoma with significant lymphadenopathy. Past history of cystic lung disease and pneumothorax along with positive finding of renal cell carcinoma on CT and biopsy suggested Birt–Hogg–Dubé (BHD) syndrome. The patient underwent right radical nephrectomy and lymph node dissection. His 3 months post- surgery follow up CT scan indicated disease recurrence.

CONCLUSION: In conclusion, it is important to identify this rare syndrome at early stages. Diagnosis for the patients with a positive family history for renal cell cancer and pneumothorax should be considered. FLCN sequencing should also be taken into account in patients and their families because incidence of renal cancer in BHD patients is very high and detection at early stages can prevent its metastasis.

© 2017 The Authors. Published by Elsevier Ltd on behalf of IJS Publishing Group Ltd. This is an open access article under the CC BY-NC-ND license (<http://creativecommons.org/licenses/by-nc-nd/4.0/>).

1. Introduction

Birt–Hogg–Dubé syndrome (BHDS), which is also known as Hornstein–Knickenberg syndrome, is a rare autosomal dominant disease originally reported in 1977. [1] BHDS is an autosomal dominant monogenic disorder caused by constitutional mutations in the FLCN gene [2–4]. FLCN is a tumor suppressor gene [5–7], and codes for the protein folliculin [8]. Since the first discovery of the mutation in the FLCN gene, various FLCN germ line mutations have been identified in Caucasian and Asian families [9–11]. The clinical manifestations of this syndrome are as follows; Lung cyst that is the hall mark of lung involvement that increases the risk of pneumothorax [12,13]. Secondly manifestations of the skin are; fibrofolliculomas, trichodiscomas, and acrochordons, which mainly occurs on the face, neck, and upper trunk [1,14]. However, the utmost severe manifestation of the syndrome is the susceptibility to renal cell carcinoma (RCC) [15]. More than 600 families with BHDS have been reported till 2016 [16]. Since BHDS is a rare syndrome therefore it is unknown to many physicians. More families with BHDS may exist

and the syndrome is likely to be under-diagnosed. Since it is a rare disease its diagnosis and management is a crucial element. Therefore we present a case of BHDS and hope to draw the attention of the treating physician to this rare inherited disorder.

2. Case

A 50-year old male presented to the consulting clinics of a University Hospital with right flank pain since the last 2 months. Family history showed that the mother had bullous lung disease. Moreover about 10 years back the patient presented with complain of shortness of breath and was diagnosed with cystic lung disease and underwent video assisted thoracoscopy (VAT)/apical pleurectomy/pleurodosis. On examination his vitals were stable and systematic examination was unremarkable except there was decrease air entry in middle and lower zone bilaterally. His laboratory test showed anemia and raised C reactive protein. The Computed Tomography (CT) presented ill-defined infiltrating right infrahilar and lower pole renal lesion with a partly exophytic component along with multiple enlarged adjacent centrally located necrotic lymph nodes in the aortocaval and retrocaval locations (Fig. 1) and enlarged mediastinal lymph nodes. Moreover emphysematous changes in the lungs with patchy fibrotic changes and scattered nodularity was found representing sequel of old infection with typical cyst in the lungs bilaterally. A biopsy was per-

* Corresponding author at: Department of Surgery, Aga Khan University, Stadium Road, 74800, Karachi, Pakistan.

E-mail addresses: hammad.ather@aku.edu (H. Ather), nida.zahid@aku.edu (N. Zahid).

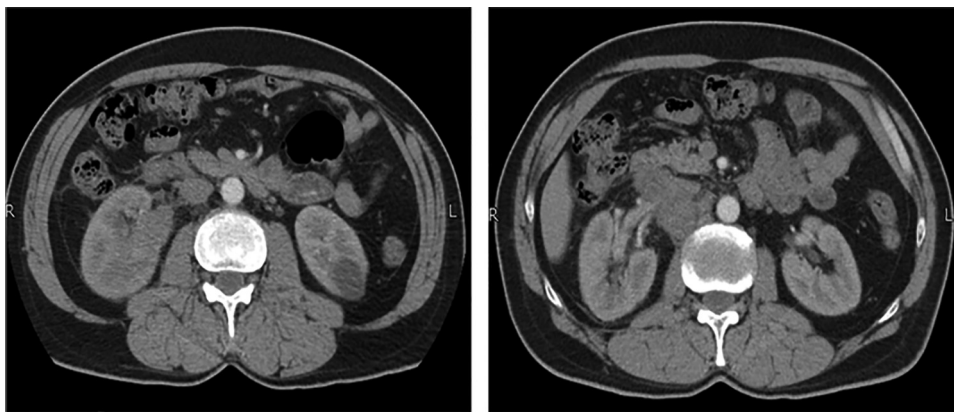


Fig. 1. The CT scan shows a suspicious looking ill-defined infiltrating right infrahilar and lower pole renal lesion with a partly exophytic component. Multiple enlarged adjacent centrally necrotic lymph nodes in the aortocaval and retrocaval locations.

formed on the right renal mass that indicated clear cell type renal cell carcinoma with significant lymphadenopathy. Histopathology showed multiple cores comprising of fibro collagenous tissue infiltrated by neoplastic lesion comprising of polygonal cells showing clear to eosinophilic cytoplasm and round to oval hyperchromatic nuclei. Focally, papillary like structure was noted. The lesion was surrounded by lymphocytic population. However, no definite lymphoid was observed. Special PAS stain highlighted abundant intracytoplasmic glycogen in the neoplastic cells. The CT and biopsy findings of renal cell carcinoma in combination with the past history of cystic lung disease and pneumothorax and a positive family history of bullous lung disease suggested Birt-Hogg-Dubie (BHD) syndrome. The patient underwent right radical nephrectomy and lymph node dissection which was performed by the urologist. On discharge the patient was referred for chest physiotherapy as he had low lung compliance. Standard of care was given according to institutional policies and intervention according to EAU guideline. Two months post- surgery the patient again presented with cough and chest X- ray revealed right pneumothorax. He was admitted for chest tube insertion and was treated for lower respiratory tract infection. His follow up CT three months following radical nephrectomy indicated disease recurrence (Fig. 2). He is being referred for consideration of systemic treatment.

The work has been reported in line with the SCARE criteria [17].

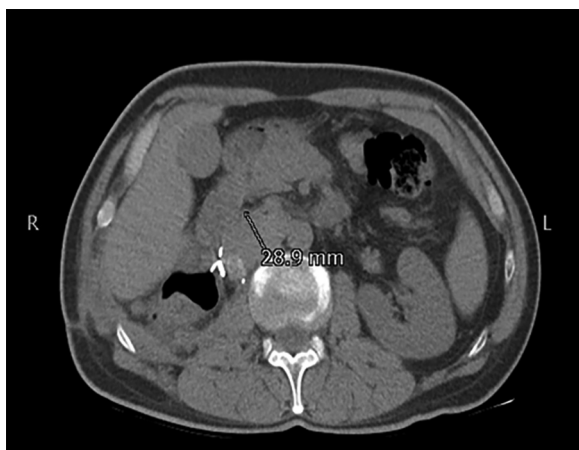

Fig. 2. The CT scan reveals interval follows radical nephrectomy and lymphodec-tomy and increase in caval node at renal hilum on right side measuring 29 mm in short axis. A simple renal cortical cyst evident at the lower pole of the left kidney.

3. Discussion

BHDS is a rare hereditary syndrome with a higher increased risk of, multiple lung cysts predisposing to recurrent pneumothorax, increased risk of renal cancer and fibro-folliculomas in the skin. Multiple lung cysts are seen in approximately 67–90% of patients with BHDS and about 40% experience pneumothorax [12]. This was evident in our case where the patient first presented with an apical bleb and developed cystic lung disease and pneumothorax. The treatment of pneumothorax in BHDS is similar to the treatment of pneumothorax of other etiologies [18]. Almoosa et al. suggested [19] that chemical and surgical pleurodesis decreases the pneumothorax recurrence rate, therefore pleurodesis after the first spontaneous pneumothorax in BHDS has been suggested. Further, thoroscopic pleural covering technique has also been suggested as a way of preventing recurrence of pneumothorax in patients with BHDS [20]. In our case the patient underwent Video Assisted Thoracoscopy (VAT)/Apical Pleurectomy/Pleurodesis when he was diagnosed with cystic fibrosis and pneumothorax for the first time.

Renal Cell Carcinoma (RCC) is one of the most dreaded complication of BHDS and its diagnosis and management is very crucial. Approximately 30% of BHDS patients develop renal tumors, and it is commonly found in middle-aged patients with mean age 50.7. [21] Early diagnosis of BHDS is important so that patients are included in RCC screening programs. It would help in preventing metastatic disease, which has miserable prognosis. Since the syndrome is rare, the diagnosis is often delayed for years and the variable presentation of the syndrome contributes to the diagnostic difficulties. Along with the diagnostic difficulties, management is also a crucial element of RCC. It is recommended that if any tumor is greater than 3 cms a partial nephrectomy should be performed with an effort to clear kidney of all grossly evident tumors. Tumor <3 cms diameter can be observed because the risk of metastasis appears to be relatively low in this situation [22]. The patients presenting with small renal tumors (<4 cm) may undergo radiofrequency ablation (RFA) or cryoablation. However, nephrectomy is the recommended standard treatment procedure [23]. In our case study the patient underwent radical nephrectomy and lymph node dissection upon diagnosis of renal cell carcinoma with a tumor size of 9*4 cms and lymphadenopathy.

Skin manifestations are also common in BHDS and are seen in approximately 58–90% of patients [21]. The involvement of the skin is benign, and no follow up is needed [24].

Recently, the European BHDS consortium has proposed a set of criteria for the diagnosis of BHDS (Table 1) [25]

Therefore it is essential that upon diagnosis of BHDS, the patients should undergo examination of the skin for fibro-folliculomas, CT

Table 1

Diagnostic Criteria for BHDS as proposed by the European BHDS consortium.

- A patient has Birt-Hogg-Dube syndrome if:
 - The patient has a pathogenic FLCN mutation, or
 - The patient has >4 fibrofolliculomas or trichodiscomas, at least one histologically confirmed, of adult onset, or
- If 2 of the 3 following manifestations are present:
 - Multiple bilateral lung cysts with basal predominance and no other apparent cause. With or without spontaneous pneumothorax.
 - A first degree relative with BHDS
 - Early debut (<50 years) of renal tumors or the presence of:
 - Multiple bilateral renal tumors
 - Renal tumors of the chromophobe/oncocytotic type

imaging of the thorax for lung cysts, abdominal MR or CT imaging for renal tumors as well as genetic screening for pathogenic FLCN mutations. In our case we did not test for FLCN mutation. Identification of FLCN defects in families with BHD has led to new insights in the penetrance and clinical variability of this syndrome. It is proposed that diagnostic criteria for BHDS should be based on clinical manifestations and the outcome of DNA testing. And it is important that all patients suspected of having BHD should be offered genetic testing to confirm the diagnosis [26]. In fact, if a pathogenic FLCN mutation is identified, all at-risk relatives should be offered genetic counseling and predictive testing [24].

4. Strengths

Through our case report we hope to draw the attention of the treating physician to this rare inherited disorder which has deleterious outcomes. Early diagnosis of BHDS is important so that patients are included in RCC screening programs. It would help in preventing metastatic disease, which has miserable prognosis. Since the syndrome is rare, the diagnosis is often delayed for years and the variable presentation of the syndrome contributes to the diagnostic and management difficulties.

5. Weakness

The weakness of our study was that we were not able to evaluate the FLCN mutation in our patients. It is observed that the offspring of an individual with BHDS have a 50% chance of inheriting the pathogenic variant. Therefore, prenatal diagnosis for pregnancies, at increased risk is possible if the FLCN pathogenic variant of an affected family member has been identified.

6. Conclusion

In conclusion, it is important to identify this rare syndrome at early stages. Diagnosis and management for the patients with a positive family history for renal cell cancer and pneumothorax should be considered. FLCN sequencing should also be considered in patients and their families because incidence of renal cancer in BHD patients is very high and detection at early stages can prevent its metastasis.

7. Learning points

1. BHD is a rare disease causing renal cell carcinoma
2. Usual histology is chromophobe tumor, however our patient histology was clear cell type.
3. Aggressive nature of the disease with lack of adjuvant treatment and morbidity related to pulmonary and renal issues have been addressed in this report.

Conflicts of interest

None.

Funding

None.

Ethical approval

4993-Sur-ERC17.

Consent

Written informed consent was obtained from the patient for publication of this case report and accompanying images. A copy of the written consent is available for review by the Editor-in-Chief of this journal on request".

Authors contribution

HA conceived the idea and wrote the draft of manuscript. NZ wrote the draft of manuscript along with HA.

Guarantor

Dr Hammad Ather.

References

- [1] A.R. Birt, G.R. Hogg, W.J. Dubé, Hereditary multiple fibrofolliculomas with trichodiscomas and acrochordons, *Arch. Dermatol.* 113 (12) (1977) 1674–1677.
- [2] M.L. Nickerson, M.B. Warren, J.R. Toro, V. Matrosova, G. Glenn, M.L. Turner, et al., Mutations in a novel gene lead to kidney tumors, lung wall defects, and benign tumors of the hair follicle in patients with the Birt-Hogg-Dube syndrome, *Cancer Cell* 2 (2) (2002) 157–164.
- [3] M. Kunogi, M. Kurihara, T.S. Ikegami, T. Kobayashi, N. Shindo, T. Kumasaka, et al., Clinical and genetic spectrum of Birt-Hogg-Dube syndrome patients in whom pneumothorax and/or multiple lung cysts are the presenting feature, *J. Med. Genet.* 47 (4) (2010) 281–287.
- [4] D.H. Lim, P.K. Rehal, M.S. Nahorski, F. Macdonald, T. Claessens, M. Van Geel, et al., A new locus-specific database (LSDB) for mutations in the folliculin (FLCN) gene, *Hum. Mutat.* 31 (1) (2010) E1043–E1051.
- [5] V. Hudon, S. Sabourin, A.B. Dydensborg, V. Kottis, A. Ghazi, M. Paquet, et al., Renal tumour suppressor function of the Birt-Hogg-Dubé syndrome gene product folliculin, *J. Med. Genet.* 47 (3) (2010) 182–189.
- [6] T. Cash, J. Gruber, T. Hartman, E.P. Henske, M. Simon, Loss of the Birt-Hogg-Dubé tumor suppressor results in apoptotic resistance due to aberrant TGFβ-mediated transcription, *Oncogene* 30 (22) (2011) 2534–2546.
- [7] S.-B. Hong, H. Oh, V.A. Valera, M. Baba, L.S. Schmidt, W.M. Linehan, Inactivation of the FLCN tumor suppressor gene induces TFE3 transcriptional activity by increasing its nuclear localization, *PLoS One* 5 (12) (2010) e15793.
- [8] M. Furuya, S.B. Hong, R. Tanaka, N. Kuroda, Y. Nagashima, K. Nagahama, et al., Distinctive expression patterns of glycoprotein non-metastatic B and folliculin in renal tumors in patients with Birt-Hogg-Dubé syndrome, *Cancer Sci.* 106 (3) (2015) 315–323.
- [9] J.R. Toro, M.-H. Wei, G.M. Glenn, M. Weinreich, O. Toure, C. Vocke, et al., BHD mutations, clinical and molecular genetic investigations of Birt-Hogg-Dubé syndrome: a new series of 50 families and a review of published reports, *J. Med. Genet.* 45 (6) (2008) 321–331.

- [10] H. Ishii, H. Oka, Y. Amemiya, A. Iwata, S. Otani, K. Kishi, et al., A Japanese family with multiple lung cysts and recurrent pneumothorax: a possibility of Birt-Hogg-Dubé syndrome, *Intern. Med.* 48 (16) (2009) 1413–1417.
- [11] J. Kim, J.-H. Yoo, D.-Y. Kang, N.J. Cho, K.-A. Lee, Novel in-frame deletion mutation in FLCN gene in a Korean family with recurrent primary spontaneous pneumothorax, *Gene* 499 (2) (2012) 339–342.
- [12] S. Tomassetti, A. Carloni, M. Chilosi, A. Maffè, S. Ungari, N. Sverzellati, et al., Pulmonary features of Birt-Hogg-Dubé syndrome: cystic lesions and pulmonary histiocytoma, *Respir. Med.* 105 (5) (2011) 768–774.
- [13] B. Fröhlich, C. Zeitz, G. Matyas, H. Alkadhi, C. Tuor, W. Berger, et al., Novel mutations in the folliculin gene associated with spontaneous pneumothorax, *Eur. Respir. J.* 32 (5) (2008) 1316–1320.
- [14] N. Misago, T. Kimura, Y. Narisawa, Fibrofolliculoma/trichodiscoma and fibrous papule (perifollicular fibroma/angiofibroma): a reevaluation of the histopathological and immunohistochemical features, *J. Cutan. Pathol.* 36 (9) (2009) 943–951.
- [15] B. Zbar, W.G. Alvord, G. Glenn, M. Turner, C.P. Pavlovich, L. Schmidt, et al., Risk of renal and colonic neoplasms and spontaneous pneumothorax in the Birt-Hogg-Dubé syndrome, *Cancer Epidemiol. Prev. Biomark.* 11 (4) (2002) 393–400.
- [16] Published BHD Families by the BHD foundation. [cited 2016 Dec 19]. Available from: <https://www.bhdsyndrome.org/for-researchers/what-is-bhd/introduction/published-bhd-families/>.
- [17] R.A. Agha, A.J. Fowler, A. Saeta, I. Barai, S. Rajmohan, D.P. Orgill, et al., The SCARE statement: consensus-based surgical case report guidelines, *Int. J. Surg.* 34 (2016) 180–186.
- [18] A. MacDuff, A. Arnold, J. Harvey, Management of spontaneous pneumothorax: british Thoracic Society pleural disease guideline 2010, *Thorax* 65 (Suppl. 2) (2010) ii18–ii31.
- [19] K.F. Almoosa, J.H. Ryu, J. Mendez, J.T. Huggins, L.R. Young, E.J. Sullivan, et al., Management of pneumothorax in lymphangioleiomyomatosis: effects on recurrence and lung transplantation complications, *CHEST J.* 129 (5) (2006) 1274–1281.
- [20] H. Ebana, M. Otsuji, T. Mizobuchi, M. Kurihara, K. Takahashi, K. Seyama, Pleural covering application for recurrent pneumothorax in a patient with birt-Hogg-Dubé syndrome, *Ann. Thorac. Cardiovasc. Surg.* 22 (3) (2016) 189–192.
- [21] P.R. Benusiglio, S. Giraud, S. Deveaux, A. Méjean, J.-M. Correas, D. Joly, et al., Renal cell tumour characteristics in patients with the Birt-Hogg-Dubé cancer susceptibility syndrome: a retrospective, multicentre study, *Orphanet J. Rare Dis.* 9 (1) (2014) 163.
- [22] S. Madersbacher, G. Alivizatos, J. Nordling, C.R. Sanz, M. Emberton, J.J. de la Rosette, EAU 2004 guidelines on assessment, therapy and follow-up of men with lower urinary tract symptoms suggestive of benign prostatic obstruction (BPH guidelines), *Eur. Urol.* 46 (5) (2004) 547–554.
- [23] B. Ljungberg, K. Bensalah, S. Canfield, S. Dabestani, F. Hofmann, M. Hora, et al., EAU guidelines on renal cell carcinoma: 2014 update, *Eur. Urol.* 67 (5) (2015) 913–924.
- [24] D.K. Jensen, A. Villumsen, A.-B. Skytte, M.G. Madsen, M. Sommerlund, E. Bendstrup, Birt-Hogg-Dubé syndrome: a case report and a review of the literature, *Eur. Clin. Respir. J.* 4 (1) (2017) 1292378.
- [25] J.C. Herring, E.G. Enquist, A. Chernoff, W.M. Linehan, P.L. Choyke, M.M. Walther, Parenchymal sparing surgery in patients with hereditary renal cell carcinoma: 10-year experience, *J. Urol.* 165 (3) (2001) 777–781.
- [26] F.H. Menko, M.A. Van Steensel, S. Giraud, L. Friis-Hansen, S. Richard, S. Ungari, et al., Birt-Hogg-Dubé syndrome: diagnosis and management, *Lancet Oncol.* 10 (12) (2009) 1199–1206.

Open Access

This article is published Open Access at [sciencedirect.com](https://www.sciencedirect.com). It is distributed under the [IJSCR Supplemental terms and conditions](#), which permits unrestricted non commercial use, distribution, and reproduction in any medium, provided the original authors and source are credited.