

Positron emission tomography: a precious tool in the challenge of the infected cysts in ADPKD

Giorgina Barbara Piccoli¹, Vincenzo Arena², Valentina Consiglio¹, Agostino Depascale³
and Maria Chiara Deagostini¹

¹ASOU San Luigi Gonzaga, Regione Gonzole 10, Orbassano, Torino and IRMET Via Onorato Vigliani 89/A, 10135 - Torino, Italy,
²IRMET, Nuclear Medicine, Italy and ³ASOU San Luigi Gonzaga, Orbassano, Radiology, Italy

Correspondence and offprint requests to: Giorgina Piccoli; E-mail: gbpiccoli@yahoo.it

Keywords: ADPKD; infection; kidney cysts; positron emission tomography; imaging

A 68-year-old woman, affected by autosomal dominant polycystic liver and kidney disease (ADPKD), seeks nephrological attention for persistent low-grade fever, with vague abdominal discomfort. She reports a recent gastroenteritis episode, followed by a lower urinary tract infection (*Escherichia coli*), treated by amoxicillin clavulanate on the basis of the antibiogram. Afterwards, she developed a severe cutaneous allergy, which she linked to amoxicillin clavulanate. On account of the persistence of a low-grade fever, she self-prescribed different antibiotics, without complete clinical remission.

At referral, the patient is pale and normotensive with diffuse abdominal tenderness. Her main blood tests are as follows: WBC 9330/mm³, serum creatinine 0.9 mg/dL, GFR 65 mL/min, C-reactive protein 2.38 mg/dL (normal <0.8), ESR 21 mm/h, Hb 10.3 g/dL, serum albumin 2.9 g/dL and 6–8 WBC per high power field at urinalysis. Renal ultrasounds reveal enlarged liver and kidneys with large cysts (maximum 6 cm bilaterally). A complicated cyst, containing dense fluid material (caused by infection or bleeding), is located in the left kidney.

Diagnosis of intracystic infection in ADPKD is still a diagnostic challenge

On account of the limits of both CT scan and nuclear resonance in discriminating between active and 'old' lesions, positron emission tomography (PET) with 18-F-fluorodeoxyglucose (FDG) was performed. The finding of intense metabolic activity in one renal cyst confirmed the presence of intracystic infection. The finding of intense metabolic activity in one renal cyst confirmed the presence of intracystic infection (Figure 1a).

Remission of the fever and normalization of the acute phase reactants were obtained within 1 week of therapy

with aminoglycoside and ertapenem (the latter continued for a further 7 weeks). A first FDG-PET control, 3 weeks after the start of therapy, showed significant but incomplete reduction of the metabolic activity (Figure 1b). Complete normalization was achieved 1 month later, leading to discontinuation of therapy (Figure 1c). One year after the infectious episode, the patient is well, with stable renal function.

This case confirms the usefulness of FDG-PET in detecting infected cysts in ADPKD, in line with a few cases recently published, overall reporting on seven patients [1–5]. This diagnostic technique may be of help particularly in patients presenting a non-specific clinical picture, and in whom the empiric balance between long-term therapy and risk for infectious relapses may be difficult. Furthermore, our case underlines the importance of FDG-PET in the follow-up, as a guide for the duration of the antibiotic therapy [1–5].

Conflict of interest statement. None declared.

References

1. Kaim AH, Burger C, Ganter CC *et al.* PET-CT-guided percutaneous puncture of an infected cyst in autosomal dominant polycystic kidney disease: case report. *Radiology* 2001; 221: 818–821
2. Bleeker-Rovers CP, de Sévaux RG, van Hamersvelt HW *et al.* Diagnosis of renal and hepatic cyst infections by 18-F-fluorodeoxyglucose positron emission tomography in autosomal dominant polycystic kidney disease. *Am J Kidney Dis* 2003; 41: E18–E21
3. Soussan M, Sberro R, Wartski M *et al.* Diagnosis and localization of renal cyst infection by 18F-fluorodeoxyglucose PET/CT in polycystic kidney disease. *Ann Nucl Med* 2008; 22: 529–531
4. DeSouza RM, Prachalias A, Srinivasan P *et al.* Differentiation between infection in kidney and liver cysts in autosomal dominant polycystic kidney disease: use of PET-CT in diagnosis and to guide management. *Transplant Proc* 2009; 41: 1942–1945
5. Jumenez Bonilla JF, Quirce R, Calabria ER *et al.* Hepatorenal polycystic disease and fever: diagnostic contribution of gallium citrate Ga 67 scan and fluorine F18 FDG-PET/CT. *Eur Urol* 2009; In press

Received for publication: 3.4.10; Accepted in revised form: 19.5.10

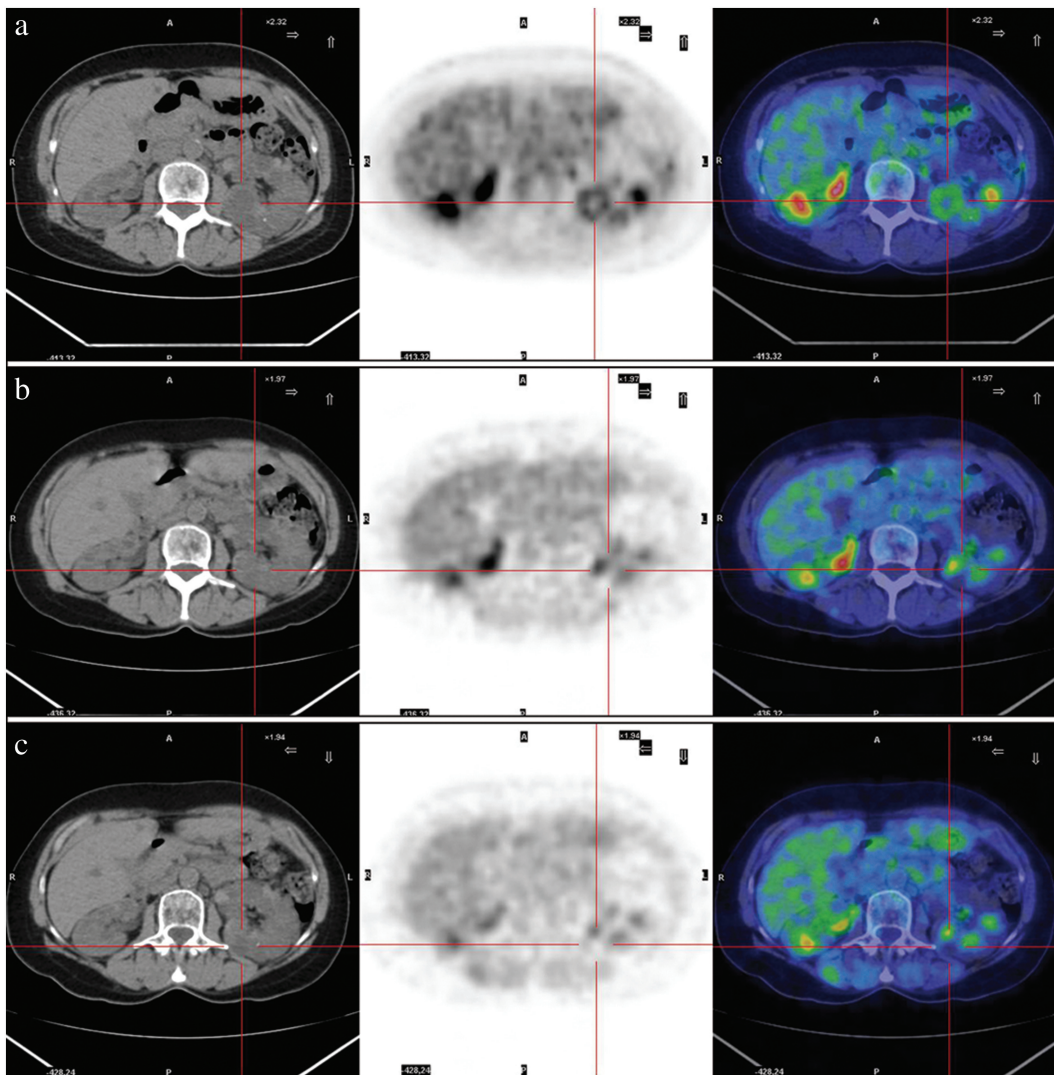


Fig. 1. Transaxial images—in sequence, CT scan, PET scan and fusion image. (a) The first FDG-PET/CT scan done in the suspect of renal intracystic infection. PET image shows an intense FDG uptake at the level of a renal cyst (pointer), thus confirming the initial hypothesis. The pericystic pattern is typical. (b) The second FDG-PET/CT scan. PET image shows the presence of a faint pathological FDG uptake (head arrow). This finding is suggestive of a partial metabolic response to the antibiotic treatment. (c) The third FDG-PET/CT scan. PET image does not show pathological uptake (pointer). This finding is suggestive of a complete metabolic response to the antibiotic treatment. The intense background activity is due to the urinary elimination of FDG. Indeed, this was initially considered as a potential limit for kidney imaging by FDG-PET. However, the combination of the persistence of the positive circular area in the complicated cyst, located at the CT scan, and the fusion image allows the identification of the infection, in spite of the intense, but rapidly clearing, background activity.