

Management Options in Avascular Necrosis of Talus

Abstract

Avascular necrosis (AVN) of the talus can be a cause of significant disability and is a difficult problem to treat. The most common cause is a fracture of the talus. We have done a systematic review of the literature with the following aims: (1) identify and summarize the available evidence in literature for the treatment of talar AVN, (2) define the usefulness of radiological Hawkins sign and magnetic resonance imaging in early diagnosis, and (3) provide patient management guidelines. We searched MEDLINE and PUBMED using keywords and MESH terminology. The articles' abstracts were read by two of the authors. Forty-one studies met the inclusion criteria of the 335 abstracts screened. The interventions of interest included hindfoot fusion, conservative measures, bone grafting, vascularized bone graft, core decompression, and talar replacement. All studies were of Level IV evidence. We looked to identify the study quality, imprecise and sparse data, reporting bias, and the quality of evidence. Based on the analysis of available literature, we make certain recommendations for managing patients of AVN talus depending on identified disease factors such as early or late presentation, extent of bone involvement, bone collapse, and presence or absence of arthritis. Early talar AVN seems best treated with protected weight bearing and possibly in combination with extracorporeal shock wave therapy. If that fails, core decompression can be considered. Arthrodesis should be saved as a salvage procedure in late cases with arthritis and collapse, and a tibiotalar calcaneal fusion with bone grafting may be needed in cases of significant bone loss. Role of vascularized bone grafting is still not defined clearly and needs further investigation. Future prospective, randomized studies are necessary to guide the conservative and surgical management of talar AVN.

Keywords: Avascular necrosis, management, talus fracture, treatment options

MeSH terms: Necrosis, avascular of bone; talar joint; autograft; decompression, surgical

**Mandeep S Dhillon¹,
Balvinder Rana²,
Inayat Panda²,
Sandeep Patel¹,
Prasoon Kumar¹**

¹Department of Orthopaedics,
Postgraduate Institute of
Medical Education and
Research, Chandigarh,

²Department of Orthopaedics,
Fortis Bone and Joint Institute,
Fortis Hospitals, New Delhi,
India

Introduction

Avascular necrosis (AVN) of the talus is a dreaded sequel to talar fractures, with the chances of AVN increasing with the severity of trauma and the associated damage to the already precarious blood supply.¹⁻³ Apart from posttraumatic causes, it can occasionally have non-traumatic aetiologies ranging from alcoholism, steroid use, dyslipidemia, or an idiopathic cause.⁴ The diagnosis of AVN talus can be a challenge, and the surgeon needs to anticipate it, especially in traumatic cases with significantly displaced body fragment.^{5,6} The treatment of AVN talus can also be frustrating and is a major challenge to the surgeon; the results after talus collapse are suboptimal in many cases, even in the best of surgical hands.^{2,5}

The preoperative workup and imaging gives an idea about the aetiology, duration, rate of

progression, extent of the AVN, including the stage of the disease, and the degree of disability of the patient.

The various treatment modalities described in literature for treating AVN talus include the following:

Nonoperative management (non weight bearing, protected weight bearing using splints such as the patellar tendon brace [PTB], and extracorporeal shock wave therapy [ESWT])⁷ [Table 1] (b) Surgical joint-sparing procedures (core decompression, bone grafting – vascularized or non vascularized autografts)^{9,10} [Tables 2 and 3] (c) Joint sacrificing procedures (partial or total talar replacement [TTR])^{18,19} [Table 4] (d) Salvage procedures (talectomy, arthrodesis of ankle, subtalar, tibionavicular, tibiocalcaneal [TC], or tibiotalar calcaneal joints)^{21,22} [Table 5] (e) Total ankle replacement (TAR)^{31,32} [Table 4].

Address for correspondence:

Dr. Sandeep Patel,
Department of Orthopaedics,
Postgraduate Institute of
Medical Education and
Research, Chandigarh, India.
E-mail: sandeepdrpatelortho@
gmail.com

Access this article online

Website: www.ijonline.com

DOI:
10.4103/ortho.IJOrtho_608_17

Quick Response Code:



How to cite this article: Dhillon MS, Rana B, Panda I, Patel S, Kumar P. Management options in avascular necrosis of talus. Indian J Orthop 2018;52:284-96.

This is an open access journal, and articles are distributed under the terms of the Creative Commons Attribution-NonCommercial-ShareAlike 4.0 License, which allows others to remix, tweak, and build upon the work non-commercially, as long as appropriate credit is given and the new creations are licensed under the identical terms.

For reprints contact: reprints@medknow.com

Table 1: Conservative management – literature review

Author	Year	Treatment given	Level of study	Number of ankles (with recorded outcomes)	Average duration of followup	Mean Age (years)	Etiology of AVN	Outcome	Failure
Canale and Kelly <i>et al.</i> ²	1978	Conservative prolonged NWB (15) and PTB brace (8)	IV	23	180 months	N/A	Posttraumatic	8 (E+G) in NWB patients; 2 (G) and 3 poor outcomes in PTB patients	2 ankle fusion, 2 talectomies, 5 TC fusion
Hawkins ³	1970	Conservative	IV	24	107.3	N/A	Posttraumatic	7/24 with no pain 3 (E+G)	3 talectomies, 4 underwent bone grafting, 4 underwent fusion
Mindell <i>et al.</i> ⁵	1963	Conservative	IV	13	14	36	Posttraumatic	46% satisfied, 6 (E+G)	N/S
Freund ⁸	1988	Conservative	IV	4	78	36.3	Posttraumatic	2 G, 2 (F+P)	2/4 needed fusion
Zhai <i>et al.</i> ⁷	2010	Conservative 17 ESWT 17 physical therapy	I Prospective RCT	34	18	44.1	Posttraumatic	AOFAS – 65.7-92.3 postoperative MRI >50% improvement in edema pattern in ESWT group; 29% in control group 77% (E+G)	1/34 required fusion

AVN=Avascular necrosis, RCT=Randomized controlled trial, E=Excellent, G=Good, F=Fair, P=Poor, NWB=Nonweightbearing, PWB=Partial weightbearing, PTB=Patellar tendon bearing, MRI=Magnetic resonance imaging, ESWT=Extracorporeal shock wave therapy, N/A=Not available, N/S=Not significant, TC=Tibiocalcaneal, AOFAS=American Orthopaedic Foot and Ankle Society

Table 2: Outcomes of core decompression – literature review

Author	Year	Level of study	Number of ankles	Duration of followup	Average Age (years)	Etiology	Outcome	Complications
Mont <i>et al.</i> ¹¹	1996	IV	17	84	47	82.3% steroids, 17.7% idiopathic	14 (82%) (E+G)	3/14 required fusion
Delanois <i>et al.</i> ¹²	1999	IV	32 29 Stage II 8 Stage III/IV	40	40	66.7% steroid, 33.3% nontraumatic	29 (E+G)	3/32 needing fusion
Marulanda <i>et al.</i> ¹³	2010	II	44 57% Stage I 43% Stage II	45	43	44% steroids, 16% SLE, 40% – other causes	40 (91%) (E+G)	14/44 (32%) had signs of progressive talar degeneration, among which 3/44 collapsed requiring fusion
Issa <i>et al.</i> ¹⁴	2014	IV	101 (85 isolated talus AVN, 11 distal tibial + talus AVN, 5 distal tibial AVN)	60		49.3% steroids, 35.6% alcohol, 29% tobacco use	Significant improvement in outcome scores, 83% no disease progression	

Most of these cases had nontraumatic etiology. AVN=Avascular necrosis, SLE=Systemic lupus erythematosus, E=Excellent, G=Good

The stage of the disease at presentation (specifically the presence or absence of talar dome collapse) and extent of involvement could probably be the most important factor guiding the decision for selecting a particular mode of treatment. The age of patient, duration of

disease, concomitant peritalar arthritis, degree of disability, and surgeon preference/experience may be other factors affecting treatment and outcomes.^{11,12,14,33} The literature seems to be inconclusive regarding the ideal modality of treatment of the condition, and the

Table 3: Outcome of bone grafting – literature review

Author	Year	Level of study	Treatment given	Number of ankles	Duration of followup	Average age (years)	Etiology	Outcome	Complications
Yu <i>et al.</i> ¹⁰	2010	IV	Vascularized cuneiform BG + iliac crest (cancellous)	20 8 stage II/10 III/3 IV	37	N/A	All nontraumatic	18 (E+G) 90% good-to-excellent outcome and BG incorporation	N/A
Zhang <i>et al.</i> ¹⁵	1998	IV	Vascularized 1st cuneiform (13) and cuboid (11)	16 out of 24 patients at last followup	36-66	N/A	N/A	16/16 complete bone incorporation 83.3% success rate	Minor ankle pain – 4/16
Doi and Hattori ¹⁶	2009	IV	Vascularized graft from supracondylar femur	7	N/A	48	5 posttraumatic, 2 idiopathic	Good-to-excellent outcomes in all, no dome collapse	Nil
Nunley and Hamid ⁹	2017	IV	Vascularized pedicle BG from cuboid + restricted weightbearing + PTB brace	13 Stage II/III	72	46.1	8 idiopathic, 2 posttraumatic, 2 steroid use	Significant improvement in quality of life scores PCS increase by 23.3 and MCS by 39.4 points	Two underwent TAR at 4 years, 1 re-surgery, arthroscopic debridement for soft-tissue impingement
Kodama <i>et al.</i> ¹⁷	2015	IV	Vascularized distal tibial BG + nonweight bearing + PTB brace	8 Stage II/III	26	50	6 - idiopathic 2 - posttraumatic	All good-to-excellent results with bony incorporation, Mazur score increased from 39 to 81	Nil

BG=Bone graft, PTB: Patellar tendon brace, PCS=Physical component summary, MCS=Mental component summary, N/A=Not available, E=Excellent, G=Good, TAR=Total ankle replacement

Table 4: Outcome of prosthetic replacement – literature review

Author	Year	Level of study	Treatment given	Number of ankles	Duration of followup (months)	Average age (years)	Etiology	Outcome	Complications
Harnroongroj and Vanadurongwan ¹⁸	1997	IV	Cemented dome replacement (stainless steel)	16	118	32	Posttraumatic	14/16 satisfactory outcome at final followup	2/16 eventually required fusion or revision Prosthesis sinkage and loosening of an issue
Taniguchi <i>et al.</i> ¹⁹	2015	IV	Partial talar replacement	22 First-generation prosthesis – 8, Second-generation – 14	98	65.4	20 – idiopathic 2 – posttraumatic	1 st generation – 3E/1G/3F/1P 2 nd generation – 3E/5G/4F/2P	4/22 (2 from each group) – total talar replacement
Devalia <i>et al.</i> ²⁰	2015	IV	First stage – subtalar fusion, Second stage – TAR	7 6 followed up till 3 years	36	67.3		5/6 (83%) overall satisfied at 3 years AOFAS 24.5-77.5 postoperative	2/6 dissatisfied with ADL and recreational activities

TAR=Total ankle replacement, ADL=Activities of daily living, E=Excellent, G=Good, F=Fair, P=Poor, AOFAS=American Orthopaedic Foot and Ankle Society

Table 5: Literature review on various hindfoot arthrodesis

Author	Year	Level of study	Mean Age (years)	Etiology of AVN	Treatment	Number of ankles (with recorded outcomes)	Average duration of followup (months)	Outcome	Complications
Kitaoka and Patzer ²³	1998	IV	34	94.7% posttraumatic, 3.3% steroids	TT, TTC fusion	19	72	7E/6G/3F/3P	4/19 Nonunion in 3/19
Dennison <i>et al.</i> ²⁴	2001	IV	45	83% posttraumatic, 16.7% failed ankle fusion	TC fusion using ring external fixator	6	32	1E/4G/1P	All 6 had delayed union, 1 frame removal done at 22 months
Devries <i>et al.</i> ²⁵	2010	IV	47.4	78.6% posttraumatic, 21.4% idiopathic	TTC using IMN	14	15.8	12/14 (85%) had solid fusion, 2 stable braceable pseudoarthrosis shoe-wearing ability in 8 patients, unassisted walking in 8 patients	4/14 minor complications such as superficial infection, partial hardware removal, stress fracture
Tenenbaum <i>et al.</i> ²⁶	2015	IV	54.3	64.3% posttraumatic, 35.7% nontraumatic 86% total body AVN, 78% with bone collapse	TC fusion using retrograde compression IMN without structural bone grafts	14	26	Mean VAS improved from 6.9 to 1.7 postoperative, AOFAS from 32.7 to 72.1 postoperative	4/14 all minor (screw removal, superficial wound dehiscence) 1 patient needed AFO
Urquhart <i>et al.</i> ²²	1996	IV	45	50% steroids, 40% posttraumatic, 10% idiopathic	Various hindfoot fusions	11	78	Union rate of 82% and average time for union 7.3 months	2/11 1 required below knee amputation, 6 delayed union
Lionberger <i>et al.</i> ²⁷	1982	IV	21-65 years	Posttraumatic	Blair's fusion	5	12-30	4/5 union at 5 months, 3 excellent outcomes	2/5 2 re-operations
Van Bergeyk <i>et al.</i> ²⁸	2003	IV	51	Posttraumatic	Blair's fusion	7	20	5/7 union at 4 months, postoperative mean AOFAS – 67	2/7 repeat fusion for delayed union, guarded functional outcome
Kendal <i>et al.</i> ²⁹	2015	IV	53.5	43.7% Idiopathic, 18.8% posttraumatic, 37.5% others 9/16 stage IV	Arthroscopic ankle fusion	15		15/15 complete union of arthrodesis, 13/15 complete resolution of pain	3/15 subsequent subtalar fusion 3 – metalware irritation
Kodama <i>et al.</i> ³⁰	2016	IV	57.4	14 idiopathic, 12 steroids, 7 posttraumatic	Anterior sliding tibial graft – vascularized versus nonvascularized	27 Distal tibial graft Vascularized – 17 Nonvascularized – 10	35	Complete fusion of graft in 13/17 (76%) in vascularized group and 4/10 (40%) in nonvascularized group Significant improvement in outcome scores in both groups	Confirmed nonunion in 1/17 (6%) vascularized, 4/10 (40%) in nonvascularized group

TT=Tibiotalar, TTC=Tibiotalocalcaneal, IMN=Intramedullary nail, AFO=Ankle foot orthosis, AVN=Avascular necrosis, VAS=Visual analog scale, E=Excellent, G=Good, F=Fair, P=Poor, AOFAS=American Orthopaedic Foot and Ankle Society, TC=Tibiocalcaneal

factors that should guide such treatment have not been well elucidated.

This review intends to discuss the indications for various treatment options described in literature and suggest a treatment algorithm based on simple criteria. The prognostic significance of Hawkins sign has also been discussed.

Materials and Methods

A thorough Medline search was made with the following keywords: (“Osteonecrosis” [Mesh] OR “AVASCULAR NECROSIS” [All]) AND (“Talus” [Mesh] OR “ASTRALGUS” [All]) on October 02, 2017, and a total of 335 hits were obtained. All abstracts of the articles were read by two of the authors; this led to exclusion of 294 papers. No Level 1 evidence articles on the subject were found, as most of the articles were case series or small cohorts. The reasons for exclusion of articles were those articles not relating to AVN, not relating to treatment, not

relating to talus bone, case reports and review articles, technique articles, animal studies, and others.

The articles were divided broadly into six categories of treatment currently in practice for AVN talus [Figure 1]. The shortlisted articles were analysed in detail. Finally, based on the evidence in these publications, an algorithm for treatment was devised.

To understand the prognostic significance of Hawkins sign, all the articles were thoroughly reviewed; we identified eight articles of which six were of our interest, as they had mentioned the prognostic value of Hawkins sign.³⁴⁻³⁹

Discussion

Role of nonoperative treatment

Nonoperative management is reserved for the cases diagnosed early, with the intention of preventing collapse till revascularization is complete. The published literature

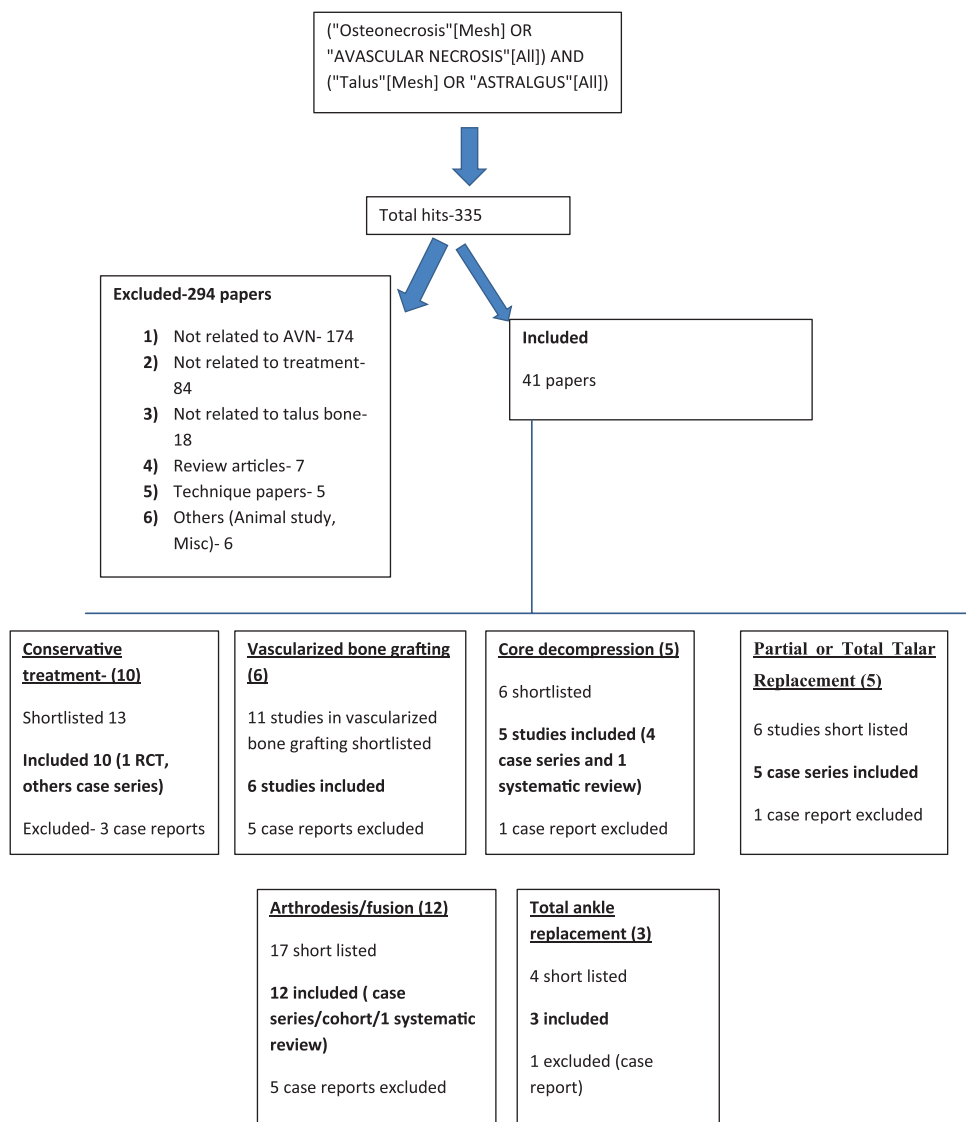


Figure 1: Flowchart showing the methodology

recommends that patients with asymptomatic early-stage lesions should be followed up frequently (every 3–6 months). Most of the studies recommend giving a trial of conservative therapy for at least 3 months prior to surgical intervention, even in symptomatic early-stage AVN. The options include a period of non-weight bearing, protected weight bearing using PTB [Figures 2 and 3], and ESWT [Table 1].⁷

Non-weight bearing is particularly beneficial in early cases or those with evidence of subchondral atrophy or revascularization when the talus is structurally weak. The role becomes controversial in patients with sclerotic zones and late presentation of the disease, since the exact role of non-weight bearing in the prevention of talar collapse has never been proven.¹

Canale and Kelly reported 23 patients undergoing conservative therapy with prolonged non-weight bearing (for >9 months) or PTB. In the non-weight bearing group, 89% of the patients reported excellent or good outcomes, while only 33.3% of patients reported good outcomes following PTB, with 66.7% having fair or poor results.² In the study on 24 patients by Hawkins *et al.*, only 7 (29%) had complete pain relief at last followup and only 12.5% had reported excellent or good outcomes.³

Mindell *et al.* reported relatively better results, with excellent-to-good clinical outcomes seen in 46% of the cases among 13 patients after prolonged non-weight bearing.⁵ However both these studies did not comment upon the collapse of talar dome despite usage of a brace that is meant to prevent it till revascularization occurs.

The duration of non-weight bearing appears to be ill defined in literature. Some believe in non-weight bearing until complete fracture healing and completion of revascularization.^{3,6} A better strategy in our opinion would be to keep it till fracture union followed by progressively

increasing weight bearing within limits of pain.⁴ A PTB brace can be used during the later period.

Zhai *et al.* conducted a prospective randomized controlled trial to evaluate the role of liquid-electric ESWT as compared to physical therapy among 34 patients with post-traumatic AVN of talus.⁷ This included patients with Ficat and Arlet (FA) Stage I and II.⁴⁰ They reported significant improvement in American Orthopaedic Foot and Ankle Society (AOFAS) Hind-foot score from 65.7 to 92.3 at final followup in those undergoing ESWT. Only one patient in the control group failed treatment and eventually required arthrodesis. The visual analog scale (VAS) score and ankle function were significantly better than those in the control group. Magnetic resonance imaging (MRI) at 18 months showed >50% improvement in the necrotic area in the ESWT group. These results are quite promising and ESWT can be a valuable adjunct to other modalities of treatment. This is the only Level 1 study available for any form of treatment described in AVN talus.

Electrical stimulation of bone reduces osteoclastic activity and some studies have found beneficial results of pulsed electric magnetic fields and implanted bone current with decreased clinical and radiographic progression in AVN of femoral head. The effects of these methods are yet to be studied in AVN talus, which may prove to be valuable adjuncts to treatment in early stages.⁷

Radiographic or clinical progression of disease or incomplete resolution, with absence of significant talar dome collapse, may necessitate surgical treatment; joint-

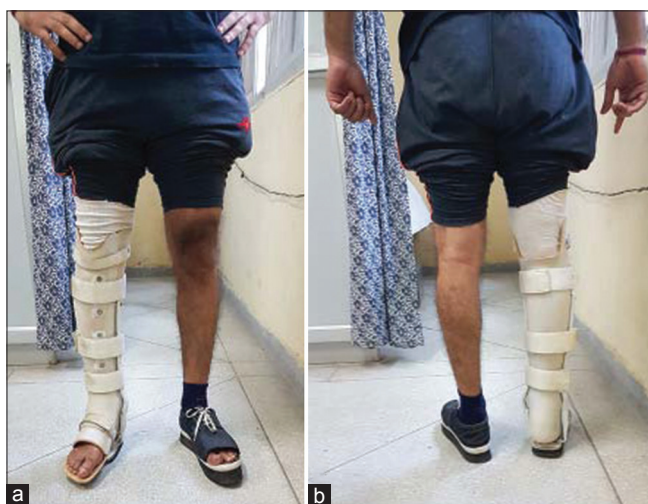

Figure 2: A clinical photograph showing indigenously designed brace used for conservative management of early AVN Talus (a) Front view of leg (b) Back view of leg

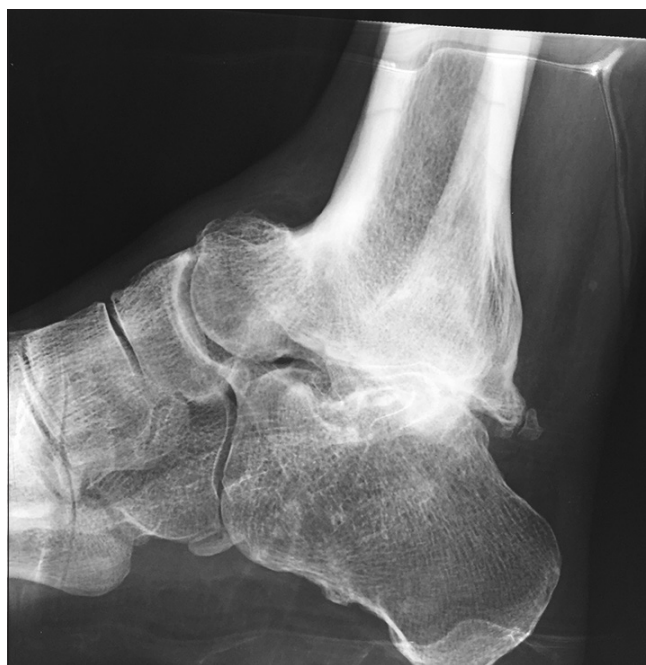

Figure 3: X-ray ankle joint lateral view of 20 year long term followup showing that Blair's Fusion done by excision of talar body and anterior tibial sliding Graft after which the patient recovered and currently is working as a Restaurant manager in Australia

sparing techniques such as core decompression and bone grafting become the next preferred options.

Joint-Sparing Treatments: When and Which?

Core decompression

The outcomes of core decompression in the treatment of early-stage AVN talus have been extremely satisfactory, especially when the cause is non traumatic.^{11,12,33} This works by reduction in the intraosseous pressure and enhances revascularization in the necrotic zone, akin to the idiopathic variant of osteonecrosis of femur head. Although it is recommended upto Stage I and II of the disease, we believe that the initial Stage III without significant collapse of the dome (<1 mm) can be given a trial of core decompression because the only alternative may be to go for an arthrodesis or joint-sacrificing treatment. The procedure is minimally invasive and carried out under fluoroscopic guidance, mostly through a posterolateral approach between the peroneal and Achilles tendon. Concomitant bone grafting or backfilling with demineralized bone matrix may be carried out [Table 2].⁹

The outcomes have been excellent to good in atraumatic AVN, but the role of core decompression in post traumatic AVN is yet to be studied.

Mont *et al.* reported excellent-to-good outcomes in 82% of patients (14 out of 17 ankles) at mean followup of 7 years in precollapse stage following atraumatic AVN.¹¹ The remaining thrMarulanda *et al.* published a prospective observational study on 44 symptomatic AVN talus cases in 31 patients, who underwent core decompression using percutaneous drilling with small diameter drills (3–4 mm).¹³ Forty-one (90%) reported successful outcome with significant improvement in AOFAS score (42 preoperative to 88 postoperative). They noted that while 20 (45.2%) of the ankles had been advised arthrodesis preoperatively, only 3 ankles (6.8%) eventually required fusion. They concluded that core decompression is an extremely good alternative in eliminating or at least deferring the need for fusion.

Issa *et al.* evaluated 101 ankles of atraumatic osteonecrosis (85 isolated talus AVN, 11 talus and distal tibia AVN, 5 both talus and distal tibia AVN); 83% of ankles did not demonstrate further disease progression after the core decompression procedure. There were significant improvements ($P < 0.05$) in clinical and patient-reported outcomes after surgical treatment.¹⁴

In the systematic review by Gross *et al.*, data from 85 patients from 3 studies, all involving atraumatic AVN talus at an average followup of 48 months, showed significant improvement in postoperative functional scores.³³ The combined rate of progression averaged 28%, with benefits seen both in early and late (Stage I/II and Stage II/III) stages of the disease in precollapse stage. Relief of symptoms is usually seen in 3–6 months. Repeat drilling

is advisable in case of non-remitting symptoms, development of new lesions, and prior inaccurate placement of drill, and if there is evidence of incomplete revascularization.

Thus, the reviewed literature shows that core decompression is a very useful procedure for Stages I and II AVN talus, with reported significant improvements in functional scores and decreased need for fusion surgery. Stage III AVN with minimum collapse can also be considered for this procedure, although no supportive evidence exists.

Role of vascularized bone grafting

The use of nonvascularized and vascularized bone grafts has provided beneficial results in the treatment of AVN talus. Besides providing structural support, they induce revascularization by creeping substitution from the surrounding vascularized bone into the avascular region of talus.

Yu *et al.* used a vascularized cuneiform bone graft with concomitant iliac cancellous grafting in twenty patients (8 Stage II, 10 Stage III, and 3 Stage IV). At a mean followup of 37 months, the outcomes were reported to be excellent in 8, good in 10, and poor in 2 cases, with complete incorporation into the bone seen in 90% of the cases.¹⁰

Among the 24 patients in the study by Zhang *et al.*, first cuneiform bone graft with a malleolaris anteromedialis was used in 9, first cuneiform with the medial tarsal artery in 4, and cuboid graft with lateral tarsal artery was used in 11 cases. With a followup duration of 3–5.5 years, all 16 patients had excellent bone incorporation with a reported success rate of 83.3%, while minor ankle pain was seen in 4 cases.¹⁵

Doi *et al.* used vascularized bone graft from the supracondylar femoral region based on the articular branch of the descending genicular artery in seven patients (five post traumatic and two with idiopathic AVN). They reported good to excellent outcomes in all patients with no subsequent dome collapse.¹⁶

Kodama *et al.* described a new technique of using vascularized bone graft from the distal tibia based on their study of the perimalleolar arterial arch on forty cadavers. Their study included 8 patients with isolated AVN and 12 patients with AVN and secondary osteoarthritis (OA) who had ankle arthrodesis. In the first group with AVN but no OA, at average followup of 34 months, the Mazur ankle score increased from 30 to 81 points postoperatively. There was no incidence of talar collapse and revascularization, and bone healing was seen in all the patients. In the second group of cases who had AVN and OA and underwent arthrodesis, 11 out of 12 attained union of the arthrodesis at an average followup of 34 months [Table 3].¹⁷

Struckmann *et al.* reported significant improvement in AOFAS scores in three patients at 1 year using a

vascularized autograft from the medial femoral condyle, with MRI showing good incorporation of the graft in all patients.⁴¹

In a recent study by Nunley *et al.*, 13 patients undergoing vascularized pedicle bone graft from cuboid with concomitant core decompression and bracing were included. Those cases with AVN involving <60% of talus on MRI and with articular collapse up to 1 mm were included. At an average followup of 6 years, they noted significant improvement in the physical component summary by 23.3 ($P = 0.006$) points and mental component summary score by 39.4 points ($P < 0.001$). Two patients had failure and required TAR, while one patient required arthroscopic debridement for soft tissue impingement. No progression of collapse was seen in 2 (out of the 13 patients) who had 1 mm of talar dome collapse preoperatively.⁹

All the above studies prove that a vascularized bone graft can give satisfactory and predictable outcomes with joint preservation in patients even up to Stage III of the disease and can be combined with arthrodesis in cases with OA and collapse.

Joint-Sacrificing Procedures

Partial or total talar replacement

Harnroongroj *et al.* first introduced talar dome prosthesis for cemented fixation made from stainless steel templated from plain radiographs. Sixteen patients between 1974 and 1990 were operated (12 cases due to AVN and the rest 4 due to crushed talus). One patient had failure of prosthesis at 8 months. Of the nine patients who were available for followup between 11 and 15 years, eight had satisfactory results and one patient had an unsatisfactory result because the prosthetic stem had sunk into the talar neck.¹⁸

Taniguichi *et al.* reported their experience with partial talar replacement (of the talar body) using a ceramic prosthesis (1999–2006) – first generation (with a peg for attachment into residual talar neck and head, 8 patients) and second generation (without the peg, 14 patients). At a mean followup of 98 months, good to excellent results were reported in 12/22 (54.5%) patients with a significant improvement in AOFAS scores postoperatively with no significant difference between the two groups. Conversion to total talar prosthesis was required in four patients, two in each group, due to loosening and fracture of head and neck of talus. They eventually recommended use of a total talar implant (which the authors started using from 2005) because of the higher potential for failure with talar body prosthesis [Table 4].¹⁹

TTR with a custom-made prosthesis has shown promising results. This has the advantage of maintaining a reasonable amount of ankle and subtalar motion while maintaining ankle height.

Taniguichi *et al.*, who have the biggest series, started using Alumina Ceramic Total Talar Prosthesis from 2005

and reported their results in 55 ankles (in 51 consecutive patients of osteonecrosis) by assessing Japanese Society for Surgery of the Foot Ankle-Hindfoot Scale and the Ankle Osteoarthritis Scale before surgery and at the final followup and noted favourable results and concluded it to be a useful procedure for patients with osteonecrosis of the talus as it maintains ankle function.¹⁹

A case series by Angthong *et al.* involving four patients using custom total talar prosthesis (anatomic metallic version) included one 25 year old male patient undergoing TTR for AVN of talus. There was a significant improvement in the VAS-FA score (from 6 to 57.5) and Social Functioning (SF)-36 score (19.3–73.7) with increase in dorsiflexion from 0° to 5° and plantar flexion from 0° to 16°. Inversion increased from 0° to 10° and eversion from 0° to 21°.⁴²

The first usage of TTR was however reported by Crespo Neches *et al.* in the early 1980s, who used them in four cases and noticed good results in three cases (one had a followup of 6 years).⁴³

Ando *et al.* reported a single case of a 72 year old female undergoing TTR with a custom-made alumina ceramic prosthesis with excellent outcome at 2 year followup. The AOFAS score increased from 45 to 90 postoperatively with increased dorsiflexion from 0° to 20° and plantar flexion from 20° to 40°. At final followup, the prosthesis was found to be stable with no significant changes in the surrounding bones.⁴⁴

In spite of the encouraging results of talar replacement [as summarized in Table 4] with reasonable restoration of joint mobility, rapid pain relief, shorter period of immobilization, and limb length preservation, further long term studies are needed to evaluate the survival and risk of development of degenerative changes in adjacent bones. The availability and cost of these custom made prostheses will be a big constraint in their widespread use in the near future.

Role of salvage procedures

Salvage procedures include various arthrodesis procedures with or without concomitant partial or complete talectomy. These are regarded as the last line of treatment, especially in the young population, and the main aim is to create a well-aligned, painless, plantigrade foot. Even after a successful fusion, these procedures are quite disabling for the patients with development of gait abnormalities and development of secondary arthritis in the surrounding joints [Figures 2b and 3]. The ankle is fused in neutral dorsi/plantar flexion, 0°–5° of hindfoot valgus and 5°–10° of external rotation with the talus aligned in line with the tibia. The principles of arthrodesis are the same as for joints elsewhere and the details of various technical modifications for arthrodesis at different joints are beyond the scope of this discussion. The different salvage procedures carried out for late stage of AVN of talus include talectomy, ankle

arthrodesis, subtalar and talonavicular fusion, Blair's tibiotalar (TT) fusion, TC, TT, and tibialocalcaneal (TTC) fusion [Table 5].

Talectomy

Either a partial or complete talectomy depending on the extent of involvement and a concomitant fusion procedure is carried out to avoid instability and maintain the limb length.

Subtalar and talonavicular fusion

These are reliable alternatives in patients without dome collapse and symptoms limited to the specific joints. Such a situation is rare. Rigid fixation is carried out by using cancellous or cannulated screws which may be supplemented by minifragment plates or staples and bone grafts.

Blair's tibiotalar fusion

This involves fusion of the talar neck and head with the distal anterior tibia (anterior sliding distal tibial osteotomy) usually with removal of talar body and structural graft augmentation. This kind of fusion has the advantage of preserving some subtalar motion, better cosmesis and shoe wearing, plus preservation of limb length.²¹ The original procedure was designed for severe posttraumatic bone loss in old fracture dislocation of talar body, but the procedure was later also used for severe dome collapse due to all causes of AVN with osteoarthritis of the ankle with limited success, which necessitated the need for modification of the procedure with rigid supplementary fixation with or without vascularized or nonvascularized bone grafts, with varying success. The original procedure has been reported to have high pseudoarthrosis rates (up to 28%) and the results are further compromised in the presence of AVN talus with higher chances of nonunion and progressive talar collapse. Hence, modifications have been devised to improve fusion rates by using different compression devices [Figure 3].

Lionberger *et al.* used a modification to bring about TT compression using an intermediate hip compression screw and modified bone staple. They reported a fusion rate of 80% (4/5) at 3 months.²⁷ Van Bergey *et al.* used anterior plate fixation and the healing rates were 71% (5/7) at 4 months. They reported a somewhat guarded functional outcome which they described to be "less than normal" with postoperative AOFAS hindfoot score of 67 and VAS scores for pain and function at 7.1 and 6, respectively.²⁸ In a recent case report, Ross *et al.* used an anterior compression plate and reported full incorporation of the graft at 6 weeks with good functional outcome and normal shoe-wearing ability.²¹

Use of vascularized anterior sliding tibial graft has the advantage of promoting neovascularization leading to better rates of fusion as compared to conventional nonvascularized grafts. This was reported by Kodama *et al.* while comparing

outcomes in 27 ankles (vascularized graft in 17 and conventional in 10 ankles) undergoing fusion for OA of ankle secondary to AVN of talus.³⁰ The functional outcome scores were better in the vascularized graft group with mean postoperative AOFAS score in vascularized and conventional groups being 80.1 and 67.6 and mean postoperative Mazur scores being 74.6 and 65, respectively. Complete fusion was achieved in 13 ankles (76%) in vascularized group and 4 ankles (40%) in nonvascularized group.

Hindfoot fusion-tibiotalar, tibiocalcaneal fusion, and tibiotibialocalcaneal fusion

Urquhart *et al.* in their series of 11 patients where various hindfoot arthrodeses were performed for symptomatic osteonecrosis of talus noted good-to-excellent result in 9/11 patients (82%). The average time to fusion was 7 months. Two patients had nonunion due to infection which subsided and fused with further debridement. They concluded hindfoot arthrodeses for osteonecrosis to have excellent clinical outcome.²²

Kendal *et al.* performed arthroscopic ankle fusion for AVN of the talus in their cohort of 16 patients. Their primary outcome was fusion rate which was achieved in all 15/15 patients who were available at last followup. Thirteen patients reported resolution of pain at followup. Three patients who had ongoing pain underwent a subsequent successful subtalar fusion.²⁹

Kitaoka *et al.* in their arthrodesis series of 19 patients, 3 required arthrodesis only at ankle and the rest 16 needed both ankle and subtalar joints. External fixators were used in 13 cases, internal fixation in 4, and no fixation in 2 cases. Bone graft was used in all cases (14 cases for iliac crest and the rest 5 from local bone graft). Seven patients had excellent, six patients had good, three had fair, and three had poor results. Union was achieved in 16 patients.²³

Good results have been reported in different studies with the use of retrograde intramedullary nailing (IMN) for TTC fusion. Devries *et al.* reported 85% (12/14 ankles) solid fusion rate with the use of retrograde intramedullary nail for TTC arthrodesis done for AVN of talus with secondary OA.²⁵ The other two developed a stable, braceable pseudoarthrosis. Full weight bearing mobilization could be started at an average of 100.6 (36 range–195 days) days. All the seven patients in Millet *et al.*'s study undergoing TTC fusion achieved complete fusion with the use of IMN.⁴⁵

Tenebaum *et al.* reported 100% union in 14 patients (10 TTC fusion and 4 TC fusion) with the use of retrograde compression IMN without the use of structural allograft with significant improvement in VAS, AOFAS, and SF-36 scores postoperatively.²⁶

The inherent risks of using structural grafts for TC fusion are well recognized including graft collapse, donor site

morbidity, infection, and nonunion among others. Use of porous tantalum cones can alleviate most of these issues. Cohen *et al.* reported the use of porous tantalum tibial cone along with morselized fibular graft, bone marrow aspirate injection, and retrograde TC nailing in a 59-year-old male with posttraumatic global AVN of talus. At last followup at 21 months, the patient was asymptomatic and capable of unassisted weightbearing without any evidence of hardware loosening on radiographs. Further studies are needed to evaluate the role of porous tantalum cones in the setting of arthrodesis.⁴⁶

In the systematic review by Gross *et al.*, six studies involved arthrodesis conducted for AVN talus.³³ Although there was wide variability in the outcome measures used among the different studies, the aggregate outcome in the fusion group was reported to be excellent in 11 ankles, good in 10, fair in 3, and poor in 4 patients. The incidence of nonunion was high (up to 18%). Delayed union was seen in all the six patients in the study by Dennison *et al.* with the use of circular external fixator.²⁴ Due to the high rates of complications and longer duration of rehabilitation and long term morbidity associated with arthrodesis procedures, this is an unattractive but final treatment resort, particularly in young patients.

Total Ankle Replacement

Earlier studies on the use of cementless TAR in patients with AVN talus and secondary arthritis, although extremely limited, have not been encouraging.^{31,32} The propensity of progression of AVN and the inevitable progressive talar dome collapse eventually may lead to talar component subsidence followed by loosening of implant and instability.

Lee *et al.* observed that cementless TAR is likely to be successful if revascularization is complete and necrotic bone has healed completely and this seems to be the most important factor determining the success of cementless TAR done for AVN of talus.³¹

Newton *et al.* observed progression of talar collapse in two out of the three cases who had undergone TAR using the Scandinavian Total Ankle Replacement prosthesis.³²

Keeping this in mind, Devalia *et al.* reported a unique 2-staged technique in a cohort of seven patients. The first stage involved carrying out a subtalar fusion that would revascularize the talus through creeping substitution. Once complete fusion was achieved, a TAR was carried out. The average interval between the 2 stages was 9 months. Full weightbearing mobilization could be started at 2 weeks following TAR. The mean followup was 3 years. They observed significant improvement in pain with no evidence of talar component subsidence. The long term outcomes and eventual survival of prosthesis are yet to be determined.²⁰

Prognostic Significance of Hawkins Sign

The Hawkins sign refers to the line of subchondral lucency, first visible between 6 and 8 weeks after the injury and reflecting disuse osteopenia in vascularized bone. It has been considered as a reflector of developing AVN in talus fracture cases, wherein a negative Hawkins sign indicates a high chance of developing AVN. Several authors have studied the prognostic significance of Hawkins sign. Tezval *et al.* who followed more than 34 patients for 3 years observed that a positive Hawkins sign excludes future AVN (100% sensitivity, 57.7% specificity) and concluded Hawkins sign to be a good indicator of talus vascularity following fracture.³⁴ The Hawkins sign (when present) appeared between the 6th and the 9th week after trauma. Rodríguez-Paz *et al.* in their series of 23 cases observed positive Hawkins sign in 12 cases and none of those 12 developed necrosis. In the remaining 11 cases of Hawkins sign negative, 4 cases developed necrosis. They concluded that a positive Hawkins sign rules out the development of AVN in fractured talus, but its absence does not confirm it.³⁵ Schulze *et al.* in their followup of 65 fractures could evaluate the Hawkins sign in 24 of their patients and concluded the Hawkins sign to be a relatively reliable sign for vitality of the talus after fracture.³⁶ Lutz *et al.* and Schwarz *et al.* also found a positive Hawkins sign as a prognostic favorable sign in terms of osteonecrosis.^{37,38} Chen *et al.* in addition to observing Hawkins sign as a reliable predictor in excluding the possibility of AVN also tried to correlate Hawkins sign with ankle function by comparing the AOFAS scores of the Hawkins sign-positive and Hawkins sign-negative groups during the followup of their 44 cases. The AOFAS scores showed no statistically significant difference between Hawkins sign-positive group and Hawkins sign-negative group in Types I and II fractures. However, in Types III and IV fractures, the Hawkins sign-positive group had better AOFAS scores than the Hawkins sign-negative group. They also suggested that Hawkins sign-negative patients should undergo MRI examinations 12 weeks after the fractures, especially in high-energy traumatic cases.³⁹

Thus, literature conclusively proves that Hawkins sign has a high sensitivity and its appearance in a fractured talus case implies that talus vascularity is maintained and AVN is highly unlikely to occur.

Authors' Suggested Treatment Algorithm

Based on this review of literature, Figure 4 is a suggested treatment algorithm which can be followed in cases of AVN talus.

Any AVN talus case is first staged based on MRI and radiographs (FA staging). Attention is given to determine collapse and identify the sclerotic zones. Determining the etiology (whether traumatic or nontraumatic) is also important.

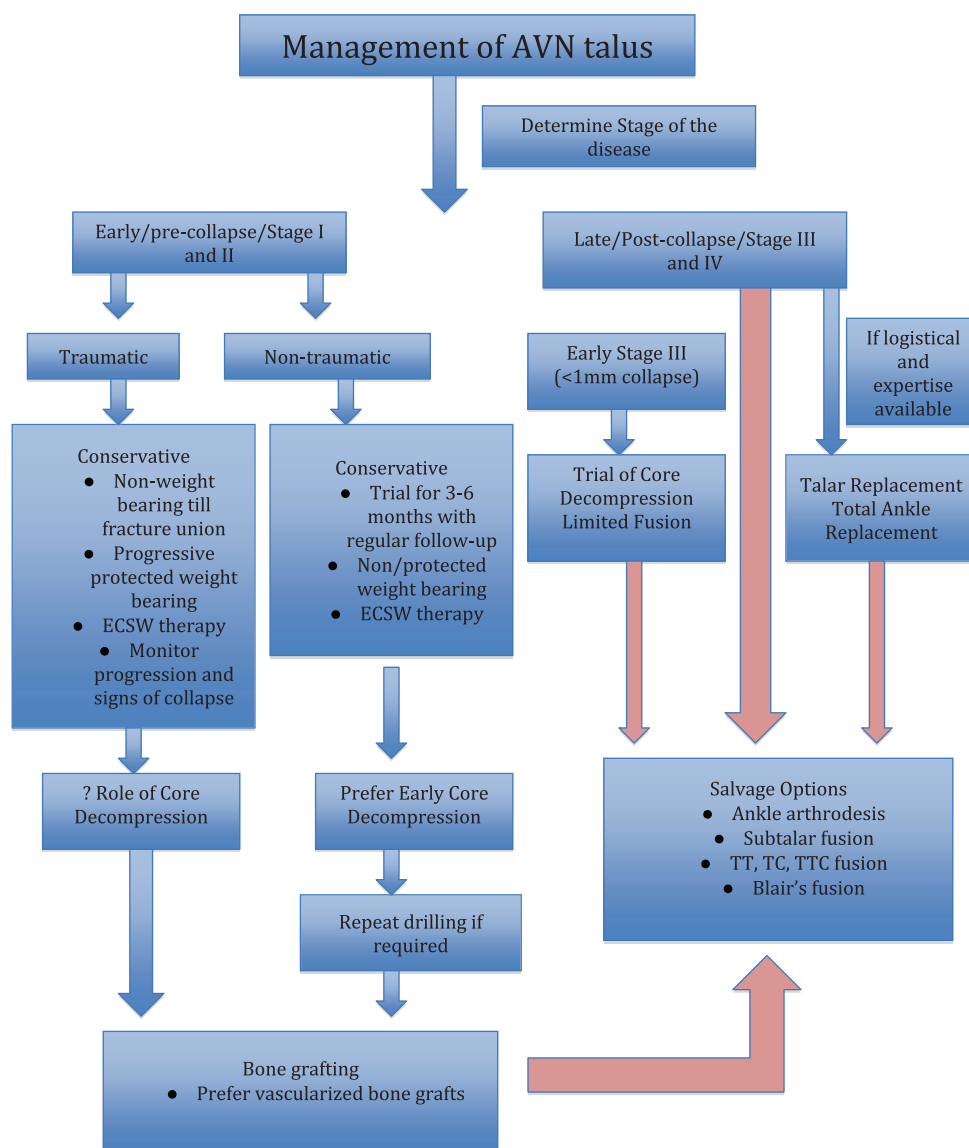


Figure 4: Suggested treatment algorithm

Early/precollapse/Stages I and II

(a) Traumatic AVN cases need strict nonweightbearing till fracture union (b) Conservative measures include nonweightbearing/protected weightbearing and ECSW (c) Prefer early core decompression in atraumatic cases (after a brief 3–6 months’ trial of conservative management) (d) Role of core decompression is doubtful in traumatic AVN (e) Bone grafting (preferably vascularized) is indicated in traumatic AVN and those atraumatic AVNs not responding to core decompression (f) Salvage options (ankle arthrodesis, subtalar fusion, TT, TC, TTC fusion, and Blair’s fusion) are viable options when all the above measures fail (g) Regular followup is important to monitor progression and collapse.

Late/postcollapse/Stages III and IV

(a) Early Stage 3 (<1 mm collapse) – A trial of core

decompression or limited fusion can be attempted (b) Talar replacement and TAR in the hands of experts and in ideal patients (low body mass index/nonsmoker), where feasible (c) Salvage options (ankle arthrodesis, subtalar fusion, TT, TC, TTC fusion, Blair’s fusion) as a primary procedure or when the above measures fail.

Conclusion

There are multiple treatment modalities available, varying from nonoperative treatment that works as long as the collapse of talar dome or body could be prevented, to interventions such as core decompression and vascularized grafts that can delay but unfortunately not stop the progression of the disease to collapse and subsequent subtalar and ankle OA. Joint fusions are reserved for the inevitable sequelae of talar body collapse leading to subtalar or ankle OA. Conventional fusion techniques such

as Blair's fusion work well in such scenarios. Furthermore, other fusion techniques using retrograde nails or screws are readily available. Modern technology also makes prosthesis available though partial talar replacement has had limited success. TAR is an evolving concept though its effectiveness in the setting of AVN is not conclusive as talar collapse is a hindering issue. One alternative intervention could be fusion of subtalar joint and replacement of the ankle joint. However, conclusive evidence is still not available and further research is warranted for the same. In addition, Hawkins sign appears to be a good prognostic indicator for the treatment of such injuries as it aids in identifying the probability of collapse.

Financial support and sponsorship

Nil.

Conflicts of interest

There are no conflicts of interest.

References

- Penny JN, Davis LA. Fractures and fracture-dislocations of the neck of the talus. *J Trauma* 1980;20:1029-37.
- Canale ST, Kelly FB Jr. Fractures of the neck of the talus. Long term evaluation of seventy-one cases. *J Bone Joint Surg Am* 1978;60:143-56.
- Hawkins LG. Fractures of the neck of the talus. *J Bone Joint Surg Am* 1970;52:991-1002.
- Trauth J, Blasius K. Talus necrosis and its treatment. *Aktuelle Traumatol* 1988;18:152-6.
- Mindell ER, Cisek EE, Kartalian G, Dziob JM. Late results of injuries to the talus. Analysis of forty cases. *J Bone Joint Surg Am* 1963;45:221-45.
- Canale ST. Fractures of the neck of the talus. *Orthopedics* 1990;13:1105-15.
- Zhai L, Sun N, Zhang BQ, Wang JG, Xing GY. Effect of liquid-electric extracorporeal shock wave on treating traumatic avascular necrosis of talus. *J Clin Rehabil Tissue Eng Res* 2010;14:3135-8.
- Freund KG. Complicated fractures of the neck of the talus. *Foot Ankle* 1988;8:203-7.
- Nunley JA, Hamid KS. Vascularized pedicle bone-grafting from the cuboid for talar osteonecrosis: Results of a novel salvage procedure. *J Bone Joint Surg Am* 2017;99:848-54.
- Yu XG, Zhao DW, Sun Q, Wang TN, Yu HB, Su Y, *et al.* Treatment of non-traumatic avascular talar necrosis by transposition of vascularized cuneiform bone flap plus iliac cancellous bone grafting. *Zhonghua Yi Xue Za Zhi* 2010;90:1035-8.
- Mont MA, Schon LC, Hungerford MW, Hungerford DS. Avascular necrosis of the talus treated by core decompression. *J Bone Joint Surg Br* 1996;78:827-30.
- Delanois RE, Mont MA, Yoon TR, Mizell M, Hungerford DS. Atraumatic osteonecrosis of the talus. *J Bone Joint Surg Am* 1998;80:529-36. Erratum in: *J Bone Joint Surg Am* 1999;81:296.
- Marulanda GA, McGrath MS, Ulrich SD, Seyler TM, Delanois RE, Mont MA, *et al.* Percutaneous drilling for the treatment of atraumatic osteonecrosis of the ankle. *J Foot Ankle Surg* 2010;49:20-4.
- Issa K, Naziri Q, Kapadia BH, Lamm BM, Jones LC, Mont MA, *et al.* Clinical characteristics of early-stage osteonecrosis of the ankle and treatment outcomes. *J Bone Joint Surg Am* 2014;96:e73.
- Zhang Y, Liu Y, Jiang Y. Treatment of avascular necrosis of talus with vascularized bone graft. *Zhongguo Xiu Fu Chong Jian Wai Ke Za Zhi* 1998;12:285-7.
- Doi K, Hattori Y. Vascularized bone graft from the supracondylar region of the femur. *Microsurgery* 2009;29:379-84.
- Kodama N, Takemura Y, Ueba H, Imai S, Matsusue Y. A new form of surgical treatment for patients with avascular necrosis of the talus and secondary osteoarthritis of the ankle. *Bone Joint J* 2015;97-B:802-8.
- Harnroongroj T, Vanadurongwan V. The talar body prosthesis. *J Bone Joint Surg Am* 1997;79:1313-22.
- Taniguchi A, Takakura Y, Tanaka Y, Kurokawa H, Tomiwa K, Matsuda T, *et al.* An alumina ceramic total talar prosthesis for osteonecrosis of the talus. *J Bone Joint Surg Am* 2015;97:1348-53.
- Devalia KL, Ramaskandhan J, Muthumayandi K, Siddique M. Early results of a novel technique: Hindfoot fusion in talus osteonecrosis prior to ankle arthroplasty: A case series. *Foot (Edinb)* 2015;25:200-5.
- Ross JS, Rush SM, Todd NW, Jennings MM. Modified Blair tibiotalar arthrodesis for posttraumatic avascular necrosis of the talus: A case report. *J Foot Ankle Surg* 2013;52:776-80.
- Urquhart MW, Mont MA, Michelson JD, Krackow KA, Hungerford DS. Osteonecrosis of the talus: Treatment by hindfoot fusion. *Foot Ankle Int* 1996;17:275-82.
- Kitaoka HB, Patzer GL. Arthrodesis for the treatment of arthrosis of the ankle and osteonecrosis of the talus. *J Bone Joint Surg Am* 1998;80:370-9.
- Dennison MG, Pool RD, Simonis RB, Singh BS. Tibiocalcaneal fusion for avascular necrosis of the talus. *J Bone Joint Surg Br* 2001;83:199-203.
- Devries JG, Philbin TM, Hyer CF. Retrograde intramedullary nail arthrodesis for avascular necrosis of the talus. *Foot Ankle Int* 2010;31:965-72.
- Tenenbaum S, Stockton KG, Bariteau JT, Brodsky JW. Salvage of avascular necrosis of the talus by combined ankle and hindfoot arthrodesis without structural bone graft. *Foot Ankle Int* 2015;36:282-7.
- Lionberger DR, Bishop JO, Tullos HS. The modified Blair fusion. *Foot Ankle* 1982;3:60-2.
- Van Bergeyk A, Stotler W, Beals T, Manoli A 2nd. Functional outcome after modified Blair tibiotalar arthrodesis for talar osteonecrosis. *Foot Ankle Int* 2003;24:765-70.
- Kendal AR, Cooke P, Sharp R. Arthroscopic ankle fusion for avascular necrosis of the talus. *Foot Ankle Int* 2015;36:591-7.
- Kodama N, Takemura Y, Shioji S, Imai S. Arthrodesis of the ankle using an anterior sliding tibial graft for osteoarthritis secondary to osteonecrosis of the talus: A comparison of vascularised non-vascularised grafts. *Bone Joint J* 2016;98-B:359-64.
- Lee KB, Cho SG, Jung ST, Kim MS. Total ankle arthroplasty following revascularization of avascular necrosis of the talar body: Two case reports and literature review. *Foot Ankle Int* 2008;29:852-8.
- Newton SE 3rd. Total ankle arthroplasty. Clinical study of fifty cases. *J Bone Joint Surg Am* 1982;64:104-11.
- Gross CE, Haughom B, Chahal J, Holmes GB Jr. Treatments for avascular necrosis of the talus: A systematic review. *Foot Ankle Spec* 2014;7:387-97.
- Tezval M, Dumont C, Stürmer KM. Prognostic reliability of

- the Hawkins sign in fractures of the talus. *J Orthop Trauma* 2007;21:538-43.
35. Rodríguez-Paz S, Muñoz-Vives JM, Froufe-Siota MÁ. Is the Hawkins sign able to predict necrosis in fractures of the neck of the Astragalus? *Rev Esp Cir Ortop Traumatol* 2013;57:403-8.
 36. Schulze W, Richter J, Russe O, Ingelfinger P, Muhr G. Prognostic factors for avascular necrosis following talar fractures. *Z Orthop Ihre Grenzgeb* 2002;140:428-34.
 37. Lutz M, Golser K, Sperner G, Gabl M, Wambacher M, Sailer R, *et al.* Posttraumatic ischemia of the talus. Is talus necrosis unavoidable? *Unfallchirurg* 1998;101:461-7.
 38. Schwarz N, Eschberger J, Kramer J, Posch E. Radiologic and histologic observations in central talus fractures. *Unfallchirurg* 1997;100:449-56.
 39. Chen H, Liu W, Deng L, Song W. The prognostic value of the Hawkins sign and diagnostic value of MRI after talar neck fractures. *Foot Ankle Int* 2014;35:1255-61.
 40. Ficat RP. Idiopathic bone necrosis of the femoral head. Early diagnosis and treatment. *J Bone Joint Surg Br* 1985;67:3-9.
 41. Struckmann VF, Harhaus L, Simon R, Woelfl C, von Recum J, Thiele J, *et al.* Surgical revascularization-an innovative approach to the treatment of talar osteonecrosis dissecans stages II and III. *J Foot Ankle Surg* 2017;56:176-81.
 42. Anghong C. Anatomic total talar prosthesis replacement surgery and ankle arthroplasty: An early case series in Thailand. *Orthop Rev (Pavia)* 2014;6:5486.
 43. Crespo Neches A, Crespo Neches S. Total astragaloplasty. *Foot Ankle* 1983;3:203-6.
 44. Ando Y, Yasui T, Isawa K, Tanaka S, Tanaka Y, Takakura Y, *et al.* Total talar replacement for idiopathic necrosis of the talus: A case report. *J Foot Ankle Surg* 2016;55:1292-6.
 45. Millett PJ, O'Malley MJ, Tolo ET, Gallina J, Fealy S, Helfet DL, *et al.* Tibiotalocalcaneal fusion with a retrograde intramedullary nail: Clinical and functional outcomes. *Am J Orthop (Belle Mead NJ)* 2002;31:531-6.
 46. Cohen MM, Kazak M. Tibiocalcaneal arthrodesis with a porous tantalum spacer and locked intramedullary nail for posttraumatic global avascular necrosis of the talus. *J Foot Ankle Surg* 2015;54:1172-7.