

Device closure of post-myocardial infarction ventricular septal defect three weeks after coronary angioplasty

A. N. Patnaik, Ramachandra Barik, N. Rama Kumari, A. S. Gulati

Department of Cardiology, Nizam's Institute of Medical Sciences, Hyderabad, Andhra Pradesh, India

Address for correspondence: Dr. A. N. Patnaik, Department of Cardiology, Nizam's Institute of Medical Sciences, Hyderabad - 500 082, Andhra Pradesh, India. E-mail: anpatnaik@yahoo.com

ABSTRACT

Percutaneous device closure appears to be safe and effective in patients treated for a residual shunt after initial surgical closure, as well as after two to three weeks of index myocardial infarction. The index case presented with a ventricular septal defect on second of acute myocardial infarction thrombolysed with streptokinase. The general condition of the patient was fairly stable. Cardiac catheterization and coronary angiography showed significant left to right shunt and there was 90 % proximal stenosis of left anterior descending coronary artery. Other coronary arteries were normal. Angioplasty and stenting to the coronary artery lesion was done using drug eluting stent (DES) with very good angiographic result. Patient was discharged after four days in stable condition. After 3 weeks his ventricular septal defect was closed percutaneously using cardio –O-fix device with tiny residual shunt. The procedure was uneventful and of brief duration. He was discharged after 5 days of the post procedure in very stable condition with minimal residual shunt. A staged procedure is a better option if the condition of the patient allows strengthening ventricular septal defect border.

Key words: Cardio-Fix-Occluder, myocardial infarction, ventricular septal defect

INTRODUCTION

Ventricular septal defect (VSD) complicating acute myocardial infarction (AMI) is reported in 0.2 % the patients in this thrombolytic era. In the first week, the incidence is about 1-2%. On medical management alone, 94 % die within 30 days.^[1,2] Emergent surgical closure of post infarction VSD with or without appropriate revascularization irrespective of the clinical status had been the standard treatment.^[3] Mortality rates of surgical closure remain high at 20 – 87% in most series.^[4,5] Many surgeons prefer surgical closure after a 3 – 4 week delay to allow scarring of the surrounding tissue, which allows better anchoring of sutures. An interventional approach using a device is a less

invasive option, and allows immediate complete closure after initial hemodynamic stabilization. Immediate reduction of the left-to-right shunt, even if the VSD is not completely closed, may stabilize the patient enough to function as a bridge to surgery.^[6] Current interventional reports are mainly restricted to VSD closure in the sub acute or chronic setting, or for residual shunts after initial surgical closure.^[7-9] We report a case of anterior myocardial infarction (MI) which was subjected to per-cutaneous transluminal coronary angioplasty (PTCA) of the culprit lesion on fourth day of myocardial infarction, and closure of VSD with a device 3 weeks later, to allow reasonable stabilization of patient and the rims of the defect.

CASE REPORT

A 60 year old gentleman without previous history of hypertension, diabetes mellitus and smoking, sustained an acute anterior wall myocardial infarction, and was thrombolysed with streptokinase within a window period of six hours at a local hospital. He was shifted to our hospital

Access this article online	
Quick Response Code: 	Website: www.jcdronline.com
	DOI: 10.4103/0975-3583.95374

on detection of a ventricular septal defect, ongoing angina and breathlessness at rest next day. On admission, he was in congestive heart failure of Killip II with a pulse rate of 109/minute, blood pressure of 100/70 mm Hg and a grade IV pan systolic murmur at left lower parasternal area. His 12 lead surface electrocardiogram (ECG) was consistent with evolved acute anterior wall myocardial infarction [Figure 1]. Two-dimensional and 3-dimensional echocardiogram showed akinetic mid and distal interventricular septum and apex, moderate left ventricular dysfunction and a muscular ventricular septal defect of 10 mm size in the anterior-middle part of the septum [Figure 2]. Cardiac catheterization done on the same day revealed a single muscular ventricular septal defect of size 10 mm [Figure 3], with a significant step up of oxygen saturation at right ventricular level by 23% and the ratio of pulmonary blood flow (QP) to the systemic blood flow (Qs) depicted as QP/QS equal to 1.8:1. Pulmonary artery pressure (40/12/15 mm Hg) and pulmonary wedge pressure (mean-17 mmHg) was mildly elevated. Left Anterior Descending artery was the only affected vessel with proximal 90% stenosis (Type B;

Society of Coronary Angiography and Interventions (SCAI) [Figures 4 and 5]. Coronary angioplasty using a drug eluting (Endeavour Resolute 3 mm × 15 mm) stent was done with good angiographic result [Figure 6]. He was pain free and asymptomatic since then. The device closure was planned after 4 weeks; however had to be done earlier as patient was unwilling to stay longer than 3 weeks in hospital due to some domestic problem.

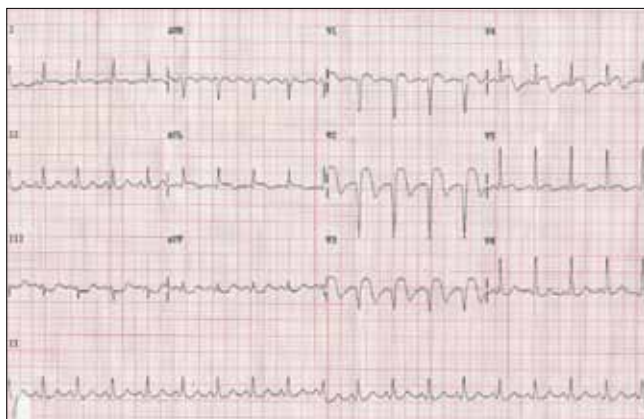

Figure 1: 12 lead electrocardiography shows persistent ST segment elevation in V2-V4 even after thrombolysis as an evidence of septal aneurysm

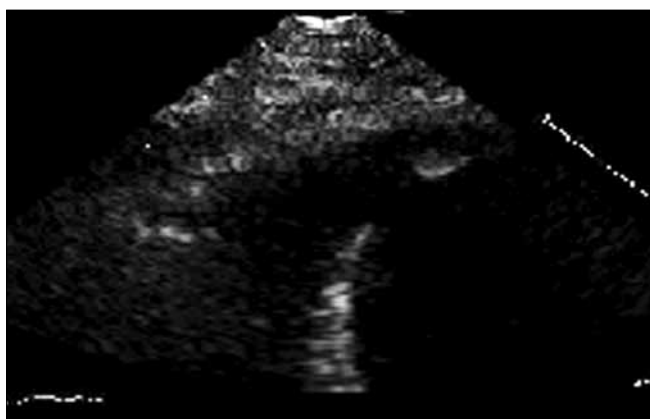


Figure 2: Echocardiography in apical four chamber view single and discrete muscular septal defect

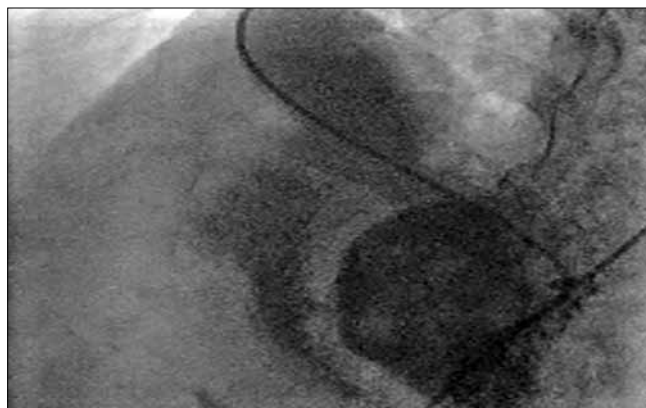


Figure 3: Left ventricular angiogram in left anterior oblique view shows single discrete muscular VSD of size 10mm

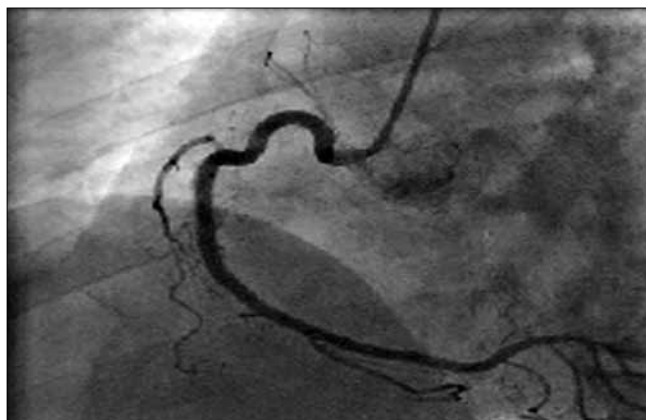

Figure 4: Selective coronary hooking of right coronary artery reveals normal right coronary artery

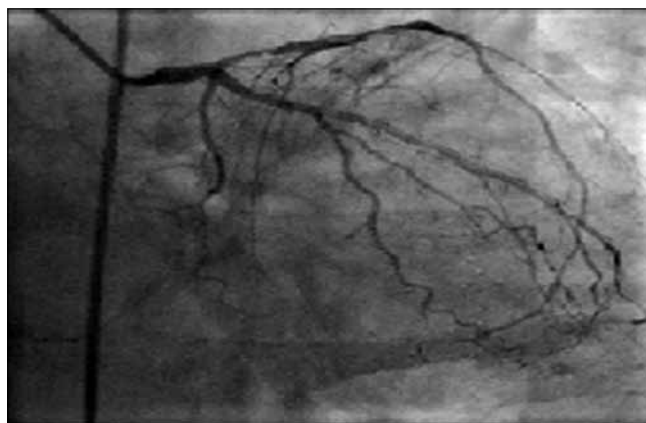


Figure 5: Selective left coronary injection shows type B proximal significant stenosis in left anterior descending artery

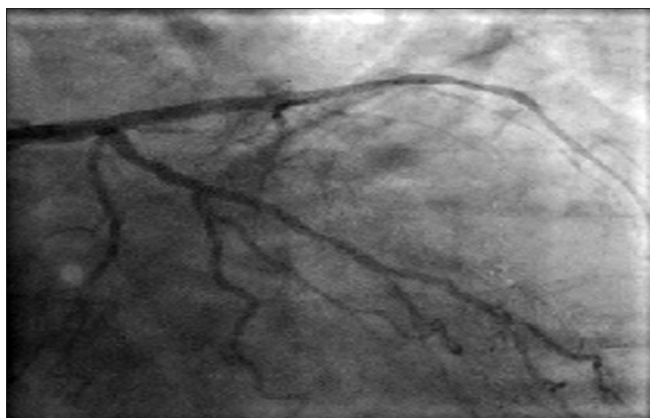


Figure 6: Successful angioplasty and stenting of left anterior descending artery with very good angiographic result

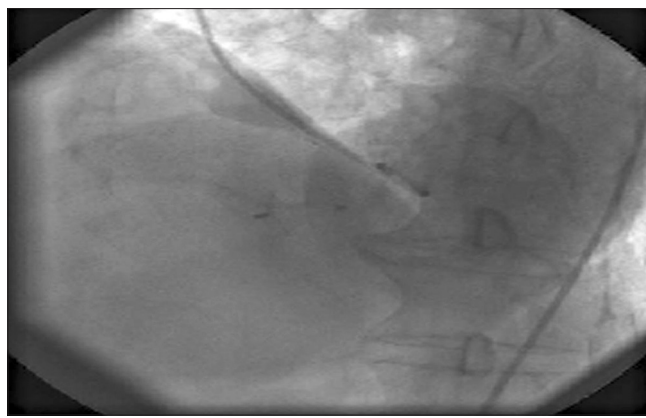


Figure 8: Appropriate placement of Cardio-Fix septal occluder across ventricular septal defect with tiny residual shunt is evident from left ventricular angiogram in left anterior oblique view

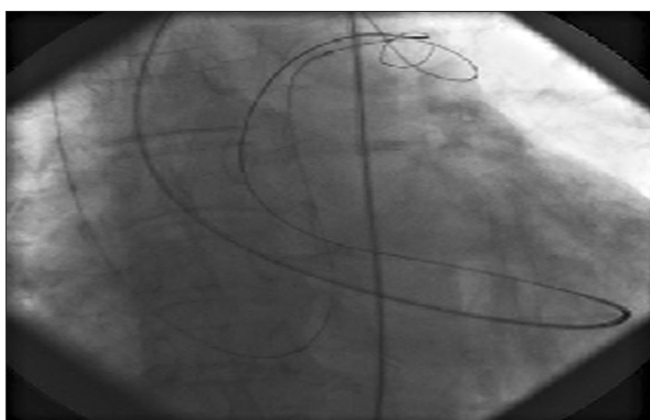


Figure 7: Successful snaring of regular guide wire from left pulmonary artery from right internal jugular venous approach

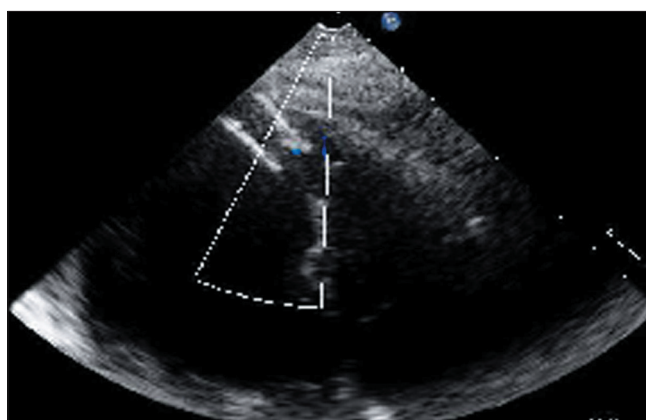


Figure 9: Two dimensional color Doppler showing septal occluder exactly across the ventricular septal defect after four days of procedure

On day-23, the right femoral artery and right internal jugular vein were cannulated under local anesthesia. After a left ventricular angiogram ventricular septal defect was crossed using 5 french right Judkin's (JR) catheter and a 0.035" × 260 cm angled tip Terumo wire (Terumo, Tokyo, Japan) using a retrograde arterial approach. It was passed into right ventricle, to main pulmonary artery and then into the left pulmonary artery. The right Judkin's catheter was advanced a little more into Right ventricular outflow tract (RVOT) and the Terumo wire was exchanged with 0.035" × 260 cm Teflon exchange length wire (Medtronic). The distal end of that wire was then caught with a 10 mm Amplatzer goose-neck snare (Microvena, MN) in the left pulmonary artery [Figure 7], and extracted outside via the right internal jugular sheath. A 12 Fr 180 degree curve device delivery sheath with its dilator (Star Way Medical Technology, Inc) was advanced from the jugular vein into the left ventricle (LV) across the VSD. Then dilator and the guide wire were removed. A 14 mm Cardio-O-Fix septal occluder was screwed onto the delivery cable, and introduced into the sheath. The distal disc (left ventricle) was initially opened and pulled back onto the LV side of

the septum under trans-thoracic echocardiography (TTE) and fluoroscopic guidance. After confirming the septal alignment, the proximal disc (right ventricle) was also opened. Once adequate placement was ascertained by TTE and left ventricular angiogram, the device was released [Figure 8]. TTE and left ventricular angiography showed proper positioning of device with only minimal shunting through the device. Patient remained hemodynamically stable after the procedure. The duration of procedure was 35 minutes. TTE on the next day showed only a trivial residual shunt [Figure 9]. The patient was discharged on day 4 in a stable condition. At 4 month follow-up, he remained symptom free and had fair left ventricular function on echocardiogram.

DISCUSSION

Ventricular septal defect (VSD) complicates acute myocardial infarction in about 1-2% cases in the first week.^[1] Surgical closure had been the gold standard of this fatal complication.^[2] As the mortality rates of surgical

closure remains high at 20 – 87% in acute stage, surgeons recommend a 3 – 4 week delay to allow scarring of the surrounding tissue to occur, which allows for better anchoring of sutures. Device closure of post infarction VSD is more studied in sub-acute and chronic stages and for residual shunts after surgical closure. Till today there are no guidelines available for device closure of ventricular septal defect after myocardial infarction. The small series and anecdotal reports highlighted that device closure in acute settings has a high mortality and more complications like device embolization, major shunting, left ventricular rupture and malignant arrhythmias.^[7-10] The reported number of interventional post infarction VSD procedures till Nov 2009 were less than 200 in literature.^[11] In a recent study, Demkow and colleagues described their 5 year experience with Amplatzer device with satisfactory results. For very severely ill patients, surgery may be a better option.^[12-14]

The possible difficulties faced by intervention cardiologist are I) lack of expertise due to the rarity of the procedure, II) the rigid delivery sheath that has to cross the ventricular septal defect (VSD) and needs to be advanced into the direction of the left ventricular outflow tract, might tear the borders of the VSD, resulting in an increased VSD size or, in the worst case, left ventricular rupture III) The requirement of guide wire removal after insertion of the delivery sheath may result in kinking of sheath or jumping of device into right ventricle and IV) The currently available device sizes of the muscular VSD occluder not sufficient to close the large and complex VSD. Furthermore, healing of the infarcted myocardium over time may increase the size of the VSD leading to device malposition and embolization. This requires the use of devices that are larger than the measured VSD size at the time of implantation. The higher transventricular pressure for a VSD leads to persistent shunting until thrombus formation and endothelialization of the device has occurred. In contrast to surgical VSD closure, inferior and basal VSDs are more easily closed with an interventional technique due to the more favorable access from the upper jugular vein.

We critically analyzed all four variables: The hemodynamic status, coronary artery disease burden, VSD profile and financial aspects before adopting this strategy for ventricular defect closure after myocardial infarction. The timing of the procedure was critical. As the patient had angina and we found a significant critical lesion, we did angioplasty of the coronary artery lesion on fourth day. As the acute setting has potential for more complications, we staged the VSD closure to a later date. We had to take up the device closure a few days earlier than a desirable gap of

4 four weeks as the patient gave only conditional consent. Literature review showed only few anecdotal reports for device closure with Cardio-O-Fix VSD occluder which is used by us. This device is less expensive than commonly used ones. The use of this device in a case of post-operative residual VSD was recently presented in.^[15] The StarwayCardio-O-Fix VSD Occluder is a self-expandable, double disc implant device made from a Nitinol wire mesh. The two discs are linked together by a short connecting waist corresponding to the size of the VSD. In order to increase its closing ability, the discs and the waist are filled with polyester fabric. The polyester fabric is securely sewn to each disc by surgical sutures. In our experience it is as user friendly as Amplatzer VSD occluder.

CONCLUSION

In reasonably hemodynamically stable patient, with a favorable coronary anatomy and ventricular septal defect anatomy, an initial percutaneous revascularization of culprit lesion and elective device closure of VSD at a later date may make a safer strategy as alternative to surgery. This strategy also helps using local anesthesia instead of general anesthesia, TTE in place of trans-esophageal echocardiogram and Cardio-O-fix device as an used alternative to Amplatzer VSD occluder, hence adding to the safety and reduced cost of the whole procedure.

REFERENCES

1. Crenshaw BS, Granger CB, Birnbaum Y, Pieper KS, Morris DC, Kallan NS, *et al.* Risk factors, angiographic patterns, and outcomes in patients with ventricular septal defect complicating acute myocardial infarction. GUSTO-I (Global Utilization of Streptokinase and TPA for Occluded Coronary Arteries) Trial Investigators. *Circulation* 2000;101:27-32.
2. Lee WY, Cardoon L, Slodki SJ. Perforation of infarcted interventricular septum. Report of a case with prolonged survival and review of the literature. *Arch Intern Med* 1962;109:731-5.
3. Ryan TJ, Antman EM, Brooks NH, Califf RM, Hillis LD, Hiratzka LF, *et al.* 1999 Update: ACC/AHA guidelines for the management of patients with acute myocardial infarction: A report of the ACC/AHA Task Force on Practice guidelines. *J Am Coll Cardiol* 1999;34:890-911.
4. Jepson A, Liden H, Johnson P, Hartford M, Radegran K. Surgical repair of post infarction Ventricular septal defects: A national experience. *Eur J Cardiothorac Surg* 2005;27:216-21.
5. Menon V, Webb JG, Hillis LD, Sleeper LA, Abboud R, Dzavik V, *et al.* Outcome and profile of ventricular septal rupture with cardiogenic shock after myocardial infarction: A report from the SHOCK Trial Registry. Should we emergently Revascularize Occluded Coronaries in cardiogenic shock? *J Am Coll Cardiol* 2000;36:1110-6.
6. Ahmed J, Ruygrok PN, Wilson NJ, Webster MW, Greaves S, Gerber I. Percutaneous closure of post myocardial infarction ventricular septal defects: A single centre experience. *Heart Lung Circ* 2008;17:119-23.
7. Goldstein JA, Casserly JP, Blazer DT, Lee R, LaSalle JM. Transcatheter closure of recurrent post Myocardial infarction ventricular septal defects utilizing the Amplatzer post infarction VSD device: A case series. *Catheter Cardiovasc Interv* 2003;59:238-43.
8. Holzer RJ, Balzer D, Amin Z, Ruiz CE, Feinstein J, Bass J, *et al.* Transcatheter Closure of post infarction ventricular septal defects using the new Amplatzer

- muscular VSD occluder: Results of the US registry. *Catheter Cardiovasc Interv* 2004;61:196-201.
9. Mullasari AS, Umesan CV, Krishnan U, Srinivasan S, Ravikumar M, Raghuraman H. Transcatheter Closure of post myocardial infarction ventricular septal defect with Amplatzer septal occluder. *Catheter Cardiovasc Interv* 2001;54:484-7.
 10. Nikolaos K, Stephen JD. Device closure for ventricular septal defect after myocardial infarction. *Cardiac Intervention Today*, Nov 2009.
 11. Demkow M, Ruzyllo W, Kepka C, Chmielak Z, Konka M, Dzielinska Z, *et al.* Primary Transcatheter closure of post infarction ventricular septal defects with the Amplatzer septal occluder - immediate results and up-to 5 years follow-up. *EuroIntervention* 2005;1:43-7.
 12. De Boer HD, De Boer WJ. Infarct exclusion, septal stabilization, and left ventricular remodeling. *Ann Thorac Surg* 1998;65:853-4.
 13. Killen DA, Piehler JM, Borkon AM, Gorton ME, Reed WA. Early repair of post infarction ventricular septal rupture. *Ann Thorac Surg* 1997;63:138-42.
 14. Prêtre R, Ye Q, Grünenfelder J, Lachat M, Vogt PR, Turina MI. Operative results of “repair” of ventricular septal rupture after acute myocardial infarction. *Am J Cardiol* 1999;84:785-8.
 15. Yalçın Y, Zeybek C, Onsel IO, Bilal MS. Transcatheter device closure of a residual postmyocardial infarction ventricular septal defect. *Türk Kardiyol Dern Ars* 2011;39:491-4.

How to cite this article: Patnaik AN, Barik R, Kumari NR, Gulati AS. Device closure of post-myocardial infarction ventricular septal defect three weeks after coronary angioplasty. *J Cardiovasc Dis Res* 2012;3:155-9.

Source of Support: Nil, **Conflict of Interest:** None declared.