

Transcapsular Decompression of Shoulder Ganglion Cysts



Cameron J. Phillips, M.D., Adam C. Field, B.S., and Larry D. Field, M.D.

Abstract: Paralabral cysts are an increasingly recognized cause of suprascapular nerve (SSN) impingement, often causing insidious weakness in the rotator cuff. Compression at the suprascapular notch is often due to the presence of a SLAP tear and leads to pain, weakness, and atrophy of both the supraspinatus and infraspinatus muscles. Compression of the SSN at the spinoglenoid notch leads to weakness and atrophy of the infraspinatus only. Arthroscopic decompression of cysts with repair of labral pathology is typically performed in a sublabral fashion, which may make visualization of the extent of the cyst difficult and places the SSN at increased risk. With any approach, an intimate knowledge of the anatomy of the SSN is vital to safe decompression. We present a surgical technique for decompression of paralabral cysts using an intra-articular transcapsular approach. This approach maximizes visualization and efficiency and reduces possible damage to the SSN.

Suprascapular neuropathy has been reported to cause 1% to 2% of all shoulder pain and is often overlooked.¹ However, the prevalence in higher-risk athletic populations, such as volleyball players, has been reported to be as high as 33%.² Suprascapular neuropathy had previously been viewed as a diagnosis of exclusion, but recent increases in awareness and improvements in diagnostic imaging have led to increased recognition of the disorder.³ Suprascapular neuropathy can present with atrophy and weakness in the supraspinatus, infraspinatus, or both and can be accompanied by pain or can be painless. When present, pain is localized to the posterior shoulder and is often described as a dull, aching pain. Pain tends to be present when the nerve impingement occurs at the suprascapular notch, because sensory fibers to the posterior capsule extend distally to the suprascapular notch but proximally to the spinoglenoid notch. Pathology can be due to either traction or compression of the

suprascapular nerve (SSN), and identification of the cause is critical in forming a treatment plan. Traction-related injury is treated by cessation of the inciting activity and may require repair of the rotator cuff in cases of retracted tears generating tension on the nerve. These injuries tend to be more refractory to conservative treatment.⁴ Compression injury is commonly caused by a paralabral ganglion cyst, which typically compresses the nerve at the spinoglenoid or suprascapular notch.⁵ Indications for nerve release include weakness or wasting of the infraspinatus with or without wasting of the supraspinatus. This may occur with or without pain and with or without positive electromyographic findings. Another indication for paralabral ganglion cyst nerve compression is posterior shoulder pain with a positive SSN stretch test, as described by LaFosse et al.⁶

The SSN arises from the upper trunk of the brachial plexus formed by the C5 and C6 roots, with a C4 contribution in 22% of cases.⁷ The nerve courses through the posterior triangle of the neck anteromedially to posterolaterally, through the suprascapular notch. After passing through the suprascapular notch and under the suprascapular ligament, it gives off sensory branches to the glenohumeral joint capsule and 1 to 3 motor branches to the suprascapular muscle. As it approaches the glenoid rim, the nerve can be found approximately 1 to 2.5 cm medial to the glenoid rim and approximately 4 cm from the posterior corner of the scapular spine.⁸ The nerve continues inferiorly toward the spinoglenoid notch, where it passes through a fibro-osseous tunnel formed by the spinoglenoid

From Mississippi Sports Medicine and Orthopaedic Center, Jackson, Mississippi, U.S.A.

The authors report the following potential conflicts of interest or sources of funding: L.D.F. receives support from AANA. Full ICMJE author disclosure forms are available for this article online, as [supplementary material](#).

Received May 4, 2018; accepted August 3, 2018.

Address correspondence to Larry D. Field, M.D., Mississippi Sports Medicine and Orthopaedic Center, 1325 E Fortification St, Jackson, MS 39202, U.S.A. E-mail: lfield@msmoc.com

© 2018 by the Arthroscopy Association of North America. Published by Elsevier. This is an open access article under the CC BY-NC-ND license (<http://creativecommons.org/licenses/by-nc-nd/4.0/>).

2212-6287/18558

<https://doi.org/10.1016/j.jats.2018.08.011>

ligament and the spine of the scapula, terminating in 2 to 4 motor branches to the infraspinatus muscle.

We present our preferred technique for arthroscopic intra-articular transcapsular decompression of paralabral ganglion cysts. This technique affords the surgeon a safe means of visualizing the extent of the cyst, ensuring complete decompression of the cyst with minimal chance of recurrence after limited capsulectomy. Critical to the technique is a knowledge of the course of the SSN, as well as the size and location of the ganglion cyst.

Surgical Technique

Although extensive labral repairs often require lateral decubitus positioning, patients with fluid sequestration in a ganglion cyst may only have a limited posterior labral tear or SLAP tear that can be addressed in the beach-chair position. The entire extremity is prepared and draped, and external landmarks are marked, including the coracoid, acromion, acromioclavicular joint, and portal incisions. These landmarks help preserve the surgeon's perspective on the bony anatomy and SSN course after insufflation and intraoperative edema make landmarks difficult to palpate. In this technique, the standard posterior viewing portal and anterior interval portal are consistently established, with the use of other accessory portals being case dependent.

A posterior viewing portal is established, and a 30° arthroscope is inserted into the glenohumeral joint. An anterior working portal is established in the rotator cuff interval using an outside-in technique with an 18-gauge spinal needle, and the labral pathology and cyst location are confirmed on careful diagnostic arthroscopy. The location of the cyst is identified using the clock-face location from preoperative magnetic resonance imaging (MRI). The labral tear may give rise to a cyst that propagates more inferiorly or superiorly from the tear itself, so localizing and characterizing the cyst on MRI are critical in determining the specific location of the limited capsulectomy (Fig 1).

Identification of the pericapsular location of the cyst allows a limited capsulectomy to begin exposing the margins of the cyst. With a probe, the capsule overlying the predetermined location of the cyst (from MRI) is probed and manipulated to confirm the location of the cyst behind the capsule (Fig 2). Then, by use of a shaver (Dyonics Platinum FR, 5.5 mm; Smith & Nephew), the capsule overlying the cyst is removed, which unroofs the lateral margin of the cyst. In the case of a SLAP tear, the shaver is used through the anterior portal, and the camera can be inserted through the capsular window from the posterior portal to examine the cyst. If the cyst extends very posteromedially, the camera can be switched to the anterior portal to drive into the cyst and ensure adequate decompression. In the case of a

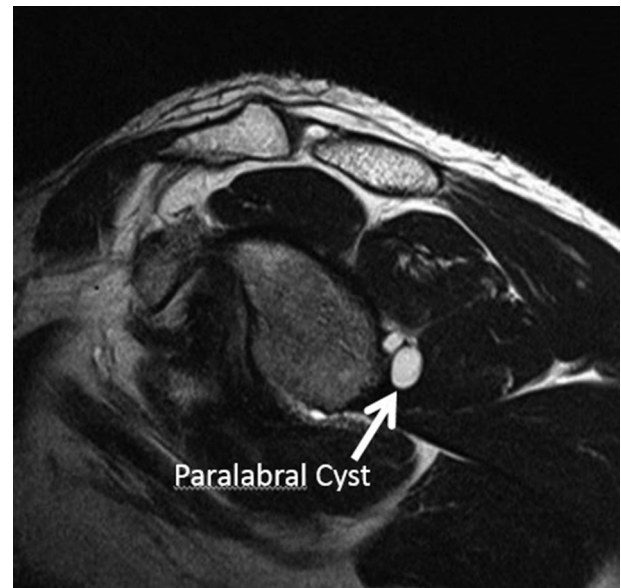

Fig 1. Sagittal oblique magnetic resonance imaging view of the en face glenoid showing the location of the paralabral cyst on the clock face of the glenoid to plan for the location of the limited capsular window (arrow). This view of the cyst is a critical component of this technique because it allows the surgeon to know the exact location of the cyst as it abuts the capsule. The location of the cyst as it abuts the capsule will determine the specific location of the limited capsular window that allows access to the cyst. In this view, the loculated cyst can be seen just off the posterior-inferior aspect of the glenoid, at roughly the 4-o'clock position.

posterior labral tear and ganglion cyst, the shaver is used from the posterior portal to create the capsular window, and the camera is then inserted posteriorly to drive into the cyst (Figs 3-5). This capsular window provides excellent visualization of the remaining cyst margins and may help identify the SSN and branches to the infraspinatus (Video 1). Table 1 presents advantages and disadvantages, and Table 2 lists pearls and pitfalls.

Discussion

Diagnosis and treatment of paralabral ganglion cysts have increased in the past 2 decades.³ The condition may still be underappreciated in overhead athletes and other individuals with external rotation weakness. Electrophysiological testing has been used to identify and further standardize diagnostic criteria and has been shown to confirm the diagnosis of suprascapular neuropathy in 4.3% of all initially presenting patients and in 43% of patients with clinical or radiographic suspicion of neuropathy in an academic shoulder referral practice.¹ The diagnosis is often made concurrently with other shoulder pathology and thus often may not be addressed with the appropriate significance. When one is treating patients with SLAP tears or posterior

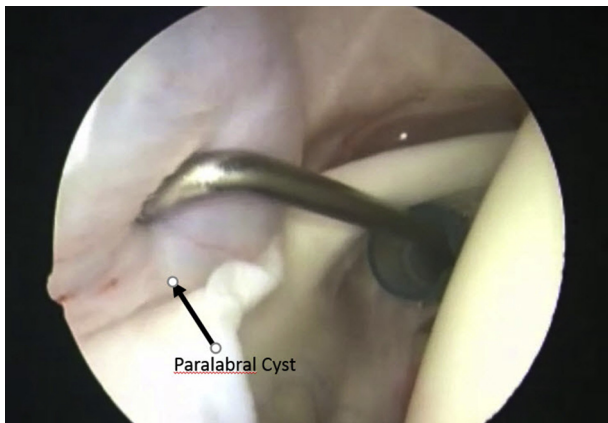


Fig 2. With visualization through the posterior portal with a 30° arthroscope with the patient in the beach-chair position, the probe is inserted through the anterior working portal through the rotator interval. In this case, the capsular tissue just posterior to the biceps origin is probed and manipulated to confirm the location of the paralabral cyst (arrow) just medial to the capsule. The location is determined from the reference point found on magnetic resonance imaging. Here, the probe can be seen to compress a fluid-filled mass just deep to the capsular tissue, which shows the most lateral margin of a posterior-superior paralabral cyst. This confirmation under direct visualization allows the surgeon to establish the location of the limited capsulectomy that is to be made to gain access to the cyst and decompress it.

labral tears, a critical examination for weakness on examination and a keen look at the MRI scan may help identify SSN-compressing ganglion cysts. Some controversy exists on the importance of decompression of a paralabral ganglion cyst in conjunction with repair of a

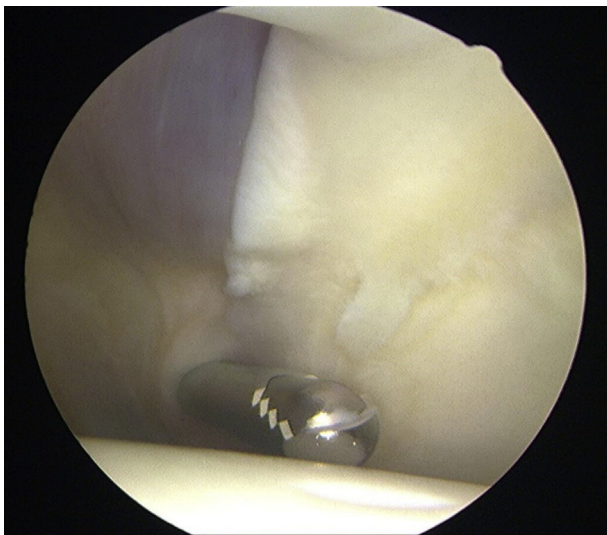


Fig 3. The same paralabral cyst as in [Figure 2](#) viewed from the anterior working portal with the patient in the beach-chair position, with a Smith & Nephew Dyonics 5.5-mm Full Radius shaver seen before the limited capsulectomy is performed.

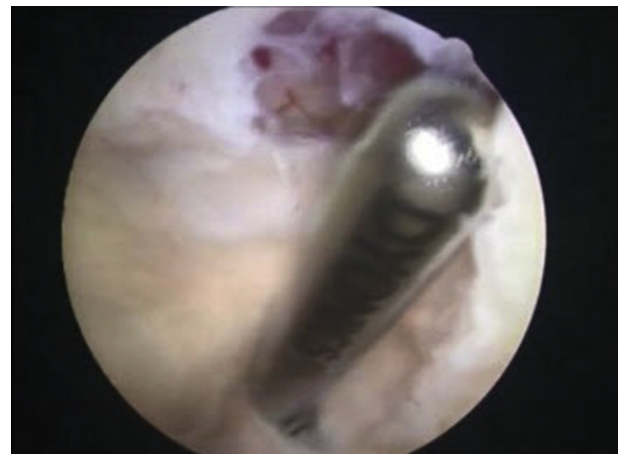

Fig 4. Performance of a limited capsulectomy using a Smith & Nephew Dyonics 5.5-mm Full Radius shaver from the posterior portal, viewed from the anterior portal, to create a window in the most lateral aspect of the cyst. This safely provides access to the cyst and allows complete decompression.

SLAP tear, with some authors advocating simple repair of the tear and no true cyst decompression.⁹ Other authors have shown that decompression aids in faster recovery of neuropathy, with more rapid increases in strength.¹⁰ A subacromial space approach has been described for SSN decompression but requires a significant resection of the subacromial bursa and places the SSN and coracoclavicular ligaments at risk of iatrogenic injury.¹¹

Arthroscopic treatment of intra-articular paralabral ganglion cysts has been well described, with the most common technique using a sublabral decompression.¹¹⁻¹³ Iannotti and Ramsey¹⁴ originally described a sharp sublabral decompression with a rosette knife under indirect visualization with good results in 3 patients. The sublabral approach limits visualization and may inhibit

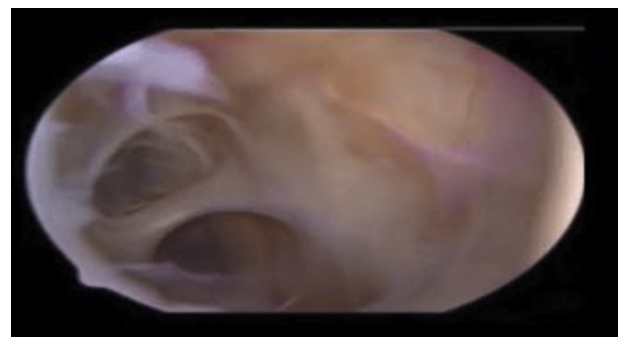


Fig 5. Arthroscopic photograph with the arthroscope inserted through the anterior portal with the patient in the beach-chair position. The arthroscope has been driven into the posterior paralabral cyst after the limited capsulectomy. This view shows the extensive nature of the cyst and confirms that adequate decompression has been performed.

Table 1. Advantages and Disadvantages of Limited Capsulectomy for Cyst Decompression

Technique advantages
The transcapsular technique avoids the potential necessity for excessive labral mobilization or potentially even labral destabilization that may be required to allow for adequate access to the cyst through a sublabral approach.
The limited capsulectomy preserves adequate capsular and ligamentous tissue that will not compromise glenohumeral stability postoperatively or reduce the surgeon's ability to reattach or advance capsular tissue as necessary intraoperatively.
The limited capsulectomy technique provides excellent visualization of the cyst and allows for reproducible and efficient unroofing and cyst decompression.
Technique disadvantages
Some controversy exists regarding the indications for decompression of paralabral ganglion cysts that occur in conjunction with labral tears, especially in the absence of clinical weakness or positive electrodiagnostic findings.
General consensus on this treatment has not been reached, with some authors advocating simple repair of the labral tear without cyst decompression.
A thorough knowledge of the anatomic location and course of the suprascapular nerve is critical to avoiding iatrogenic injury to this important structure.

one's ability to drive the camera into the cyst to appreciate its full extent. With only limited visualization, the surgeon may not recognize how medial the shaver blade is, and with the course of the SSN as little as 1 to 2 cm from the glenoid, this technique may carry undue risk. Paralabral cysts have been found to be multisegmented in as many as 75% of cases, which may lead to an incomplete decompression when a sublabral approach is used.¹⁵ A limited capsulectomy is often sufficient for easy visualization of the cyst's course and extent, and driving the camera into the cyst allows examination and decompression of loculations within the cyst if needed. This technique requires only a limited window in a specific location in the capsule to facilitate the camera and shaver working concomitantly within the cyst. This technique allows complete cyst decompression without destabilizing the labrum further as may occur in a sublabral decompression. The placement and extent of the

Table 2. Pearls and Pitfalls of Limited Capsulectomy for Paralabral Cyst Decompression

Pearls
Establish the position of the most lateral aspect of the cyst where it abuts the capsular wall.
Confirm the location of the cyst with a probe before performing the limited capsulectomy.
Size the capsulectomy appropriately to adequately decompress the cyst without resecting tissue in the medial aspect of the cyst.
Perform any labral work after the cyst is decompressed to appreciate the capsular anatomy without distortion from the cyst.
Pitfalls
Do not perform a complete debridement of the cyst: This places the suprascapular nerve at undue risk.

limited capsulectomy also allow the surgeon to leave enough paralabral capsular tissue to provide a robust suture repair of a posterior labral or SLAP tear. Some authors have reported a transcapsular technique of resecting the cyst in its entirety, with debridement of all margins of the cyst. This technique may be time-consuming and may still pose a risk to the SSN.¹⁶ Our limited capsulectomy allows excellent visualization of the extent of the cyst, minimizes the chance of recurrence, is technically fast and simple to perform, and has shown good results with excellent reproducibility.

References

1. Boykin RE, Friedman DJ, Zimmer ZR, Oaklander AL, Higgins LD, Warner JJP. Suprascapular neuropathy in a shoulder referral practice. *J Shoulder Elbow Surg* 2011;20:983-988.
2. Witvrouw E, Cools A, Lysens R, et al. Suprascapular neuropathy in volleyball players. *Br J Sports Med* 2000;34:174-180.
3. Moen TC, Babatunde OM, Hsu SH, Ahmad CS, Levine WN. Suprascapular neuropathy: What does the literature show? *J Shoulder Elbow Surg* 2012;21:835-846.
4. Menorca RMG, Fussell TS, Elfar JC. Peripheral nerve trauma: Mechanisms of injury and recovery. *Hand Clin* 2015;29:317-330.
5. Boykin RE, Friedman DJ, Higgins LD, Warner JJP. Suprascapular neuropathy. *J Bone Joint Surg Am* 2010;92:2348-2364.
6. Lafosse L, Piper K, Lanz U. Arthroscopic suprascapular nerve release: Indications and technique. *J Shoulder Elbow Surg* 2011;20:S9-S13 (suppl).
7. Lee HY, Chung IH, Sir WS, et al. Variations of the ventral rami of the brachial plexus. *J Korean Med Sci* 1992;7:19-24.
8. Plancher KD, Petterson SC. Posterior shoulder pain and arthroscopic decompression of the suprascapular nerve at the spinoglenoid notch. *Oper Tech Sports Med* 2014;22:73-87.
9. Youm T, Matthews PV, El Attrache NS. Treatment of patients with spinoglenoid cysts associated with superior labral tears without cyst aspiration, debridement, or excision. *Arthroscopy* 2006;22:548-552.
10. Pillai G, Baynes JR, Gladstone J, Flatow EL. Greater strength increase with cyst decompression and SLAP repair than SLAP repair alone. *Clin Orthop Relat Res* 2011;469:1056-1060.
11. Bhatia S, Chalmers PN, Yanke AB, Romeo AA, Verma NN. Arthroscopic suprascapular nerve decompression: Trans-articular and subacromial approach. *Arthrosc Tech* 2012;1:e187-e192.
12. Moore TP, Fritts HM, Quick DC, et al. Suprascapular nerve entrapment caused by supraglenoid cyst compression. *J Shoulder Elbow Surg* 1997;6:445-452.
13. Piatt BE, Hawkins RJ, Fritz RC, Ho CP, Wolf E, Schickendantz M. Clinical evaluation and treatment of spinoglenoid notch ganglion cysts. *J Shoulder Elbow Surg* 2002;11:600-604.

14. Iannotti JP, Ramsey ML. Arthroscopic decompression of a ganglion cyst causing suprascapular nerve compression. *Arthroscopy* 1996;12:739-745.
15. Shon MS, Jung SW, Kim JW, Yoo JC. Arthroscopic all intra-articular decompression and labral repair of paralabral cyst in the shoulder. *J Shoulder Elbow Surg* 2015;24:e7-e14.
16. Sreehari CK, Varshney A, Yoo Y-S, Lee S-J. Arthroscopic intra-articular spinoglenoid cyst resection following SLAP repair. *Arthrosc Tech* 2017;6:e1795-e1799.