

Atrial flutter: from ECG to electroanatomical 3D mapping

CLAUDIO PEDRINAZZI¹, ORNELLA DURIN¹, GIOSUÈ MASCIOLI², ANTONIO CURNIS², RICCARDO RADDINO², GIUSEPPE INAMA¹, LIVIO DEI CAS²

¹Department of Cardiology, Ospedale Maggiore, Crema - Italy

²Division of Cardiology, Department of Experimental and Applied Medicine, University of Brescia - Italy

ABSTRACT: Atrial flutter is a common arrhythmia that may cause significant symptoms, including palpitations, dyspnea, chest pain and even syncope. Frequently it's possible to diagnose atrial flutter with a 12-lead surface ECG, looking for distinctive waves in leads II, III, aVF, aVL, V1, V2. Puech and Waldo developed the first classification of atrial flutter in the 1970s. These authors divided the arrhythmia into type I and type II. Therefore, in 2001 the European Society of Cardiology and the North American Society of Pacing and Electrophysiology developed a new classification of atrial flutter, based not only on the ECG, but also on the electrophysiological mechanism. New developments in endocardial mapping, including the electroanatomical 3D mapping system, have greatly expanded our understanding of the mechanism of arrhythmias. More recently, Scheinman et al, provided an updated classification and nomenclature. The terms like common, uncommon, typical, reverse typical or atypical flutter are abandoned because they may generate confusion. The authors worked out a new terminology, which differentiates atrial flutter only on the basis of electrophysiological mechanism. (*Heart International* 2006; 3-4: 161-70)

KEY WORDS: Atrial flutter, Catheter ablation, ECG, Electroanatomical mapping

INTRODUCTION

Atrial flutter is a common arrhythmia that may cause significant symptoms, including palpitations, dyspnea, chest pain and even syncope. For five decades the mechanism of atrial flutter remained controversial with protagonists and antagonists of circus movement versus ectopic focus theories. The development of clinical electrophysiology in the 1970s and the observations made by many authors in various canine heart models supported the concept that flutter is a macro-reentrant arrhythmia, often determined by a re-entrant circuit confined to the right atrium (1-3).

The atrial rhythm, during atrial flutter, is regular (250-350 beats/min) with little or no isoelectric interval on the ECG. The surface 12-lead ECG is helpful in establishing a diagnosis of atrial flutter at least for the

common form due to counterclockwise reentry in the right atrium and the uncommon form with reverse activation sequence (4-6).

The first classification of atrial flutter was developed in 1970 by Puech et al (7) on the basis of the morphology of flutter waves on surface ECG. The authors classified atrial flutter as common (or typical), atypical and impure flutter. In the common form, there were predominantly negative F waves in inferior leads (II, III and aVF) and V6, with an atrial rate ranging from 250 to 330 b.p.m. In the atypical form, F waves were positive in inferior leads and V6, with the same rate as common atrial flutter. Impure flutter was defined as a transitional pattern between atrial flutter and atrial fibrillation, with an atrial rate > 320 b.p.m. In 1977, Waldo et al (8) developed another classification of atrial flutter, mainly based on the atrial rate and on the possibility of interrupting ar-

rhythmia with atrial pacing. Therefore, atrial flutter was divided into types I and II. Type I atrial flutter had an atrial rate of 240–340 b.p.m. and could be interrupted with overdrive atrial pacing. By contrast, type II atrial flutter had a faster atrial rate, between 340 and 430 b.p.m., and could not be interrupted with overdrive atrial pacing. Subsequent electrophysiological studies with mapping of the right atrium have demonstrated that type I typical flutter is caused by a macro-re-entrant circuit in the right atrium, which proceeds in a counterclockwise direction. By contrast, in type I atypical flutter, the macro-re-entrant circuit in the right atrium proceeds in a clockwise direction (1-13). Furthermore, the development of atrial mapping has also led to a better definition of the electrophysiological mechanisms of atypical atrial flutter.

In 2001 the European Society of Cardiology and the North American Society of Pacing and Electrophysiology (9) published a new atrial flutter nomenclature taking into consideration not only the ECG features, but also the electrophysiological mechanisms of the arrhythmia. In this classification the common and uncommon type I atrial flutter are called respectively typical and reverse typical. All the arrhythmias whose electrophysiological mechanisms are different from a macro-re-entrant circuit in the right atrium, which proceeds in counterclockwise or clockwise direction involving the CTI, are called atypical flutters.

More recently, Scheinman et al (10) provided an updated classification and nomenclature based on the most recent information on the electrophysiological mechanisms of atrial flutter derived from recently developed techniques of endocardial mapping (Tab. I). This classification is based only on electrophysiological mechanisms, without considering ECG features. It divides atrial flutter into right and left, depending on the cardiac chamber involved in the macroreentrant circuit. Right atrial flutters are then divided into CTI-dependent, if the CTI is involved in the circuit, or non CTI-dependent, if CTI is not involved. Within these two categories, various types of atrial flutter have been identified, depending on the precise location of re-entrant circuit. By contrast, left atrial flutter is classified only on the basis of circuit location.

However, surface ECG may be particularly useful for the diagnosis of atrial flutter and it may provide relevant information for its classification. In fact, frequently it is

possible to diagnose atrial flutter with a 12-lead surface ECG, looking for distinctive waves in leads II, III, aVF, V1. When flutter waves are not clearly visible, slowing AV nodal conduction through vagal stimulation manoeuvres or drugs increasing AV conduction block like Verapamil, makes their recognition easier. Furthermore, the presence of clearly detectable flutter waves in inferior leads and D1 is highly specific (up to 90%) for CTI-dependent atrial flutter, while in patients with non-CTI-dependent re-entrant circuit the ECG features are less specific (6, 9).

RIGHT ATRIAL CTI-DEPENDENT FLUTTER

Counterclockwise flutter (common form)

The ECG is very helpful in establishing a diagnosis of right atrial cavo-tricuspid isthmus (CTI)-dependent flutter, mainly the common form due to counterclockwise re-entry in the right atrium. This is the most common type of atrial flutter and makes up about 90% of clinical cases. It is sustained by macro-re-entrant circuits in the right atrium supported by endocardial structures such as crista terminalis, eustachian ridge/valve (posteriorly) and tricuspid annulus (anteriorly). The activation wave front proceeds in a cranial direction over the right atrial septum, reaches the top of the right atrium, then de-

TABLE I - CLASSIFICATION OF ELECTROPHYSIOLOGICAL MECHANISMS OF ATRIAL FLUTTER (From ref. 10 modified)

New classification of atrial flutter

- 1) Right atrial CTI-dependent flutter
 - Counterclockwise flutter (common)
 - Clockwise flutter (uncommon)
 - Double-wave reentry
 - Lower loop reentry
 - Intra-isthmus reentry
- 2) Right atrial nonCTI-dependent flutter
 - Scar-related flutter
 - Upper loop flutter
- 3) Left atrial flutter
 - Mitral annulus flutter
 - Scar and pulmonary vein-related flutter
 - Coronary sinus flutter
 - Left septal flutter

scends on the right atrial free wall in a caudal direction, and finally reaches the space located between the low part of the right atrium and the atrial septum. The inferior area, called cavotricuspid isthmus, is the critical link of the circuit and it is the target of the radiofrequency (RF) catheter ablation procedure. Several investigators reported that RF energy applied in the isthmus between inferior vena cava and tricuspid valve isthmus is effective in eliminating the atrial flutter.

The creation of a line of block with RF application in the isthmus between the inferior vena cava (IVC) and the tricuspid valve annulus (TA), with documentation of bidirectional block during pacing in coronary sinus, is actually considered a success index of RF ablation of the right atrial CTI-dependent counterclockwise flutter and the electrophysiological end-point of the procedure (11-19) (Fig. 1).

In the right atrial CTI-dependent counterclockwise flutter an inverted F wave with a sawtooth pattern is observed in the inferior leads II, III, aVF, with low amplitude biphasic F waves in leads I and aVL, an upright F wave in lead V1, with transition to an inverted F wave in lead V6 (Fig. 1). It is possible to confirm the 12-lead ECG diagnosis with an electrophysiological study with mapping and entrainment to demonstrate the counterclockwise sequence in the right atrium (Fig. 2) (20).

Clockwise flutter (uncommon form)

In contrast, in the uncommon form of the right atrial CTI-dependent flutter the F wave pattern on the 12-lead ECG is less specific and variable. Figure 3 shows another episode of right atrial CTI-dependent flutter in the same patient of Figures 1 and 2 during a RF ablation procedure (6). The activation sequence of this “reverse” version of flutter proceeds superiorly over the right atrial anterior and lateral walls and inferiorly over the right atrial posterior and septal walls.

Clockwise flutter makes up about 10% of clinical cases and has ECG findings that include positive F waves in the inferior leads II, III, aVF, and negative deflection in V1. During electrophysiological study the diagnosis of common or uncommon form of right atrial CTI-dependent flutter is suggested by observing a counterclockwise or clockwise activation pattern in the right atrium and around the tricuspid valve annulus.

The uncommon form of the right atrial CTI-dependent

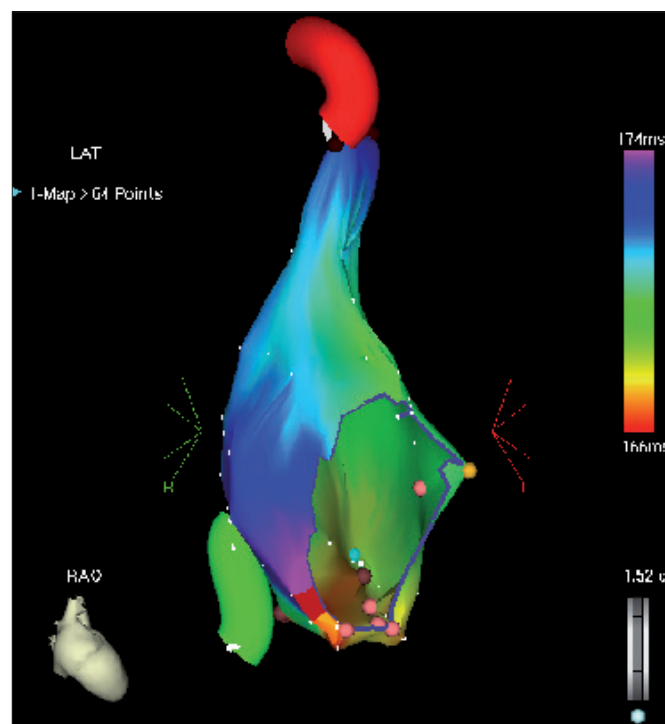


Fig. 1 - Electroanatomical map of right atrium showing the counterclockwise activation during atrial flutter. The activation sequence proceeds from red to purple.

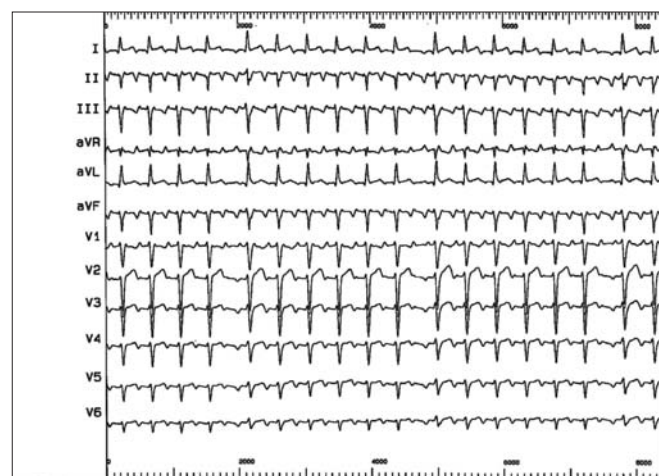

Fig. 2 - 12-lead ECG recorded from a patient with the counterclockwise (CTI)-dependent flutter (common type). Note the typical saw-toothed pattern of inverted F waves in the inferior leads II, III, aVF. Counterclockwise right atrial flutter is also characterized by flat to biphasic F waves in I and aVL, an upright F wave in V1 and an inverted F in V6.

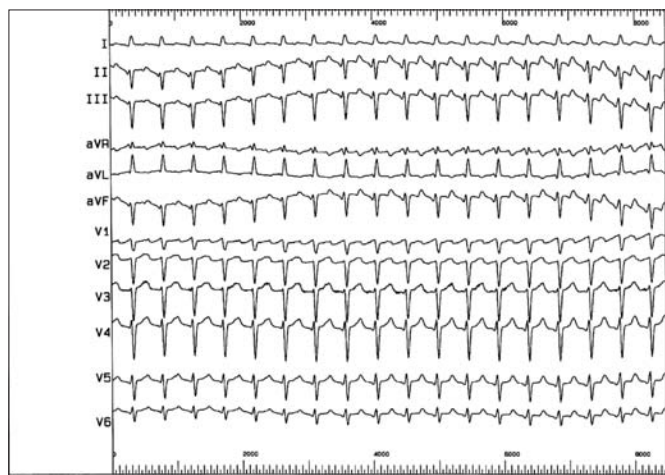


Fig. 3 - 12-lead ECG recorded, during RF ablation procedure, in the same patient in Figures 1 and 2, now with the clockwise (CTI)-dependent form of flutter (uncommon type). The F wave, in this reverse form, may be manifested as the mirror image of the counterclockwise form with positive F waves in the inferior leads II, III, aVF, biphasic in leads I and aVL, negative deflection in V1 and an inverted F in V6.

flutter is diagnosed electrophysiologically by demonstrating clockwise activation sequence around the right atrium and tricuspid valve annulus, with cranial to caudal activation in the interatrial septum and caudal to cranial activation in the right atrial free wall, the opposite sequence of that seen in the counterclockwise right atrial CTI-dependent flutter. Confirmation that the re-entry circuit involves the inferior isthmus requires the demonstration, for the common and uncommon forms, of the classic criteria for entrainment, including concealed entrainment with tachycardia acceleration to the pacing cycle length without a change in the F wave pattern on the surface 12-lead ECG (21, 22).

Lower loop reentry

Lower loop re-entry is a CTI-dependent flutter circuit that localises in the lower right atrium. Several endocavitary studies, using electroanatomic mapping CARTO system, documented that the circuit rotates around the inferior vena cava, either in counterclockwise or clockwise sequence, or around both the inferior vena cava and the tricuspid valve annulus resulting in a figure of eight double loop configuration (23-25). The surface 12-lead ECG findings are similar to those of counterclockwise or clockwise atrial flutter.

RIGHT ATRIAL NON CTI-DEPENDENT FLUTTER

Scar-related flutter and upper loop reentry flutter are macro-re-entrant circuits due to anatomic obstacles located outside the cavo-tricuspid isthmus.

Surgical atrial scars, especially due to cardiac surgery in congenital heart disease, are the anatomopathological substrate of scar related circuits in right atrial non CTI dependent flutter (14, 26-28). Nakagawa et al (28) reported that areas of slow conduction in narrow channels within islands of scar set up reentrant circuits in the right atrial free wall. Radiofrequency catheter ablation of the critical corridors can eliminate the tachycardia.

The upper loop flutter is characterized by a critical circuit confined in the superior portion of the right atrium, and this circuit is non-CTI dependent (26-30). The diagnosis is possible only during an electrophysiological mapping study. The direction of rotation can be either counterclockwise with descending sequence in the free wall anterior to the crista terminalis or clockwise with ascending sequence in the free wall anterior to the crista. The surface 12-lead ECG shows no difference from the ECG in the counterclockwise or clockwise flutter.

LEFT ATRIAL FLUTTER

The incidence of left atrial flutter in an unselected patient population is unknown. A structural heart disease in the left heart is frequently present in patients with left atrial flutter. The surface 12-lead ECG findings of left atrial flutter are often not specific to one particular tachycardia mechanism, making the analysis of atrial flutter based only on ECG problematic. Electrical silent areas are frequently identified in the left atrium by conventional and electroanatomic 3D mapping techniques during left atrial flutter, and similar areas in the posterior and anterior wall of the left atrium have been also found during sinus rhythm. Several studies have demonstrated that in most patients there is a fractionated atrial activation before the onset of stable atrial flutter and it is usual to observe right atrial nonCTI-dependent flutter or left atrial flutter in patients with untreated atrial fibrillation with periodic transition between the two arrhythmias. Frequently patients without structural heart disease and a history suggestive of paroxysmal atrial fibril-

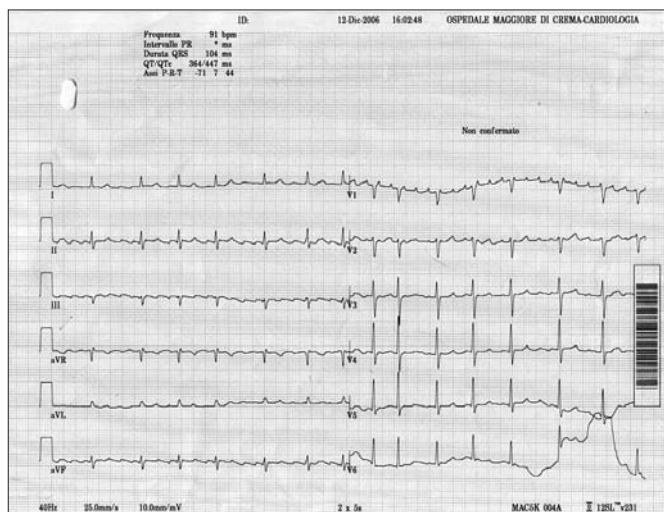


Fig. 4 - Surface ECG showing left atrial flutter in a patient who has undergone pulmonary vein circumferential ablation. There are evident F wave in precordial leads, without clearly detectable F waves in inferior leads.

lation may have evidence of atrial flutter triggering fibrillation episodes. The atrial flutter circuit is postulated to play a critical role in the initiation and maintenance of atrial fibrillation in some patients (31, 32).

The CARTO electroanatomic 3D mapping system provides important information to completely map and characterize left atrial flutter as well as providing precise localization of the ablation catheter and the graphical presentation of the ablation line.

Mitral annulus flutter

This form is sustained by macro-re-entrant circuit in the left atrium that rotates around the mitral annulus either in counterclockwise or clockwise direction, supported by endocardial structures such as the mitral annulus anteriorly and low-voltage areas or scars posteriorly (20, 33-35).

The surface 12-lead ECG findings of mitral annulus flutter present low amplitude flutter waves in the inferior leads II, III, aVF, and positive waves in V1 and V2.

Scar and pulmonary vein-related flutter

The re-entry circuit in this form involves one or more pulmonary veins in the posterior wall of the left atrium,

especially in patients with mitral valve disease and sometimes after RF ablation procedure in the left atrium to cure atrial fibrillation (Fig. 4). These circuits can have multiple loops and are related to regions with low voltage or scar areas. The radiofrequency catheter ablation is complex and requires a 3D electroanatomic mapping approach to demonstrate the circuit and to guide the ablation with several RF applications from a pulmonary vein to mitral annulus or to the opposite pulmonary vein. The surface 12-lead ECG shows low amplitude of the flutter waves in inferior leads with positive wave in lead I.

Left septal flutter

Recently several authors (20, 36, 37) reported a different form of left atrial flutter with circuit rotating around the fossa ovalis in counterclockwise or clockwise sequence.

The critical isthmus is located on the septum between the fossa ovalis and the pulmonary vein or the mitral annulus. The surface 12-lead ECG findings show prominent positive flutter waves only in V1 or V2 and diminished amplitude of atrial waves in the other leads. The use of 3D mapping systems can improve the correct diagnosis of the flutter and may provide precise localization of the circuit to guide the ablation.

ECG AS A GUIDE FOR TREATMENT OF ATRIAL FLUTTER

The ECG classification of atrial flutter may be useful in order to identify the electrophysiological mechanisms of the arrhythmia. In fact, the presence of clearly detectable flutter waves in inferior leads and D1 is highly specific (up to 90%) for CTI-dependent atrial flutter, while in patients with non-CTI-dependent re-entrant circuit the ECG features are less specific (6, 9). Furthermore, a correct interpretation of 12-lead ECG may be useful in order to choose the most appropriate approach for interventional therapy. In fact, patients with CTI-dependent atrial flutter may benefit from linear ablation of the inferior CTI with a purely anatomical approach (12). By contrast, the interventional procedures for the treatment of non-CTI-dependent arrhythmias are much more complex and longer in duration, requiring an extremely accurate mapping of the atria with either en-

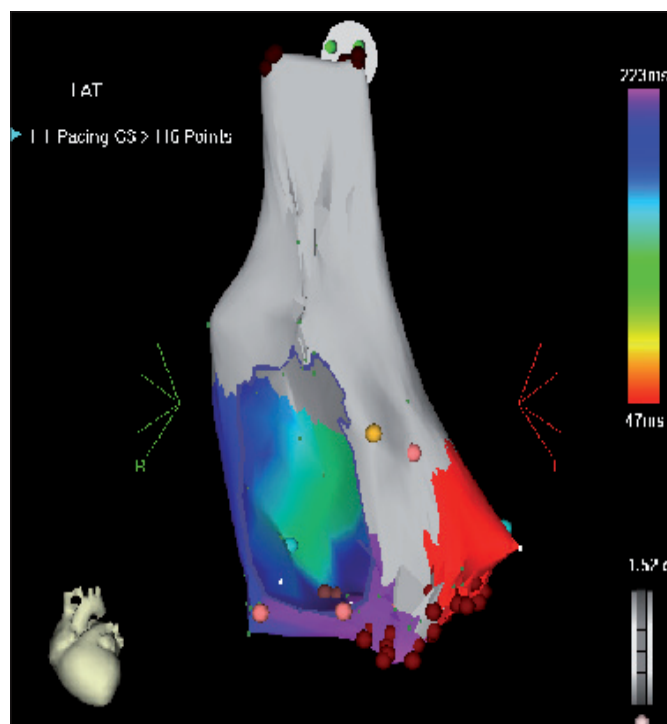


Fig. 5 - Electroanatomical map of right atrium after ablation of the CTI. Red dots represent the line of ablation. Furthermore, in this figure the assessment of conduction block across ablation line is documented (176 ms of delay between the red and purple colours)

training technique, electroanatomical 3D mapping or both, in order to correctly localize the re-entrant circuit and the target site for radiofrequency energy delivery (28,33). Specifically, the electroanatomical 3D mapping with CARTO system makes it possible to obtain information about the anatomical details of cardiac chambers, the direction of wavefront propagation and the voltage amplitude, so detecting the presence of scar areas.

Right atrial CTI-dependent atrial flutter

Radiofrequency catheter ablation of the CTI through a purely anatomical approach is a very effective procedure for treatment of CTI-dependent right atrial flutter. Several studies have reported a procedural success rate of about 80-85%, significantly higher than that obtained with pharmacological antiarrhythmic therapy (38-40). Successful ablation requires complete interruption of the isthmus obtained by a linear lesion from the

inferior vena cava to the inferior side of the tricuspidal ring, with bidirectional conduction block. The conduction block should be assessed at the end of procedure demonstrating a counterclockwise septal to lateral activation when pacing from the proximal coronary sinus, and a clockwise lateral to septal activation when pacing from the low lateral side of the right atrium (Fig. 5) (41). However, newer methods for the assessment of conduction block, including for example looking for double atrial potential along the ablation line or performing pacing protocol during isoproterenol infusion, have reduced the recurrence rate to about 5% (42, 43). Furthermore, even though radiofrequency ablation of CTI has a very high efficacy when performed with conventional techniques, the electro-anatomical mapping with CARTO system may increase the success rate in patients with significant distortion to the right atrial anatomy (eg, after heart transplant or after surgery for congenital heart disease) (44).

Right atrial non CTI-dependent and left atrial flutter

Radiofrequency ablation of non CTI-dependent atrial flutter is generally more difficult than that of CTI-dependent circuits. In these cases it is very important to correctly localize areas of low voltage or conduction block within atrial chambers. These areas may act as anatomical obstacles for macro-re-entrant circuits, which may be better identified by the use of electro-anatomical mapping techniques. The target site of radiofrequency ablation is usually the "critical circuit isthmus", defined as the narrowest part of the macro-re-entrant circuit (28, 33).

The majority of non CTI-dependent atrial flutters are detected in patients who have undergone surgery for congenital heart disease (mainly atrial septal defects), with macro-re-entrant circuits rotating around the atriotomy scars (28). The success rate of radiofrequency ablation reported in this kind of patient is between 50 and 88% (45). Iatrogenic non CTI-dependent atrial flutter has also been detected in patients who underwent pulmonary vein isolation for treatment of atrial fibrillation (Fig. 6). In these cases the macro-re-entrant circuit runs through conducting channels between islands of scars around the pulmonary veins, and targeted ablation of these channels can eliminate the arrhythmia

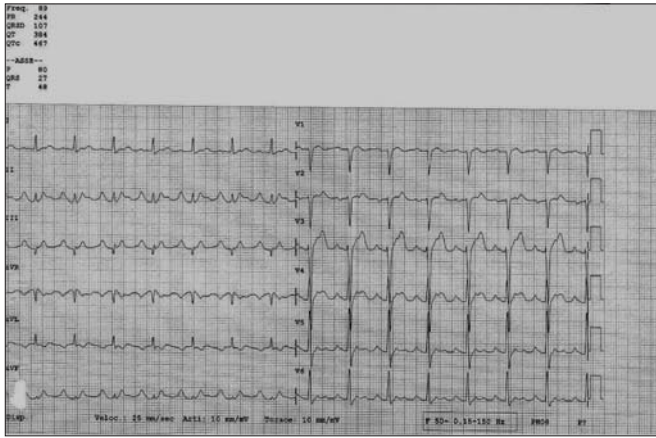


Fig. 6 - 12-lead ECG recorded in a patient who had undergone pulmonary vein ablation for atrial fibrillation. The ECG shows the presence of atrial flutter with positive F waves in inferior and precordial leads.

(Fig.7) (46, 47). Furthermore, Pappone et al (48) reported that a modified circumferential pulmonary vein ablation technique, including additional ablation lines on posterior wall and the mitral isthmus, is associated with a reduced risk of atrial flutter and atrial tachycardia after pulmonary vein ablation (3.9% vs. 10%) (Fig. 8).

CONCLUSIONS

The traditional classification of atrial flutter is based especially on the surface ECG. However, various types of atrial flutter have been described and there has been a considerable amount of confusion in using the old classification. Furthermore, electrophysiological mapping studies and the entrainment pacing technique have aided the definition of the mechanism of arrhythmia with the activation sequence, providing information on the timing of intra-atrial events with respect to the surface ECG, especially for the non CTI-dependent atrial flutter. New developments in endocardial mapping, including the electroanatomical 3D mapping system, have greatly expanded our understanding of the mechanism of arrhythmias, making a new classification necessary. It is obvious that in this new classification the surface ECG does not provide a precise understanding of all atrial flutters. In fact, the electrocardiographic pattern is often the same for different mechanisms of atrial flutter. For example, the surface ECG in upper loop re-entry right

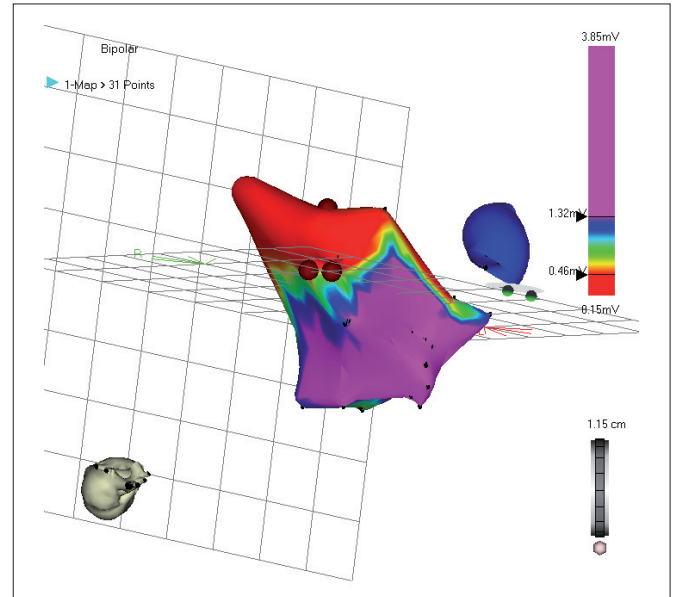


Fig. 7 - Electroanatomical 3D mapping obtained in the same patient in Figure 6, with voltage map of the area surrounding the superior right pulmonary vein. The voltage map shows the presence of a critical isthmus within the previous ablation line. RF energy delivery in this area interrupted the arrhythmia.

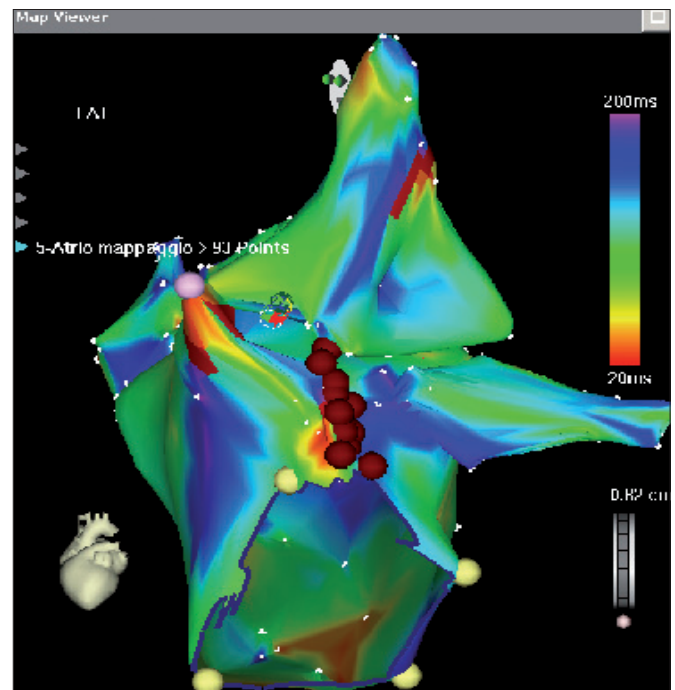


Fig. 8 - Ablation of left atrial isthmus between inferior pulmonary vein and mitral anulus (ablation line in red dots) in a patient with atrial flutter after pulmonary vein circumferential ablation for atrial fibrillation.

atrial flutter is the same as in clockwise or counter-clockwise CTI-dependent atrial flutter and, in left atrial flutter, the electrocardiographic pattern does not show significant modifications according to the different electrophysiological substrates of dysrhythmia. However, as discussed above, ECG can help to guide diagnosis and consequently treatment mainly in CTI-dependent right atrial flutter.

Radiofrequency catheter ablation has an enormous potential for the definitive cure of atrial flutter and, from surface ECG, it may be possible to predict if the flutter is amenable to ablation and the type of approach that may be necessary.

However, further study will be needed in order to more precisely identify correlations between the locations of the different electrophysiological types of re-entrant circuit and the electrocardiographic features.

Address for correspondence:
Dr. Giuseppe Inama
Department of Cardiology
Ospedale Maggiore
Largo U. Dossena, 2
26013 Crema - Italy
g.inama@hcrema.it

REFERENCES

1. Disertori M, Inama G, Vergara G, Furlanello F. Evidence of a reentry circuit in the common type of atrial flutter in man. *Circulation* 1983; 67: 434-40.
2. Waldo AL, Mackall JA, Biblo LA. Mechanisms and medical management of patients with atrial flutter. *Cardiol Clin* 1997; 15: 661-76.
3. Scheinman MM, Yang Y. Atrial flutter: Historical notes-Part 1. *Pacing Clin Electrophysiol* 2004; 27: 379-81.
4. Halligan SC, Gersh BJ, Brown RD Jr, et al. The natural history of lone atrial flutter. *Ann Intern Med* 2004; 140: 265-8.
5. Calkins H, Leon AR, Deam AG, Kalbfleisch SJ, Langberg JJ, Morady F. Catheter ablation of atrial flutter using radiofrequency energy. *Am J Cardiol* 1994; 73: 353-6.
6. Saoudi N, Nair M, Abdelazziz A, et al. Electrocardiographic patterns and results of radiofrequency catheter ablation of clockwise type I atrial flutter. *J Cardiovasc Electrophysiol* 1996; 7: 931-42.
7. Puech P, Latour H, Grolleau R. Le flutter et ses limites. *Arch Mal Coeur* 1970; 63: 116-44.
8. Waldo AL, MacLean WA, Karp RB, Kouchoukos NT, James TN. Entrainment and interruption of atrial flutter with atrial pacing: Studies in man following open heart surgery. *Circulation* 1977; 56: 737-45.
9. Saoudi N, Cosio F, Waldo A, et al. A classification of atrial flutter and regular atrial tachycardia according to electrophysiological mechanisms and anatomical bases; a Statement from a Joint Expert Group from The Working Group of Arrhythmias of the European Society of Cardiology and the North American Society of Pacing and Electrophysiology. *Eur Heart J* 2001; 22: 1162-82.
10. Scheinman MM, Yang Y, Cheng J. Atrial flutter: Part II. Nomenclature. *Pacing Clin Electrophysiol* 2004; 27: 504-6.
11. Kalman JM, Olgin JE, Saxon LA, Fisher WG, Lee RJ, Lesh MD. Activation and entrainment mapping defines the tricuspid annulus as the anterior barrier in typical atrial flutter. *Circulation* 1996; 94: 398-406.
12. Nakagawa H, Lazzara R, Khastgir T, et al. Role of the tricuspid annulus and the eustachian valve/ridge on atrial flutter. Relevance to catheter ablation of the septal isthmus and a new technique for rapid identification of ablation success. *Circulation* 1996; 94: 407-24.
13. Arribas F, Lopez-Gil M, Cosio FG, Nunez A. The upper link of human common atrial flutter circuit: Definition by multiple endocardial recordings during entrainment. *Pacing Clin Electrophysiol* 1997; 20: 2924-9.
14. Kalman JM, Olgin JE, Saxon LA, Lee RJ, Scheinman MM, Lesh MD. Electrocardiographic and electrophysiologic characterization of atypical atrial flutter in man: Use of activation and entrainment mapping and implications for catheter ablation. *J Cardiovasc Electrophysiol*

- 1997; 8: 121-44.
15. Milliez P, Richardson AW, Obioha-Ngwu O, Zimetbaum PJ, Papageorgiou P, Josephson ME. Variable electrocardiographic characteristics of isthmus-dependent atrial flutter. *J Am Coll Cardiol* 2002; 40: 1125-32.
 16. Chan DP, Van Hare GF, Mackall JA, Carlson MM, Waldo AL. Importance of atrial flutter isthmus in postoperative intra-atrial reentrant tachycardia. *Circulation* 2000; 102: 1283-9.
 17. Tsuchiya T, Okumura K, Tabuchi T, Iwasa A, Yasue H, Yamabe T. The upper turnover site in the reentry circuit of common atrial flutter. *Am J Cardiol* 1996; 78: 1439-42.
 18. Inama G, Gramegna L, Pessano P, Vergara G, Disertori M. Una esperienza italiana sull'ablazione transcatetere con radiofrequenza nel flutter atriale tipo I^o: risultati e follow-up. *G Ital Cardiol* 1998; 28: 666-77.
 19. Inama G, Gramegna L, Pessano P, Disertori M. Long-term results in radiofrequency catheter ablation of type 1 atrial flutter. *G Ital Cardiol* 1998; 28 (suppl 1): 371-4.
 20. Bochoeyer A, Yang Y, Cheng J, et al. Surface electrocardiographic characteristics of right and left atrial flutter. *Circulation* 2003; 108: 60-6.
 21. Frame LH. Double reentry: A mechanism of overdrive acceleration of re-entrant tachycardias. *Circulation* 1987; 76 (Suppl. IV): 430.
 22. Frame LH, Rhee EK, Bernstein RC, Fei H. Reversal of reentry and acceleration due to double-wave reentry: Two mechanisms for failure to terminate tachycardias by rapid pacing. *J Am Coll Cardiol* 1996; 28: 137-45.
 23. Cheng J, Cabeen JWR, Scheinman MM. Right atrial flutter due to lower loop reentry: Mechanisms and anatomic substrates. *Circulation* 1999; 99: 1700-5.
 24. Zhang S, Younis G, Hariharan R, et al. Lower loop reentry as a mechanism of clockwise right atrial flutter. *Circulation* 2004; 109: 1630-5.
 25. Cheng J, Scheinman MM. Acceleration of typical atrial flutter due to double-wave reentry induced by programmed electrical stimulation. *Circulation* 1998; 97: 1589-96.
 26. Yang Y, Cheng J, Bochoeyer A, et al. Atypical right atrial flutter patterns. *Circulation* 2001; 103: 3092-8.
 27. Kall J, Rubenstein DS, Kopp DE, et al. Atypical atrial flutter originating in the right atrial free wall. *Circulation* 2000; 101: 270-9.
 28. Nakagawa H, Shah N, Matsudaira K, et al. Characterization of reentrant circuit in macroreentrant right atrial tachycardia after surgical repair of congenital heart disease: Isolated channels between scars allow "focal" ablation. *Circulation* 2001; 103: 699-709.
 29. Feld GK, Shahandeh-Rad F. Activation patterns in experimental canine atrial flutter produced by right atrial crush injury. *J Am Coll Cardiol* 1992; 20: 441-51.
 30. Tai CT, Huang JL, Lin YK, et al. Noncontact three-dimensional mapping and ablation of upper loop re-entry originating in the right atrium. *J Am Coll Cardiol* 2002; 40: 746-53.
 31. Leloirier P, Humphries KH, Krahn A, et al. Prognostic differences between atrial fibrillation and atrial flutter. *Am J Cardiol* 2004; 93: 647-9.
 32. Vidaillet H, Granada JF, Chyou PH, et al. A population based study of mortality among patients with atrial fibrillation or flutter. *Am J Med* 2002; 113: 365-70.
 33. Jais P, Shah DC, Haissaguerre M, et al. Mapping and ablation of left atrial flutters. *Circulation* 2000; 101: 2928-34.
 34. Ouyang F, Ernst S, Vogtmann T, et al. Characterization of reentrant circuits in left atrial macroreentrant tachycardia: Critical isthmus block can prevent atrial tachycardia recurrence. *Circulation* 2002; 105: 1934-42.
 35. Cosio FG, Martin-Penato A, Pastor A, Nunez A, Goicolea A. Atypical flutter: A review. *Pacing Clin Electrophysiol* 2003; 26: 2157-69.
 36. Olgin JE, Jayachandran JV, Engesstein E, Zipes DP. Atrial macroreentry involving the myocardium of the coronary sinus: A unique mechanism for atypical flutter. *J Cardiovasc Electrophysiol* 1998; 9: 1094-9.
 37. Marrouche NF, Natale A, Wazni OM, et al. Left septal atrial flutter: Electrophysiology, anatomy, and results of ablation. *Circulation* 2004; 109: 2440-7.
 38. Kirkorian G, Moncada E, Chevalier P, et al. Radiofrequency ablation of atrial flutter. Efficacy of an anatomically guided approach. *Circulation* 1994; 90: 2804-14.
 39. Scheinman MM, Huang S. The 1998 NASPE prospective catheter ablation registry. *Pacing Clin Electrophysiol* 2000; 23: 1020-8.
 40. Natale A, Newby KH, Pisano E, et al. Prospective randomized comparison of antiarrhythmic therapy versus first-line radiofrequency ablation in patients with atrial flutter. *J Am Coll Cardiol* 2000; 35: 1898-904.
 41. Poty H, Saoui N, Nair M, et al. Radiofrequency catheter ablation of atrial flutter. Further insights into the various type of isthmus block: Application to ablation during sinus rhythm. *Circulation* 1996; 94: 3204-13.
 42. Anselme F, Savoure A, Cribier A, Saoudi N. Catheter ablation of typical atrial flutter: A randomized comparison of 2 methods for determining complete bidirectional isthmus block. *Circulation* 2001; 103: 1434-9.
 43. Nabar A, Rodriguez LM, Timmermans C, Smeets JL, Wellens HJ. Isoproterenol to evaluate resumption of conduction after right atrial isthmus ablation in type I atrial flutter. *Circulation* 1999; 99: 3286-91.
 44. Kottkamp H, Hugl B, Krauss B, et al. Electromagnetic versus fluoroscopic mapping of the inferior isthmus for ablation of typical atrial flutter. A prospective randomized study. *Circulation* 2000; 102: 2082-6.

45. Blomstrom-Lundqvist C, Scheinman MM, Aliot EM, et al. ACC/AHA/ESC guidelines for the management of patients with supraventricular arrhythmias—executive summary. A report of the American College of Cardiology/American Heart Association task force on practice guidelines and the European Society of Cardiology committee for practice guidelines (writing committee to develop guidelines for the management of patients with supraventricular arrhythmias) developed in collaboration with NASPE-Heart Rhythm Society. *J Am Coll Cardiol* 2003; 42: 1493-531.
46. Oral H, Knight BP, Morady F. Left atrial flutter after segmental ostial radiofrequency catheter ablation for pulmonary vein isolation. *Pacing Clin Electrophysiol* 2003; 26: 1417-9.
47. Villacastin J, Perez-Castellano N, Moreno J, Gonzalez R. Left atrial flutter after radiofrequency catheter ablation of focal atrial fibrillation. *J Cardiovasc Electrophysiol* 2003; 14: 417-21.
48. Pappone C, Manguso F, Vicedomini G, et al. Prevention of iatrogenic atrial tachycardia after ablation of atrial fibrillation: A prospective randomized study comparing circumferential pulmonary vein ablation with a modified approach. *Circulation* 2004; 110: 3036-42.