



Treatment of Severe Ankle and Hindfoot Deformity: Technique Using Femoral Head Allograft for Tibiototalcaneal Fusion Using a Cup-and-Cone Reamer

Victor Hoang, D.O., Taylor Anthony, B.S., Shivali Gupta, D.O., Ryan Chang, Holman Chan, M.D., and Troy Watson, M.D.

Abstract: Limb shortening due to structural bone loss in tibiototalcaneal arthrodesis is a concern that can negatively impact the patient's gait and weight-bearing. To aid in preventing the risk of limb shortening, the use of a femoral head allograft and intramedullary nail in tibiototalcaneal arthrodesis has been shown to successfully preserve limb length in patients with structural bone deficits. We present our technique using a femoral head allograft with a cup-and-cone reamer for the treatment of severe ankle and hindfoot deformity.

Malalignment of the ankle and hindfoot is a common pathology in patients with end-stage ankle arthritis.¹ If conservative treatments fail to provide relief and the success of joint-preserving techniques is unlikely, total ankle arthroplasty or ankle arthrodesis become the standard treatment to improve quality of life.² Limb shortening due to structural bone loss in tibiototalcaneal (TTC) arthrodesis is a concern that can negatively impact the patient's gait and weight-bearing.³ To aid in preventing the risk of limb shortening, the use of a femoral head allograft and intramedullary nail in TTC arthrodesis has been shown

to successfully preserve limb length in patients with structural bone deficits.⁴

Indications

The indications for using a femoral head allograft for TTC fusion include large talar body defects and severe fixed deformity of the ankle and hindfoot. Patients who have not responded to nonoperative and operative treatments including a failed previous TTC fusion are

From the Valley Hospital Medical Center, Las Vegas, Nevada (V.H., S.G., T.W.); Touro University Nevada College of Osteopathic Medicine, Henderson, Nevada (T.A.); University of San Diego, San Diego, California (R.C.); Nevada Orthopedic & Spine Center, Henderson, Nevada (H.C.); Desert Orthopaedic Center, Las Vegas, Nevada (T.W.); and The Foot & Ankle Institute, Henderson, Nevada (T.W.), U.S.A.

The authors report that they have no conflicts of interest in the authorship and publication of this article. Full ICMJE author disclosure forms are available for this article online, as [supplementary material](#).

Received October 28, 2020; accepted January 11, 2021.

Address correspondence to Victor Hoang, D.O., Valley Hospital Medical Center, 620 Shadow Lane, Las Vegas, NV 89106. E-mail: Hoangorthopedics@gmail.com

© 2021 Published by Elsevier on behalf of the Arthroscopy Association of North America. This is an open access article under the CC BY-NC-ND license (<http://creativecommons.org/licenses/by-nc-nd/4.0/>).

2212-6287/201792

<https://doi.org/10.1016/j.eats.2021.01.012>

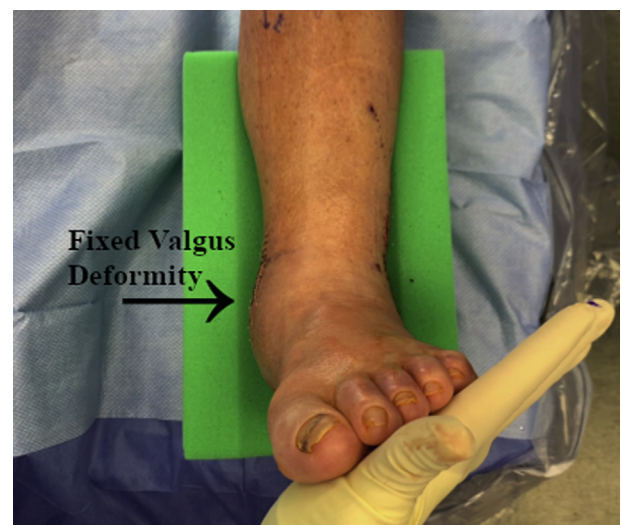

Fig 1. Preoperative image from an anterior viewpoint of the left foot and ankle demonstrating an extreme fixed valgus deformity through the ankle joint.

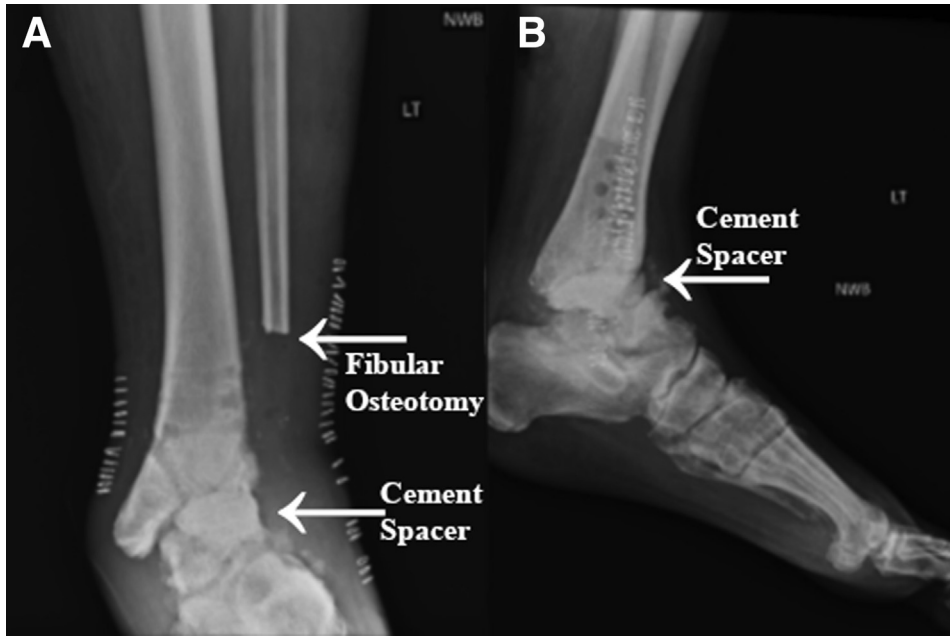


Fig 2. (A, B) Preoperative antero posterior and lateral non-weight-bearing radiographic views of the left ankle following a previous procedure consisting of removal of hardware, bony exostectomy, fibular osteotomy of the distal portion of the fibula with irrigation and debridement, biopsy, culture, and placement of a cement spacer.

considered candidates for TTC fusion with a femoral head allograft.

Preoperative Patient Evaluation and Imaging

Preoperative examination should include findings of a fixed deformity through the ankle joint (Fig 1) with confirmation from obtaining preoperative radiographs of the ankle. Additional findings including large talar body defects or an incomplete deformity correction from a previous procedure may be observed on these radiographs (Fig 2 A and B).

Surgical Technique (With Video Illustration)

Materials

Materials for performing a TTC fusion with femoral head allograft include Ace Depuy acetabular reamers (Warsaw, IN), a Zimmer Biomet Phoenix nail with screw fixation (Warsaw, IN), 2 Arthrex 4.5-mm cannulated screws (Naples, FL), femoral head allograft, and the use of intraoperative fluoroscopy.

Patient Positioning

The patient is positioned in a partial lateral decubitus position on the operating table. A tourniquet is placed on the thigh of the operative side. The leg is prepped

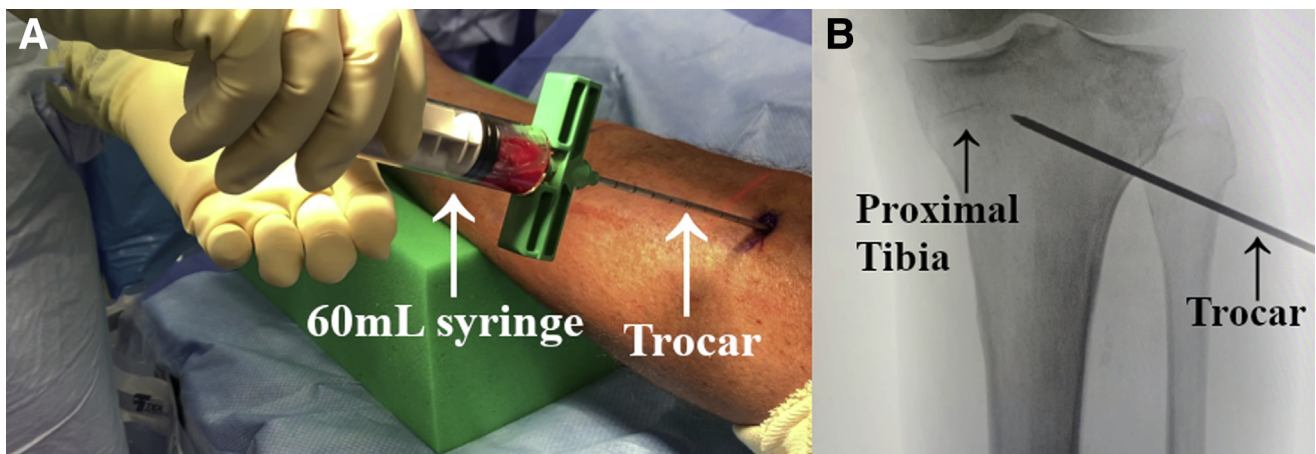


Fig 3. (A) Image of the lateral left lower leg with the patient in a partial lateral decubitus position. (B) Fluoroscopic anteroposterior view of the left proximal tibia. Before the tourniquet is inflated, a bone marrow aspirate is performed with insertion of the trocar through the anterolateral aspect of the left proximal tibial metaphysis.

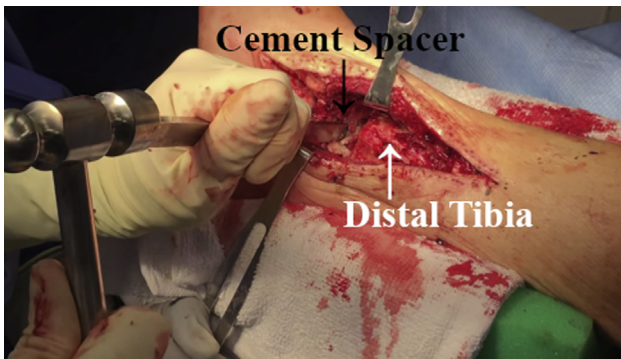


Fig 4. Intraoperative image from a lateral viewpoint of the left distal tibia with the patient positioned in a partial lateral decubitus position. A fibular osteotomy is typically performed at this step to gain access to the ankle joint, but the distal fibula was resected and a cement spacer was placed into the ankle joint in a previous procedure. Joint preparation is completed with an osteotome, mallet, and rongeur to remove the talus in piecemeal fashion.

and draped in sterile fashion. Before the tourniquet is inflated, bone marrow aspirate is obtained from the proximal tibia by using a large trocar that is prepared in standard fashion. The trocar is introduced into the proximal metaphyseal tibial bone and 60 mL of bone marrow is extracted into 2 syringes (Fig 3 A and B). The bone marrow aspirate is then centrifuged to create 6 mL of bone marrow aspirate concentrate. Subsequently, the operative extremity is inflated to 300 mm Hg.

Incision and Approach

A transfibular approach is made along the lateral aspect of the ankle. Once dissection is completed across the skin and subcutaneous tissues, fibular resection is performed. Next, the talus is removed from the ankle in piecemeal fashion using an osteotome and mallet under direct fluoroscopic imaging (Fig 4). Intraoperative fluoroscopy allows direct visualization of the talar body

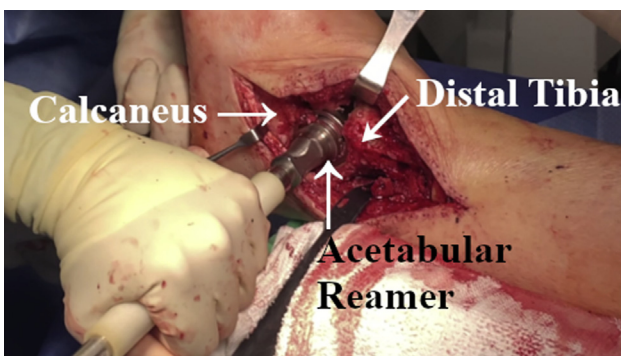


Fig 5. Intraoperative image from a lateral viewpoint of left distal tibia and calcaneus with the patient positioned in a partial lateral decubitus position. Acetabular reamers are used to concentrically ream between the distal tibia and calcaneus for acceptance of the femoral head allograft.




Fig 6. Image of femoral head allograft with femoral head reamer. The femoral head is contoured line to line with corresponding femoral head resurfacing reamers to equate the size of the acetabular reamer used to prepare the distal tibia and calcaneus.

and neck, ensuring a 3-dimensional correction of deformity. Once the talus is adequately removed and confirmed under fluoroscopic imaging, attention is turned to reaming of the distal tibia and calcaneus. The Ace DePuy acetabular reamers are used to concentrically ream the distal tibia and calcaneus. Initial reaming is carried out using a 34-mm acetabular reamer, which

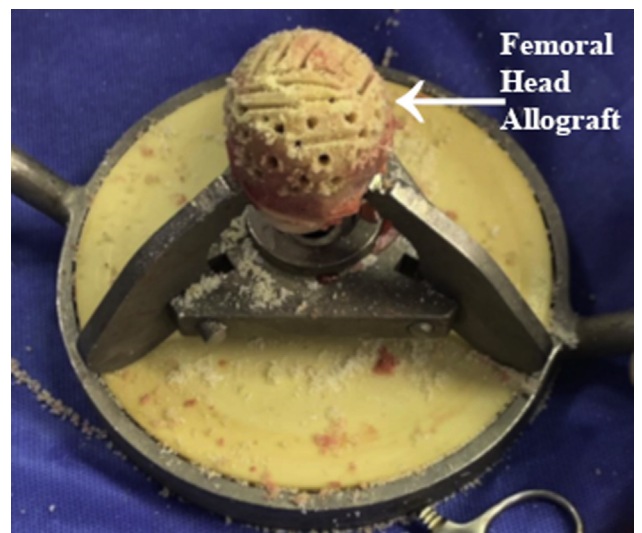

Fig 7. Image of prepared femoral head allograft. Following reaming and resurfacing of the femoral head allograft, multiple fenestrations are created with a large diameter guidewire and 5-mm round burr to create golf ball dimpling for increased surface area of the allograft. Hatches also are created with an osteotome and mallet.

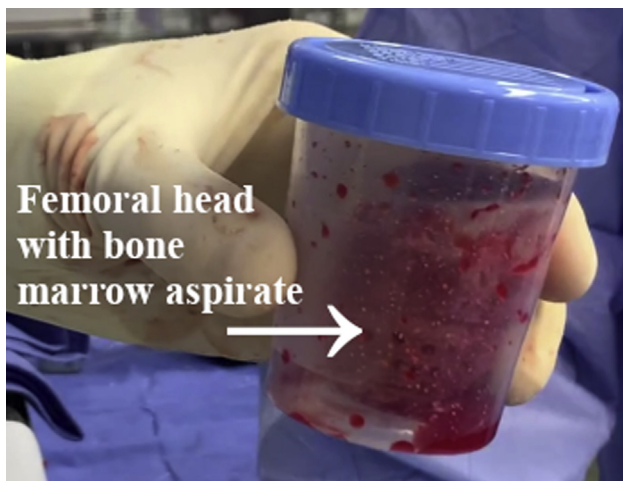

Fig 8. Image of prepared femoral head allograft placed in container with bone marrow aspirate.

is placed concentrically between the distal tibia and calcaneus (Fig 5). Reaming is completed with a 39-mm acetabular reamer, creating a cancellous concentric circle to accept the femoral head allograft (Video 1). Once reaming is complete, the tibial and calcaneal bone graft from the reamers is retrieved. A large Infuse is used to create Infuse rolls with the autograft.

Preparation of the Femoral Head Allograft

The femoral head is prepared in standard fashion to go with the previously reamed 39-mm acetabular reamers at the level of the ankle and subtalar joints. The femoral head is placed in device and reamed line-to-line to equate with the size of the 39-mm acetabular reamer (Fig 6). Once the femoral head allograft is adequately sized, golf ball dimples are created into the femoral head allograft using a large diameter guidewire (Fig 7). Subsequently, the femoral head allograft is soaked in the bone marrow aspirate (Fig 8).

Preparation of the Ankle Joint

The ankle is copiously irrigated and debrided using pulse lavage and chlorhexidine solution. Fenestrations are created into the tibia and calcaneus using the large diameter guide wire (Fig 9 A and B).

Allograft and Tibiocalcaneal Nail Placement

The femoral head allograft is placed into the previously prepared ankle joint space (Fig 10A). Placement of the femoral head allograft is confirmed under direct fluoroscopic visualization (Fig 10B). Next, a guidewire is introduced into the calcaneus and subsequently advanced into the allograft and tibia under direct fluoroscopic guidance (Fig 11 A and B). After placement of the guidewire is confirmed radiographically, the guidewire is overdrilled and reamed to a 12-mm diameter. Subsequently, an 11 × 180-mm nail is affixed to the appropriate jig and advanced across the calcaneus, femoral head allograft, and tibia (Fig 12 A and B). The previously prepared Infuse sponges and autograft are placed proximal, distal and medial to the implant (Fig 13). The nail is then manually compressed. Next, 2 screws are placed proximally, one of which is placed in dynamic configuration and the other in static. Subsequently, a screw is placed into the graft (Fig 14). An additional screw is placed into the calcaneus from the lateral to medial aspect of the calcaneus. The posterior-to-anterior screw is advanced through the calcaneus into the cuboid (Fig 15 A and B).

Lastly, two 4.5-mm cannulated screws are advanced and compressed through the talar head into the femoral head allograft (Fig 16 A and B, Table 1). Remaining bone graft is placed across the talar head and femoral head allograft interface. The wound is then irrigated and the subcutaneous and skin layers are closed. Final C-arm images, including a Harris heel view, are performed to demonstrate excellent alignment of the tibia, femoral head allograft, and calcaneus.

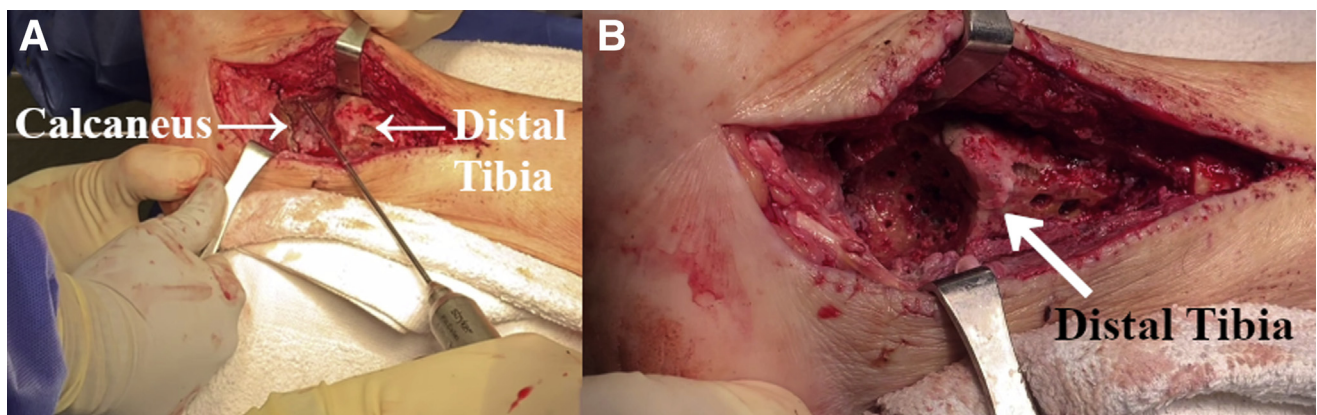


Fig 9. (A, B) Intraoperative images from a lateral viewpoint of the left distal tibia and calcaneus. The patient is positioned in a partial lateral decubitus position. Further joint preparation is completed with a large diameter wire and high-speed burr to create fenestrations and golf ball dimpling in the calcaneus and distal tibia for acceptance the femoral head allograft.

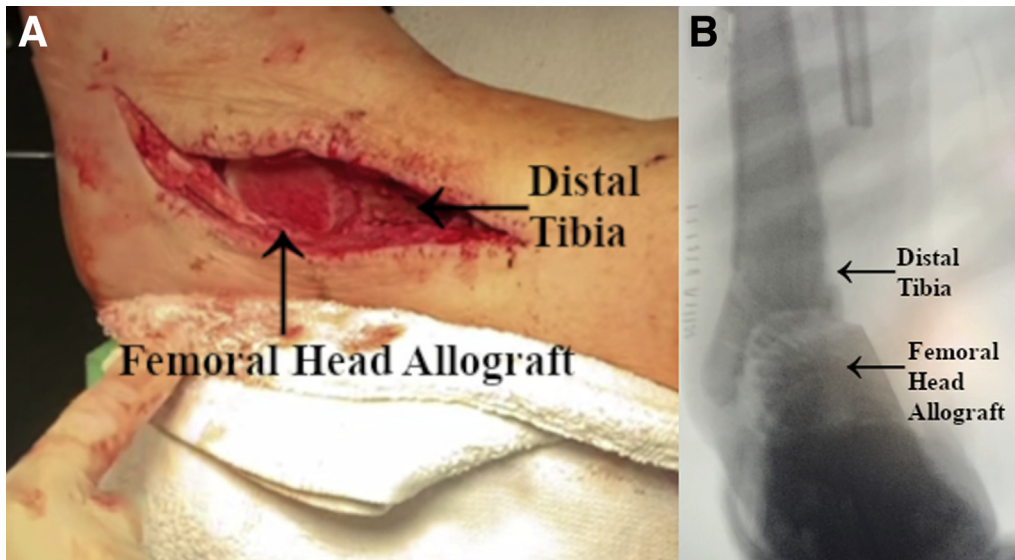


Fig 10. (A) Intraoperative image from a lateral viewpoint of the left distal tibia with femoral head allograft. (B) Fluoroscopic anteroposterior view of the left ankle. The patient is positioned in a partial lateral decubitus position. The femoral head allograft is impacted with a mallet to ensure it has been concentrically reduced. The foot is placed in neutral dorsiflexion with slight valgus alignment. The femoral head allograft should line up with the posterior aspects of the tibia and calcaneus.

Postoperative Rehabilitation

Postoperative rehabilitation consists of casting to increase chances of successful union with non-weight-bearing for 10 to 12 weeks following the procedure to assess healing (Fig 17 A-C). The use of a knee scooter is used in the interim. Once walking, the patient is transitioned to a Cam walker boot or CROW walker boot for an additional 2 to 3 months.

Discussion

The necessity for correcting severe ankle and hindfoot deformity is essential in patients requiring operative intervention. If left uncorrected, a progressive deformity can increase the weight-bearing stress on surrounding

joints, which can lead to subtalar or talonavicular arthritis.⁵ Although recent studies have demonstrated otherwise, severe coronal plane ankle deformities greater than 15° have historically been a contraindication for total ankle arthroplasty due to the recurrence of deformity, increased risk of complications, and poor outcomes.⁶⁻¹⁰ TTC arthrodesis often serves as the only option to provide the patient with a stable and painless ankle and hindfoot, with the only other alternative being transtibial amputation in some cases.^{11,12} Union rates for standard TTC arthrodesis have historically ranged from 50% to 86.7% with complication rates as high as 55.7% and revision arthrodesis being performed in 3% of the cases.¹²⁻¹⁵ The use of a femoral head

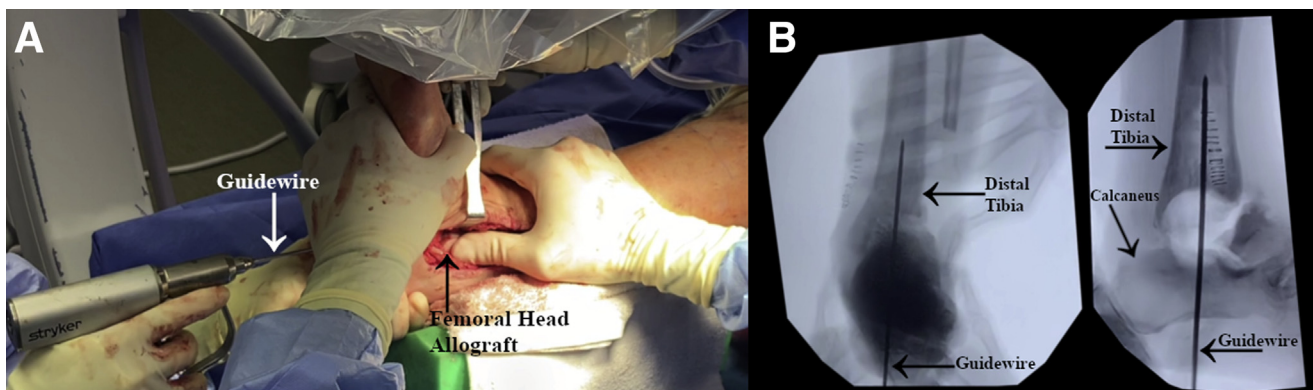


Fig 11. (A) Intraoperative image from an inferolateral viewpoint of the left foot and ankle. (B) Anteroposterior and lateral fluoroscopic views of the left ankle. The patient is positioned in a partial lateral decubitus position. Before intramedullary nail insertion, a guidewire is inserted into the calcaneus and subsequently advanced into the allograft and tibia under direct fluoroscopic guidance.

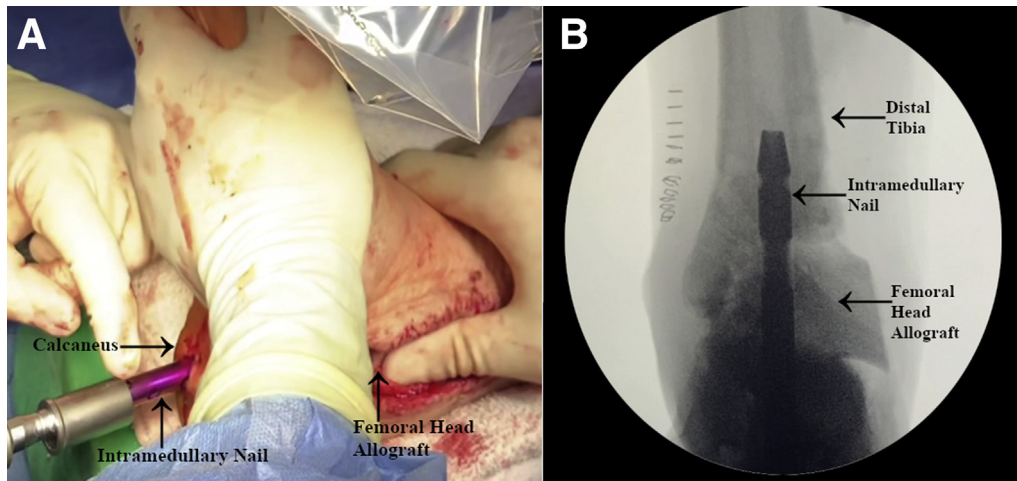


Fig 12. (A) Intraoperative image from an inferolateral viewpoint of the left foot and ankle. (B) Anteroposterior fluoroscopic view of the left ankle. The patient is positioned in a partial lateral decubitus position. Following guidewire insertion, reaming to the appropriate diameter nail is completed and the intramedullary nail is advanced across the calcaneus, femoral head allograft and distal tibia under direct fluoroscopic guidance.

allograft for TTC arthrodesis has recently been reported to achieve a 75% successful arthrodesis rate and a complication rate of 29%. The same study also suggests that successful patient outcomes are possible without complete radiographic fusion.¹⁶

Using a femoral head allograft has previously been noted to be difficult to maintain allograft position during placement of the intramedullary nail in TTC arthrodesis. The “cup-and-cone” reamer technique described by Cuttica and Hyer³ provides a stable construct for alignment and placement of the intramedullary nail by creating a concave surface of the distal tibia and remaining

talus or calcaneus with an acetabular reamer. This technique allows for the convex femoral head allograft to be placed with maximal bone-to-bone surface contact to achieve fusion. Using an allograft also presents with decreased donor-site morbidity and time of surgery when compared with using an autogenous iliac crest bone graft for TTC arthrodesis.³ Femoral head allografts have been shown to correct tibiotalar and hindfoot deformity

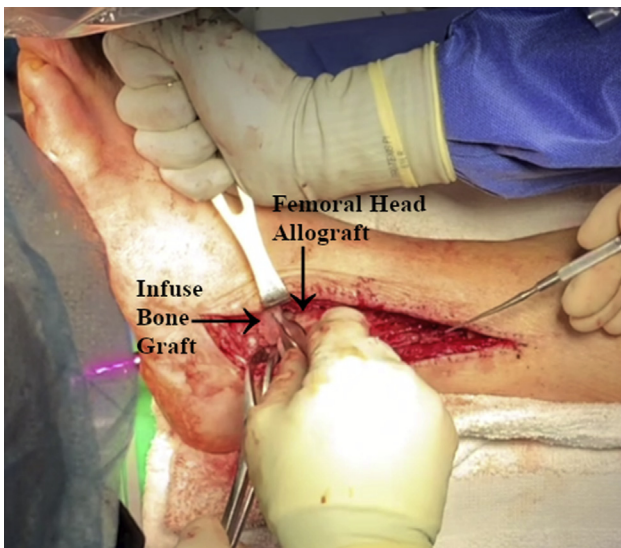


Fig 13. Intraoperative image from a lateral viewpoint left foot and ankle. The patient is positioned in a partial lateral decubitus position. Infuse bone graft is inserted proximal, distal, and medial to the femoral head allograft to enhance fusion potential.

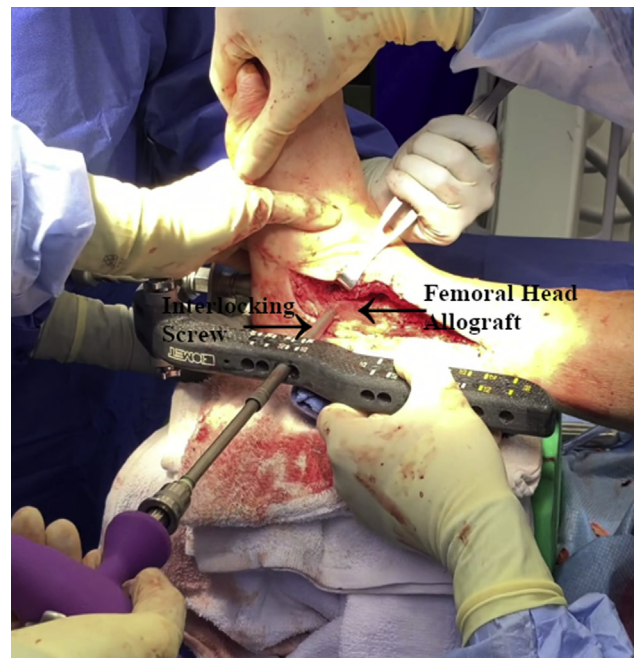


Fig 14. Intraoperative image from a lateral viewpoint of the left foot and ankle. The patient is positioned in a partial lateral decubitus position. An interlocking screw is placed directly into the femoral head allograft. Two more screws are placed into the distal third of the tibia.

Fig 15. (A) Intraoperative image from an inferolateral viewpoint of the left foot and ankle. (B) Lateral fluoroscopic view of the left ankle. The patient is positioned in a partial lateral decubitus position. Further screw placement is inserted posterior to anterior through the calcaneus and into the cuboid.

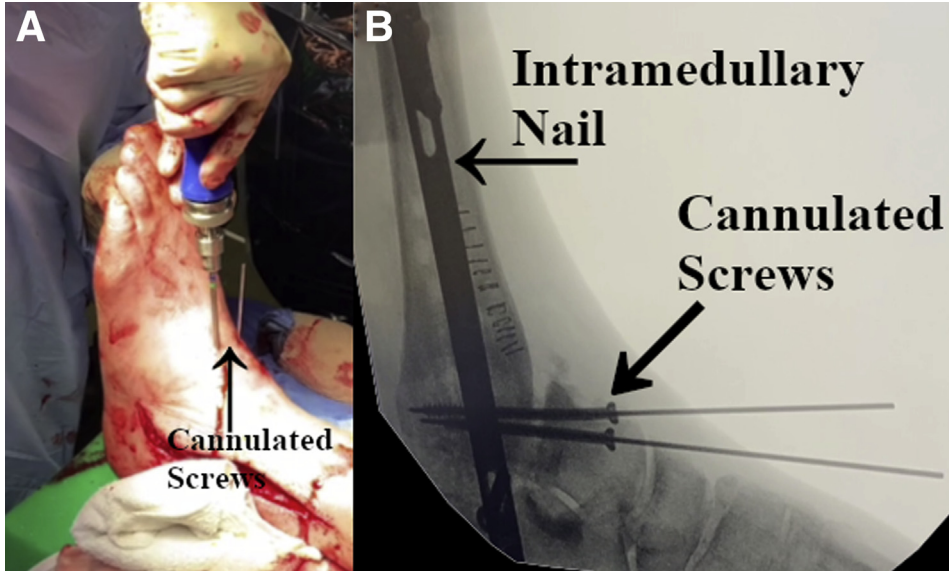
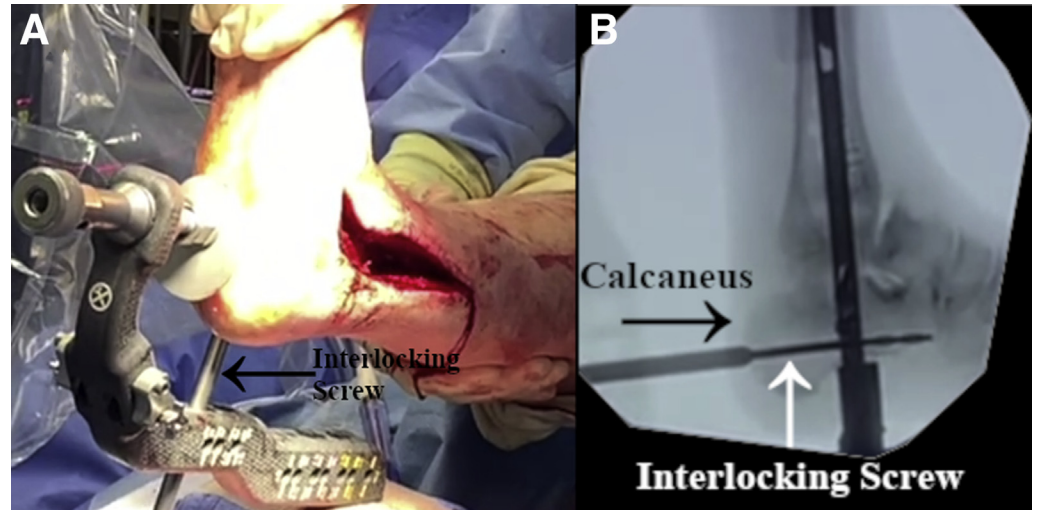


Fig 16. (A) Intraoperative image from a lateral viewpoint of the left foot and ankle. (B) Lateral fluoroscopic view of the left ankle. The patient is positioned in a partial lateral decubitus position. Two 4.5-mm cannulated screws are advanced through the talar head and neck to gain further compression of the femoral head allograft.

Table 1. Pearls and Pitfalls

Pearls	Pitfalls
Biopsy and culture the ankle before definitive fusion.	Failure to identify and ratify infection may cause catastrophic failure.
The femoral head allograft and ankle joint should be prepared line-to-line with the same size reamer.	Larger femoral head allograft may cause difficulty with placing and positioning in the prepared joint.
Joint preparation of the distal tibia and calcaneus should be performed with concentric reaming.	Eccentric reaming may lead to difficulty in placing the femoral head allograft and positioning for the TTC nail.
Obtain cancellous bone autograft and insert superiorly and inferiorly to the femoral head allograft to aid in TTC fusion.	Pseudoarthrosis may require revision or cause hardware failure.
Additional compression of the allograft can be achieved by applying additional fixation through the talar head and neck with 2 cannulated screws.	Less compression of the femoral head allograft may lead to pseudoarthrosis.

TTC, tibiototalocalcaneal.

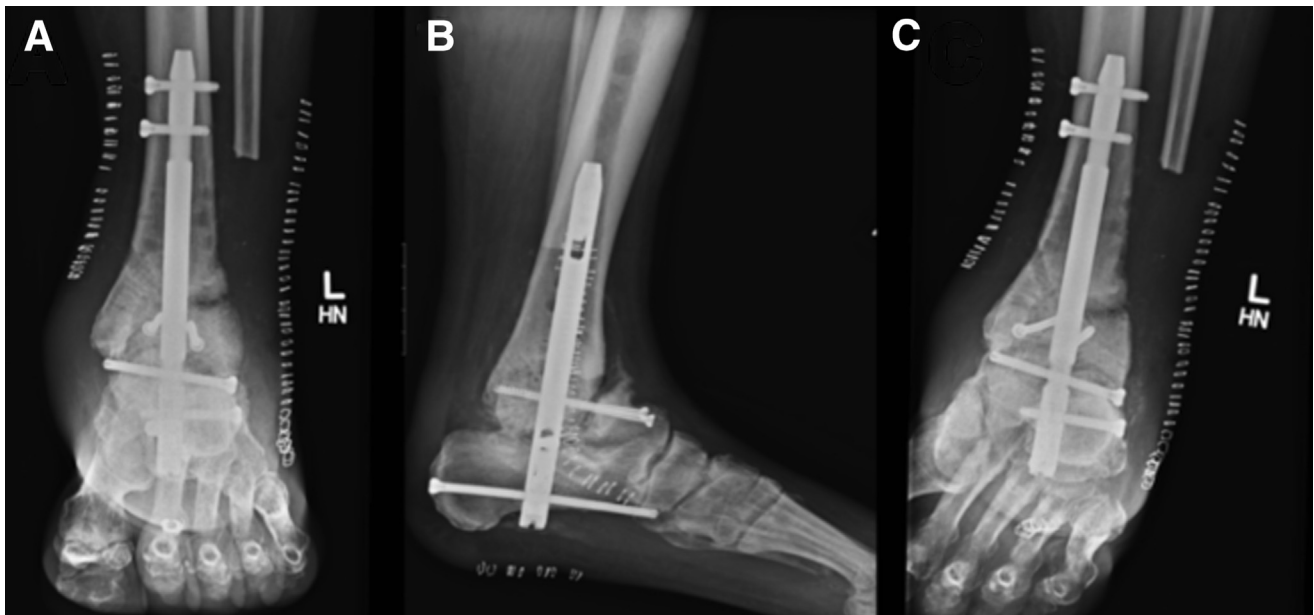


Fig 17. (A, B, C) Postoperative anteroposterior, lateral, and mortise non-weight-bearing radiographic views of the left ankle following a tibiototalcalcaneal arthrodesis with femoral head allograft and intramedullary nail.

without graft resorption or subsidence.¹⁷ There is also supporting evidence for preserving limb length with a reasonable fusion rate for salvage of failed total ankle arthroplasty.¹⁸ Fusion rates in correcting valgus and varus tibiotalar deformities with a femoral head allograft have been comparable with standard ankle fusion rates in previous literature.¹⁹ Although long-term and patient-reported outcomes have not been noted, a recent study reports that using a 3-dimensional custom metal sphere was shown to have a significantly greater fusion rate with a lower graft resorption rate when compared with femoral head allografts in TTC fusion.²⁰ For cases with large structural bone loss, the cup-and-cone technique previously described serves as a promising procedure to preserve limb length, correct ankle or hindfoot deformities, and achieve fusion in patients undergoing TTC arthrodesis.³

References

1. Barg A, Pagenstert GI, Leumann AG, Müller AM, Henninger HB, Valderrabano V. Treatment of the arthritic valgus ankle. *Foot Ankle Clin* 2012;17:647-663.
2. Krause FG, Schmid T. Ankle arthrodesis versus total ankle replacement: How do I decide? *Foot Ankle Clin* 2012;17:529-543.
3. Cuttica DJ, Hyer CF. Femoral head allograft for tibiototalcalcaneal fusion using a cup and cone reamer technique. *J Foot Ankle Surg* 2011;50:126-129.
4. Bussewitz B, DeVries JG, Dujela M, McAlister JE, Hyer CF, Berlet GC. Retrograde intramedullary nail with femoral head allograft for large deficit tibiototalcalcaneal arthrodesis. *Foot Ankle Int* 2014;35:706-711.
5. Thordarson DB. Fusion in posttraumatic foot and ankle reconstruction. *J Am Acad Orthop Surg* 2004;12:322-333.
6. Demetracopoulos CA, Cody EA, Adams SB, DeOrto JK, Nunley JA, Easley ME. Outcomes of total ankle arthroplasty in moderate and severe valgus deformity. *Foot Ankle Spec* 2019;12:238-245.
7. Doets HC, Brand R, Nelissen RGHH. Total ankle arthroplasty in inflammatory joint disease with use of two mobile-bearing designs. *J Bone Joint Surg Am* 2006;88:1272-1284.
8. Haskell A, Mann RA. Ankle arthroplasty with preoperative coronal plane deformity: Short-term results. *Clin Orthop Relat Res* 2004;424:98-103.
9. Lee G-W, Lee K-B. Outcomes of total ankle arthroplasty in ankles with >20° of coronal plane deformity. *J Bone Joint Surg Am* 2019;101:2203-2211.
10. Wood PLR, Prem H, Sutton C. Total ankle replacement: Medium-term results in 200 Scandinavian total ankle replacements. *J Bone Joint Surg Br* 2008;90:605-609.
11. Asomugha EU, Den Hartog BD, Junko JT, Alexander IJ. Tibiototalcalcaneal fusion for severe deformity and bone loss. *J Am Acad Orthop Surg* 2016;24:125-134.
12. Steele JR, Lazarides AL, DeOrto JK. Tibiototalcalcaneal arthrodesis using a novel retrograde intramedullary nail. *Foot Ankle Spec* 2019 Oct 23; 1938640019883138.
13. Jehan S, Shakeel M, Bing AJF, Hill SO. The success of tibiototalcalcaneal arthrodesis with intramedullary nailing—a systematic review of the literature. *Acta Orthop Belg* 2011;77:644-651.
14. Jeng CL, Campbell JT, Tang EY, Cerrato RA, Myerson MS. Tibiototalcalcaneal arthrodesis with bulk femoral head allograft for salvage of large defects in the ankle. *Foot Ankle Int* 2013;34:1256-1266.
15. Rammelt S, Pyrc J, Agren P-H, et al. Tibiototalcalcaneal fusion using the hindfoot arthrodesis nail: A multicenter study. *Foot Ankle Int* 2013;34:1245-1255.
16. Rogero R, Tsai J, Fuchs D, Shakked R, Raikin SM. Midterm results of radiographic and functional outcomes

- after tibiototalcalcaneal arthrodesis with bulk femoral head allograft. *Foot Ankle Spec* 2020;13:315-323.
17. Myerson MS, Neufeld SK, Uribe J. Fresh-frozen structural allografts in the foot and ankle. *J Bone Joint Surg Am* 2005;87:113-120.
 18. Halverson AL, Goss DA Jr, Berlet GC. Ankle arthrodesis with structural grafts can work for the salvage of failed total ankle arthroplasty. *Foot Ankle Spec* 2020;13:132-137.
 19. Kleiber BD, Klein SE, McCormick JJ, Johnson JE. Radiographic analysis of wedge allograft correction of angular malalignment in ankle fusion. *Foot Ankle Int* 2011;32:380-384.
 20. Steele JR, Kadakia RJ, Cunningham DJ, Dekker TJ, Kildow BJ, Adams SB. Comparison of 3D printed spherical implants versus femoral head allografts for tibiototalcalcaneal arthrodesis. *J Foot Ankle Surg* 2020;59:1167-1170.