



ELSEVIER

Contents lists available at [ScienceDirect](https://www.sciencedirect.com)

## Respiratory Medicine Case Reports

journal homepage: [www.elsevier.com/locate/rmcr](http://www.elsevier.com/locate/rmcr)

## Case report

## Venovenous extra corporeal life support in an infant with foreign body aspiration: A case report

Ahmed S. AlKhalifah<sup>\*</sup>, Nada A. AlJassim<sup>\*\*</sup>

Department of Pediatric Critical Care, Critical Care Center, King Fahad Medical City, Riyadh, Saudi Arabia

## ARTICLE INFO

## Keywords:

Venovenous extracorporeal life support (VV-

ECMO)

Foreign body aspiration (FBA)

Pneumothorax

Infant

Ultrasound

Respiratory insufficiency

## ABSTRACT

**Background:** Foreign body aspiration (FBA) is a life-threatening emergency and a common cause of morbidity and mortality in children. FBA can lead to rapidly progressive respiratory failure. Stabilizing patients after FBA for bronchoscopic removal of the aspirated object can be complex and may necessitate advanced support such as high-frequency oscillatory ventilation (HFOV) or extracorporeal membrane oxygenation (ECMO). This case report presents the feasibility of using ultrasound (US) in percutaneous catheterization in infants and the benefit of using venovenous ECMO (VV-ECMO) as rescue therapy in FBA.

**Case summary:** A 10-month-old girl accidentally aspirated a metallic piece that was dislodged further to the right main bronchus after failed trials to remove it. She was intubated and mechanically ventilated, complicated by milk aspiration and bilateral pneumothoraces secondary to high-pressure lung ventilation. She had refractory mixed respiratory failure despite high settings of HFOV and inhaled nitric oxide. Venovenous ECMO (VV-ECMO) was initiated for stabilization and a bridge for bronchoscopic foreign body removal and awaiting lung recovery. She was weaned off ECMO after 166 hours. The patient was extubated after a few days and discharged home 28 days after admission without clinical evidence of neurological or respiratory complications. ECMO has been described in the literature as rescue therapy for FBA resulting in respiratory failure. However, ECMO cannulation in children under these circumstances is challenging because of vessel size restrictions. Two-vessel cannulation or dual-lumen cannulation are available options via open cut-down or percutaneous cannulation techniques, depending on the general expertise. The use of vascular ultrasound to assess vessel size is a helpful tool for cannulating infants.

**Conclusion:** VV-ECMO support is expanding for respiratory failure in pediatric patients. Percutaneous cannulation in infants and children for VV-ECMO is safe and feasible.

**Abbreviations:** FBA, Foreign body aspiration; HFOV, high-frequency oscillatory ventilation; ECMO, extracorporeal membrane oxygenation; PEEP, positive end-expiratory pressure; FiO<sub>2</sub>, fraction inspiratory oxygen; ICU, intensive care unit; US, ultrasound; OR, operation room; VV-ECMO, venovenous ECMO; ECHO, echocardiography.

<sup>\*</sup> Corresponding author. Department of Pediatric Critical Care, Critical Care Services Administration, King Fahad Medical City, P.O. Box. 59046, Riyadh, 11525, Saudi Arabia.

<sup>\*\*</sup> Corresponding author. Department of Pediatric Critical Care, Critical Care Services Administration, King Fahad Medical City, P.O. Box. 59046, Riyadh, 11525, Saudi Arabia.

**E-mail addresses:** [ahmedsk2@gmail.com](mailto:ahmedsk2@gmail.com) (A.S. AlKhalifah), [aljassim.nada4@gmail.com](mailto:aljassim.nada4@gmail.com) (N.A. AlJassim).

<https://doi.org/10.1016/j.rmcr.2022.101636>

Received 9 November 2021; Received in revised form 28 January 2022; Accepted 17 March 2022

Available online 18 March 2022

2213-0071/© 2022 The Authors. Published by Elsevier Ltd. This is an open access article under the CC BY-NC-ND license (<http://creativecommons.org/licenses/by-nc-nd/4.0/>).

## 1. Introduction

In children, foreign body aspiration (FBA) is a preventable, life-threatening emergency that leads to high morbidity and mortality [1]. Early diagnosis and immediate management are crucial to prevent complications and detrimental outcomes [2]. FBA can be complicated by subcutaneous emphysema, pneumothorax, lung atelectasis, or consolidation, which may lead to respiratory failure and the need for mechanical ventilatory support [2,3].

Stabilizing patients before the bronchoscopic removal of aspirated objects can be complex because of refractory respiratory failure. To maintain proper gas exchange, children may need high pressure on conventional mechanical ventilation or high-frequency oscillatory ventilation (HFOV), or extracorporeal membrane oxygenation (ECMO) [4].

Multiple studies have demonstrated the benefits of using ECMO in patients with refractory respiratory failure secondary to FBA [4]. ECMO is used as a bridge to stabilize patients for bronchoscopic foreign body removal and may continue for a longer duration, awaiting lung recovery [4]. Here we describe the successful use of venovenous ECMO (VV-ECMO) in an infant who suffered from refractory mixed respiratory failure secondary to FBA, complicated by aspiration pneumonia and pressure-induced lung injury.

## 2. Case report

A 10-month-old healthy girl accidentally aspirated a metallic piece from her toy while playing. Attempts by her family members to remove it from her mouth had failed, and unfortunately, led to further lodgment of the item. The infant became blue and was unable to breathe. Thus, the family took her to the nearest hospital while conducting mouth-to-mouth rescue breathing. On arrival, she developed cardiopulmonary arrest that required resuscitation for approximately 20 min, and likely hypoxia-related bradycardia; however, the documentation was deficient in the referring hospital. She was intubated with a cuffed endotracheal tube (size 4) and mechanically ventilated. After intubation, a large amount of milk was suctioned from the endotracheal tube. She had refractory hypoxia and required high mechanical ventilation, with positive end-expiratory pressure (PEEP) of 17 cmH<sub>2</sub>O. She developed bilateral pneumothoraxes requiring three chest tube insertions: one on the right side and two on the left side. She also developed hypotension, which required dopamine infusion.

The next day, she was referred to our hospital for foreign body removal via a medevac. During transfer, it was challenging to maintain stable oxygenation. At presentation to our hospital, she was sedated, intubated, and ventilated using pressure control mode with the following settings: set respiratory rate, 50 breath per minute; pressure control, 20 cmH<sub>2</sub>O; PEEP, 10 cmH<sub>2</sub>O; and fraction inspiratory oxygen (FiO<sub>2</sub>) of 100%. Lung auscultation revealed bilateral weak breath sounds, poor lung compliance while bagging, and difficulty maintaining an O<sub>2</sub> saturation of 60–70%. The patient's hemodynamics were supported by vasoactive medications. Her heart rate was 196 beats per minute, and her blood pressure was 85/45 mmHg, with a lactate level of 1.7 mmol/L. The pupils were equal and reactive in response to light, moving all limbs in between; no head imaging was performed. The initial investigations are summarized in Table 1. The initial chest radiograph showed a foreign body lodged at the right main bronchus with bilateral pneumothorax and atelectasis (Fig. 1).

The initial management in our hospital included optimizing sedation, starting a muscle paralysis agent, and initiating hemodynamic support using epinephrine infusion instead of dopamine. HFOV was also introduced to improve oxygenation and ventilation with the following settings: a frequency of 5 Hz, amplitude of 53 CmH<sub>2</sub>O, and mean airway pressure of 25 CmH<sub>2</sub>O, in addition to 20 parts per million inhaled nitric oxide. The patient's O<sub>2</sub> saturation improved to 80%, but the CO<sub>2</sub> accumulated further, and respiratory acidosis worsened.

The otorhinolaryngology team was consulted for rigid bronchoscopy and foreign body removal; however, the patient's clinical situation was unstable with refractory mixed respiratory failure. Therefore, the ECMO team was called for rescue support to perform emergency bronchoscopy during ECMO; we anticipated awaiting lung recovery after foreign body aspiration was complicated by milk aspiration and an air leak.

To transport the patient from the emergency department to the children's hospital operation room (OR), she was transferred to a conventional mechanical ventilator with a high peak inspiratory pressure of 45 cmH<sub>2</sub>O. In the OR, induction of general anesthesia was initiated, and the patient was connected to an anesthesia ventilator machine. The patient's O<sub>2</sub> saturation at the start of cannulation was 80%. The right internal jugular and right femoral veins were screened using an ultrasound (US) vascular probe to estimate vessel diameter. Subsequently, percutaneous cannulation was attempted by pediatric intensivists with a standby surgeon. A right internal jugular vein cannula (size 12 French) was used for drainage, while the right femoral vein cannula (size 10 French) was used for the return. During cannulation, the patient's O<sub>2</sub> saturation declined with an acute drop to 40% without improvement after troubleshooting measures, including chest tubes and increased ventilatory settings. By the time VV-ECMO cannulas were inserted, the ECMO circuit was unclamped, and O<sub>2</sub> saturation rapidly improved to 93%. Subsequently, the patient was extubated, and video-assisted

**Table 1**  
Initial investigations.

<b>WBC</b>	12.7 10 <sup>3</sup> /uL	<b>Hemoglobin</b>	9.8 g/dL	<b>Platelets</b>	518 10 <sup>3</sup> /uL
<b>ALT</b>	69 U/L	<b>AST</b>	83 U/L	<b>Albumin</b>	25.6 g/L
<b>Urea</b>	9.6 mmol/L	<b>Creatinine</b>	26 μmol/l	<b>Sodium</b>	132 mmol/L
<b>Potassium</b>	4.48 mmol/L	<b>aPTT</b>	30.6 Seconds	<b>Prottime</b>	24.3 seconds
<b>INR</b>	2.08	<b>D-DIMER</b>	22.3 μg/ml	<b>Fibrinogen</b>	3.58 G/L

WBC, white blood cell; ALT, alanine aminotransferase; AST, aspartate aminotransferase; aPTT, activated partial thromboplastin clotting time; PT, prothrombin time; INR, international normalized ratio.

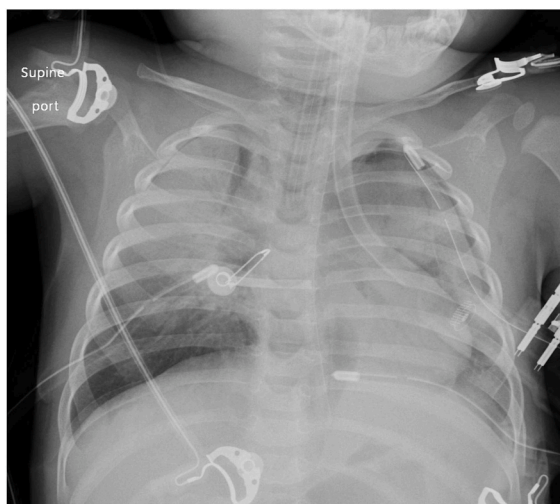


Fig. 1. Chest X-ray at presentation.

bronchoscopy was performed. The airway scope revealed a large amount of secretion, and a foreign body was visualized, located in the right main bronchus. It was extracted successfully and was found to be a small LED bulb measuring approximately 5 mm × 5 mm × 21 mm (Fig. 2a and b). Tracheal reintubation was performed, and the patient was admitted to the pediatric ICU on VV-ECMO. The initial ECMO settings included a flow of 100 mL/kg/min, speed of 5250 revolutions per minute, FiO<sub>2</sub> of 100%, venous pressure of 12–18 mmHg, pre-oxygenator pressure of 81–82 mmHg, and post-oxygenator pressure of 53–56 mmHg.

The patient required ECMO for 166 h. She was sedated and maintained on resting mechanical ventilation settings while awaiting lung recovery, which was evaluated daily at the bedside and by serial chest X-rays. ECMO anticoagulation using unfractionated heparin infusion was guided by activated clotting time and anti-factor Xa. On day 3 of ECMO, the echocardiographic (ECHO) assessment revealed mildly depressed left ventricular function and pericardial effusion (Fig. 3); therefore, the patient was started on milrinone. The drainage cannula at the right internal jugular was touching the septal leaflet of the tricuspid valve, for which readjustment and fixation of the cannula were performed at the bedside. By the third day, ventilatory support gradually escalated for recruitment. The patient showed gradual clinical and radiological improvement (Figs. 4 and 5). Two chest tubes were removed while the patient was on ECMO, and the third chest tube was removed before extubation on day 9 of admission.

After decannulation, ECHO was repeated, which revealed a resolving pericardial effusion. Right femoral vein Doppler showed external iliac and common femoral thrombosis, and the patient was started on enoxaparin. The patient was transferred from the

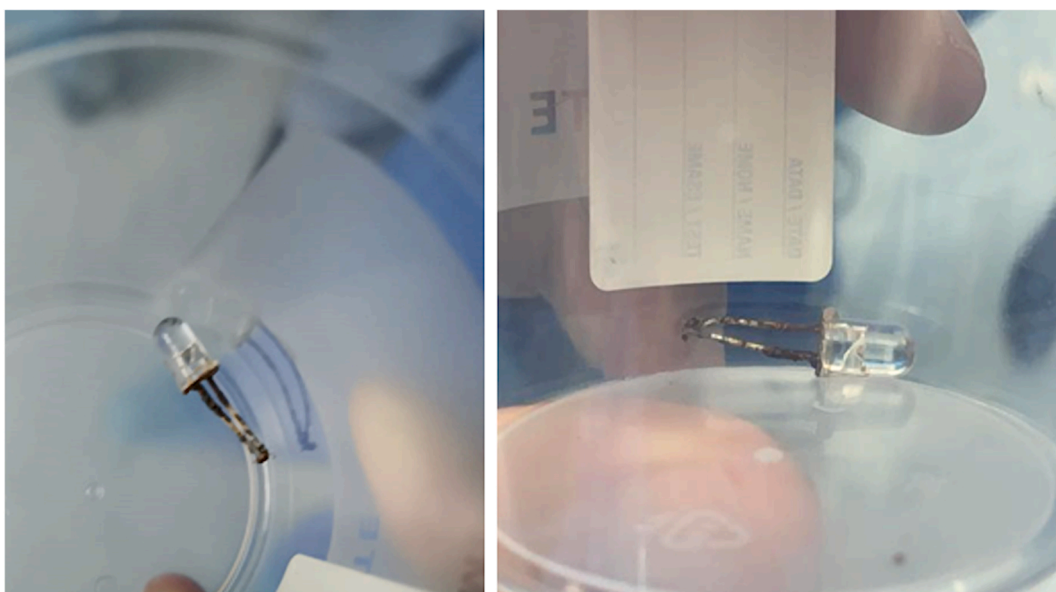


Fig. 2. Small LED bulb measuring approximately 5 mm × 5 mm X 21 mm.

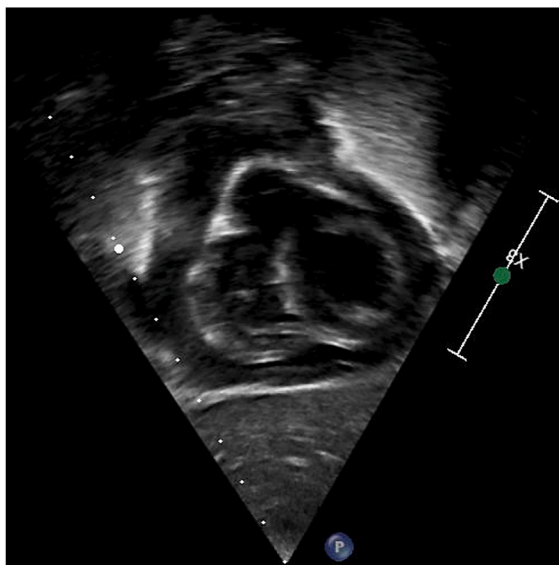


Fig. 3. Day 3 on extracorporeal membrane oxygenation; echocardiography with pericardial effusion.

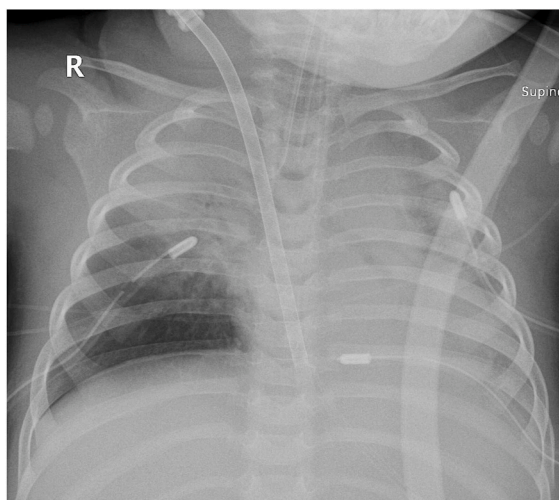


Fig. 4. Day 4 chest X-ray after cannulation.

pediatric ICU to the general pediatric ward on the 13th day of admission and discharged on the 28th day of hospitalization without clinical evidence of neurological or respiratory complications. Brain MRI was recommended as a routine follow-up.

Written informed consent for publication of this case report was obtained from the patient's guardian.

### 3. Discussion

We present the case of an infant who developed refractory mixed respiratory failure secondary to foreign body aspiration, mandating VV-ECMO support for stabilization and foreign body removal through bronchoscopy. The patient's course was complicated by aspiration pneumonia and pressure-induced lung injury evident by pneumothoraces.

FBA is common in children [1]. Most of the reported aspirations are related to food, but aspiration of other materials has also been documented [1,5]. Aspirated objects are most likely to lodge into the right main bronchus because of the airway anatomy and alignment [2]. Early diagnosis and treatment may reduce the associated complications and mortality. Rigid bronchoscopy is the best management approach in such circumstances and is usually performed in operation theaters under general anesthesia [2]. The management of these patients is challenging and may necessitate advanced support, such as HFOV or ECMO [4].

Anton-Martin et al. reported that four patients (14–24 months old) survived ECMO support post-FBA, one of whom suffered from post-arrest neurological injury [4]. When the Extracorporeal Life Support Organization registry queried for cases with FBA, a total of

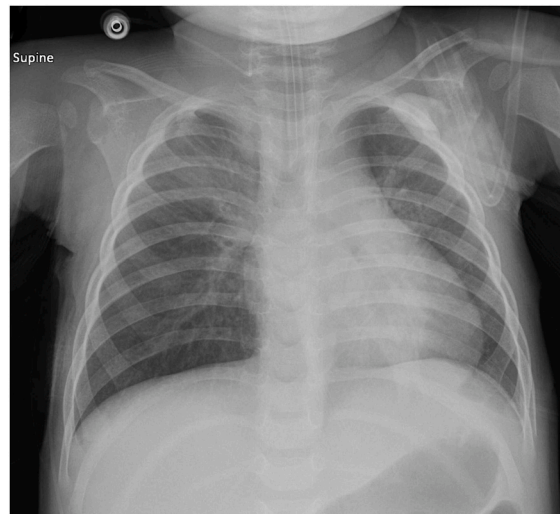


Fig. 5. Day 9 chest X-ray before extubation.

42 patients with a median age of 1.54 years (range 0.04–16.7 years) and a median weight of 12 kg (range 7.5–98 kg) were found [4].

ECMO initiation in children with FBA requires immediate multidisciplinary decisions and timely intervention to rescue the patient. Cannulation in smaller children can be challenging, especially in children weighing less than 10 kg, as cannulation techniques and experience are needed due to the small vessel size [6]. Percutaneous dual-lumen cannulation is becoming increasingly popular because of its advantages: fewer recirculation and cannula kinking events [6–8]. Thus, jugular veins are commonly accessed for VV-ECMO in these children due to smaller femoral veins [6,9,10]. Two-vessel cannulation for VV-ECMO is still used through the femoral and jugular veins, especially if proper size dual-lumen cannulas are lacking, as in our patient [11]. It can be achieved by open cut-down or percutaneous cannulation techniques in children, depending on the expertise and facilities available.

Percutaneous ECMO cannulation use is increasing in children, as several studies have reported its safety. It can be performed by intensivists, has fewer complications, is less invasive, and has better wound healing than conventional cannulation methods [6,11–15]. The weight cutoff for the cannulation technique is variable (3 kg–40 kg) based on the health care facility and cannulating physicians [16]. US use is beneficial in ECMO cannulation to assess vessel size and directly visualize the entire wire, avoiding arterial perforation and malposition [6,12,13,16]. Additionally, ECHO, US, and fluoroscopy to guide the cannulation procedure and positioning are helpful in pediatric patients for safer cannulation and better positioning [12,13,16]. Smaller cannulas may be used in percutaneous cannulation if there is no significant impact on the targeted ECMO flow. Exchanging the function of cannulas by drainage from the internal jugular vein and returning to the femoral vein can be one way of overcoming the cannula size limitation, as in our patient. However, venoarterial cannulation of the neck vessels may be the best approach to provide sufficient ECMO support if expertise is available [17].

While the use of percutaneous cannulation is increasing, there are many limitations, including patient size, lack of experienced physicians, and availability of ECMO cannulas. Cannulation complications can include vessel laceration, bleeding, and perforation. Alerting surgical specialties for standby support is recommended [10,12,13].

Our pediatric intensivist performed percutaneous cannulation using the US vascular probe as guidance in addition to transthoracic echocardiography. Two-vessel cannulation was attempted after assessing the jugular and femoral vein size by checking the transverse diameter via US. No complications were encountered during or immediately after cannulation, but femoral vein thrombosis and pericardial effusion developed during subsequent days and were managed without long-term complications.

#### 4. Conclusion

VV-ECMO is expanding support for respiratory failure in pediatric patients despite cannulation challenges. However, percutaneous cannulation for dual-lumen VV-ECMO is safe and becoming increasingly common. Two-vessel VV-ECMO can still be performed by the pediatric intensivist to provide adequate ECMO support in infants and children using ultrasound guidance and echocardiography.

#### Financial support

This research did not receive any specific grant from funding agencies in the public, commercial, or not-for-profit sectors.

#### Declaration of competing interest

There is no conflict of interest for all authors involved in this case report.

## Acknowledgments

The authors are thankful to the patient and her parents, the cardiology department, the pediatric cardiovascular operating theater, and pediatric cardiovascular ICU nurses and doctors.

## References

- [1] R. Altkorn, X. Chen, S. Milkovich, et al., Fatal and non-fatal food injuries among children (aged 0-14 years), *Int. J. Pediatr. Otorhinolaryngol.* 72 (2008) 1041–1046.
- [2] G. Wang, Z. Pan, H. Li, et al., Diagnosis and treatment of tracheobronchial foreign bodies in 1024 children, *J. Pediatr. Surg.* 47 (2012) 2004–2010.
- [3] S. Na'ara, I. Vainer, M. Amit, A. Gordin, Foreign body aspiration in infants and older children: a comparative study, *Ear Nose Throat J* 99 (2020) 47–51.
- [4] P. Anton-Martin, P. Bhattarai, P. Rycus, et al., The use of extracorporeal membrane oxygenation in life-threatening foreign body aspiration: case series, review of extracorporeal life support organization registry data, and systematic literature review, *J. Emerg. Med.* 56 (2019) 523–529.
- [5] N. Saki, S. Nikakhlagh, F. Rahim, et al., Foreign body aspirations in Infancy: a 20-year experience, *Int. J. Med. Sci.* 6 (2009) 322–328.
- [6] T.V. Brogan, L. Lequier, R. Lorusso, et al., *ELSO Red Book 5th Edition*, vol. 53, 2019.
- [7] W. Kim, H.W. Kwon, J. Min, et al., Extracorporeal membrane oxygenation in pediatric patients with respiratory failure: early experience with the double-lumen cannula over 2 years, *Kor J Thorac Cardiovasc Surg* 53 (2020) 132–139.
- [8] P.A. Salazar, D. Blitzer, S.C. Dolejs, et al., Echocardiographic guidance during neonatal and pediatric jugular cannulation for ECMO, *J. Surg. Res.* 232 (2018) 517–523.
- [9] M.J. Griffiee, J.E. Tonna, S.H. McKellar, et al., Echocardiographic guidance and troubleshooting for venovenous extracorporeal membrane oxygenation using the dual-lumen bicaval cannula, *J. Cardiothorac. Vasc. Anesth.* 32 (2018) 370–378.
- [10] A. Moscatelli, F. Febbo, S. Buratti, et al., Intensivists performed percutaneous bicaval double-lumen echo-guided extracorporeal membrane oxygenation cannulation at bedside in newborns and children: a retrospective analysis, *Pediatr. Crit. Care Med.* 20 (2019) 551–559.
- [11] T. Bull, A. Corley, I. Lye, et al., Cannula and circuit management in peripheral extracorporeal membrane oxygenation: an international survey of 45 countries, *PLoS One* 14 (2019) 1–14.
- [12] S.A. Conrad, L.R. Grier, L.K. Scott, et al., Percutaneous cannulation for extracorporeal membrane oxygenation by intensivists: a retrospective single-institution case series, *Crit. Care Med.* 43 (2015) 1010–1015.
- [13] M.D. Jarboe, S.K. Gadepalli, J.T. Church, et al., Avalon catheters in pediatric patients requiring ECMO: placement and migration problems, *J. Pediatr. Surg.* 53 (2018) 159–162.
- [14] J.L. Carpenter, Y.R. Yu, D.L. Cass, et al., Use of venovenous ECMO for neonatal and pediatric ECMO: a decade of experience at a tertiary children's hospital, *Pediatr. Surg. Int.* 34 (2018) 263–268.
- [15] S.B. Cairo, M. Arbuthnot, L. Boomer, et al., Comparing percutaneous to open access for extracorporeal membrane oxygenation in pediatric respiratory failure, *Pediatr. Crit. Care Med.* 19 (2018) 981–991.
- [16] N.A. Drucker, S.K. Wang, T.A. Markel, et al., Practice patterns in imaging guidance for ECMO cannulation: a survey of the American Pediatric Surgical Association, *J. Pediatr. Surg.* 55 (2020) 1457–1462.
- [17] C. Maratta, R.M. Potera, G. Van Leeuwen, et al., Extracorporeal life support organization (ELSO): 2020 pediatric respiratory ELSO guideline, *ASAIO J* 66 (2020) 975–979.