

Therapeutic Response of Extracorporeal Shock Wave Therapy for Insertional Achilles Tendinopathy Between Sports-Active and Nonsports-Active Patients With 5-Year Follow-up

Shurong Zhang,* MD, PhD, Hong Li,* MD, PhD, Wei Yao,* PT, Yinghui Hua,* MD, PhD, and Yunxia Li,*† MD

Investigation performed at the Department of Sports Medicine, Huashan Hospital, Fudan University Shanghai, People's Republic of China

Background: Insertional Achilles tendinopathy (IAT) is a common cause of posterior heel pain. Extracorporeal shock wave therapy (ESWT) has proven to be an effective treatment, but the relationship between therapeutic responses and sports activity levels has not been studied.

Purpose: To compare the clinical outcomes of ESWT used to treat IATs between sports-active and nonsports-active patients over 5 years.

Study Design: Cohort study; Level of evidence, 3.

Methods: A retrospective study was conducted on 33 patients with IAT who received ESWT from October 2012 to September 2013. Patients were classified into 2 groups according to their preinjury Tegner activity level: a sports-active group, defined as patients who self-reported to be regular joggers (SA group; Tegner activity level >3 ; $n = 16$), and a nonsports-active group (control group; Tegner activity level ≤ 3 ; $n = 17$). The mean age was 31 ± 7 years for the SA group and 37 ± 10 years for the control group. The Victorian Institute of Sports Assessment–Achilles (VISA-A) questionnaire scores and visual analog scale (VAS) pain scores were used to evaluate the clinical outcomes before treatment, immediately after treatment, and 5 years after treatment. Ultrasonography was also used to assess the insertional Achilles tendon quality.

Results: Before treatment, there were no significant differences between the groups with regard to VAS scores, while the VISA-A score in the SA group was higher than that in the control group. After ESWT, both groups had increased VISA-A scores and decreased VAS scores, indicating improvement. At 5-year follow-up, the SA group had a significantly lower mean VAS score (0.3 ± 0.8 vs 1.6 ± 1.3 ; $P = .001$) and a significantly higher mean VISA-A score (90 ± 4 vs 78 ± 7 ; $P < .001$) compared with the control group. There was no significant difference between the groups regarding the calcification and neovascularization of the Achilles tendon based on ultrasonography.

Conclusion: ESWT can improve the symptoms of Achilles tendinopathy, and patients with IAT who had greater sports activity levels had better therapeutic responses than nonsports-active patients after 5-year follow-up.

Keywords: extracorporeal shock wave; Achilles tendon; tendinopathy; ultrasonography

Insertional Achilles tendinopathy (IAT) is a common cause of posterior heel pain that occurs at the insertion of the Achilles tendon onto the calcaneus.^{12,27} IATs may cause considerable morbidity and are difficult to manage,²⁵ and they most commonly affect active adults aged between 30 and 60 years, particularly those who are engaged in racket

sports, track and field, volleyball, and soccer.^{3,18} It had been hypothesized that IATs were caused by repetitive sports injuries¹⁸; however, Rolf and Movin¹⁹ reported on a study of 58 Achilles tendinopathy patients in which 31% of the patients did not participate in sports or vigorous physical activities. This suggests that in addition to repetitive sports injuries, other causes of this condition are present in the general population.

In a study⁴ comparing Achilles tendon morphology between adolescent elite athletes and recreational active

The Orthopaedic Journal of Sports Medicine, 8(1), 2325967119898118

DOI: 10.1177/2325967119898118

© The Author(s) 2020

This open-access article is published and distributed under the Creative Commons Attribution - NonCommercial - No Derivatives License (<https://creativecommons.org/licenses/by-nc-nd/4.0/>), which permits the noncommercial use, distribution, and reproduction of the article in any medium, provided the original author and source are credited. You may not alter, transform, or build upon this article without the permission of the Author(s). For article reuse guidelines, please visit SAGE's website at <http://www.sagepub.com/journals-permissions>.

populations, higher fiber density and organization was found in recreationally active participants than in less active participants, which indicates that different Achilles tendon adaptations might occur in athletic and nonathletic patients. In such cases, different treatment strategies should be applied. However, not many studies have investigated the difference in therapeutic outcomes between sports-active and nonsports-active IAT patients. Only Rolf and Movin¹⁹ compared the surgical outcomes between athletic and nonathletic patients, but there was insufficient evidence to determine whether sports-active patients responded differently compared with nonsports-active patients when receiving nonoperative treatments.

Physical therapy, such as extracorporeal shock wave therapy (ESWT), is considered an effective treatment for IAT before surgical options.¹² ESWT has proven effective in lateral epicondylitis, plantar fasciitis, tendinopathy of the shoulder, and also bone and skin disorders.^{9,10,16,21} ESWT has some evidence of benefit for the treatment of both IAT and non-IAT, as reported in several systematic reviews.^{2,8,15} The evidence is limited, yet it suggests that ESWT is an effective option for treating chronic IATs, particularly when other nonoperative treatments have failed.^{2,15} It would, therefore, be interesting to know if there is a difference in clinical response between sports-active patients and nonsports-active patients after ESWT for IATs.

Ultrasonography has proven to be a reliable tool to detect Achilles tendon pathologies, including calcific plaque sizes and neovascularizations.^{22,24} It can also be used in clinical environments to determine the morphological changes of the tendon after ESWT.⁵ Therefore, the aim of the present study was to evaluate and compare the clinical efficacy of ESWT in the treatment of Achilles tendons between sports-active and nonsports-active patients using functional scores and ultrasonography examinations. It was hypothesized that sports-active patients would have similar functional outcomes compared with nonsports-active patients after ESWT.

METHODS

Study Design

This study was approved by the ethics committee of our hospital. A retrospective study was conducted on patients with IAT who received ESWT from October 2012 to September 2013. The diagnosis of IAT was confirmed by the following definition: pain and localized tenderness at the insertion region of the Achilles tendon and decreased activity levels secondary to Achilles tendon pain.^{5,22,24,25} According to

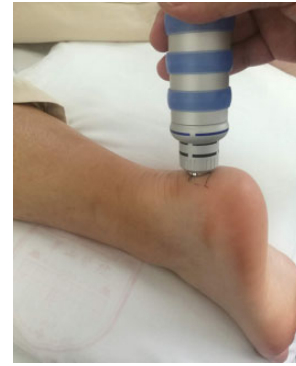

Figure 1. Extracorporeal shock wave therapy in the treatment of insertional Achilles tendinopathy.

previously reported shockwave therapy studies,¹³ visual analog scale (VAS) scores for pain were used to determine the appropriate sample size, which was estimated to be between 15 and 24 patients ($\alpha = 0.05$, 2-tailed, and $\delta = 2$). Patients were classified into 2 groups according to their pre-injury Tegner activity level: a sports-active group, defined as patients who self-reported to be regular joggers (SA group; Tegner activity level >3), and a nonsports-active group (control group; Tegner activity level ≤ 3).

Before the first ESWT treatment, baseline measurements of clinical function and ultrasonography results were recorded. Follow-up examinations were performed immediately after treatment and 5 years after treatment.

The inclusion criteria were (1) Achilles tendinopathy confirmed by magnetic resonance imaging or ultrasonography; (2) duration between onset of symptoms and treatment >3 months; (3) no other treatments (such as anti-inflammatory drugs, physiotherapy, etc) before or during the treatment period; and (4) successful completion of a course of extracorporeal shock wave treatments. Patients with the following conditions were excluded: (1) Haglund deformities or Achilles tendon ruptures; (2) previous ankle or Achilles tendon operations; (3) midportion Achilles tendinopathy; (4) ankle deformities; (5) ankle osteoarthritis; or (6) peripheral neuropathies, systematic neurological diseases, or seronegative diseases.

Extracorporeal Shock Wave Therapy

A radial shock wave device (EMS Swiss Dolor-Clast) was used to perform the ESWT on the most sensitive point of the Achilles tendon (Figure 1). Therapies were administered once a week for 5 sessions by the same practitioner. The

[†]Address correspondence to Yunxia Li, MD, No. 12, Wulumuqi Zhong Road, Shanghai 200040, China (email: liyunxia912@aliyun.com).

^{*}Department of Sports Medicine, Huashan Hospital, Fudan University, Shanghai, People's Republic of China.

S.Z., H.L., and W.Y. contributed equally to this article.

Final revision submitted September 27, 2019; accepted October 10, 2019.

One or more of the authors has declared the following potential conflict of interest or source of funding: This study was supported by the grants 18Z004 and 18Z002 funded by Shanghai Sports Science and Technology "Comprehensive Plan" Project and "Huaxiu" Grant No. Yuan 811 funded by Huashan Hospital, Fudan University. AOSSM checks author disclosures against the Open Payments Database (OPD). AOSSM has not conducted an independent investigation on the OPD and disclaims any liability or responsibility relating thereto.

Ethical approval for this study was obtained from Huashan Hospital of Fudan University.

energy dose was controlled by the operator to a “maximal comfortably tolerated” level, which was different for each patient and varied between sessions. During each session, the number of impacts was 2000, the energy density was 0.06 to 0.1 mJ/mm², the pressure was 1.5 to 2.5 Pa, and the frequency was 6 to 8 Hz. Patients were given standardized postprocedural advice after ESWT and were advised to avoid nonsteroidal anti-inflammatory drugs (NSAIDs) the day of, and a few days after, each ESWT session.

Clinical Evaluation

Clinical functional evaluations included the Victorian Institute of Sports Assessment–Achilles (VISA-A) questionnaire and the VAS for pain. The VISA-A questionnaire is a valid and reliable measure of the severity of Achilles tendinopathy. The VISA-A contains 8 questions that cover the 3 domains of pain, function, and activity (a maximum score of 100).¹⁸ The Tegner activity level was also recorded at the final follow-up.

Ultrasonographic Examination

Ultrasonography scanning was performed using an iU22 ultrasonography unit (Philips Medical Systems) with a wide-frequency linear array transducer (5-17 MHz) according to a previous report.⁵ All Achilles tendons were scanned in the longitudinal plane, and calcifications and neovascularization were analyzed. Since normal Achilles tendons are avascular tissues, neovascularization was defined as the appearance of vessel signals inside the tendon¹⁷ and was assessed around the insertional site.

Statistical Analysis

Data analyses were performed using Stata 10.0 software (Stata Corp), and the data were reported as means \pm SDs. A χ^2 test was used to compare categorical variables. The Shapiro-Wilk test was used to test the distribution of data. Comparisons between groups were made with the Student *t* test for normal distribution or 2-sample Wilcoxon rank-sum test for abnormal distribution of continuous variables. The significance level was set at $P < .05$.

RESULTS

From an initial 37 patients, 4 patients were lost to follow-up. Thus, 33 patients were available at the final follow-up, including 16 patients from the SA group and 17 from the control group. The 2 groups did not differ significantly in age, body mass index (BMI), sex, therapeutic side, or VAS scores. The VISA-A score of the SA group was slightly higher than that of the control group (56 ± 7 vs 51 ± 8 ; $P = .04$) (Table 1).

No patient reported serious complications, including infections or Achilles tendon ruptures. For this cohort, the VISA-A score increased with time and the VAS score decreased with time after ESWT treatments (Figure 2).

TABLE 1
Participant Characteristic Data^a

	SA group (n = 16)	Control group (n = 17)	P
Age, y	31 \pm 7	37 \pm 10	.06
Body mass index, kg/m ²	23.5 \pm 0.3	24.5 \pm 0.6	.17
Sex, male/female	16/0	15/2	.48
Pretreatment Tegner score	6 \pm 1	3 \pm 0	<.001
Therapeutic side, left/right	6/10	6/11	.99
Calcification, n	8	12	.30
VAS pain score before treatment	7 \pm 1	7 \pm 1	.87
VISA-A score before treatment	56 \pm 7	51 \pm 8	.04

^aValues are expressed as mean \pm SD unless otherwise indicated. SA, sports-active; VAS, visual analog scale; VISA-A, Victorian Institute of Sports Assessment–Achilles.

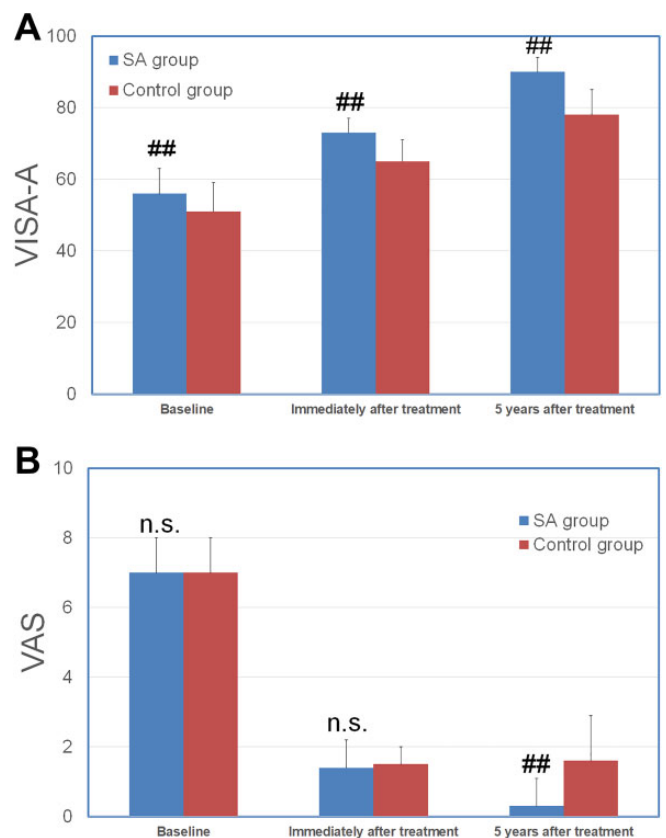


Figure 2. Comparison between the sports-active (SA) and control groups in (A) Victorian Institute of Sports Assessment–Achilles (VISA-A) scores and (B) pain visual analog scale (VAS) scores before treatment, immediately after treatment, and at 5 years after treatment. ##Significant difference between groups; n.s., no significant difference between groups.

The sports activity level did not significantly change after ESWT treatments in either group. The Tegner activity level in the SA group was 6 ± 1 before treatment and

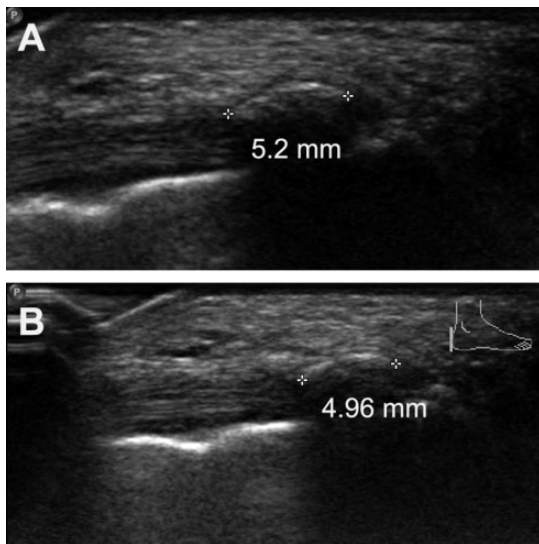


Figure 3. (A) A calcific plaque in the insertion of the Achilles tendon before therapy (outline of Achilles tendon traced by asterisk-like marks). (B) The calcific plaque was still present and did not change significantly posttherapy.

6 ± 0 after the 5-year follow-up, and it was 3 ± 0 before treatment and 3 ± 0 after the 5-year follow-up in the control group. Immediately after treatment, the 2 groups had comparable VAS scores (1.4 ± 0.8 vs 1.5 ± 0.5 ; $P = .70$), while the SA group had a significantly higher VISA-A score than the control group (73 ± 4 vs 65 ± 6 ; $P < .001$). At the 5-year follow-up, the SA group had a significantly lower VAS score than the control group (0.3 ± 0.8 vs 1.6 ± 1.3 ; $P = .001$), and the SA group had a significantly higher VISA-A score than the control group (90 ± 4 vs 78 ± 7 ; $P < .001$) (Figure 2).

All study patients were examined before treatment and after treatment by ultrasonography. Before ESWT treatments, 8 patients in the SA group and 12 patients in the control group were found to have calcifications. After treatment, the number or the size of calcifications did not change in any patient (Figure 3). No obvious neovascularizations were observed at the Achilles insertional site in any patient after treatment. Interestingly, the neovascularization near the proximal site of Achilles insertion decreased after ESWT treatments in 3 control group patients (Figure 4).

DISCUSSION

There are several nonoperative treatments for IATs, such as rest and icing, NSAIDs, platelet-rich plasma (PRP) injections, and physiotherapy. It has been reported that ESWT yields better clinical outcomes over eccentric exercises²⁰ and relatively similar results compared with PRP injections in physically active patients.⁶ Despite the reported efficacy of ESWT for chronic Achilles tendinopathy, some patients do not respond to treatment and still have residual symptoms. Therefore, it is important to know which patients are more amenable to ESWT.

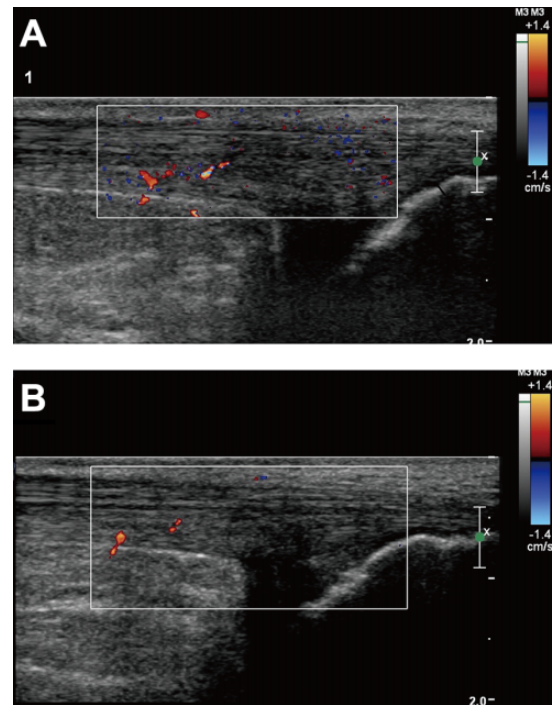


Figure 4. (A) Color Doppler shows no vessels in the insertion of the Achilles tendon, while there were numerous vessels near the insertion site before therapy. (B) After ESWT therapy, there were no neovascularizations in the insertion site, and the revascularization decreased near the insertion site compared with ultrasonographic images before the treatment. ESWT, extracorporeal shock wave therapy.

IATs tend to be recalcitrant to a range of treatment options, and there may be long recovery times.⁷ Excessive sports activities accompanied by Achilles tendon degeneration have been suspected as possible causes.^{1,18} Other studies¹¹ have claimed that Achilles tendon degeneration is seen in middle-aged and overweight populations who do not participate in sports. Kearney and Costa¹² found the cause to be primarily repetitive activities in young athletes, while degeneration might be the cause in the elderly.

Our results suggest that sports activity level is an important factor influencing long-term ESWT outcomes for IAT. In this study, the sports-active patients had better clinical outcomes than nonsports-active patients after 5 years of follow-up. Maffulli et al¹⁴ also reported that nonathletic patients experienced more prolonged recoveries and more complications and were at a greater risk of further surgeries than athletic patients with recalcitrant Achilles tendinopathy after surgical treatment. It was presumed that the nonathletic patients might have had degenerated Achilles tendons. Additionally, our study determined that the effect of ESWT might continue after completion of the treatment, with clinical outcomes continuing to improve after 5 years. Furia⁹ evaluated the effectiveness of ESWT in the symptomatic treatment of Achilles tendinopathy over time and observed satisfactory results in 47.2% of cases at 2-month follow-up, 73.2% of cases at medium-term (6- to 12-month)

follow-up, and 76% of cases at long-term (13- to 24-month) follow-up. These findings indicate that ESWT can effectively treat Achilles tendinopathy for a long period of time.

In the present study, ultrasonography was applied to evaluate the calcification and neovascularization of Achilles tendons. However, according to our results, the number as well as the size of calcifications did not change, and no obvious neovascularizations were observed at the Achilles insertional site in any patients. A previous study²⁶ reported that theories about ESWT can be roughly divided into pain relief, tissue regeneration, and destruction of calcifications. Pain relief was indeed obtained, while calcifications did not change in this study. Santamato et al²³ reported that ultrasound examinations revealed neovascularization in 91.7% of patients 1 and 2 months after focused ESWT and demonstrated the efficacy of ESWT in pain reduction with a high degree of patient satisfaction, although doubt persists regarding the neovascularization effect on the treated Achilles tendons. These findings indicate the limitation of ultrasonography examination for IATs. In a previous animal study, Vetrano et al²⁸ observed a significant increase in neovessels after biopsy at 4 weeks, and this increase persisted until 12 weeks after ESWT. In the present study, the neovascularizations near the proximal site of Achilles insertions were observed to change after ESWT treatments. It is believed that the neovascularizations can appear on the noninsertional site of Achilles tendons.

There are several limitations in this study. First, as a retrospective study, the number of patients recruited was small, and therefore this might have introduced biases and inaccuracies. Second, the tissue composition of the Achilles tendon insertional areas is unknown because histological analyses could not be performed. Third, the reason we defined patients with a Tegner activity level ≤ 3 as non-sports active was mainly because we defined sports active patients as those who jogged regularly, and this could have introduced some bias. Since this is a small study, clinical effects could not be investigated for a longer time (5 years). Furthermore, the etiology of IAT in both sports-active and non-sports-active patients might overlap, and the ESWT mechanisms for treating tendinopathy are still unclear.

CONCLUSION

ESWT can improve the symptoms of Achilles tendinopathy, and sports-active patients having IAT had better therapeutic responses than non-sports-active patients after 5 years of follow-up.

REFERENCES

- Abate M, Silbernagel KG, Siljeholm C, et al. Pathogenesis of tendinopathies: inflammation or degeneration? *Arthritis Res Ther*. 2009;11(3):235.
- Al-Abbad H, Simon JV. The effectiveness of extracorporeal shock wave therapy on chronic Achilles tendinopathy: a systematic review. *Foot Ankle Int*. 2013;34(1):33-41.
- Alfredson H, Lorentzon R. Chronic Achilles tendinosis: recommendations for treatment and prevention. *Sports Med*. 2000;29(2):135-146.
- Cassel M, Risch L, Mayer F, et al. Achilles tendon morphology assessed using image based spatial frequency analysis is altered among healthy elite adolescent athletes compared to recreationally active controls. *J Sci Med Sport*. 2019;22(8):882-886.
- Cheng Y, Zhang J, Cai Y. Utility of ultrasonography in assessing the effectiveness of extracorporeal shock wave therapy in insertional Achilles tendinopathy. *Biomed Res Int*. 2016;2016:2580969.
- Erroi D, Sigona M, Suarez T, et al. Conservative treatment for insertional Achilles tendinopathy: platelet-rich plasma and focused shock waves. A retrospective study. *Muscles Ligaments Tendons J*. 2017;7(1):98-106.
- Fahlstrom M, Jonsson P, Lorentzon R, Alfredson H. Chronic Achilles tendon pain treated with eccentric calf-muscle training. *Knee Surg Sports Traumatol Arthrosc*. 2003;11(5):327-333.
- Furia JP. High-energy extracorporeal shock wave therapy as a treatment for insertional Achilles tendinopathy. *Am J Sports Med*. 2006;34(5):733-740.
- Furia JP. High-energy extracorporeal shock wave therapy as a treatment for chronic noninsertional Achilles tendinopathy. *Am J Sports Med*. 2008;36(3):502-508.
- Gerdesmeyer L, Mittermayr R, Fuerst M, et al. Current evidence of extracorporeal shock wave therapy in chronic Achilles tendinopathy. *Int J Surg*. 2015;24(pt B):154-159.
- Irwin TA. Current concepts review: insertional Achilles tendinopathy. *Foot Ankle Int*. 2010;31(10):933-939.
- Kearney R, Costa ML. Insertional Achilles tendinopathy management: a systematic review. *Foot Ankle Int*. 2010;31(8):689-694.
- Korakakis V, Whiteley R, Tzavara A, Malliaropoulos N. The effectiveness of extracorporeal shockwave therapy in common lower limb conditions: a systematic review including quantification of patient-rated pain reduction. *Br J Sports Med*. 2018;52(6):387-407.
- Maffulli N, Testa V, Capasso G, et al. Surgery for chronic Achilles tendinopathy yields worse results in nonathletic patients. *Clin J Sport Med*. 2006;16(2):123-128.
- Mani-Babu S, Morrissey D, Waugh C, Screen H, Barton C. The effectiveness of extracorporeal shock wave therapy in lower limb tendinopathy: a systematic review. *Am J Sports Med*. 2015;43(3):752-761.
- Mansur NS, Faloppa F, Bellotti JC, et al. Shock wave therapy associated with eccentric strengthening versus isolated eccentric strengthening for Achilles insertional tendinopathy treatment: a double-blinded randomised clinical trial protocol. *BMJ Open*. 2017;7(1): e013332.
- Ohberg L, Alfredson H. Ultrasound guided sclerosis of neovessels in painful chronic Achilles tendinosis: pilot study of a new treatment. *Br J Sports Med*. 2002;36(3):173-175.
- Robinson JM, Cook JL, Purdam C, et al. The VISA-A questionnaire: a valid and reliable index of the clinical severity of Achilles tendinopathy. *Br J Sports Med*. 2001;35(5):335-341.
- Rolf C, Movin T. Etiology, histopathology, and outcome of surgery in achillodynia. *Foot Ankle Int*. 1997;18(9):565-569.
- Rompe JD, Furia J, Maffulli N. Eccentric loading compared with shock wave treatment for chronic insertional Achilles tendinopathy. A randomized, controlled trial. *J Bone Joint Surg Am*. 2008;90(1):52-61.
- Rompe JD, Furia J, Maffulli N. Eccentric loading versus eccentric loading plus shock-wave treatment for midportion Achilles tendinopathy: a randomized controlled trial. *Am J Sports Med*. 2009;37(3):463-470.
- Ryan M, Wong A, Taunton J. Favorable outcomes after sonographically guided intratendinous injection of hyperosmolar dextrose for chronic insertional and midportion Achilles tendinosis. *AJR Am J Roentgenol*. 2010;194(4):1047-1053.
- Santamato A, Beatrice R, Micello MF, et al. Power Doppler ultrasound findings before and after focused extracorporeal shock wave therapy for achilles tendinopathy: a pilot study on pain reduction and neovascularization effect. *Ultrasound Med Biol*. 2019;45(5):1316-1323.
- Sunding K, Fahlstrom M, Werner S, Forssblad M, Willberg L. Evaluation of Achilles and patellar tendinopathy with greyscale ultrasound

- and colour Doppler: using a four-grade scale. *Knee Surg Sports Traumatol Arthrosc.* 2016;24(6):1988-1996.
25. Sussmilch-Leitch SP, Collins NJ, Bialocerowski AE, Warden SJ, Crossley KM. Physical therapies for Achilles tendinopathy: systematic review and meta-analysis. *J Foot Ankle Res.* 2012;5(1):15.
 26. van der Worp H, van den Akker-Scheek I, van Schie H, Zwerver J. ESWT for tendinopathy: technology and clinical implications. *Knee Surg Sports Traumatol Arthrosc.* 2013;21(6):1451-1458.
 27. van Dijk CN, van Sterkenburg MN, Wiegerinck JI, Karlsson J, Maffulli N. Terminology for Achilles tendon related disorders. *Knee Surg Sports Traumatol Arthrosc.* 2011;19(5):835-841.
 28. Vetrano M, d'Alessandro F, Torrisi MR, Ferretti A, Vulpiani MC, Visco V. Extracorporeal shock wave therapy promotes cell proliferation and collagen synthesis of primary cultured human tenocytes. *Knee Surg Sports Traumatol Arthrosc.* 2011;19(12):2159-2168.