

# Two ticking time bombs: giant coronary artery aneurysm and abdominal aortic aneurysm in the setting of urgent vascular surgery—a case report

Sara Schukraft <sup>1</sup>, Thierry Carrel <sup>2</sup>, Mario Togni<sup>1</sup>, and Adrian Attinger-Toller <sup>1\*</sup>

<sup>1</sup>Department of Cardiology, University and Hospital Fribourg, Chemin des Pensionnats 2, 1708 Fribourg, Switzerland; and <sup>2</sup>Heart and Vascular Surgery, University Hospital of Bern, Freiburgstrasse 18, 3010 Bern, Switzerland

Received 12 December 2019; first decision 27 February 2020; accepted 30 June 2020; online publish-ahead-of-print 12 October 2020

## Background

Giant coronary artery aneurysms (CAAs) are rare and treatment strategies various, especially in the setting of a concomitant abdominal aortic aneurysm (AAA) which needs urgent repair.

## Case summary

A 78-year-old Caucasian male was admitted for evaluation of a rapidly expanding AAA. In addition, computed tomography angiography revealed a 5 × 4 cm giant aneurysm of the right coronary artery. After interdisciplinary discussion, the patient underwent aorto-bi-iliac bypass grafting first. In a second step, CAA was successfully excluded and coronary artery bypass grafting of the right coronary artery was performed.

## Discussion

Treatment strategy of CAA and timing of non-cardiac surgery is challenging. In order to minimize the overall risk of rupture interdisciplinary discussion is crucial. In our case, aorto-bi-iliac bypass grafting was safely performed, and the patient underwent successful CAA excision in a second step.

## Keywords

Coronary artery aneurysm • Non-cardiac surgery • CT angiography • Case report

## Learning points

- Giant coronary aneurysms are rare.
- Computed tomography and coronary angiography provide exact information about aneurysm diameter, luminal thrombosis, and any significant stenosis.
- Interdisciplinary discussion of treatment strategies is crucial for optimal outcome.

## Introduction

Coronary artery aneurysms (CAAs) are rare findings on coronary angiograms (0.3–5.3%).<sup>1–3</sup> Coronary artery aneurysm is defined as

coronary artery dilatation exceeding the normal adjacent segments or the diameter of the largest coronary vessel by 1.5 times.<sup>4</sup> However, it is considered giant if its diameter is >4 cm.<sup>5</sup>

Pathogenesis of CAA is still unclear and not yet completely understood. The presence of atherosclerosis has been commonly associated with aneurysms in older patients, although it is unknown if atherosclerotic changes truly play a role in the development of CAA.<sup>1</sup> Coronary artery aneurysms have also been reported in patients with systemic inflammatory diseases, connective tissue diseases, trauma, as well as after percutaneous coronary interventions (PCIs).<sup>6</sup>

Most CAAs are clinically silent and are detected incidentally during angiography or computed tomography. Clinical symptoms usually arise due to complications of CAA including: (i) thrombosis in the lumen of

\* Corresponding author. Tel: +41 26 306 20 50, Fax: +41 26 306 20 51, Email: [adrian.atinger@bluewin.ch](mailto:adrian.atinger@bluewin.ch)

Handling Editor: Gabor G. Toth

Peer-reviewers: Pierre Deharo and Laszlo Gobolos

Compliance Editor: Stefan Simovic

Supplementary Material Editor: Peysh A. Patel

© The Author(s) 2020. Published by Oxford University Press on behalf of the European Society of Cardiology.

This is an Open Access article distributed under the terms of the Creative Commons Attribution Non-Commercial License (<http://creativecommons.org/licenses/by-nc/4.0/>), which permits non-commercial re-use, distribution, and reproduction in any medium, provided the original work is properly cited. For commercial re-use, please contact [journals.permissions@oup.com](mailto:journals.permissions@oup.com)

large aneurysms leading to distal embolization and myocardial infarction (MI), (ii) acute cardiac tamponade following rupture of CAA, and (iii) progressive enlargement and compression of adjacent structures.<sup>7</sup>

Overall, treatment options of CAA include medical management, surgical excision combined with coronary artery bypass grafting (CABG), or PCI. However, due to the lack of evidenced-based recommendations, the optimal timing of CAA treatment in the context of vascular surgery is unknown.

## Timeline

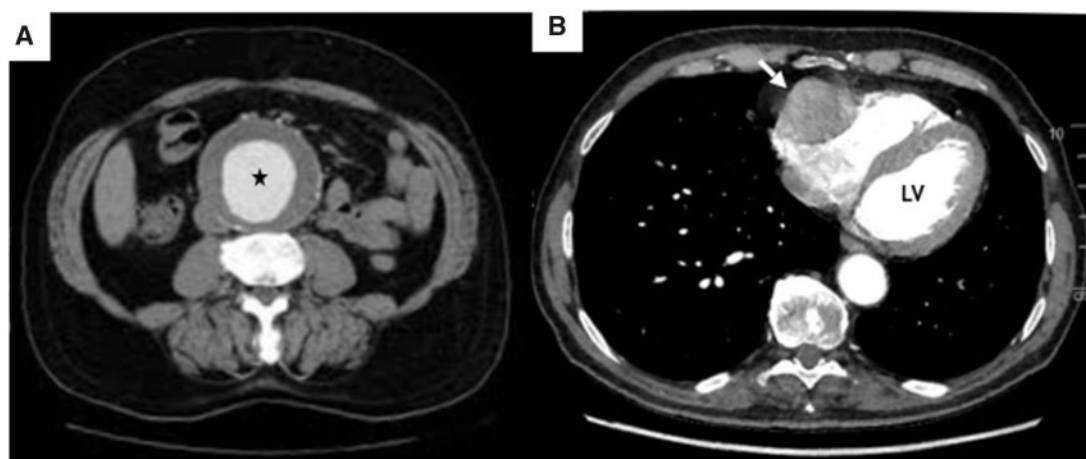
Time	Event
Day 1	Patient was admitted for evaluation of a rapidly expanding abdominal aortic aneurism. Computed tomography angiography revealed a rapidly expanding abdominal aortic aneurism and a giant aneurysm of the right coronary artery.
Day 2	Diagnostic coronary angiogram confirmed the coronary artery aneurysm (CAA) with no evidence of significant parietal thrombus. Ventriculography demonstrated a preserved ejection fraction of 60%.
Day 4	The patient underwent endovascular aortic repair explant and aorto-bi-iliac bypass grafting.
9 months	The patient underwent successful CAA exclusion and coronary artery bypass grafting of the right coronary artery.
10 days post-surgery	Patient was discharged without any complications.

## Case presentation

A 78-year-old caucasian male was referred to our hospital to evaluate expansion of an abdominal aortic aneurysm (AAA) 4 years after endovascular aortic repair (EVAR). At presentation, the patient was suffering from abdominal pain but denied chest pain or dyspnoea. His past medical history includes arterial hypertension, hypercholesterolaemia, and smoking. Initial vital signs were blood pressure 170/87 mmHg, heart rate 97 beats/min, oxygen saturation 97%, respiratory rate 24/min, and temperature 36.5°C. Physical examination did not reveal any abnormal heart or vascular murmurs. Laboratory testing was within normal range.

Computed tomography angiography showed a rapid expansion of the AAA from 62 × 60 mm to 67 × 60 mm in 1 year and up to 69 × 62 mm in the 2 weeks prior to hospitalization, attributed to a type V endoleak (Figure 1A). Computed tomography angiography incidentally revealed a giant CAA of the right coronary artery with cross-sectional diameters up to 5 × 4 cm (Figure 1B). Coronary angiogram confirmed the CAA (Figure 2A) and showed highly significant stenoses at the entrance and the exit of the coronary aneurysm, with good flow (wash-in and wash-out) and no evidence of significant parietal thrombus (Video 1). The left coronary system was ectatic without significant stenosis (Figure 2B). Ventriculography demonstrated a preserved ejection fraction of 60% without regional wall motion abnormalities. Given the patients' age, cardiovascular risk factors and history, an atherosclerotic aetiology was assumed and screening for cerebral aneurysms was not performed.

After interdisciplinary discussion (heart team together with vascular surgeons), the patient underwent urgent EVAR explant and aorto-bi-iliac bypass grafting first (Figure 3). He recovered well from the surgical procedure and had an uneventful postoperative course. In a second step, the CAA was excised, and CABG of the right

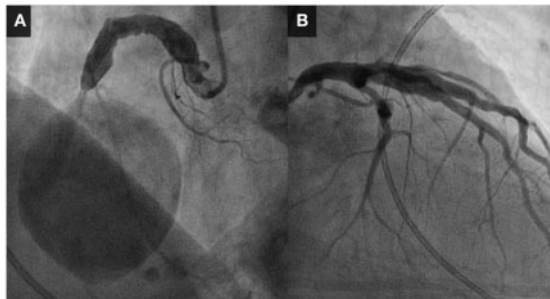


**Figure 1** Computed tomography showing a 5 × 4 cm mass of the right coronary artery (white arrow) and a 6 × 7 cm abdominal aortic aneurism (black star). LV, left ventricle.

coronary artery was performed. Histological analysis of the aneurysmal wall was in line with an atheromatous aetiology of the CAA. Based on the patients' history and the histological analysis, there was no evidence of an underlying systemic disease causing the aneurysms. Sixteen months after surgery, the patient was asymptomatic with good exercise tolerance.

## Discussion

Cardiovascular risk assessment is an important component of the overall management of patients undergoing major vascular surgery. These patients not only have a high prevalence of associated cardiac disease but are also at high risk of major perioperative cardiac events.<sup>8,9</sup>

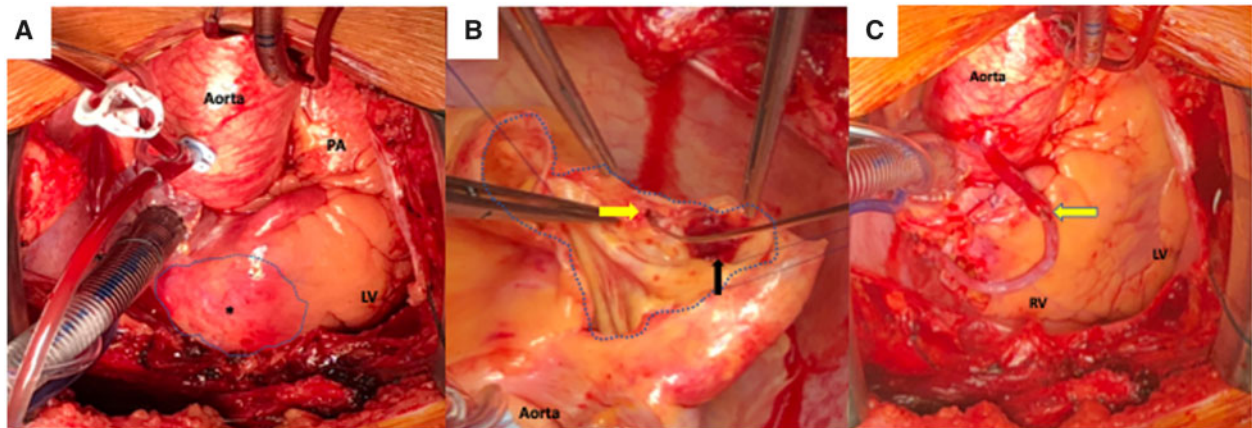


**Figure 2** Coronary angiography showing (A) a giant coronary aneurysm of the right coronary artery and (B) diffuse ectasia of the left coronary arteries.

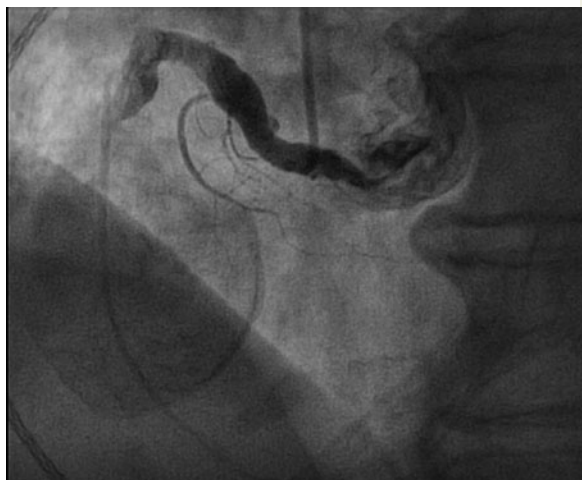The pathophysiology underlying perioperative cardiac events is complex and includes surgical trauma, bleeding, anaemia, hypoxia, haemodynamic changes, and a hypercoagulable state.<sup>10</sup> Despite the strong association between aortic and coronary aneurysm,<sup>11</sup> clinical outcome data of patients with CAA undergoing vascular surgery is lacking. Therefore, little is known about disease progression or prognosis. Nevertheless, distal embolization leading to MI or aneurysms rupture is perioperative risks in patients with CAA, possibly fatal when they occur.

Perioperative management of patients with CAA undergoing vascular surgery, including timing of intervention has not been defined. Based on the results of the Coronary Artery Revascularization Prophylaxis (CARP) trial,<sup>12</sup> prophylactic revascularization in patients with asymptomatic or stable ischaemic heart disease, is not recommended before non-cardiac surgery in contemporary guidelines.<sup>13</sup> However, the risk of CAA-rupture and distal embolization during surgery rather than significant ischaemia due to stenotic coronary artery disease is critical for the decision-making, which is not addressed by current guidelines.

Treatment modality of CAAs should be individualized depending on its morphology, extent and size, as well as associated comorbidities. Both percutaneous and surgical revascularization are associated with technical challenges. The majority of published data following PCI derive from symptomatic patients presenting with acute MI.<sup>14</sup> Although perioperative morbidity after open-heart surgery can be avoided, PCI entails the risk of stent thrombosis, stent migration and distal embolization.<sup>15</sup> Due to the very large size of the CAA and the absence of angina, surgical resection was considered the optimal treatment for our patient.



**Figure 3** (A) Intraoperative view of the CAA (\* and dotted line). (B) Incision of the coronary artery aneurysm. The right coronary artery exits the aneurysm (yellow arrow). Very little thrombotic material in the aneurysmal cavity (black arrow). (C) Final result following exclusion of the coronary artery aneurysm and aortocoronary bypass to the right coronary artery just at the level of the right coronary artery exiting the aneurysm (yellow arrow). LV, left ventricle; PA, pulmonary artery.



**Video 1** Coronary angiography showing a giant coronary aneurysm of the right coronary artery.

## Conclusion

In conclusion, treatment strategy of CAA as well as timing of non-cardiac surgery remains challenging and interdisciplinary discussion of patients is crucial for optimal outcome. In this case, aorto-bi-iliac bypass grafting was safely performed, and the patient underwent successful CAA excision in a second step. The multidisciplinary approach allowed prompt diagnosis, individualized treatment, and a favourable outcome.

## Lead author biography



Sara Schukraft obtained her medical doctor's licence at the University of Geneva in 2016. She began her training in cardiology in the cardiology department of the University and Hospital of Fribourg under the supervision of Prof. Stéphane Cook and Prof. Mario Togni.

## Supplementary material

Supplementary material is available at *European Heart Journal - Case Reports* online.

**Slide sets:** A fully edited slide set detailing this case and suitable for local presentation is available online as [Supplementary data](#).

**Consent:** The author/s confirm that written consent for submission and publication of this case report including image(s) and associated text has been obtained from the patient in line with COPE guidance.

**Conflict of interest:** none declared.

## References

- Cohen P, O'Gara PT. Coronary artery aneurysms: a review of the natural history, pathophysiology, and management. *Cardiol Rev* 2008;**16**:301–304.
- Swaye PS, Fisher LD, Litwin P, Vignola PA, Judkins MP, Kemp HG et al. Aneurysmal coronary artery disease. *Circulation* 1983;**67**:134–138.
- Manginas A, Cokkinos DV. Coronary artery ectasias: imaging, functional assessment and clinical implications. *Eur Heart J* 2006;**27**:1026–1031.
- Scott DH. Aneurysm of the coronary arteries. *Am Heart J* 1948;**36**:403–421.
- Abou Sherif S, Ozden Tok O, Taşköylü Ö, Goktekin O, Kilic ID. Coronary artery aneurysms: a review of the epidemiology, pathophysiology, diagnosis, and treatment. *Front Cardiovasc Med* 2017;**4**:24.
- Nichols L, Lagana S, Parwani A. Coronary artery aneurysms: a review and hypothesis regarding etiology. *Arch Pathol Lab Med* 2008;**132**:823–828.
- Kawsara A, Núñez Gil JJ, Alqahtani F, Moreland J, Rihal CS, Alkhouli M. Management of coronary artery aneurysms. *JACC Cardiovasc Interv* 2018;**11**:1211–1223.
- Hertzer NR, Beven EG, Young JR, O'Hara PJ, Ruschhaupt WF, Graor RA et al. Coronary artery disease in peripheral vascular patients. A classification of 1000 coronary angiograms and results of surgical management. *Ann Surg* 1984;**199**:223–233.
- Ruby ST, Whittemore AD, Couch NP, Collins JJ, Cohn L, Shemin R et al. Coronary artery disease in patients requiring abdominal aortic aneurysm repair. Selective use of a combined operation. *Ann Surg* 1985;**201**:758–764.
- Devereaux PJ, Goldman L, Cook DJ, Gilbert K, Leslie K, Guyatt GH. Perioperative cardiac events in patients undergoing noncardiac surgery: a review of the magnitude of the problem, the pathophysiology of the events and methods to estimate and communicate risk. *CMAJ* 2005;**173**:627–634.
- Balderston JR, Giri J, Kolansky DM, Bavaria JE, Gertz ZM. Coronary artery aneurysms associated with ascending aortic aneurysms and abdominal aortic aneurysms: pathophysiologic implications. *Catheter Cardiovasc Interv* 2015;**85**:961–967.
- McFalls EO, Ward HB, Moritz TE, Goldman S, Krupski WC, Littooy F et al. Coronary-artery revascularization before elective major vascular surgery. *N Engl J Med* 2004;**351**:2795–2804.
- Kristensen SD, Knuuti J, Saraste A, Anker S, Bøtker HE, Hert SD, Authors/Task Force Members. 2014 ESC/ESA Guidelines on non-cardiac surgery: cardiovascular assessment and management: the Joint Task Force on non-cardiac surgery: cardiovascular assessment and management of the European Society of Cardiology (ESC) and the European Society of Anaesthesiology (ESA). *Eur Heart J* 2014;**35**:2383–2431.
- Yip H-K, Chen M-C, Wu C-J, Hang C-L, Hsieh KY-K, Fang C-Y et al. Clinical features and outcome of coronary artery aneurysm in patients with acute myocardial infarction undergoing a primary percutaneous coronary intervention. *Cardiology* 2002;**98**:132–140.
- Ipek G, Gungor B, Karatas MB, Onuk T, Keskin M, Tanik O et al. Risk factors and outcomes in patients with ectatic infarct-related artery who underwent primary percutaneous coronary intervention after ST elevated myocardial infarction. *Catheter Cardiovasc Interv* 2016;**88**:748–753.