

# Importance of Cervical Elongation Assessment for Laparoscopic Sacrocolpopexy

Mikihisa Onigahara, Shintaro Yanazume\*, Takashi Ushiwaka, Shinichi Togami, Masaki Kamio, Hiroaki Kobayashi

Department of Obstetrics and Gynecology, Faculty of Medicine, Kagoshima University, Kagoshima, Japan

## Abstract

Cervical elongation in patients with pelvic organ prolapse (POP), who previously underwent laparoscopic sacrocolpopexy (LSC), is not fully understood. We report a case of a second surgery for endometrial cancer complicated with POP recurrence, which seemed to be related to cervical elongation following LSC. A 65-year-old woman was referred for invasive treatment following LSC. Although preoperative endometrial cytology was negative, the resected uterine specimen revealed endometrioid carcinoma. The patient also had complications of cervical prolapse with cystocele Stage III. Repeat surgery was performed with a trachelectomy, anterior-posterior colporrhaphy, and vaginal apex suspension. Mesh had been adequately sutured to the upper cervix in the previous surgery, and the resected cervix was elongated up to 9 cm. Cervical elongation may be correlated with the inaccurate preoperative endometrial examination, and it may also promote POP recurrence leading to a poorly supported pelvic floor. We suggest that cervical elongation should be identified before POP surgery.

**Keywords:** Cervical elongation, endometrial cancer, laparoscopic sacrocolpopexy, pelvic organ prolapse

## INTRODUCTION

Laparoscopic sacrocolpopexy (LSC) has rapidly become the treatment of choice for pelvic organ prolapse (POP) treatment over the past 20 years; it has shorter operative time, shorter hospital stays, and there is less blood loss when compared to laparotomy.<sup>[1]</sup> The role of cervical elongation in patients with POP following LSC has not been understood to date.

Herein, we report a case of repeat surgery for endometrial cancer complicated with POP recurrence, which seemed to be related to cervical elongation following LSC.

## CASE REPORT

The patient, a 65-year-old woman, 149 cm in height, 47 kg weight, gravida 4, and para 2, was urgently referred to our hospital for invasive treatment of endometrial cancer following LSC treatment for POP. Full informed consent

was obtained from the patient. This study was conducted in accordance with the Declaration of Helsinki (as revised in Fortaleza 2013) and approved by the IRB of Kagoshima University (approval no. 190230).

The patient had visited a gynecological clinic complaining of abdominal discomfort 3 months before being admitted to our hospital. A vaginal pessary for uterine prolapse had been inserted 7 years earlier, which was severely adhered to the vaginal wall and could not be removed. At the time, endometrial cytology was negative, and she was introduced to a urologic clinic for POP surgery. A supracervical hysterectomy, LSC, and perineoplasty were performed. During the operation, the mesh was sutured to the bladder neck with five stitches, and the cervical stump was sutured with three stitches. The other side of the mesh was fixed to

**Address for correspondence:** Dr. Shintaro Yanazume, Department of Obstetrics and Gynecology, Faculty of Medicine, Kagoshima University, 8-35-1 Sakuragaoka, Kagoshima 890-8520, Japan. E-mail: s-yana@m3.kufm.kagoshima-u.ac.jp

### Article History:

**Submitted:** 16 March 2020

**Revised:** 11 August 2020

**Accepted:** 27 August 2020

**Published:** 30 April 2021

### Access this article online

#### Quick Response Code:



**Website:**  
www.e-gmit.com

**DOI:**  
10.4103/GMIT.GMIT\_114\_19

This is an open access journal, and articles are distributed under the terms of the Creative Commons Attribution-NonCommercial-ShareAlike 4.0 License, which allows others to remix, tweak, and build upon the work non-commercially, as long as appropriate credit is given and the new creations are licensed under the identical terms.

**For reprints contact:** WKHLRPMedknow\_reprints@wolterskluwer.com

**How to cite this article:** Onigahara M, Yanazume S, Ushiwaka T, Togami S, Kamio M, Kobayashi H. Importance of cervical elongation assessment for laparoscopic sacrocolpopexy. Gynecol Minim Invasive Ther 2021;10:127-31.

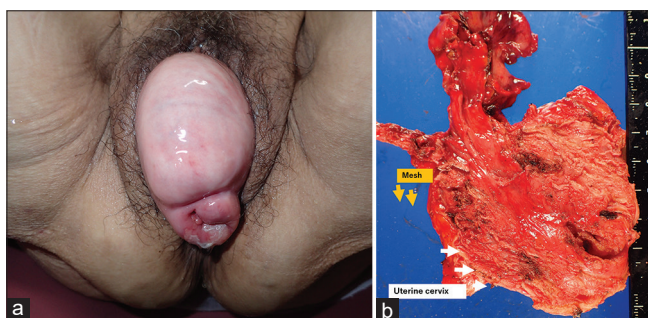
the front of the sacrum with two needles and covered with the peritoneum. Pathological findings of a resected uterine specimen revealed endometrioid carcinoma, Grade 1, and negative vessel permeation. However, the POP relapsed within 2 months following surgery; the vaginal wall was relaxed, and the cervix had re-prolapsed exceeding vaginal introitus, which was complicated with cystocele Stage III [Figure 1a]. At this stage, the patient was referred to our hospital.

Neither distant metastasis nor lymph node swelling was seen using computed tomography. The patient underwent invasive surgery with a simple trachelectomy, bilateral adnexectomy, anterior-posterior colporrhaphy, and vaginal apex suspension and uterosacral ligament suspension and round ligament fixation in laparotomy. Mesh was sutured to the upper cervix and the suture was not frayed; the resected cervix was complicated by cervical elongation up to 9 cm [Figure 1b]. The pathology of a resected specimen did not indicate carcinoma, and washing cytology was negative. Finally, Stage 1A was confirmed, and there was no adjuvant therapy. There were no complications, and no evidence of disease relapse has been reported for 6 months.

## DISCUSSION

In this case, cervical elongation may have made it difficult to perform an accurate preoperative endometrial examination, and cervical suspension alone, as created by the LSC treatment, could not completely support the pelvic floor. Cervical elongation may also have promoted the recurrence of POP.

Endometrial sampling is often used for screening when the presence of endometrial cancer is in doubt, and the diagnostic accuracy is similar to endometrial biopsy.<sup>[2]</sup> In particular, van Hanegem *et al.*,<sup>[3]</sup> reported that the sensitivity of endometrial sampling with dilation and curettage for the diagnosis of endometrial cancer was 100% and 92% for atypical hyperplasia. In the current case, although endometrial



**Figure 1:** (a) The cervix was re-prolapsed, exceeding the vaginal introitus, and also complicated with cystocele. (b) The resected cervix revealed cervical elongation up to 9 cm

sampling took place before the surgery, it is suggested that the biopsy device did not fully reach the endometrial cavity due to cervical elongation.

A list of cases of diagnosed endometrial cancer following POP surgery is shown in Table 1.<sup>[4-8]</sup> Due to incomplete data, the age distribution was not accurately assessed, but it was relatively high. The majority of patients did not show signs of atypical bleeding before surgery; therefore, only four out of 25 patients underwent endometrial examination. Research by Ramm *et al.*,<sup>[6]</sup> included 146 patients who underwent preoperative endometrial examinations and revealed five patients with postoperatively diagnosed uterine malignancies, with three having a negative endometrial biopsy in preoperative work-up. The patients with POP may have had less accurate diagnoses in the preoperative endometrial examinations. On the other hand, Vallabh-Patel *et al.*,<sup>[7]</sup> identified five out of 176 patients with malignancies preoperatively by endometrial biopsy, and none of the remaining patients were diagnosed with malignancies postoperatively. The histology column of Table 1 shows endometrioid carcinoma 1–2 was the most common finding, despite the majority of patients being elderly with higher frequencies of type 2 endometrial cancer. In most cases, the malignancies tended to be at an early stage. Vaginal hysterectomy was performed in most cases in POP surgery, and the uterus was collected trans-vaginally. Only one study collected the uterus by laparoscopic morcellators in a robotic-assisted supracervical hysterectomy. All of the patients underwent one of several types of invasive repeat surgery for endometrial cancer. With the exception of two women with uterine leiomyosarcoma, all patients are alive and clear of disease to date.

Recurrence of POP has been a common reason for repeat surgery following POP initial surgery. DeLancey<sup>[9]</sup> advocates supporting the organization of the vagina divided into three levels. Although complete repair at all levels is an advantage, Level 1 repair is particularly important in apical prolapse. Level 1, which is the upper third of the vagina, is fixed to the pelvic wall by the paracolpium tissue that continues to the cardinal ligament.<sup>[9]</sup> Although the vaginal apex remains well suspended, a lack of the paracolpium Level 1 formation leads to the recurrence of POP. In our case, one of the reasons for POP recurrence may have arisen from the incomplete support of Level 1 that disabled uterine traction to the cranial side – the only remaining entity following Level 1.

Finally, we should consider the malignancies only found in resected uterine specimens, despite an endometrial examination, in POP surgery. POP is commonly repeated due to insufficient Level 1 repairs. Therefore, pelvic floor support may not be completely accomplished solely by performing LSC, especially for patients with cervical elongation.

**Table 1: Reported cases of diagnosed malignancy following uterine prolapse surgery in resected uterine specimens**

Author, years	Age (y)	Number of cases	Atypical bleeding	Preoperative investigation	Prolapse surgery procedure	Collection method	FIGO stage	Histology	Additional treatment	Metastasis	Outcome
Yin <i>et al.</i> , 2003		2/372									
Case 1	NA		NA	NA	NA	NA	1A	Endometrioid ca	NA	None	NA
Case 2	NA		NA	NA	NA	NA	1A	Endometrioid ca, Grade 2	NA	None	NA
Frick <i>et al.</i> , 2010 <sup>[3]</sup>		2/644									
Case 1	NA		-	NA	Hysterectomy	NA	1A	Endometrioid ca, Grade 3	None	NA	NA
Case 2	NA		+	NA	Hysterectomy	NA	1A	Endometrioid ca, Grade 3	None	NA	NA
Renganathan <i>et al.</i> , 2010 <sup>[4]</sup>		4/517									
Case 1	65		-	NA	VH, PFR	Trans-vaginal	1B	Endometrioid ca	None	NA	NA
Case 2	74		-	NA	VH, PFR	Trans-vaginal	1B	Endometrioid ca	None	NA	NA
Case 3	62		-	NA	VH, PFR, and TVT	Trans-vaginal	1A	Endometrioid ca	Laparoscopic BSO	NA	NA
Case 4	71		-	NA	VH, PFR, and TVT	Trans-vaginal	2B	Endometrioid ca	Laparoscopic BSO, PLNDx, and Vault brachytherapy	NA	NA
Ramm <i>et al.</i> , 2012 <sup>[5]</sup>		5/708									
Case 1	71		-	Endometrial biopsy- benign	VH, BSO, and apical suspension	Trans-vaginal	NA	Endometrioid ca, grade 1	None	NA	NED
Case 2	52		-	none	VH, apical suspension	Trans-vaginal	NA	Endometrioid ca, grade 1	None	NA	NED
Case 3	71		-	Endometrial biopsy- benign	VH, BSO, and apical suspension	Trans-vaginal	NA	Endometrioid ca, grade 1	None	NA	NED
Case 4	60		-	Endometrial biopsy- benign	VH, BSO, and apical suspension	Trans-vaginal	NA	Endometrioid ca, grade 2	None	NA	NED
Case 5	55		-	Endometrial stripe	VH, BSO, and apical suspension	Trans-vaginal	NA	Leiomyosarcoma	Laparotomy, CT	NA	DOD at 7 months
WAN <i>et al.</i> , 2013		3/640									
Case 1	NA		-	Endometrial sampling- complex hyperplasia with atypia	VH	Trans-vaginal	1A	Endometrioid ca, grade 1	Laparoscopic BSO	None	Good
Case 2	NA		+	NA	VH	Trans-vaginal	1A	Endometrioid ca, grade 2	None	None	Good
Case 3	NA		+	NA	VH	Trans-vaginal	NA	High-grade leiomyosarcoma	Chemotherapy	Nodal metastasis (PET-CT)	Rec of pelvic mass at 2 years
Grigoriadis <i>et al.</i> , 2015		1/333									

*Contd...*

**Table 1: Contd...**

Author, years	Age (y)	Number of cases	Atypical bleeding	Preoperative investigation	Prolapse surgery procedure	Collection method	FIGO stage	Histology	Additional treatment	Metastasis	Outcome
Case 1	71		-	NA	VH	Trans-vaginal	NA	Squamous cell ca of the uterine cervix	NA	NA	NA
Vallabh-Patel <i>et al.</i> , 2016 <sup>(6)</sup>		4/786									
Case 1	NA		NA	None	Robotic-assisted supracervical hysterectomy	Morcellate	1	Endometrioid ca, grade 1	Laparoscopic BSO	None	Disease-free at >5 years
Case 2	NA		NA	None	Robotic-assisted supracervical hysterectomy	Morcellate	1	Endometrioid ca, grade 1	Trachelectomy, appendectomy	None	Disease-free at >5 years
Case 3	NA		NA	None	Robotic-assisted supracervical hysterectomy	Morcellate	1	Endometrioid ca, Grade 1	Only pelvic ex	None	Disease-free at >5 years
Case 4	NA		NA	None	Robotic-assisted supracervical hysterectomy	Morcellate	NA	Serous carcinoma	Laparoscopic BSO, trachelectomy, partial mesh removal, and CT	NA	Disease-free at >2.5 years
Ackenboom <i>et al.</i> , 2016 <sup>(7)</sup>		3/1196									
Case 1	NA		NA	NA	VH	Trans-vaginal	NA	Endometrioid ca	NA	NA	NA
Case 2	NA		NA	NA	VH	Trans-vaginal	NA	Endometrioid ca	NA	NA	NA
Case 3	NA		NA	NA	VH	Trans-vaginal	NA	Endometrioid ca	NA	NA	NA
Mizrachi <i>et al.</i> , 2017		1/667									
Case 1	65		-	None	VH, PFR	Trans-vaginal	1A	Endometrioid ca, Grade 1	None	NA	Disease-free at >10 years

FIGO: The International Federation of Gynecology and Obstetrics, NA: Not available, BSO: bilateral salpingo-oophorectomy, CT: Chemotherapy, VH: Vaginal hysterectomy, PFR: pelvic floor repair, TVT: Tension-free vaginal tape, PLNDx: Pelvic lymph nodes dissection, NED: No evidence of disease DOD: Died of disease

Cervical elongation may result in uterine malignancies being overlooked preoperatively. It might also be an important factor in the recurrence of POP following LSC treatment and should be identified before the surgery. Further extensive studies are necessary and warranted on the influence of cervical elongation for POP surgery.

### Declaration of patient consent

The authors certify that they have obtained all appropriate patient consent forms. In the form the patient has given her consent for her images and other clinical information to be reported in the journal. The patient understands that her name and initials will not be published and due efforts will be made to conceal the identity, but anonymity cannot be guaranteed.

### Financial support and sponsorship

Nil.

### Conflicts of interest

There are no conflicts of interest.

## REFERENCES

1. Hoshino K, Yoshimura K, Nishimura K, Hachisuga T. How to reduce the operative time of laparoscopic sacrocolpopexy? *Gynecol Minim Invasive Ther* 2017;6:17-9.
2. Visser NC, Reijnen C, Massuger LF, Nagtegaal ID, Bulten J, Pijnenborg JM. Accuracy of endometrial sampling in endometrial carcinoma: A systematic review and meta-analysis. *Obstet Gynecol* 2017;130:803-13.
3. van Hanegem N, Prins MM, Bongers MY, Opmeer BC, Sahota DS, Mol BW, *et al.* The accuracy of endometrial sampling in women with postmenopausal bleeding: A systematic review and meta-analysis. *Eur J Obstet Gynecol Reprod Biol* 2016;197:147-55.
4. Frick AC, Walters MD, Larkin KS, Barber MD. Risk of unanticipated abnormal gynecologic pathology at the time of hysterectomy for uterovaginal prolapse. *Am J Obstet Gynecol* 2010;202:507.e1-4.
5. Renganathan A, Edwards R, Duckett JR. Uterus conserving prolapse surgery – What is the chance of missing a malignancy? *Int Urogynecol J* 2010;21:819-21.
6. Ramm O, Gleason JL, Segal S, Antosh DD, Kenton KS. Utility of preoperative endometrial assessment in asymptomatic women undergoing hysterectomy for pelvic floor dysfunction. *Int Urogynecol J* 2012;23:913-7.
7. Vallabh-Patel V, Saiz C, Salamon C, Francis A, Pagnillo J, Culligan P. Prevalence of occult malignancy within morcellated specimens removed during laparoscopic sacrocolpopexy. *Female Pelvic Med Reconstr Surg* 2016;22:190-3.
8. Ackenbom MF, Giugale LE, Wang Y, Shepherd JP. Incidence of occult uterine pathology in women undergoing hysterectomy with pelvic organ prolapse repair. *Female Pelvic Med Reconstr Surg* 2016;22:332-5.
9. DeLancey JO. Anatomic aspects of vaginal eversion after hysterectomy. *Am J Obstet Gynecol* 1992;166:1717-24.