



RESEARCH ARTICLE

REVISION **Proposed classification for interproximal contacts of primary molars using CBCT: a pilot study [version 2; referees: 2 approved]**

M. Kirthiga ¹, M. S. Muthu ¹, G. Kayalvizhi ², C. Krithika³

¹Department of Pedodontics and Preventive Dentistry, Sri Ramachandra University, Chennai, India

²Department of Pedodontics and Preventive Dentistry, Indira Gandhi Institute of Dental Sciences, Puducherry, India

³Department of Oral Medicine and Radiology, Thai Moogambigai Dental College and Hospital, Chennai, India

v2 First published: 09 Aug 2018, 3:98 (doi: [10.12688/wellcomeopenres.14713.1](https://doi.org/10.12688/wellcomeopenres.14713.1))
Latest published: 27 Sep 2018, 3:98 (doi: [10.12688/wellcomeopenres.14713.2](https://doi.org/10.12688/wellcomeopenres.14713.2))

Abstract

Background: Interproximal contact areas in primary teeth are known to be broader, flatter, and situated more gingivally than in permanent teeth. The objective of the present study was to evaluate the different types of intact interproximal contact areas in primary teeth using cone beam computed tomography (CBCT) among children.

Methods: A cross-sectional study was designed with 74 contacts from 28 existing CBCT images of children aged between 3 and 14 years, obtained from the Indian Dental Education Academy, Chennai, India. The shape of the contact area was observed at three levels, the coronal, middle, and apical thirds, in three different sections of CBCT. Prevalence of the types of contact areas was expressed in the form of numbers and percentages.

Results: The weighted Cohen's kappa values for inter-examiner reliability was 0.893 at baseline. Results exhibited four different types of contact areas between the primary molars, namely, O type, X type, I type, and S type, based on the shapes observed; hence, the proposed classification is referred to as OXIS. The most common pattern seen was I (66.2%), followed by X (21.6%), O (9.4%) and the least common was S (2.7%).

Conclusion: The three-dimensional evaluation of intact interproximal contact areas between primary molars are of four types, O,X, I and S.

Keywords

Computed tomography, proximal contact, primary molars, cross-sectional study

Open Peer Review

Referee Status:

	Invited Referees	
	1	2
version 2 published 27 Sep 2018		
version 1 published 09 Aug 2018	 report	 report

- 1 **Sivakumar Nuvvula** , Narayana Dental College and Hospital, India
- 2 **Manikandan Ekambaram**, University of Otago, New Zealand

Discuss this article

Comments (0)



This article is included in the [Wellcome Trust/DBT India Alliance](#) gateway.

Corresponding author: M. S. Muthu (muthumurugan@gmail.com)

Author roles: **Kirthiga M:** Conceptualization, Data Curation, Formal Analysis, Funding Acquisition, Investigation, Methodology, Project Administration, Resources, Software, Supervision, Visualization, Writing – Original Draft Preparation, Writing – Review & Editing; **Muthu MS:** Conceptualization, Data Curation, Formal Analysis, Funding Acquisition, Investigation, Methodology, Project Administration, Resources, Software, Supervision, Visualization, Writing – Original Draft Preparation, Writing – Review & Editing; **Kayalvizhi G:** Data Curation, Investigation, Methodology, Supervision, Visualization, Writing – Review & Editing; **Krithika C:** Data Curation, Investigation, Methodology, Validation, Writing – Review & Editing

Competing interests: No competing interests were disclosed.

Grant information: This study was supported by a grant from the Wellcome Trust/DBT India Alliance (number 503352) to M.K. *The funders had no role in study design, data collection and analysis, decision to publish, or preparation of the manuscript.*

Copyright: © 2018 Kirthiga M *et al.* This is an open access article distributed under the terms of the [Creative Commons Attribution Licence](https://creativecommons.org/licenses/by/4.0/), which permits unrestricted use, distribution, and reproduction in any medium, provided the original work is properly cited.

How to cite this article: Kirthiga M, Muthu MS, Kayalvizhi G and Krithika C. **Proposed classification for interproximal contacts of primary molars using CBCT: a pilot study [version 2; referees: 2 approved]** Wellcome Open Research 2018, 3:98 (doi: [10.12688/wellcomeopenres.14713.2](https://doi.org/10.12688/wellcomeopenres.14713.2))

First published: 09 Aug 2018, 3:98 (doi: [10.12688/wellcomeopenres.14713.1](https://doi.org/10.12688/wellcomeopenres.14713.1))

REVISED Amendments from Version 1

We thank the reviewers for their comments and suggestions. Taking these into account, in this version (2), we have made the following amendments:

1. The word "patients" in Methods section of abstract has been changed to "children".
2. Scoring of the type of contact in Discussion section has been changed from 1 to 4 to 0 to 3, as in the methods sections and suggested by both the reviewers.
3. As per the authors comments, it has been added as to "why CBCT is not recommended as a routine investigation as well as the special conditions in which it is indicated".
4. In the abstract, the term interproximal has been added to contact areas.
5. "The weighted Cohen's kappa.....at baseline" has been moved to the results part of the abstract.
6. In the introduction section, the phrase "Several pediatric dentistry textbooks have suggested that" has been removed.
7. The sentence "There were two trained.....data collection process" has been changed to "Two trained pediatric dentists (K.M., K.G.) participated in the data collection process".
8. In Paragraph 3, the last few sentences, for the overall scoring criteria, has been changed.
9. The last few lines in the participant section has been rephrased as "The final sample of 28 CBCT images were from 12 girls and 16 boys aged between 3 and 14 years."

See referee reports

Introduction

"Contact area" is a term used to denote the proximal heights of contour of the mesial and distal surfaces of the tooth¹. A well-contoured, properly positioned, firm proximal contact is essential to maintain the integrity of the dental arches and the health of the supporting structures. The contact areas between primary molars are broader, flatter, and situated farther gingivally than the contact points between permanent molars²⁻⁵. Essentially, the broader proximal contact areas observed in primary teeth are likely to increase caries susceptibility, since the self-cleansing action would be reduced because of the limited movement, leading to greater plaque accumulation^{2,6,7}. Previous studies in this regard⁸⁻¹³ have focused mainly on two areas, the association of closed or open contacts with dental caries and the progression of proximal caries. Prior studies^{8,10} concluded that there is an increased risk of proximal caries in the posterior primary dentition if contact points are closed rather than open. Nevertheless, another study¹¹ reported that the absence of interdental spaces is weakly associated with greater caries experience in the primary dentition. In summary, results in the existing literature regarding interproximal spaces and dental caries susceptibility are controversial. Hence, a three-dimensional assessment and a classification of interproximal contacts might facilitate a complete understanding of the relationship of adjoining surfaces of teeth at different levels, namely the coronal, middle, and apical thirds. To the best of our knowledge, no previous study has investigated the three-dimensional shapes of proximal contact areas in primary teeth. Therefore, the present cross-sectional study was undertaken to

evaluate the types of non-carious interproximal contact areas of primary molars in children using existing cone beam computed tomography (CBCT) images.

Methods

Participants

The study protocol was reviewed and approved by the Institutional Ethics Committee, Sri Ramachandra University, Chennai (IEC-NI/16/AUG/55/54). A retrospective study was designed with CBCT images of patients who presented at the Indian Dental Education Academy, Chennai, India for various dental problems between June 2011 and March 2016. After an initial screening of 74 CBCT images selected by means of convenience sampling, 28 images of good quality and with intact primary molars in at least one quadrant were selected. CBCT images of children with special health care needs or teeth with dental caries, restorations, or crowns were excluded from the study. The final sample of 28 CBCT images were from 12 girls and 16 boys aged between 3 and 14 years.

Measurement

Two trained pediatric dentists (K.M., K.G.) participated in the data collection process. The calibration exercise was carried out by an oral and maxillofacial radiologist (K.C.) who regularly conducts hands-on workshops on CBCT assessment and interpretation. Prior to the start of the study, the program consisted of theoretical discussions followed by practical sessions on the evaluation of CBCT images. To check the diagnostic reproducibility of the inter-reliability of the investigators, 10 CBCT images were examined independently by the two aforementioned pediatric dentists. To ensure consistency in measurements, inter-examiner variability was assessed prior to and at the end of the data collection period. The weighted Cohen's kappa value was 0.893 at baseline and 0.931 at the end of the study, which reflected a high degree of conformity in the examination. Any disagreement between the examiners was arbitrated by the subject expert (K.C.) to reach a consensus.

To ensure image standardization, all CBCT images were chosen from a single machine (Planmeca ProMax[®] 3D Mid) with a standard field of view = 80 mm × 80 mm; voxel size of 0.40 mm; 90 kV and 12 mA; exposure time of 12 s; and slice thickness of 0.4 mm. CBCT images were analyzed with the built-in Romexis[®] digital imaging software, version 3.5.2 (Planmeca, Helsinki, Finland), on a 15.6-inch Samsung LCD screen with an Intel[®] Core™ i3 2.4 GHz processor, and 500 GB of memory at a resolution of 1280×1024 pixels in a dark room. The observers evaluated the teeth using the Planmeca Romexis[®] toolbar, by carefully scrolling down through the images from the floor of the pulp chamber in all three orthogonal reconstructions (axial, coronal, and sagittal). The measurement tool was used to determine the total length of the crown of the primary second molar, measured from the tip of the mesiobuccal cusp to the cemento-enamel junction. Based on this length, the crown portion was divided into three levels: coronal, middle and apical thirds. Next, the shapes of the contact areas between the maxillary and mandibular primary molars were examined at various levels, coronal, middle, and apical, and were scored in all three sections (axial, coronal, and sagittal) according to the

criteria shown in [Figure 1](#). Depending on the maximum score among the three levels (the coronal, middle, and apical thirds), the overall score for a particular tooth was assigned. For example, if the scoring of the right maxillary contact between two primary molars was 2 at the coronal third (I shape), 1 at the middle third (X shape), and 0 at the apical third (O shape), then the overall score of this tooth would be the maximum number (that is, 2).

Statistical analysis

Statistical analysis was performed using Microsoft Excel Version 15 (2013). Data was recorded on a custom-made data extraction sheet. Descriptive statistics were obtained for all independent variables. Prevalence of the types of contact areas was expressed in the form of numbers and percentages.

Results

A total of 74 contacts from 28 CBCT images were included in the present study¹⁴, of which 67 (90.5%) were of the closed

type. [Table 1](#) shows the prevalence and percentages of primary contacts according to the arch and the side. Among the different types of contacts ([Figure 2](#)), the most common contact in the maxilla was I (67.4%) and the least was S (4.6%). In the mandible, the most and least common were I (64.5%) and S (0%), respectively. The type of contact area at the occlusal third coincided with the overall score. In addition, 65 contacts had an open contact at the middle and the apical third. The remaining nine contacts had a contact at the occlusal and middle thirds. [Figure 3](#) and [Figure 4](#) show CBCT images of the interproximal contact areas of the primary molars in the maxilla and mandible at the coronal, middle, and apical levels. [Figure 3](#) shows CBCT images of the interproximal contact areas of the primary molars in the maxilla. The (a) coronal, (b) middle, and (c) apical thirds are shown, classified as X, O, and O, respectively. [Figure 4](#) shows CBCT images of the interproximal contact areas of the primary molars in the mandible. The (a) coronal, (b) middle, and (c) apical thirds are shown, classified as X, O, and O, respectively.

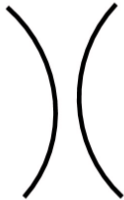

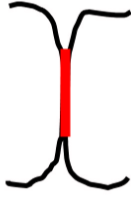
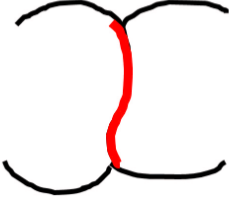
S N	Diagrammatic representation	Criteria	Type of contact	Score
1		When there is no contact between the primary molars.	Open contact	0
2		When there is a point of contact (≤ 1.5 mm) between the primary molars.	X-shaped contact	1
3		When there is a straight contact (≥ 1.5 mm) between the primary molars.	I-shaped contact	2
4		When there is a straight contact (> 1.5 mm) between the primary molars.	S-shaped contact	3

Figure 1. Diagrammatic representation of the type of contact according to the OXIS scoring criteria.

Table 1. Prevalence and percentages of primary contacts according to the arch and side.

Type of contact	Maxilla (n = 43)				Mandible (n = 31)			
	Right side (n = 21)	Left side (n = 22)	%	% closed contacts	Right side (n = 15)	Left side (n = 16)	%	% closed contacts
Open (0)	3	3	13.9	0	1	0	3	0
X (1)	1	5	13.9	16.2	2	8	32.2	33.3
I (2)	15	14	67.4	78.3	12	8	64.5	66.6
S (3)	2	0	4.6	5.4	0	0	0	0

Right side vs left side of maxilla: $\chi^2 = 26.48, P = 0.001 (< 0.05)$. Right side vs left side of mandible: $\chi^2 = 4.33, P = 0.228$.

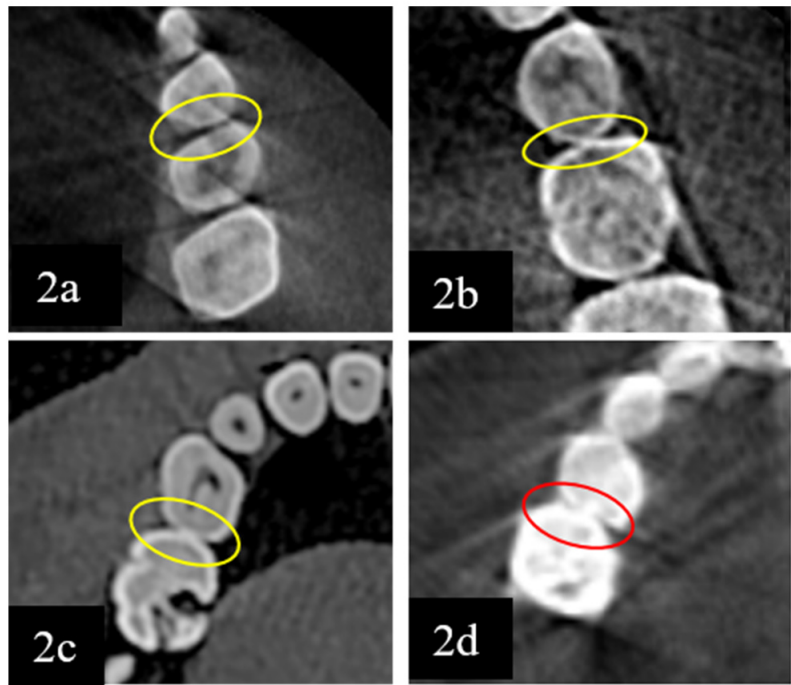


Figure 2. CBCT images showing different types of contact areas between primary molars. (a) O type, (b) X type, (c) I type, and (d) S type.

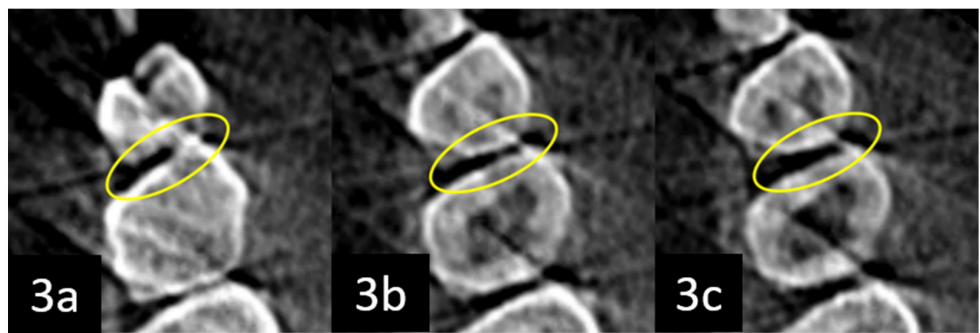


Figure 3. CBCT images of the interproximal contact areas of the primary molars in the maxilla. The (a) coronal, (b) middle, and (c) apical thirds are shown, classified as X, O, and O, respectively.

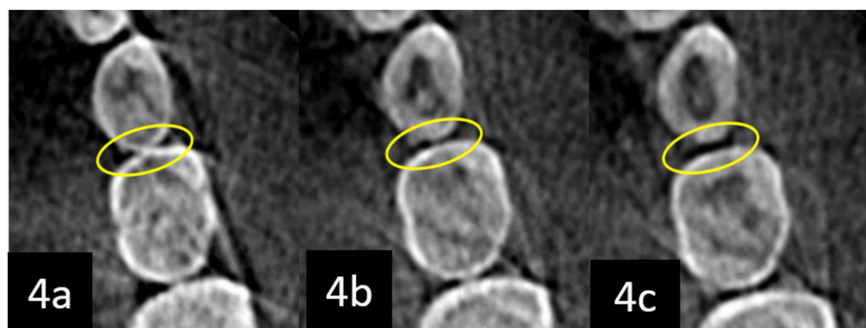

Figure 4. CBCT images of the interproximal contact areas of the primary molars in the mandible. The (a) coronal, (b) middle, and (c) apical thirds are shown, classified as X, O, and O, respectively.

Discussion

The present study used existing multi-planar CBCT scans for the preliminary classification of the contact areas of primary molars in a retrospective manner and is proposed as the OXIS classification. However the prescription of CBCTs is not recommended for the study of contact areas in children. As radiation exposure in children and young people (adolescents) is associated with greater risk of stochastic effects, appropriate use in paediatric dentistry is essential. The most frequent uses of CBCT in children are for impacted supernumerary teeth, disorders in tooth eruption, for temporomandibular joint (TMJ) investigation, localisation of unerupted teeth and the identification of resorption in relation to unerupted teeth¹⁵. The types of proximal contacts between primary molars can be visualized clearly in axial, coronal, and sagittal sections at three different levels, namely the coronal, middle, and apical thirds. The interproximal contacts were named according to the shape in which they were observed. The criteria for scoring at each level for each contact area were as described in the Methods (Figure 1). The scoring according to the numbers 0 to 3 to increase in the surface area of contact between the primary molars. This classification for non-carious interproximal contacts of primary molars based on CBCT observations is proposed as the OXIS classification.

Earlier studies^{8,10,11} used different criteria to determine the nature of the contacts or the spacing between the primary molars. The closed/open nature of the contact point was assessed by passing a dental floss through the interproximal contact point⁸. Of these previous studies, two^{10,11} evaluated tooth spacing in primary teeth on a space-to-space basis based on the following criteria: (i) spacing present >1 mm; (ii) spacing present but <1 mm; (iii) spacing not present, teeth in contact; or (iv) spacing not present, teeth overlapping. These criteria were not used in the present study, since they classified only the open/closed nature and not the specific type of contact. In the present study, 90.5% of the contacts were closed, which was comparable with results reported in previous studies^{8,10}, where 84% and 90% were observed. The number of closed contacts was greater in the maxilla than in the mandible, which again was in accordance with results from a former study¹⁰. Previous studies in this area evaluated the relationship between the closed/open nature

of contact points or spacing between teeth and interproximal caries^{8,10,11}. Their results are in agreement with the concept that the absence of interdental spaces in the primary dentition may alter plaque accumulation and cause difficulty in mechanical cleansing. This could sequentially contribute to increased caries susceptibility. Nevertheless, the specific shape of the contact area has, to our knowledge, not been previously studied. An understanding of the proximal contact area in a three-dimensional manner has increased the need for this to be considered a potential risk factor for caries risk assessment. Another clinical implication is that the change in the type of contact area (open or closed) may also influence the cavity preparation in primary teeth especially in class II preparations.

Two interesting observations were made in the present study. First, in all the contacts studied, the type of contact area at the occlusal third coincided with the overall score, indicating that the contact area existed only at the occlusal third of the tooth surface. Hence, it may be sufficient to observe the occlusal third alone, rather than the three levels. The second observation was that, of the 74 contacts, 65 had an open contact at the middle third, and all the contacts were open at the apical third. This also raises questions regarding existing knowledge²⁻⁵, which states that contact areas between primary molars are broader, flatter, and situated farther gingivally. The small sample size, however, could be seen as a limitation of the present study.

Conclusion

In conclusion, the contact areas vary as four different types, namely Open, X-shaped, I-shaped, and S-shaped; hence, we propose the OXIS classification of primary molars. Further, the three-dimensional evaluation of intact interproximal contact areas between primary molars indicated that the contact area is predominantly present at the occlusal level.

Data availability

Raw data associated with this study, including the images used to assess contact areas and the measurement of contact areas themselves, are available on OSF: <https://doi.org/10.17605/OSF.IO/N2FCE>¹⁴. Data are available under the terms of the Creative Commons Zero “No rights reserved” data waiver (CC0 1.0 Public domain dedication).

Grant information

This study was supported by a grant from the Wellcome Trust/DBT India Alliance (number 503352) to M.K.

The funders had no role in study design, data collection and analysis, decision to publish, or preparation of the manuscript.

Acknowledgements

The authors thank Dr, Umesh Wagdave. MDS, Senior Lecturer, Bharathiya Vidyapeeth University, Pune, for his statistical contributions, and Dr. E. Munirathnam Naidu, Founder of the Indian Dental Education Academy, for his contribution to the CBCT database used in the present study.

References

1. Sturdevant JR: **Clinical significance of dental anatomy, histology, physiology, and occlusion.** Sturdevant's Art and Science of Operative Dentistry. Roberson T, Heyman H, Swift E, 5th edn, Elsevier; 2015; 306.
2. Kennedy DB: **Anatomy of primary and permanent teeth, Pediatric Operative Dentistry.** Kennedy DB, 3rd edn, IOP Publishing Limited; 1986; 37.
3. Mathewson RJ, Primosch RE: **Morphology of the primary teeth, Fundamentals of Pediatric Dentistry.** Mathewson RJ, Primosch RE, 3rd edn, Quintessence Publishing Co; 2014; 197.
4. Muthu MS, Sivakumar N: **Chronology and morphology of primary and permanent teeth, Pediatric Dentistry: Principles and Practice.** Muthu MS, Sivakumar N, 2nd edn. Elsevier; 2011; 33.
[Reference Source](#)
5. Waggoner WF: **Restorative dentistry for the primary dentition.** In: Pediatric Dentistry: Infancy through Adolescence, Casamassimo PS, Fields HW, McTigue DJ, Nowak AJ, 5th edn. Elsevier; 2005; 34.
6. Gohil KS, Talim ST, Singh I: **Proximal contacts in posterior teeth and factors influencing interproximal caries.** *J Prosthet Dent.* 1973; **30**(3): 295–302.
[PubMed Abstract](#) | [Publisher Full Text](#)
7. Sarig R, Vardimon AD, Sussan C, *et al.*: **Pattern of maxillary and mandibular proximal enamel thickness at the contact area of the permanent dentition from first molar to first molar.** *Am J Orthod Dentofacial Orthop.* 2015; **147**(4): 435–44.
[PubMed Abstract](#) | [Publisher Full Text](#)
8. Allison PJ, Schwartz S: **Interproximal contact points and proximal caries in posterior primary teeth.** *Pediatr Dent.* 2003; **25**(4): 334–40.
[PubMed Abstract](#)
9. Parfitt GJ: **Conditions influencing the incidence of occlusal and interstitial caries in children.** *J Dent Child.* 1956; **23**: 31–39.
10. Subramaniam P, Babu KI G, Nagarathna J: **Interdental spacing and dental caries in the primary dentition of 4-6 year old children.** *J Dent (Tehran).* 2012; **9**(3): 207–214.
[PubMed Abstract](#) | [Free Full Text](#)
11. Warren JJ, Slayton RL, Yonezu T, *et al.*: **Interdental spacing and caries in the primary dentition.** *Pediatr Dent.* 2003; **25**(2): 109–113.
[PubMed Abstract](#)
12. Berman DS, Slack GL: **Caries progression and activity in approximal tooth surfaces. A longitudinal study.** *Br Dent J.* 1973; **134**(2): 51–57.
[PubMed Abstract](#) | [Publisher Full Text](#)
13. Dean JA, Barton DH, Vahedi I, *et al.*: **Progression of interproximal caries in the primary dentition.** *Clin Pediatr Dent.* 1997; **22**(1): 59–62.
[PubMed Abstract](#)
14. Muthu MS: **Proposed Classification for Interproximal Contacts of Primary Molars Using CBCT –a Pilot Study.** *Open Science Framework.* 2018.
<http://www.doi.org/10.17605/OSF.IO/N2FCE>
15. Hidalgo-Rivas JA, Theodorakou C, Carmichael F, *et al.*: **Use of cone beam CT in children and young people in three United Kingdom dental hospitals.** *Int J Paediatr Dent.* 2014; **24**(5): 336–48.
[PubMed Abstract](#) | [Publisher Full Text](#)

Open Peer Review

Current Referee Status:  

Version 2

Referee Report 27 September 2018

doi:[10.21956/wellcomeopenres.16184.r34003](https://doi.org/10.21956/wellcomeopenres.16184.r34003)



Sivakumar Nuvvula 

Department of Pedodontics and Preventive Dentistry, Narayana Dental College and Hospital, Nellore, Andhra Pradesh, India

Competing Interests: No competing interests were disclosed.

I have read this submission. I believe that I have an appropriate level of expertise to confirm that it is of an acceptable scientific standard.

Version 1

Referee Report 20 September 2018

doi:[10.21956/wellcomeopenres.16025.r33817](https://doi.org/10.21956/wellcomeopenres.16025.r33817)



Manikandan Ekambaram

Paediatric Dentistry, Faculty of Dentistry, University of Otago, Dunedin, New Zealand

General comments:

It is an interesting study and has clinical relevance. The authors of the study have used CBCT images for examination of the interproximal contact surfaces though this is not a routine practice. However, the CBCT images were previously taken for purposes not related to the present study and therefore, this would not raise any concerns of exposing children to ionizing radiation for the study objective.

Specific comments:

Abstract:

Background: "Contact areas in primary teeth.....teeth" should read as "Interproximal contact areas in primary teeth.....teeth". Similarly, "The objective.....of intact contact areas in primary teeth.....among children" should read as "The objective.....of intact interproximal contact areas in primary teeth.....among children". Methods: Please delete "obtained from the Indian Dental Education Academy,

Chennai, India". The sentence "The weighted Cohen's kappa.....at baseline" should be moved to the results part of the abstract.

Introduction:

Paragraph 1, line number 5 and 6, please delete the phrase "Several pediatric dentistry textbooks have suggested that"

Methods:

Participants:

The last few lines could be rewritten as follows:

The selected CBCT images did not consist images from children with special health care needs or teeth with dental caries, restorations, or crowns. The final sample of 28 CBCT images were from 12 girls and 16 boys aged between 3 and 14 years.

Measurement:

The sentence "There were two trained.....data collection process" should read as "Two trained pediatric dentists (K.M., K.G.) participated in the data collection process".

Paragraph 3, in the last few sentences, for the overall scoring criteria, score 3 for "I" shape, score 2 for "X" shape and score 1 for "O" shape does not match with the scoring criteria mentioned in figure 1.

Table 1

The heading of column 1, should be changed to "Type of contact(score)".

Is the work clearly and accurately presented and does it cite the current literature?

Yes

Is the study design appropriate and is the work technically sound?

Yes

Are sufficient details of methods and analysis provided to allow replication by others?

Yes

If applicable, is the statistical analysis and its interpretation appropriate?

Yes

Are all the source data underlying the results available to ensure full reproducibility?

Yes

Are the conclusions drawn adequately supported by the results?

Yes

Competing Interests: No competing interests were disclosed.

I have read this submission. I believe that I have an appropriate level of expertise to confirm that it is of an acceptable scientific standard.

Referee Report 23 August 2018

doi:10.21956/wellcomeopenres.16025.r33678



Sivakumar Nuvvula 

Department of Pedodontics and Preventive Dentistry, Narayana Dental College and Hospital, Nellore, Andhra Pradesh, India

Good study exploring the areas that were never touched before in Pediatric dentistry, However, there are certain language and typo errors in the abstract as well as the article text. For example: The word "**patients**" in Methods section of abstract can be changed to "**children**". Scoring of the type of contact in **Methods** section (**Figure 1**) is mentioned as **0 to 3**, however, in the **Discussion** part, it is mentioned as **1 to 4**. It should read, 0 to 3 rather than 1 to 4. Furthermore, the second line of the Discussion says, "**However the prescription of CBCTs is not recommended for the study of contact areas in children.**" Authors can add detail on why CBCT is not recommended as a routine investigation as well as the special conditions in which it is indicated.

I have marked the language corrections on the PDF file available [here](#).

Is the work clearly and accurately presented and does it cite the current literature?

Yes

Is the study design appropriate and is the work technically sound?

Yes

Are sufficient details of methods and analysis provided to allow replication by others?

Yes

If applicable, is the statistical analysis and its interpretation appropriate?

Yes

Are all the source data underlying the results available to ensure full reproducibility?

Yes

Are the conclusions drawn adequately supported by the results?

Yes

Competing Interests: Dr. MS Muthu, one of the authors and myself worked together before 2005 and have some common publications as well as edited a textbook for Elsevier, "Pediatric Dentistry, Principles and Practice 2nd Edition released in 2011.

Referee Expertise: Behavioral sciences related to Pediatric dentistry, Developmental anomalies of human dentition, clinical pediatric dentistry

I have read this submission. I believe that I have an appropriate level of expertise to confirm that it is of an acceptable scientific standard.
