

Endoscope-assisted Inguinal Hernia Repair

Saurabh Chawla, MBBS, MS, Pawan Lal, MBBS, MS, DNB, P. K. Ganguly, MBBS, MS,
M. P. Arora, MBBS, MS, N. S. Hadke, MBBS, MS

ABSTRACT

Background: Since the advent of laparoscopic inguinal hernia repair, the procedure has invited numerous controversies, and although the procedure has some definitive advantages, no definitive indications for its use have been formulated. The objective of this study was to investigate a novel method for inguinal hernia repair (through a small 2 cm to 2.5 cm) single skin incision that combines the time-tested fundamentals of Lichtenstein's tension-free repair with the advantages of laparoscopic assistance.

Methods: The study was conducted as a randomized, controlled trial over a 1-year period and included 50 patients. Only patients with simple reducible hernias without associated comorbid conditions were included. The patients were randomized into 2 groups of 25 patients each. One group underwent conventional tension-free meshplasty, while the other group underwent the repair through a single 2-cm to 2.5-cm skin incision with laparoscopic assistance. This repair was carried out with the help of an indigenously designed steel retractor, 10-mm laparoscope, and conventional instruments; the mesh was fixed with the help of endotacks. Univariate analysis of variance techniques using SPSS 7.5 software was used for data analysis.

Results: Two groups were compared for time taken for the procedure, size of skin incision, postoperative pain, complications, return to work, and cosmetic appearance. The results showed a significant decrease in postoperative pain and an earlier return to work, along with much improved cosmesis for the new procedure.

Conclusions: Although the study was conducted with a limited number of patients and a very short follow-up, it is

worth considering this method over laparoscopic and conventional techniques, especially in reducible hernias.

Key Words: Endoscope, Hernia repair.

INTRODUCTION

Inguinal hernia repair is one of the commonest operations performed by the general surgeon.¹ Traditional repairs by McVay, Bassini, and Shouldice involve suturing together tissues that are not normally in apposition, resulting in the reported recurrence rates of up to 21% for primary repair and lengthy, painful postoperative recovery.² Modern herniologists like Lichtenstein advocate no tension repair using prosthetics like plastic polymer meshes, which has been accepted widely as the gold standard today because of low recurrence rates (<1%) and fewer complications.³ With the recent introduction of laparoscopic techniques to the armamentarium of surgeons, minimally invasive procedures have received increased attention from surgeons around the world.

Although laparoscopy generally is a safe procedure and its application to inguinal hernia repair has demonstrated good short-term results, it is technically demanding and has introduced a number of potentially serious problems.⁴ Thus, despite some good early reports and favorable small-scale studies, the prudence of this technique is still in question.⁵

We propose a new endoscope-assisted technique for inguinal hernia repair using a 2.5-cm skin incision, which combines the scientific basis of open hernia repairs with the advantages of the laparoscopic repair. A prospective randomized study was undertaken to evaluate this novel procedure, in comparison with the conventional Lichtenstein hernia repair with respect to pain, complications, cosmesis, postoperative mobilization, and recurrence.

METHODS

The study was conducted in the Department of Surgery, Lady Hardinge Medical College, New Delhi, India over an

Department of Surgery, Lady Hardinge Medical College and Associated Hospitals, New Delhi, India (Drs Chawla, Arora, Hadke).

Maulana Azad Medical College, and Associated Lok Nayak Hospitals, New Delhi, India (Dr Lal).

Dr. Ram Manohar Lohia Hospital, New Delhi, India (Dr Ganguly).

Address reprint requests to: Saurabh Chawla, C/O Pawan Lal, C-63, Preet Vihar, Delhi -110 092, India. E-mail: chawlasaurabh@yahoo.co.in

© 2005 by JSLS, *Journal of the Society of Laparoendoscopic Surgeons*. Published by the Society of Laparoendoscopic Surgeons, Inc.

1-year period. Fifty male patients with simple reducible hernias were included in the study. Regional anaesthesia was used in all patients. Patients were given a single dose of third-generation cephalosporin (cefotaxime, 1gm intravenously) in the perioperative period. The exclusion criteria were patients >60 years of age, patients with a complicated inguinal hernia, and patients with coexisting medical conditions like chronic respiratory and cardiovascular diseases, which might have adversely affected the results in our study.

Fifty consecutive patients who met the inclusion criteria were allocated to either of the 2 groups by an operating room nurse by selecting a sealed envelope defining the procedure (lottery method). The 2 groups were stratified based on age and type of hernia. After informed consent, 1 group underwent conventional tension-free meshplasty, while the other group underwent the endoscope-assisted hernia repair. A special indigenously designed mechanical retractor with separable fins was used for this new procedure. This retractor has to be fixed to the table, with a bracket, and has screws that adjust the height and the width of the fins, thus helping in retraction (**Figures 1 and 2**).

The parameters under study were evaluated during the intraoperative period, the postoperative hospital stay, and during follow-up at 7 days, 6 weeks, and 6 months.

Statistical analysis was done using SPSS 7.5 software (**Table 1**). The various parameters studied and compared were operative time, postoperative pain, hospital stay, time taken to return to work, and cosmetic appearance.

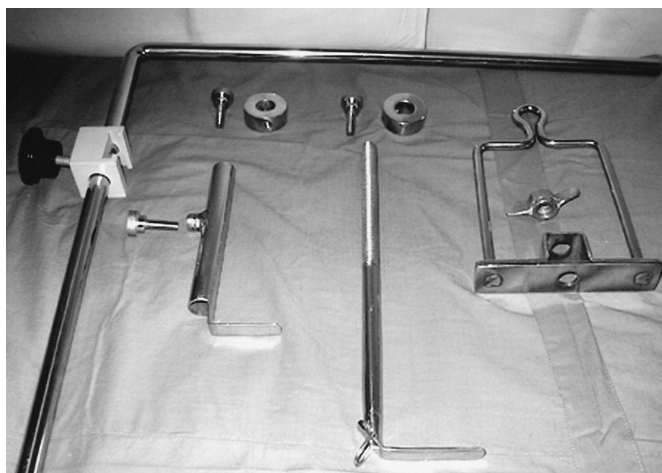

Figure 1. Disassembled apparatus of the mechanical hernia retractor.

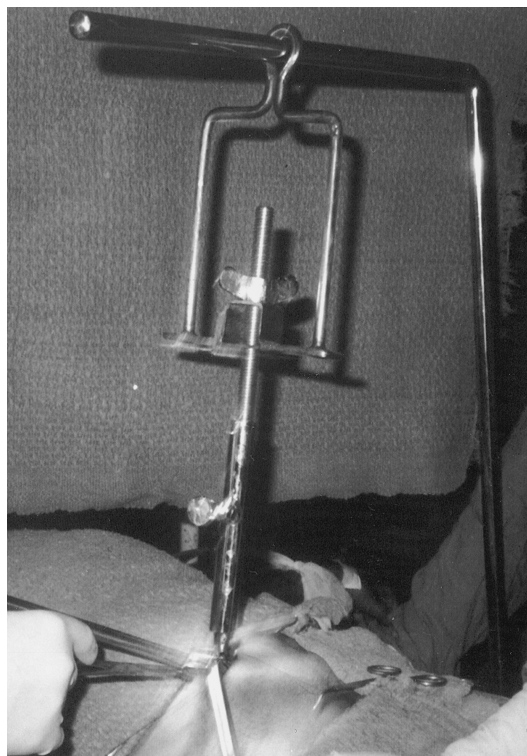


Figure 2. Mechanical hernia retractor assembled and retracting the anterior abdominal wall.

The procedure is performed with the patient under regional anesthesia. The patient is placed in a supine position and draped as for conventional tension-free meshplasty. A 2-cm to 2.5-cm incision is made on the skin at the level of the internal ring. The subcutaneous tissues are dissected till external oblique aponeurosis, and a 1-cm incision is made in it parallel to its fibers. After doing minimal blunt dissection between the spermatic cord and external oblique aponeurosis, a balloon is inserted between the 2 structures and space created till the superficial inguinal ring. Next, the mechanical retractor is placed to elevate the anterior wall of the inguinal canal. A 10-mm laparoscope connected to video imaging equipment is then inserted through the incision, thus allowing a magnified view of the inguinal canal on the video screen.

By using laparoscopic grasping and dissecting instruments, the spermatic cord is mobilized from the floor of the inguinal canal, and a window is then created just below the vas at the level of the pubic tubercle. A tape is passed through the window around the cord, and by using the dissector, the canal is further explored to completely mobilize the cord from the posterior wall and expose the conjoint tendon along its entire length. The spermatic cord is delivered through the skin incision, and

Table 1.
Mean Observations of Study Parameters and Their Statistical Significance

Parameter	Type*	N	Mean	Std Deviation	Std Error Mean	P Value
Age	G1	25	43.5	8.4	1.6	0.964
	G2	25	43.4	10.1	2.0	
Clinical group	G1	25	1.5	.5	.1	0.573
	G2	25	1.6	.4	.9	
Time	G1	25	58.3	9.3	1.8	0.011
	G2	25	52.8	4.1	.8	
Size of incision	G1	25	2.5	.1	3.8	0.000
	G2	25	6.7	.5	.1	
Pain (no. of injections)	G1	25	.7	.7	.1	0.000
	G2	25	2.4	.7	.1	
Pain (post operative day 1)	G1	25	.4	.5	.1	0.000
	G2	25	1.5	.7	.1	
Hospital stay	G1	25	2.0	.0	.0	0.161
	G2	25	2.1	.5	.1	
Time to work	G1	25	9.4	4.0	.8	0.001
	G2	25	13.1	3.2	.6	
Cosmetic appearance	G1	25	1.2	.5	1.0	0.000
	G2	25	1.8	.5	1.0	
Average VALS†	G1	25	3.8	.9	.1	0.00
	G2	25	6.3	1.0	.2	

*G1: endoscope-assisted inguinal hernia repair; G2: Lichtenstein's tension-free inguinal hernia repair.

†VALS=visual analogue linear scale.

an incision is made in the spermatic fascia. The sac is identified and dissected from the cord.

The retractors are then reinserted below the external oblique aponeurosis and spermatic cord for providing exposure to the posterior wall and floor of the inguinal canal. A sheet of monofilament polypropylene mesh measuring 3 in x 6 in (7.6 cm x 15 cm) is inserted into the canal under laparoscopic guidance and anchored under direct vision to pubic tubercle by endotacks, thus securing the mesh medially. A slit is made in the mesh at the level of internal ring, which allows emergence of cord and creates 2 tails that are crossed over and fixed to each other by endotacks, thereby creating a new internal ring. The external oblique and skin are closed in layers.

RESULTS

The mean age of patients in our study was 43.5 years (range, 31 to 60). The mean age of patients in conven-

tional mesh repair was 43.44 years, while the mean age of patients in endoscope-assisted hernia repair was 43.56 years.

Sixty percent of patients in our study had indirect hernias; the ratio of direct to indirect hernia was 2:3. Fifty-eight percent of hernias were right sided.

The average time for conventional mesh repair was 52.84 minutes (range, 48 to 56). The endoscope-assisted repair took an average time of 58.36 minutes (range, 49 to 67)

The postoperative pain was measured by both subjective and objective parameters. Subjectively, the pain was scored by each patient using a visual analogue scale of zero to 10 where zero signified no pain and 10 maximum pain. Objective assessment of pain was done on zero and first postoperative days according to the amount of analgesic requirement. Average subjective pain score for endoscope-assisted hernia repair was 3.8 and that of con-

ventional mesh repair was 6.3 (on a VALS of zero to 10) ($P \leq 0.01$). Objectively, an average dose of 0.72 injections were required for the endoscope-assisted hernia repair group, while patients undergoing conventional mesh repair required 2.4 injections of analgesic (1 injection is of 50 mg of diclofenac) ($P \leq 0.01$).

The study required that the patients remained in the hospital for 48 hours after surgery for postoperative pain monitoring. Only 2 patients in the conventional mesh repair group stayed for 4 days each, for associated minor complications vis-à-vis serous discharge from wound and stitch abscess.

Postoperative complications were divided into early and delayed categories. Early complications were those that occurred in the postoperative period up to 7 days after the operation and included wound or cord hematoma, seroma, serous discharge, stitch abscess, pus discharge, and wound dehiscence. The late complications included sinuses and recurrences. Two patients in each group suffered from early complications (4%). In the endoscope-assisted hernia repair group, these were cord hematoma and wound infection in one patient each, while in the conventional mesh repair group 1 patient had stitch abscess with urinary retention and another developed a serous discharge from the wound. No long-term complications occurred like sinuses and recurrence over a 1-year follow-up period.

We took activities like office going, driving, climbing stairs, and evening walks as endpoints to assess time taken to return to work. Patients in the endoscope-assisted hernia group took a mean of 9.4 days (range, 7 to 21), while patients in the conventional mesh repair group took a mean of 13.1 days (range, 7 to 20) to return to work ($P \leq 0.01$).

The average size of the skin incision was 2.5 cm (range, 2.3 to 3) in the endoscope-assisted group, while the average size of the skin incision in the conventional mesh repair was 6.7 cm (range, 5.5 to 8) ($P \leq 0.01$).

DISCUSSION

The average intraoperative time taken for the surface endoscope repair was 58.36 minutes (range, 49 to 67) as compared with the average time of 52.84 minutes (range, 48 to 56) for the conventional mesh repair. Much variation in the time taken to perform the conventional Lichtenstein's repair has been documented with values ranging from 20 minutes to 90 minutes.⁶⁻⁸ The intraoperative time for conventional mesh repair in our study was similar to

those in other studies.⁶ The new endoscope-assisted repair took slightly more time than the conventional repair, which we attribute to instrument variation and persistence of our learning curve.

Postoperative pain evaluation was done using both objective and subjective criteria. Pain was evaluated on both the day of surgery and the first postoperative day. Our study showed a significant difference in postoperative analgesia requirements between the 2 procedures, with it being significantly more for the Lichtenstein group. On average, 0.72 doses were required for the surface-endoscope group and 2.4 doses for conventional repair on the day of the surgery. Most patients (pts) in the surface-endoscope group required a single dose of analgesic (9 pts, no analgesic; 14 pts, 1 dose; 1 pt, 2 doses; 1 pt, 3 doses) with no patient requiring >3 doses, whereas in the conventional repair group most patients required 2 doses or more (1 pt, no dose; 14 pts, 2 doses; 14 pts, 3 doses). The results in the conventional mesh group repair are similar to those seen in other studies.^{7,9} No data have been published about the postoperative analgesic requirements for the new procedure, but it shows a significant decrease in analgesic requirement. We think the reasons for the same are the smaller skin incision, limited tissue handling, and sharper dissection.

Visual analogue linear scale (VALS) shows an average value of 3.8 for the new procedure and 6.3 for the conventional repair, which coincides with the objective findings.

Postoperative analgesic requirements showed a highly significant difference between the 2 procedures, with 16/25 patients in the surface endoscope group requiring no analgesic as compared with just 3/25 patients in the conventional mesh repair group. On comparison, studies assessing postoperative pain in laparoscopic hernia repair show similar low analgesic requirements.^{6,10}

The study required that the patients remain in the hospital for 48 hours after surgery for postoperative pain monitoring. Only 2 patients in the conventional mesh repair group stayed for 4 days each, for associated minor complications vis-à-vis serous discharge from wound and stitch abscess.

The complications were divided into 2 groups: early and delayed for better documentation. Early complications were those that occurred within 7 days of surgery and included wound or cord hematoma, seroma, serous discharge, stitch abscess, pus discharge, and wound dehiscence. Two patients in both groups (4%) had early complications. In the surface-endoscope group, cord hematoma and wound in-

fection were noted in 1 patient each. In the open hernia group, 1 patient had serous discharge from the wound while another had stitch abscess with urinary retention. Serous discharge represents exudates, most commonly resulting from trauma from the scalpel, scissors, cautery, and foreign bodies (sutures and prosthesis). Since the introduction of the prosthesis, the incidence of this complication has increased from 0% to 17.6%,¹¹ our study has an incidence of 2%. In our study, 1 patient in each group had infection-related complications. This suggests that the procedure did not influence the wound infection.

The late complications included sinuses and recurrences. No late complications were documented in the study. This was perhaps because the study sample was small and the follow-up was limited to less than a year; however, in long-term studies using mesh, recurrences have been noted in 0% to 1.7% patients.¹²

Studies assessing postoperative patient rehabilitation have used various endpoints to measure return to work.¹³ Considering our patient profile, we took time taken to resume normal activities like office going, driving, climbing stairs, and evening walks as endpoints. The patients in the surface-endoscope group took a mean of 9.4 days to return to work, while patients in the conventional hernia group took 13.1 days. This difference was highly significant. These results are remarkably similar to those published in other series, with surface endoscope hernia repair results matching those of laparoscopic hernia surgery, 10 days versus 14 days,⁹ 7.5 days versus 11.8 days,⁶ 9 days versus 17 days.⁸

The cosmetic appearance was to be assessed independently by the patient, staff nurse, and doctor. Most of the patients were satisfied by the surgery as they were interested in relief of the symptoms and the inconvenience. As a consensus, the new procedure was significantly better graded than the open procedure by both the staff nurse and the doctor, as in laparoscopic hernias.⁹

The new technique however is still in its infancy, and long-term studies and follow-up are required for evaluating recurrence.

CONCLUSION

Although the study was conducted with a limited number of patients and a very short follow-up, it is worth consid-

ering this method over laparoscopic and conventional techniques, especially with reducible hernias.

References:

1. Schumpelick P, Treutner K, Arit G. Inguinal hernia repair in adults. *Lancet*. 1994;344:374–378.
2. Abrahamson J. Hernias. In: Zinner MJ, Schwartz SI, Ellis H, eds. *Maingot's Abdominal Operations*. 10th ed. Stamford, CT: Appleton and Lange;1997:479–580.
3. Lichtenstein IL, Shulman AG, Amid PK, et al. The tension free hernioplasty. *Am J Surg*. 1989;157:188–193.
4. Nduka C, Darzi A. Other methods of laparoendoscopic hernia repair: mini hernia –inguinal hernia repair through a 2 cm incision. *Semin Laparosc Surg*. 1998;5(4):248–252.
5. Stoker DL, Spiegelhalter DJ, Singh R, et al. Laparoscopic vs. open inguinal hernia repair: randomized prospective trial. *Lancet*. 1994;343:1243–1245.
6. Brooks DC. A prospective trial of laparoscopic and tension free inguinal herniorrhaphy. *Arch Surg*. 1994;129:361–366.
7. Millikan KW, Doolas A. A prospective comparison of trans-abdominal preperitoneal laparoscopic hernia repair vs. traditional repair in a university setting. *Surg Laparosc Endosc*. 1994; 44:247–253.
8. Payne JH Jr., Griniger LM, Izawa MT, et al. Laparoscopic or open inguinal herniorrhaphy? A randomized prospective trial. *Arch Surg*. 1994;129:973–979.
9. Wilson MS, Deans GT, Brough WA. Prospective trial comparing Lichtenstein with laparoscopic tension free mesh repair of inguinal hernia. *Br J Surg*. 1995;83:274–277.
10. Filipi CJ, Gaston-Johnson F, McBrie PJ, et al. An assessment of pain and return to normal activity: laparoscopic herniorrhaphy vs. open tension free Lichtenstein repair. *Surg Endosc*. 1996;10:983–986.
11. Benedavid R, ed. Seromas and Prosthesis. In: Prosthesis and abdominal wall hernias. Austin, TX: RG Landes Company; 1994: 367–369.
12. Bendavid R. Complications of groin hernia surgery. *Surg Clin North Am*. 1998;78:1089–1102.
13. Rider MA, Baker DM, Locker A, Fawcett AN. Return to work after inguinal hernia repair. *Br J Surg*. 1993;80:745–746.