

Arthroscopic Reduction of Acute Traumatic Posterior Glenohumeral Dislocation and Anatomic Neck Fracture Without Internal Fixation

2-Year Follow-up

Arnaud Godenèche,^{*†} MD, Benjamin Freychet,[†] MD, Stanislas Gunst,[†] MD, Matt Daggett,[‡] DO, MBA, Anthony Viste,[§] MD, PhD, and Gilles Walch,[†] MD

Investigation performed at Hôpital Privé Jean Mermoz, Lyon, France

Keywords: shoulder; fracture; arthroscopy; dislocation

Fracture of the anatomic neck of the humerus is often associated with glenohumeral dislocation. One of the main consequences of anatomic neck fracture is necrosis. Hertel et al² showed that with intra-articular fracture of the humeral head, anatomic neck fracture and concurrent disruption of the medial vascular hinge lead to a high risk of necrosis.

Loofburrow³ was the first, in 1905, to describe a case of an attempted open reduction of a fracture of the anatomic neck. Galanakis et al¹ reported on a posterior glenohumeral dislocation associated with a fracture of the anatomic neck that underwent open reduction and internal fixation. At 10 months, no avascular necrosis was identified on radiographs or magnetic resonance imaging. Varghese et al⁴ were the first, to our knowledge, to report arthroscopic treatment of posterior glenohumeral dislocation associated with a fracture of the anatomic neck using percutaneous screw fixation.

*Address correspondence to Arnaud Godenèche, MD, Centre Orthopédique Santy, 24 Avenue Paul Santy, 69008 Lyon, France (email: godeneche.md@orthosanty.fr).

[†]Ramsay Générale de Santé, Hôpital Privé Jean Mermoz, Centre Orthopédique du Santy, Lyon, France.

[‡]Orthopedic Surgeons Inc, Blue Springs, Missouri, USA.

[§]CHU Lyon Sud, Chirurgie Orthopédique & Traumatologie/Anatomie, Pierre Bénite, France.

The authors declared that they have no conflicts of interest in the authorship and publication of this contribution.

Ethical approval for this study was obtained from Centre Orthopédique du Santy Ethical Committee and Institutional Review Board (study 2017-01).

The Orthopaedic Journal of Sports Medicine, 5(12), 2325967117745486

DOI: 10.1177/2325967117745486

© The Author(s) 2017

We report a clinical case of posterior glenohumeral dislocation with fracture of the anatomic neck reduced arthroscopically and treated without internal fixation.

CLINICAL PRESENTATION

A 40-year-old, right-hand-dominant man sustained trauma to the left shoulder on November 18, 2011, in “a motorbike accident” and presented to the emergency department. Physical examination was limited by pain; however, no concurrent neurovascular injury was identified. Radiographs revealed fractures of the anatomic neck of the humerus associated with grade 3 acromioclavicular joint disruption, as classified by Rockwood (Figure 1). The computed tomography scan revealed the fracture with a displaced, posteriorly oriented portion of the articular surface with a third fragment interposed (Figure 1).

This was the first time that we attempted to treat fracture-dislocation of the anatomic neck of the humerus arthroscopically and the acromioclavicular disruption functionally.

SURGICAL TECHNIQUE

After the induction of general anesthesia without an axillary nerve block, we placed the patient in the beach-chair position and prepared and draped the arm. Fluoroscopic control was used throughout surgery. A 4.5-mm arthroscopic trocar was introduced through the posterior portal (2 cm medial and inferior to the posterolateral corner of the acromion). The posterior dislocation and large osteochondral fragment were discovered immediately. Then,

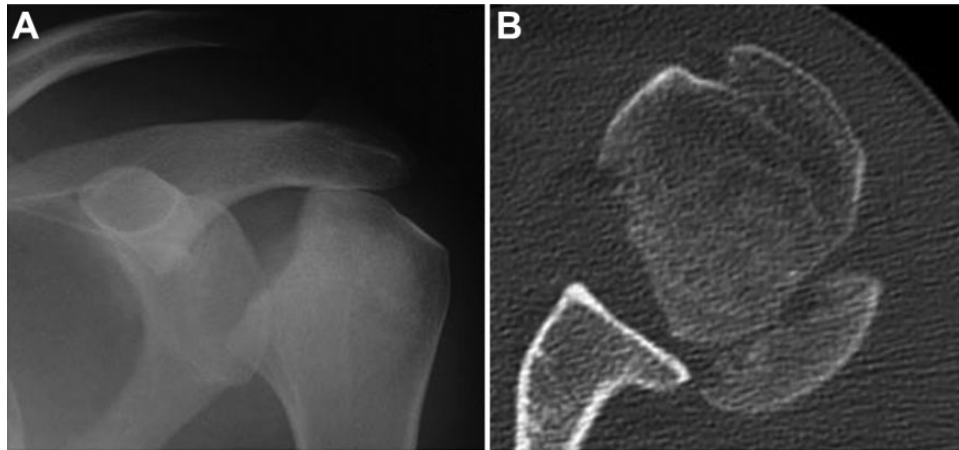


Figure 1. Preoperative (A) radiograph and (B) computed tomography scan.

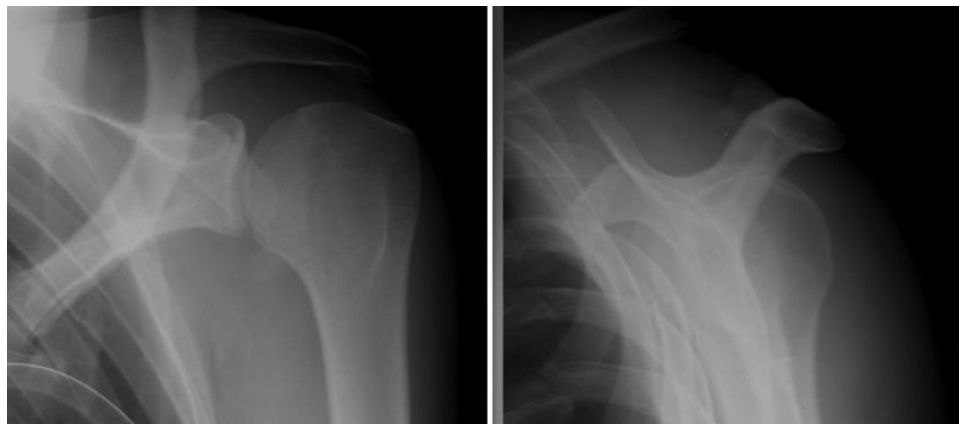


Figure 2. Radiograph at last follow-up.

the arthroscopic trocar was introduced through an anterior portal (above the subscapularis and medial to the biceps). A lateral portal was placed through the rotator cuff, and the fragment was manipulated to its reduction. The third fragment was not reduced with the large fragment but maintained a satisfactory position. We had perfect arthroscopic and radiologic reduction. The fracture was arthroscopically and radiologically stable when we moved the arm; therefore, further fixation was not attempted.

FOLLOW-UP

The patient's arm was immobilized with a sling for 6 weeks. A rehabilitation program consisting of "water therapy" was initiated after 3 weeks. The fracture showed union at 8 weeks. At 10 months, the patient recovered all range of motion, and his acromioclavicular joint disruption gradually increased to grade 5 per the Rockwood classification. At 12 months after surgery, a combined musculotendinous fixation and quarter distal resection of the acromioclavicular joint was performed. At 24

months, the patient had full range of motion, was very satisfied, and returned to work. The subjective shoulder value was 90%, and the Constant score was 90. Radiographic evidence of acromioclavicular joint disruption grade 3 was noted (Figure 2). Radiographs of the humeral head showed union, no sign of avascular necrosis, and no arthrosis (Figure 2).

DISCUSSION

Fracture of the anatomic neck is rare, and when it is associated with glenohumeral dislocation, the risk of necrosis is an important consideration.¹ That is why it is necessary to perform surgery quickly to reduce the dislocation and fracture even if the risk of necrosis is high. Indeed, if surgery is delayed, the humeral head remains posteriorly fixed with posterior capsular distension. This leads to a difficult reduction, a risk of posterior instability for secondary surgery, and a higher rate of necrosis. Although surgery with reduction can lead to necrosis, preservation of the capsulo-ligamentary structure for stability and bone stock is an optimal condition for hemiarthroplasty.

We chose arthroscopic surgical treatment, in contrast to a conventional open approach, to minimize the impact on the humeral head. A more extensive surgical approach is invasive and can affect postreduction stability and potentially increase the risk of necrosis. Arthroscopy maintains the integrity of the capsuloligamentary structures, thus allowing improved glenohumeral stability and ligamentotaxis, which in turn provide primary stability of the fracture of the anatomic neck without the need for fixation. It also maintains vascularization and prevents scar tissue formation, making secondary surgery technically easier if required.

The second issue within this case is the management of acromioclavicular disruption. We chose nonoperative treatment initially to allow for functional, immediate motion. In this case, arthroscopic reduction of the fracture-dislocation allowed for an excellent functional result despite the persistence of disruption. We chose to focus our attention on the presence of the fracture-dislocation initially, as this took clinical precedence. Fixation of the acromioclavicular disruption was subsequently performed but only because of the presence of continued symptoms of the acromioclavicular separation.

Given this type of glenohumeral dislocation with anatomic neck fracture, arthroscopic treatment without

fixation in the presence of intraoperative fracture stability can be performed as the initial treatment with a satisfactory result.

ACKNOWLEDGMENT

The authors are grateful to Mo Saffarini for his assistance with addressing reviewer remarks and in finalizing the manuscript.

REFERENCES

1. Galanakos IA, Kontakis GM, Steriopoulos KA. Posterior dislocation of the shoulder associated with fracture of the humeral anatomic neck. *J Trauma*. 1999;42:1176-1178.
2. Hertel R, Hempfing A, Stiehler M, Leunig M. Predictors of humeral head ischemia after intracapsular fracture of the proximal humerus. *J Shoulder Elbow Surg*. 2004;13:427-433.
3. Loofburrow TL. Fractures of the anatomical neck of the humerus. *Cal State J Med*. 1905;3(5):156-157.
4. Varghese J, Thilak J, Mahajan CV. Arthroscopic treatment of acute traumatic posterior glenohumeral dislocation and anatomic neck fracture. *Arthroscopy*. 2006;22:676.e1-676.e2.