

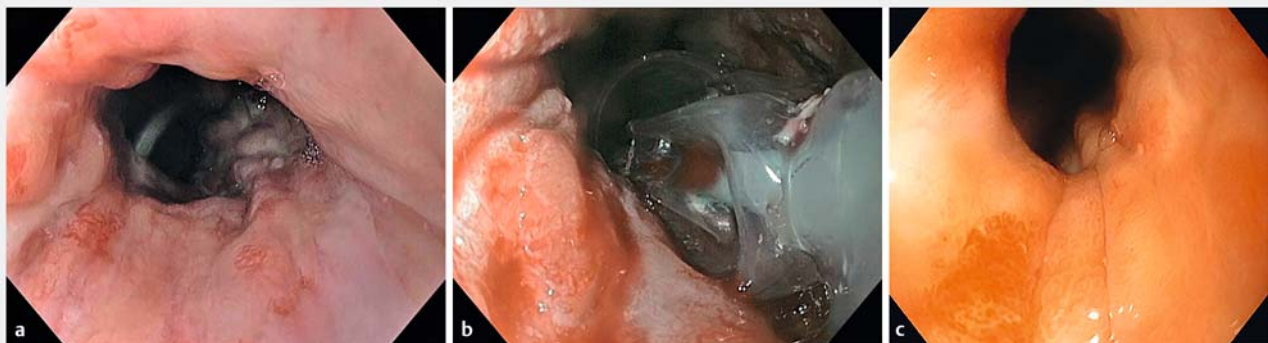
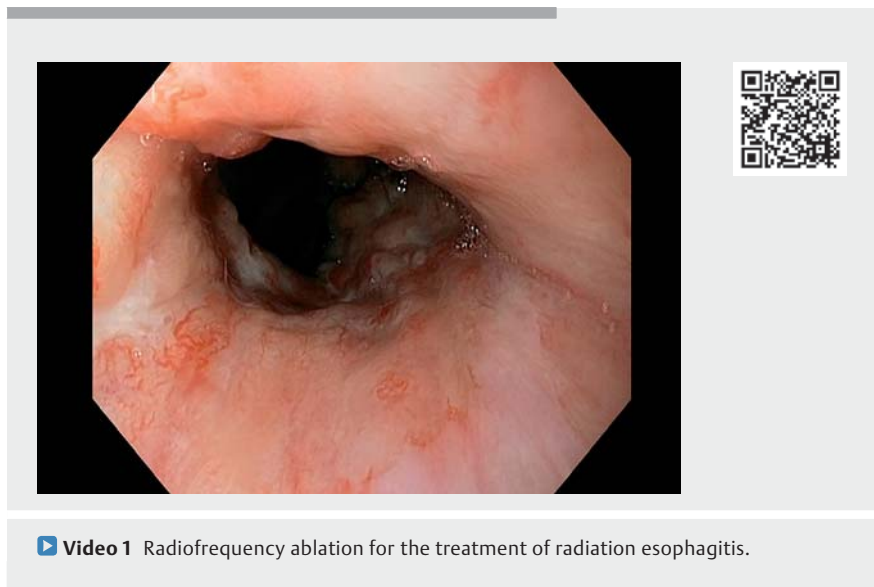
## Successful treatment of hemorrhagic radiation esophagitis with radiofrequency ablation



A 78-year-old man, with a history of T2N0M0 esophageal adenocarcinoma treated with chemoradiotherapy 2 years before, was referred to our department with recurrent upper gastrointestinal bleeding (hemoglobin level of 8.8 g/dl), attributed to radiation esophagitis. He had been admitted three times before for red blood cell transfusion and endoscopic treatment with argon plasma coagulation. Initial esophagogastroduodenoscopy showed diffuse telangiectasias of the lower esophagus and gastroesophageal junction with signs of recent bleeding (► **Fig. 1 a**). Radiofrequency ablation (RFA) of the lower esophagus and gastroesophageal junction was performed using a double 10J/cm<sup>2</sup> ablation with a 360° Express balloon catheter (Medtronic, Minneapolis, Minnesota, USA) (► **Video 1**, ► **Fig. 1 b**), followed by double-dose proton pump inhibitors. Despite no recurrent digestive bleeding, persistent iron deficiency anemia prompted repeat esophagogastroduodenoscopies, including two RFA treatment sessions every 6 months, using a triple 12J/cm<sup>2</sup> RFA application with a focal Halo 90 catheter. The 15-month follow-up esophagogastroduodenoscopy showed a significant regression of the

esophageal telangiectasias (► **Fig. 1 c**). No recurrent bleeding occurred and hemoglobin level remained stable. Radiation esophagitis occurs in up to 42% of patients after radiation therapy for lung, breast, or esophageal carcinomas or mediastinal lymphomas [1]. Whereas acute radiation esophagitis typically presents with self-limiting dysphagia and odynophagia, chronic radiation esophagitis may lead to complications such as

bleeding of esophageal telangiectasias, stenosis, impaired motility or esophago-respiratory fistula. Esophageal telangiectasias are generally managed by argon plasma coagulation (APC). As for other angioectasias occurring elsewhere in the gastrointestinal tract (gastric antral vascular ectasia, radiation proctitis), radiofrequency ablation might be offered as a rescue therapy [2]. To our knowledge, this is the second patient with radiation



► **Fig. 1 a** Initial esophagogastroduodenoscopy showing diffuse telangiectasias and signs of recent bleeding. **b** Radiofrequency ablation of the lower esophagus with a 360° Express balloon catheter. **c** Endoscopic follow-up after three radiofrequency ablation treatment sessions – ablation of the majority of the esophageal telangiectasias.

esophagitis treated with RFA [3], and the first with RFA alone. The favorable long-term evolution suggests that RFA is a feasible, safe, and promising treatment modality for radiation esophagitis with refractory bleeding.

Endoscopy\_UCTN\_Code\_TTT\_1AO\_2AD

## Competing interests

The authors declare that they have no conflict of interest.

## The authors

**Flavius-Stefan Marin<sup>1</sup>, Rachel Hallit<sup>1</sup>, Romain Coriat<sup>1,2</sup>, Stanislas Chaussade<sup>1,2</sup>, Frédéric Prat<sup>2,3</sup>, Maximilien Barret<sup>1,2</sup>**

- 1 Department of Gastroenterology and Digestive Oncology, Cochin Hospital, Assistance Publique – Hôpitaux de Paris, Paris, France
- 2 Université de Paris, Paris, France
- 3 Department of Digestive Endoscopy, Beaujon Hospital, Assistance Publique – Hôpitaux de Paris, Paris, France

## Corresponding author

**Maximilien Barret, MD**

Hôpital Cochin, service de gastro-entérologie et oncologie digestive, 27 Rue du Faubourg Saint Jacques, 75014 Paris, France  
maximilien.barret@aphp.fr

## References

- [1] Afifi A, Powerski M, Jechorek D et al. Radiation-induced damage in the upper gastrointestinal tract: clinical presentation, diagnostic tests and treatment options. *Best Pract Res Clin Gastroenterol* 2020; 48–49: 101711
- [2] Becq A, Camus M, Rahmi G et al. Emerging indications of endoscopic radiofrequency ablation. *United European Gastroenterol J* 2015; 3: 313–324
- [3] Monino L, Garcés-Duran R, Deprez PH et al. Upper gastrointestinal bleeding due to mixed adenoneuroendocrine carcinoma and radiation esophagitis treated with cap-mucosectomy combined with radiofrequency ablation. *Endoscopy* 2021. doi:10.1055/a-1516-3816

## Bibliography

Endoscopy 2022; 54: E830–E831

DOI 10.1055/a-1824-5000

ISSN 0013-726X

published online 13.5.2022

© 2022. The Author(s).

This is an open access article published by Thieme under the terms of the Creative Commons Attribution-NonDerivative-NonCommercial License, permitting copying and reproduction so long as the original work is given appropriate credit. Contents may not be used for commercial purposes, or adapted, remixed, transformed or built upon. (<https://creativecommons.org/licenses/by-nc-nd/4.0/>)

Georg Thieme Verlag KG, Rüdigerstraße 14, 70469 Stuttgart, Germany



## ENDOSCOPY E-VIDEOS

<https://eref.thieme.de/e-videos>



*Endoscopy E-Videos* is an open access online section, reporting on interesting cases and new techniques in gastroenterological endoscopy. All papers include a high quality video and all contributions are freely accessible online. Processing charges apply (currently EUR 375), discounts and wavers acc. to HINARI are available.

This section has its own submission website at <https://mc.manuscriptcentral.com/e-videos>