

Imaging Finding of Malignant Melanoma of Eustachian Tube with Extension to Middle Ear Cavity: Case Report

Hong Chul Kim, MD¹, Han Won Jang, MD², Hui Joong Lee, MD, PhD³

¹Department of Radiology, Yeungnam University College of Medicine, Daegu 705-717, Korea; ²Daekyung Radiologic Clinics, Daegu 706-824, Korea; ³Department of Radiology, Kyungpook National University Hospital, Daegu 700-721, Korea

We report a case of malignant melanoma of Eustachian tube with extension to the middle ear cavity and nasopharynx in a 51-year-old woman who presented with right ear fullness. Computed tomography showed a soft tissue mass in the middle ear cavity and caused the widening and eroding of the bony eustachian tube. Magnetic resonance imaging showed well enhancing mass in eustachian tube extending nasopharynx to middle ear cavity. A biopsy of the middle ear cavity mass revealed a malignant amelanotic melanoma.

Index terms: Melanoma; Middle ear; MRI

INTRODUCTION

Malignant melanoma usually affects the skin, but may also arise from the mucosa. Mucosal melanoma accounts for 1% of all melanoma of the head and neck, with most cases in the nasal and oral cavity. A malignant melanoma in the Eustachian tube is so rare that only 6 cases have been reported until recently (1-5). To the best of our knowledge, there was no report of the computed tomography (CT) and magnetic resonance imaging (MRI) findings of a malignant melanoma in Eustachian tube, which extended to nasopharynx and middle ear cavity simultaneously. Here, we present the magnetic resonance (MR) imaging findings of a primary amelanotic melanoma of the Eustachian tube with

unusual extension.

CASE REPORT

A 51-year-old woman with no significant medical history presented at a local otolaryngologist with right ear fullness. Only chronic otitis media and mastoiditis were diagnosed. On a follow-up examination after treatment, her symptom did not improve and an otorhinolaryngologic examination revealed a dark colored mass behind the tympanic membrane. CT showed a soft tissue mass in the middle ear cavity, which was widening and eroding the bony Eustachian tube (Fig. 1A). MRI revealed an elliptical shaped well-defined mass, located in the Eustachian tube and extending to the orifice in the nasopharynx to the middle ear cavity. The mass showed iso-signal intensity to muscle on T1-weighted image (Fig. 1B, C) and high signal intensity on T2-weighted image with moderate homogeneous enhancement following the administration of contrast material (Fig. 1D, E). Neither an enlarged retropharyngeal node, evidence of head and neck melanoma, or systemic abnormalities was found. A biopsy specimen of the dark colored middle ear cavity revealed a malignant melanoma.

Although, a hematoxylin-esosin stain did not reveal tumor

Received October 10, 2011; accepted after revision December 19, 2011.

Corresponding author: Hui Joong Lee, MD, PhD, Department of Radiology, Kyungpook National University Hospital, 130 Dongdeok-ro, Jung-gu, Daegu 700-721, Korea.

• Tel: (8253) 420-5390 • Fax: (8253) 422-2677

• E-mail: leehuijoong@knu.ac.kr

This is an Open Access article distributed under the terms of the Creative Commons Attribution Non-Commercial License (<http://creativecommons.org/licenses/by-nc/3.0>) which permits unrestricted non-commercial use, distribution, and reproduction in any medium, provided the original work is properly cited.

Malignant Melanoma of Eustachian Tube with Extension to Middle Ear Cavity

cells containing melanin (Fig. 1F), tumor cells were strongly positive for melanoma antibody HMB45 (Fig. 1G), Melan (Fig. 1H), and S-100 on immunohistochemical stainings. Of the

results of the histopathologic study suggest an amelanotic melanoma as the final diagnosis. During her work up, no other primary melanoma was found.

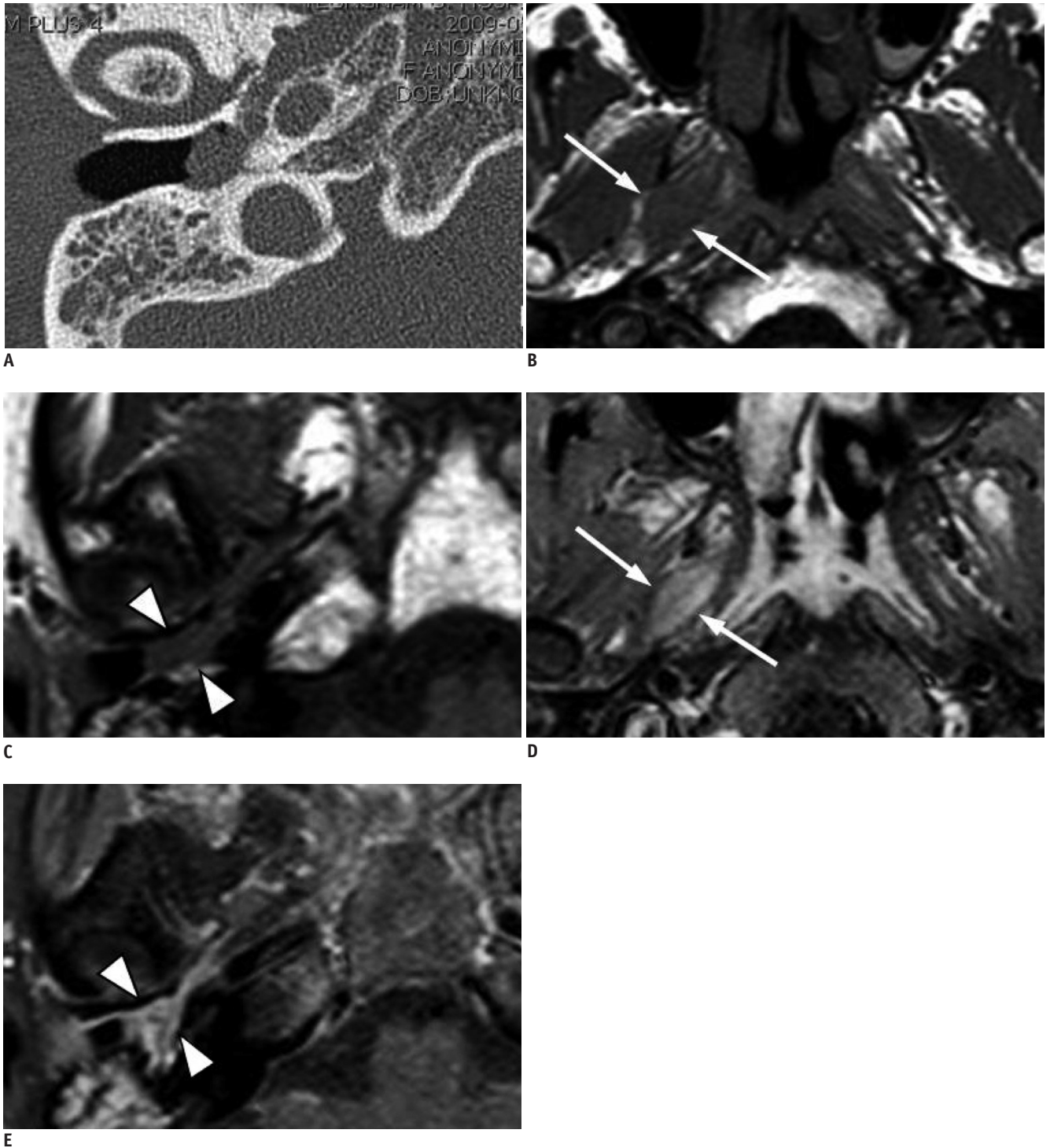


Fig. 1. 51-year-old woman with malignant melanoma of Eustachian tube.

A. Computed tomography of amelanotic melanoma. Soft tissue mass in middle ear cavity is widening and eroding bony Eustachian tube. **B-E.** Magnetic resonance imaging of amelanotic melanoma, which is characterized as elliptical-shaped well defined mass located in Eustachian tube and extending from orifice in nasopharynx (arrows) to middle ear cavity (arrowheads). Mass shows iso-signal intensity to muscle on T1-weighted images (**B, C**), with moderate homogeneous enhancement following administration of contrast material (**D, E**).

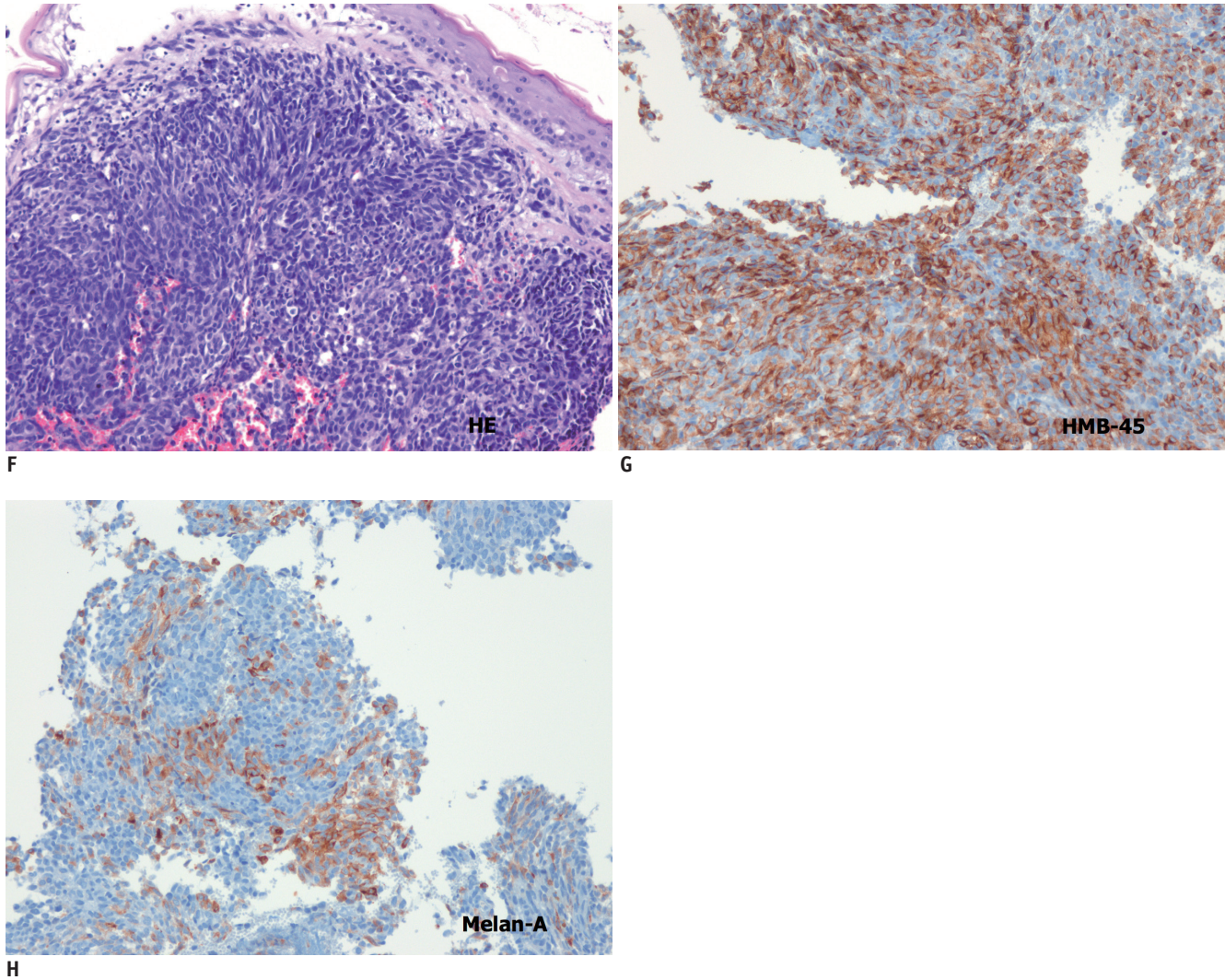


Fig. 1. 51-year-old woman with malignant melanoma of Eustachian tube.

F-H. Histopathological study of amelanotic melanoma. Most cells do not contain melanin (**F**, Hematoxylin-Eosin, original magnification $\times 10$). On immunohistochemical stainings, tumor cells are strongly positive for melanoma antibody HMB45 (**G**) and Melan-A (**H**).

DISCUSSION

Melanoma is composed of a proliferation of melanocytes, which derive from the neural crest and subsequently migrate into the nasal mucosal surface with an ectodermal origin. Mucosal melanomas of the head and neck mostly occur between the fifth and seventh decades of life, with a slight male predominance, equally involving the sinonasal or oral mucosa (6). Unusually, the malignant melanoma can be found in the nasopharyngeal opening of the Eustachian tube (1, 2, 5), restricted to Eustachian tube (4), and extending from the middle ear cavity to the nasopharynx (3). The etiology of mucosal melanoma is still unknown at present (7).

Radiological studies are mandatory for the evaluation

of the middle ear cavity mass. CT is useful to determine the bone change, but it is difficult to make a differential diagnosis by CT alone because bone destruction is negligible and the ossicles are intact in malignant melanoma of the middle ear cavity (8). Moreover, the inferior soft-tissue resolution of CT make the diagnosis more difficult (5). MR imaging is more useful for evaluation of the melanoma in the extension of the tumor and the components of the mass. Even though a physical examination revealed only a middle ear cavity mass, the tumor could extend from the Eustachian tube to the nasopharynx. The signal intensity of the lesion largely depends on the concentration and distribution of melanin in the tumor (9). Characteristic MR imaging findings of high signal intensity on T1-weighted image and low signal intensity on T2-weighted image

are due to higher content of melanin in the tumor (10). Conversely, in cases of an amelanotic melanoma, the signal intensity of the mass can demonstrate low signal intensity on T1-weighted images and high signal intensity on T2-weighted images (8, 11).

In the presenting case, we found the erosion of the bony Eustachian tube on CT and a well demarcated tumor extension on MRI. However, the signal intensity of the tumor did not show the characteristic signal intensity of melanoma, and hence, we can hardly consider the malignant melanoma on MR imaging. In considering the differential diagnoses of the lesion along the Eustachian tube extending from the middle ear cavity and nasopharynx, one should include squamous cell carcinoma, glomus tumor, and lymphoma. Squamous cell carcinoma usually originates from the Rosenmuller fossa and is limited by its cartilaginous portion and pharyngobasilar fascia. It is difficult to find squamous cell carcinoma in the Eustachian tube. A glomus tumor has a unique salt-and-pepper pattern and serpentine flow void with intense enhancement. Lastly, lymphoma may involve the Eustachian tube, but it often shows bulky mass and lymphadenopathy (5, 11, 12).

This case demonstrates an unusual manifestation of a malignant melanoma. One should have to consider the malignant melanoma as a differential diagnosis, if we found the following characteristics: (1) a soft tissue mass in the Eustachian tube extending from the middle ear cavity to the nasopharynx, even if it does not shows typical high signal intensity on T1 weighted image; (2) an erosion of the bony Eustachian tube.

REFERENCES

1. Lai CC, Tsay SH, Ho CY. Malignant melanoma of the eustachian tube. *J Laryngol Otol* 2001;115:567-569
2. Racic G, Kurtovic D, Roje Z, Tomic S, Dogas Z. Primary mucosal melanoma of the eustachian tube. *Eur Arch Otorhinolaryngol* 2004;261:139-142
3. Baek SJ, Song MH, Lim BJ, Lee WS. Mucosal melanoma arising in the eustachian tube. *J Laryngol Otol* 2006;120:E17
4. Tanaka H, Kohno A, Gomi N, Matsueda K, Mitani H, Kawabata K, et al. Malignant mucosal melanoma of the eustachian tube. *Radiat Med* 2008;26:305-308
5. Yang BT, Wang ZC, Xian JF, Chen QH. MR imaging features of primary mucosal melanoma of the eustachian tube: report of 2 cases. *AJNR Am J Neuroradiol* 2009;30:431-433
6. Batsakis JG, Regezi JA, Solomon AR, Rice DH. The pathology of head and neck tumors: mucosal melanomas, part 13. *Head Neck Surg* 1982;4:404-418
7. Snow GB, van der Waal I. Mucosal melanomas of the head and neck. *Otolaryngol Clin North Am* 1986;19:537-547
8. Uchida M, Matsunami T. Malignant amelanotic melanoma of the middle ear. *Arch Otolaryngol Head Neck Surg* 2001;127:1126-1128
9. Isiklar I, Leeds NE, Fuller GN, Kumar AJ. Intracranial metastatic melanoma: correlation between MR imaging characteristics and melanin content. *AJR Am J Roentgenol* 1995;165:1503-1512
10. Yousem DM, Li C, Montone KT, Montgomery L, Loevner LA, Rao V, et al. Primary malignant melanoma of the sinonasal cavity: MR imaging evaluation. *Radiographics* 1996;16:1101-1110
11. Hirunpat S, Riabroi K, Dechsukhum C, Atchariyasathian V, Tanomkiat W. Nasopharyngeal extension of glomus tympanicum: an unusual clinical and imaging manifestation. *AJNR Am J Neuroradiol* 2006;27:1820-1822
12. Lum C, Keller AM, Kassel E, Blend R, Waldron J, Rutka J. Unusual eustachian tube mass: glomus tympanicum. *AJNR Am J Neuroradiol* 2001;22:508-509