

# Immunoglobulin G4-Related Retroperitoneal Fibrosis Treated with Hochuekkito, a Kampo Medicine, following Steroid Treatment

Minoru Fukuchi<sup>a</sup> Shinji Sakurai<sup>b</sup> Toshiaki Kogure<sup>c</sup> Hiroshi Naitoh<sup>a</sup>  
Hiroyuki Kuwano<sup>d</sup>

Departments of <sup>a</sup>Surgery, <sup>b</sup>Diagnostic Pathology and <sup>c</sup>Japanese Oriental Medicine, Gunma Chuo Hospital, and <sup>d</sup>Department of General Surgical Science, Gunma University Graduate School of Medicine, Maebashi, Japan

## Key Words

IgG4-related retroperitoneal fibrosis · Hochuekkito · Steroid

## Abstract

We report a case of immunoglobulin G4 (IgG4)-related retroperitoneal fibrosis (RF) with complete remission and no relapses after therapy with steroids and Hochuekkito, a Kampo (i.e. traditional Japanese herbal) medicine. A 62-year-old Japanese man was admitted to our hospital for treatment of a retroperitoneal mass detected by computed tomography. The mass had a maximum diameter of 11.0 cm; it involved the left ureter and was associated with left hydronephrosis. After inserting a ureteral stent, we performed a biopsy by laparotomy. Histopathology revealed IgG4-related RF. The lesion disappeared after 7 months of steroid therapy. We subsequently used Hochuekkito as an alternative maintenance treatment because of steroid-related complications. The patient has not relapsed in the 3 years since starting the medication. To the best of our knowledge, this is the first case of IgG4-related RF treated with Hochuekkito as a maintenance treatment.

© 2014 S. Karger AG, Basel

## Introduction

Retroperitoneal fibrosis (RF) is a rare disease characterized by the development of peritoneal inflammation and fibrosis, which often cause entrapment of the ureters [1]. RF

Minoru Fukuchi, MD  
Department of Surgery  
Gunma Chuo Hospital  
1-7-13 Kouun-cho, Maebashi, Gunma 371-0025 (Japan)  
E-Mail [mfukuchi@saitama-med.ac.jp](mailto:mfukuchi@saitama-med.ac.jp)

can be either idiopathic or secondary. The recently advocated concept of immunoglobulin G4 (IgG4)-related disease, derived from research on autoimmune pancreatitis (AIP), and the associated diagnostic criteria have led to the widespread recognition of RF as a condition caused by IgG4-related disease [1].

RF can occur for other reasons or with other IgG4-related diseases, including AIP [2, 3]. Thus, the IgG4 assay is recommended to diagnose RF. High serum IgG4 levels should be viewed as a marker of IgG4-related disease [4]. The first line of treatment for RF, regardless of its cause, is standard steroid therapy as used for AIP [1, 4]. The response to steroid therapy is generally favorable. However, steroid-related complications often occur because of the 1- to 3-year treatment duration [4].

We present the first case of RF treated with Hochuekkito maintenance treatment, a Kampo (i.e. traditional Japanese herbal) medicine, selected because of the side effects of steroid therapy (such as impaired glucose tolerance). In this case, complete remission occurred and the patient has not relapsed in the 3 years since initially starting steroid therapy.

## Case Report

A 62-year-old Japanese man was admitted to our hospital for left back pain in November 2010. He had no medical history of allergic or autoimmune diseases. On admission, his back pain was unchanged by percussion. Serum biochemistry showed elevated levels of creatinine (1.47 mg/dl, normal range 0.60–1.10), soluble interleukin-2 receptor (1,130.0 U/ml, normal range 145.0–519.0), and IgG-4 (290 mg/dl, normal range 4.8–105.0). Abdominal computed tomography (CT) indicated a solitary soft tissue density mass of 4.5 × 6.0 × 11.0 cm in diameter located in the retroperitoneal space around the abdominal aorta; the mass involved the left ureter and was associated with left hydronephrosis (fig. 1a–c).

The patient first underwent the insertion of a ureteral stent for treatment of the left hydronephrosis. For the definite diagnosis of this lesion, we performed a biopsy by laparotomy through a small incision in December 2010. Histopathology revealed that the lesion was composed of abundant fibrosis with infiltrating lymphocytes and plasma cells not exhibiting nuclear atypia (fig. 2a). Elastica van Gieson staining demonstrated obliterative phlebitis (fig. 2b). Many IgG4-positive plasma cells (>70 counts per high power field) were observed with immunohistochemistry (fig. 2c). The ratio of IgG4-positive to IgG-positive cells was 41:100 (fig. 2c, d). The final diagnosis was IgG4-related RF.

The patient received steroid therapy starting in January 2011. The initial dose of oral prednisolone was 30 mg/day, and the dose was tapered by 5 mg every 2 weeks; the maintenance dose was 5 mg. Six months following his initial administration, the patient experienced steroid-related complications including impaired glucose tolerance and edema, and oral antidiabetic medication was initiated.

CT revealed a gradual decrease in the size of the lesion, with disappearance after 7 months of steroid therapy (fig. 1d, e). At this time, the ureteral stent was removed. Maintenance steroid treatment was also stopped at this time because the patient hoped to escape the steroid-related complications in addition to obtaining complete remission. After consulting with our hospital's Department of Japanese Oriental Medicine, we started a 1.5-year course of Hochuekkito, a Kampo medicine, as an alternate maintenance treatment. At 3 years following the initiation of medical treatment, the patient was doing well, his steroid-related complications had improved, and he had not experienced a relapse.

## Discussion

RF was first reported by Ormond in 1948 and has since been widely documented [5]. When all identifiable causes are excluded, the condition is labeled idiopathic RF [1]. Some cases of idiopathic RF involve other idiopathic sclerosing lesions, a condition that has been referred to as multifocal fibrosclerosis in the past [6]. Based on recent studies of AIP, a new entity of IgG4-related systematic disease has been proposed [3, 7, 8]. Accordingly, multifocal fibrosclerosis is now considered an IgG4-related disease [3]. Some individual cases and several case series of RF without obvious manifestations of AIP have been reported [9, 10]. In the present case, only the retroperitoneal space was observed to be affected, and no other sclerosing lesions were identified.

Currently, a definitive diagnosis of IgG4-related RF is based on the fulfillment of the following 3 criteria [7]: (1) soft tissue masses surrounding the aorta and/or adjacent tissues on CT and/or magnetic resonance imaging, (2) elevation of serum IgG4 levels ( $\geq 135$  mg/dl), and (3) infiltration with IgG4-positive plasma cells ( $>10$  IgG4-positive plasma cells per high power field and a ratio of IgG4-positive to IgG-positive cells of  $>40:100$ ). Our case met these criteria for the diagnosis of IgG4-related RF.

There are some considerations to take into account regarding these criteria. With regard to the radiological criterion, soft tissue masses located in the renal hilus frequently involve the ureter. Such masses evoke hydronephrosis and are sometimes misdiagnosed as urinary tumors. Other retroperitoneal masses such as malignant lymphomas and metastatic tumors may also be present. With regard to the histological criterion, histological findings from sites other than the retroperitoneal mass can be used, as performing biopsies of such masses is usually difficult [10]. Although our patient's mass was confined to the retroperitoneal space, we were able to biopsy the mass via minimal laparotomy and confirm the histological criterion.

Steroid therapy is recognized as a standard treatment for AIP [4]. The indications for steroid use are symptoms such as obstructive jaundice due to sclerosing cholangitis, abdominal pain, and hydronephrosis due to associated RF. Therefore, steroid therapy is also strongly recommended for patients with IgG4-related RF. Standard steroid treatment consists of an initial dose of 0.6 mg/kg/day of oral prednisolone, which is reduced to a maintenance dose (5 mg/day) over a period of 3–6 months. To prevent relapse, maintenance treatment for 6 months to 3 years is recommended [4]. In most cases, the pancreatic lesion or RF improves after initial treatment. However, relapse can occur after steroid withdrawal in some cases [11]. Our patient received standard steroid treatment resulting in complete remission 7 months after starting medication. However, maintenance treatment was stopped because of steroid-related complications such as impaired glucose tolerance.

As an alternative to standard maintenance treatment, we treated this patient with Hochuekkito, which potentiated the immunomodulatory effect for 1.5 years, resulting in maintenance of remission for 3 years after medication was first initiated. Hochuekkito is a type of Kampo (i.e. traditional Japanese herbal) medicine, and it has been used to improve the weakened physical condition of patients with various chronic diseases. Moreover, Hochuekkito has been reported to exhibit beneficial pharmacological immune activity [12, 13] while suppressing the inflammatory response [14]. A recent study suggests that the preoperative administration of Hochuekkito can prevent an excessive postoperative inflammatory response and prolonged postoperative immunosuppression [15]. We used Hochuekkito in this patient with IgG4-related RF as an alternative maintenance treatment to suppress the inflammatory response with fewer side effects than steroids. However,

Fukuchi et al.: Immunoglobulin G4-Related Retroperitoneal Fibrosis Treated with Hochuekkito, a Kampo Medicine, following Steroid Treatment

numerous questions remain regarding the details of Hochuekkito's mechanism of action on the immune system.

In conclusion, we report a rare case of IgG4-related RF with complete remission after steroid therapy. Hochuekkito, a Kampo medicine associated with immunomodulation, was used as a maintenance treatment with few side effects, allowing the patient to escape steroid-related complications. However, prospective studies are needed to clarify the details of the effect of Hochuekkito on IgG4-related disease.

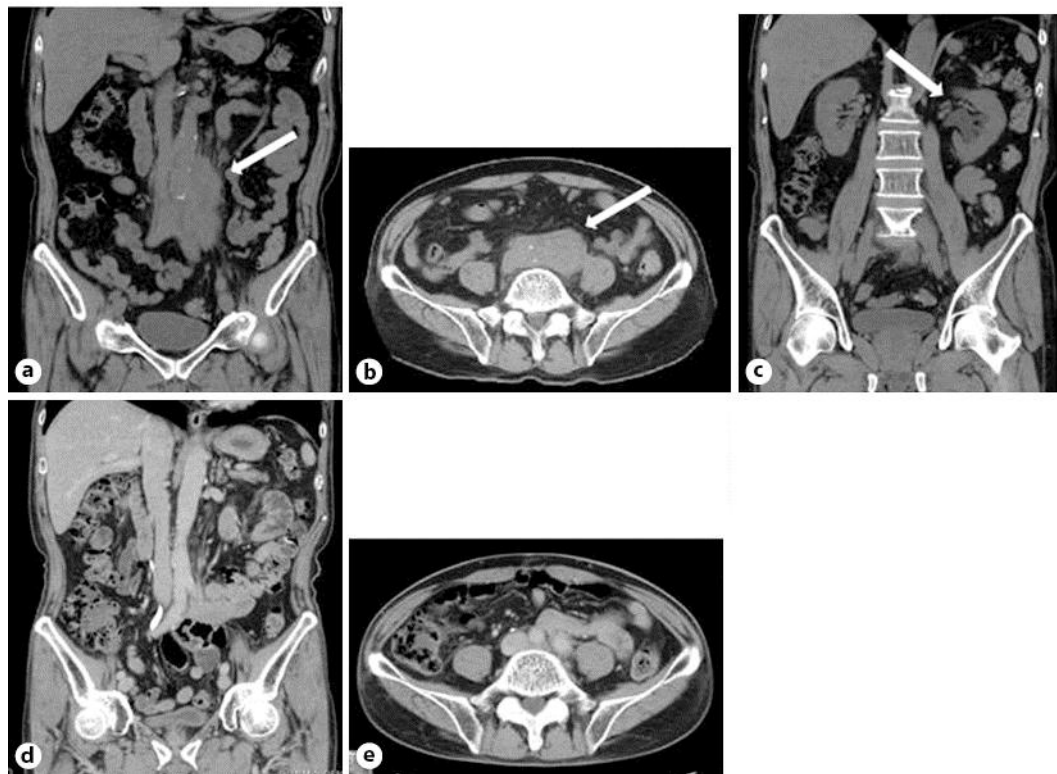
### Disclosure Statement

The authors have no conflicts of interest.

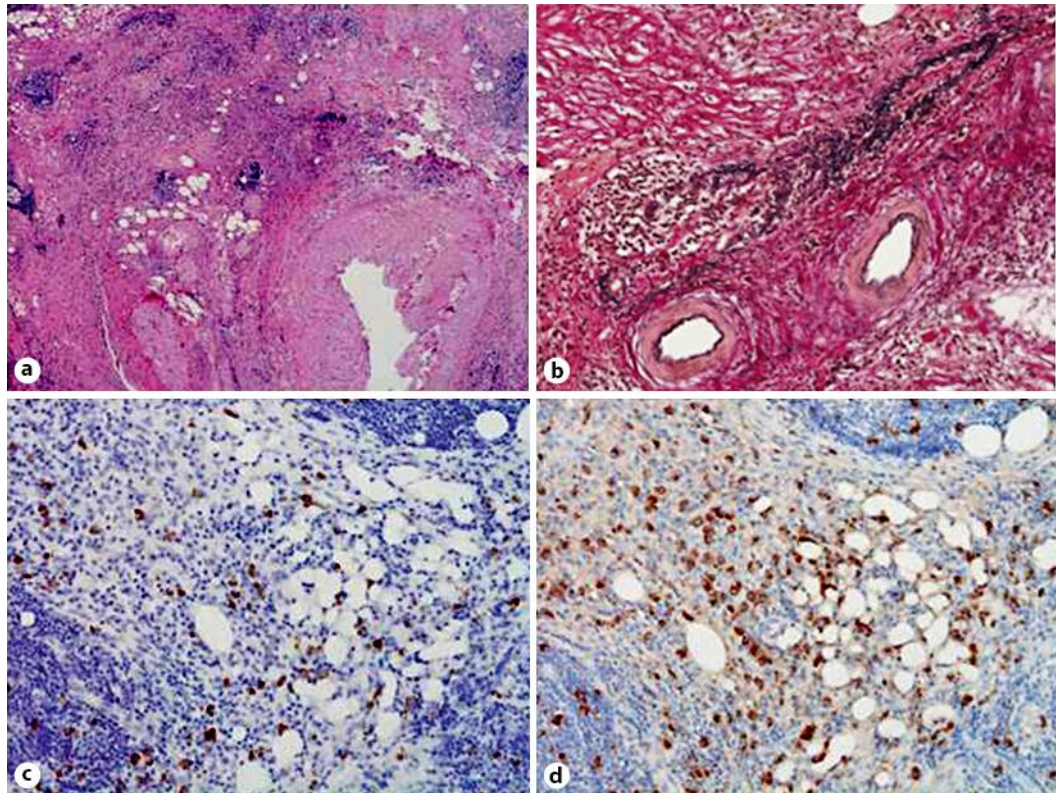
### References

- 1 Vaglio A, Salvarani C, Buzio C: Retroperitoneal fibrosis. *Lancet* 2006;367:241–251.
- 2 Kamisawa T, Nakajima H, Egawa N, Funata N, Tsuruta K, Okamoto A: IgG4-related sclerosing disease incorporating sclerosing pancreatitis, cholangitis, sialadenitis and retroperitoneal fibrosis with lymphadenopathy. *Pancreatol* 2006;6:132–137.
- 3 Kamisawa T, Takuma K, Egawa N, Tsuruta K, Sasaki T: Autoimmune pancreatitis and IgG4-related sclerosing disease. *Nat Rev Gastroenterol Hepatol* 2010;7:401–409.
- 4 Kamisawa T, Shimosegawa T, Okazaki K, Nishino T, Watanabe H, Kanno A, Okumura F, Nishikawa T, Kobayashi K, Ichiya T, Takatori H, Yamakita K, Kubota K, Hamano H, Okamura K, Hirano K, Ito T, Ko SB, Omata M: Standard steroid treatment for autoimmune pancreatitis. *Gut* 2009;58:1504–1507.
- 5 Ormond JK: Bilateral ureteral obstruction due to envelopment and compression by an inflammatory retroperitoneal process. *J Urol* 1948;59:1072–1079.
- 6 Comings DE, Skubi KB, Van Eyes J, Motulsky AG: Familial multifocal fibrosclerosis. *Ann Intern Med* 1967;66:884–892.
- 7 Umehara H, Okazaki K, Masaki Y, Kawano M, Yamamoto M, Saeki T, Matsui S, Yoshino T, Nakamura S, Kawa S, Hamano H, Kamisawa T, Shimosegawa T, Shimatsu A, Nakamura S, Ito T, Notohara K, Sumida T, Tanaka Y, Mimori T, Chiba T, Mishima M, Hibi T, Tsubouchi H, Inui K, Ohara H: Comprehensive diagnostic criteria for IgG4-related disease (IgG4-RD), 2011. *Mod Rheumatol* 2012;22:21–30.
- 8 Stone JH, Khosroshahi A, Deshpande V, et al: Recommendations for the nomenclature of IgG4-related disease and its individual organ system manifestations. *Arthritis Rheum* 2012;64:3061–3067.
- 9 Zen Y, Onodera M, Inoue D, Kitao A, Matsui O, Nohara T, Namiki M, Kasashima S, Kawashima A, Matsumoto Y, Katayanagi K, Murata T, Ishizawa S, Hosaka N, Kuriki K, Nakanuma Y: Retroperitoneal fibrosis: a clinicopathologic study with respect to immunoglobulin G4. *Am J Surg Pathol* 2009;33:1833–1839.
- 10 Chiba K, Kamisawa T, Tabata T, Hara S, Kuruma S, Fujiwara T, Kuwata G, Egashira H, Koizumi K, Koizumi S, Fujiwara J, Arakawa T, Momma K, Setoguchi K, Shinohara M: Clinical features of 10 patients with IgG4-related retroperitoneal fibrosis. *Intern Med* 2013;52:1545–1551.
- 11 Fujimori N, Ito T, Igarashi H, Oono T, Nakamura T, Niina Y, Hijioka M, Lee L, Uchida M, Takayanagi R: Retroperitoneal fibrosis associated with immunoglobulin G4-related disease. *World J Gastroenterol* 2013;19:35–41.
- 12 Cho JM, Sato N, Kikuchi K: Prophylactic anti-tumor effect of Hochuekkito (TJ41) by enhancing natural killer cell activity. *In Vivo* 1991;5:389–391.
- 13 Sekiya M, Kiyohara H, Maruyama H, Yabe T, Yamada H: Modulation of chemokine expression on intestinal epithelial cells by Kampo (traditional Japanese herbal) medicine, Hochuekkito, and its active ingredients. *J Nat Med* 2013;67:626–635.
- 14 Nakayama M, Sugiyama Y, Yamasawa H, Soda M, Mato N, Hosono T, Bando M: Effect of hochuekkito on alveolar macrophage inflammatory responses in hyperglycemic mice. *Inflammation* 2012;35:1294–1301.
- 15 Iwagaki H, Saito S: Effects of a Kampo medicine on postoperative infection (in Japanese with English abstract). *Nihon Geka Gakkai Zasshi* 2013;114:241–245.

Fukuchi et al.: Immunoglobulin G4-Related Retroperitoneal Fibrosis Treated with Hochuekkito, a Kampo Medicine, following Steroid Treatment



**Fig. 1.** Abdominal CT revealed a solitary soft tissue density mass (arrow) surrounding the left side of the abdominal aorta. **a** Sagittal slice. **b** Horizontal slice. The mass involved the left ureter and was associated with left hydronephrosis (arrow). **c** Sagittal slice. The mass disappeared after 7 months of steroid therapy. **d** Sagittal slice. **e** Horizontal slice.



**Fig. 2.** Microscopic examination. **a** The lesion is shown encasing small lobules of adipose tissue; it is composed of abundant fibrosis with infiltrating lymphocytes and plasma cells (HE staining, ×40). **b** Obliterative phlebitis was noted (Elastica van Gieson staining, ×100). **c** Numerous IgG4-positive plasma cells were observed (immunostaining for IgG4, ×400). **d** The ratio of the number of IgG4-positive to IgG-positive cells was 41:100 (immunostaining for IgG, ×400).