

## Measuring morphological parameters of the pelvic diaphragm muscles using computed tomography in healthy dogs

Mohammad Sadegh Ashtari<sup>1</sup>, Abbas Veshkini<sup>1\*</sup>, Majid Masoudifard<sup>2</sup>, Hassan Gilanpour<sup>3</sup>, Alireza Bahonar<sup>4</sup>

<sup>1</sup>Department of Clinical Sciences, Faculty of Veterinary Medicine, Science and Research Branch, Islamic Azad University, Tehran, Iran; <sup>2</sup>Department of Surgery and Radiology, Faculty of Veterinary Medicine, University of Tehran, Tehran, Iran; <sup>3</sup>Department of Basic Sciences, Faculty of Veterinary Medicine, Science and Research Branch, Islamic Azad University, Tehran, Iran; <sup>4</sup>Department of Food Hygiene and Quality Control, Faculty of Veterinary Medicine, University of Tehran, Tehran, Iran.

### Article Info

#### Article history:

Received: 15 September 2019

Accepted: 11 December 2019

Available online: 15 December 2021

#### Keywords:

Canine

Coccygeus muscle

Computed tomography

Levator ani muscle

Pelvic diaphragm

### Abstract

Evaluation of pelvic diaphragm muscles in dogs merits clinical attention because of the anatomical importance and their involvement in perineal hernia. This study aimed to evaluate the normal pelvic diaphragm muscles (*levator ani* and coccygeus muscles) using the computed tomography (CT) scan. For this purpose, 10 male and 10 female clinically normal, adult intact mixed-breed dogs weighing 15.00 to 20.00 kg were selected randomly. All animals underwent CT examination under general anesthesia and positioned in sternal recumbency. All the CT images were taken and reconstructed with a same protocol. The measurements of the pelvic diaphragm muscles were performed based on the presented guideline to the observer. The results were presented descriptively. The mean lengths of the coccygeus muscle in CT images were evaluated 4.60 cm for males and 4.30 cm for females. The mean lengths of *levator ani* muscle in CT images were measured 4.90 cm in males and 4.50 cm in females. In conclusion, the results of the present study can be beneficial to clinicians and researchers for further evaluation of the supporting muscles in pelvic cavity and underlying anatomical changes in perineal hernia in dogs.

© 2021 Urmia University. All rights reserved.

### Introduction

The pelvic diaphragm is a muscular sheet considering as a musculofascial closure of the pelvic outlet being clinically important in the development of a perineal hernia. Different muscles contribute to the formation of pelvic diaphragm including two *levator ani* muscles with bilaterally adjacent coccygeus muscle and both lamellae of the diaphragmatic fascia of the pelvis. A dorsoventrally arranged longitudinal opening can be recognized by a slight depression between the *levator ani* muscles of both sides. The dorsal part of levator door, in the anal part of the pelvic diaphragm, is closed by the anal canal with surrounding musculature. While, in the urogenital part of the pelvic diaphragm, it is closed ventrally by the urogenital canal with surrounding musculature as well as in between by the proper perineum.<sup>1</sup> The coccygeus muscle is a thick muscle starting from the ischiatic spine, cranial to the internal obturator muscle. It extends to the lateral surface of the tail by crossing the medial part of

the sacrotuberous ligament and inserts on the transverse processes of the second to fifth caudal vertebrae. This muscle is responsible for pressing the tail against the anus and genital parts. Besides, in combination with the depressors, it draws the tail between the pelvic limbs bilaterally and flexes the tail unilaterally. This muscle is innervated by the ventral branches of the third sacral nerve.<sup>2</sup> The *levator ani* muscle is a broad triangular muscle starting from the medial edge of iliac shaft, on the dorsal part of pubic ramus and the entire symphysis of pelvic. This muscle is located cranial and medial to the coccygeus muscle and ends on the hemal process of the seventh caudal vertebra by passing into the caudal fascia. Like the coccygeus muscle, *levator ani* muscle helps with pressing the tail against the anus and genital parts bilaterally and bringing the tail cranially and laterally. Also, in combination with the tail's levator muscles, it makes the sharp angulation between the sixth and seventh caudal vertebrae (characteristic for defecation) and compresses the rectum.<sup>2</sup> The defect in the pelvic diaphragm generally

#### \*Correspondence:

Abbas Veshkini. DVM, DVSc

Department of Clinical Sciences, Faculty of Veterinary Medicine, Science and Research Branch, Islamic Azad University, Tehran, Iran

E-mail: veshkini@ut.ac.ir



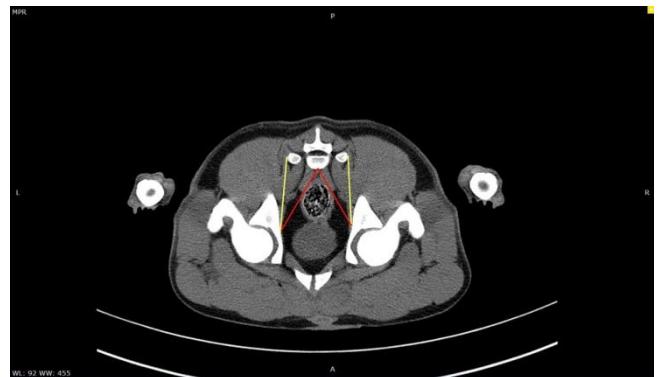This work is licensed under a Creative Commons Attribution-NonCommercial 4.0 International License which allows users to read, copy, distribute and make derivative works for non-commercial purposes from the material, as long as the author of the original work is cited properly.

happens due to the weakening of the pelvic diaphragm's muscles, with the *levator ani* muscle most commonly affected.<sup>3,4</sup> The failure of the pelvic outlet structures results in an inability of the pelvic diaphragm to hold the pelvic organs and causes a condition called perineal hernia. The exact causes of muscle weakening, and perineal hernia are still unknown. However, several hypotheses have been suggested. For instance, tenesmus secondary to prostatomegaly or chronic constipation or any condition causing straining such as urinary tract obstruction, colorectal obstruction, rectal deviation, anal sacculitis, cystitis and perianal inflammation.<sup>1,5-7</sup> Moreover, the imbalances of gonadal hormone concentrations and neurogenic atrophy of the *levator ani* muscle were also proposed by literature as other potential risk factors.<sup>1,5,8,9</sup> Advances in diagnostic imaging have provided novel insights into the anatomy and physiological function of the pelvic floor muscles in human medicine; however, to the best of the authors' knowledge, transactional information derived from computed tomography (CT) imaging for evaluation of the canine pelvic diaphragm muscles is still limited. By providing better knowledge about normal shape, length and appearance of the pelvic diaphragm muscles, CT scan images help us not only to predict and diagnose abnormalities but also to have excellent surgical planning before the surgery. Therefore, this study aims to provide better anatomical insights to these muscles by obtaining morphological data of the normal pelvic diaphragm muscles (*Levator ani* and coccygeus muscles) with CT scan in healthy dogs.

## Materials and Methods

Twenty adults, intact experimental mixed-breed dogs (10 males and 10 females) with a median weight of 18.00 kg (range of 15.00 to 20.00 kg) and a median age of 16 months (range of 12 to 20 months) were included in this study. Based on physical examination, clinical history and blood test results, all dogs were determined to be healthy. The dogs were fasted for 12 hr before scanning. To avoid artifacts effects, all patients were monitored to defecate on the day of examinations. Computed tomographic scans were performed after defecation in sternal recumbency and both hind limbs were pulled back completely. Animals were anesthetized using a combination of 10.00 mg kg<sup>-1</sup> ketamine (Alfasan, Woerden, The Netherlands) and 1.00 mg kg<sup>-1</sup> xylazine (Alfasan). Computed tomographic images were obtained using a two slice scanner (Siemens Somatom Spirit; Berlin, Germany) with scan parameters of 130 kVp, 67.00 mA and 1.00 mm slice thickness with 1.00 mm interval in soft tissue algorithm and in helical scanning mode. The CT scans were performed from the caudal endplate of 6<sup>th</sup> lumbar vertebrae to 7<sup>th</sup> caudal vertebrae. All the images were reconstructed with soft tissue Kernel and DICOM images were reviewed using Syngo MMWP

VE40A Software (Siemens AG; Munich, Germany), with window width 342 HU and window level 56 HU. To measure both muscles, CT images at the level of 1<sup>st</sup> caudal vertebrae were used. The images were adjusted in the multiple planar reconstructions (MPR) to have a final symmetrical transverse plane by focusing on a subjective symmetrical appearance of the vertebra and pelvic bones. When the transverse process was completely visible, the coccygeus muscle's measurement line was drawn from the ischiatic spine with a perpendicular angle to the center of the femoral head and it was ended at the tip of the transverse process of the 1<sup>st</sup> caudal vertebrae bilaterally. The measurement line for *Levator ani* muscle was started from the ischiatic spine and ended at the ventral aspect of the 1<sup>st</sup> caudal vertebrae (Fig. 1). The experimental protocols regarding the care and handling of dogs were approved by the Ethics Committee of Faculty of Veterinary Medicine, Science and Research Branch, Islamic Azad University, Tehran, Iran (IR.IAU.SRB.REC.1396.022).



**Fig. 1.** Measurement of *Levator ani* and coccygeus muscles in the cross-section computed tomography image. Red line: *levator ani* muscle; Yellow line: Coccygeus muscle.

**Statistical analysis.** Mean lengths of each muscle in male and female dogs were statistically analyzed with the independent samples *t*-test using SPSS software (version 20.0; SPSS Inc., Chicago, USA). A *p*-value less than 0.05 was considered statistically significant.

## Results

The pelvic diaphragm was detected subjectively in dorsal, sagittal, and transverse MPR images. The pelvic diaphragm muscles including both *levator ani* muscles and bilaterally adjacent coccygeus muscles were distinguished clearly in all dogs. The *levator ani* muscles were visible on cross-section view at the level of the hip joints. They were placed bilaterally to the rectum arising from the iliac shaft to hemal process of the 4<sup>th</sup> caudal vertebrae (Figs. 2 and 3). The mean length of the *levator ani* muscles in our CT images was calculated 4.90 cm and 4.50 cm in males and females, respectively (Table 1).

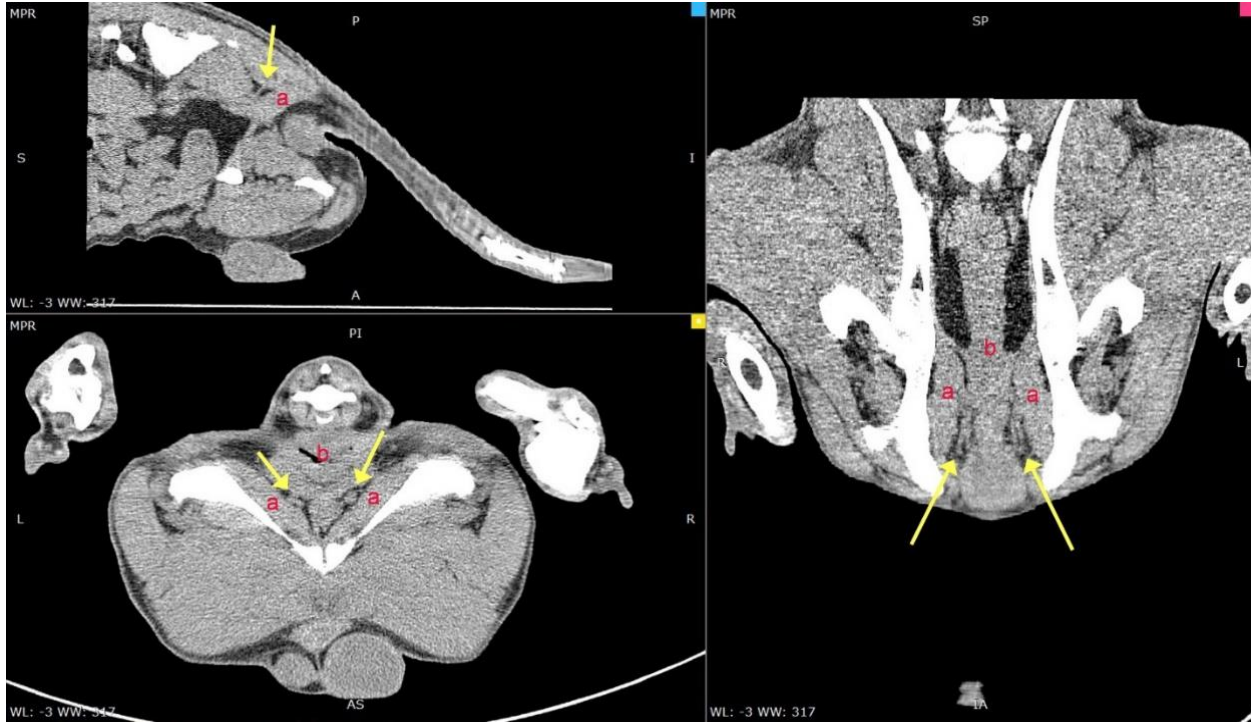

Fig. 2. Reconstructed computed tomography images. a: Coccygeus muscle; b: Rectum; Arrow: Levator ani muscle.

The coccygeus muscle appears as a thick muscle located laterally to the levator ani muscle and it was visible at the level of hip joint and second caudal vertebra at cross-section view. It originated from the medial shaft of ilium and ended at the transverse process of 2<sup>nd</sup> caudal vertebrae (Fig. 2). The mean length of coccygeus muscle in our CT images was evaluated 4.63 cm and 4.35 cm in males and females, respectively (Table 1). The study showed statistically significant difference between males and females regarding length of both muscles ( $p < 0.05$ ).

Table 1. The length (cm) of levator ani and coccygeus muscles in computed tomography scans. Data are presented as mean  $\pm$  standard deviation.

Muscles	Number	Measurements
<b>levator ani muscle</b>		
Male	10	4.98 $\pm$ 0.59 *
Female	10	4.56 $\pm$ 0.33
<b>Total</b>	<b>20</b>	<b>4.77 <math>\pm</math> 0.46</b>
<b>Coccygeus muscle</b>		
Male	10	4.63 $\pm$ 0.40*
Female	10	4.35 $\pm$ 0.34
<b>Total</b>	<b>20</b>	<b>4.49 <math>\pm</math> 0.37</b>

\* Asterisks indicate statistical significance between the males and females at  $p < 0.05$ .

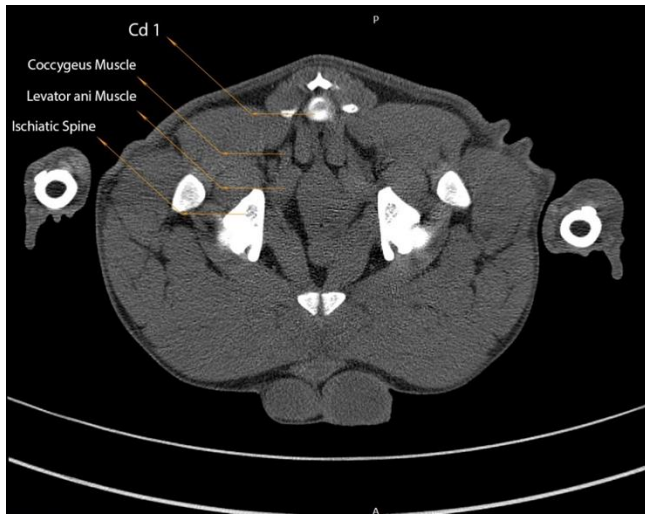


Fig. 3. Cross-section image of the pelvic outlet and pelvic diaphragm muscles.

### Discussion

The pelvic diaphragm plays an important role in developing canine perineal, when there is a weakening or failure in its muscles.<sup>10</sup> Progressive weakening of the muscular pelvic diaphragm and supporting intra-pelvic connective tissue structures eventually leads to herniation of caudal abdominal organs (bladder and prostate) and rectal deviation and sacculation.<sup>11</sup> Therefore, the evaluation of the morphological parameters of the pelvic diaphragm muscles can be beneficial for both clinical use and research purposes. In the present study, we evaluated and summarized the tomographical anatomy of the pelvic diaphragm by focusing on anatomical CT features of levator ani and coccygeus muscles in normal dogs. In all included cases, both levator ani and coccygeus muscles

were clearly detectable in transverse images and they were traceable in MPR images. In the present study, anatomically reported muscular bands including puborectalis and pubococcygeus were not distinguishable.<sup>12</sup> The results showed a significant difference between males and females regarding length of both muscles. This difference may be involved pathophysiologically in the predisposition of perineal hernia in male dogs;<sup>13</sup> however, proofing the role of musculature biometry in perineal hernia development in addition to hormonal changes needs further studies. It is important to plan surgical managements of perineal hernias based on the musculature involvement, because atrophy of the *levator ani* and/or coccygeus muscles will affect the appositional herniorrhaphy.<sup>14</sup> Morphological evaluations of these muscles and comparison with references are of value. Former studies evaluated the pelvic diaphragm were mostly based on the pathological features, defects and failures of the pelvic floor muscles that can lead to pelvic hernia.<sup>15</sup> We also found studies, in which different surgical approaches for repairing the perineal hernia were assessed.<sup>16,17</sup> However, the application of CT scan in the morphological evaluation of normal and intact pelvic diaphragm muscles was not addressed in any of these studies. The CT images of this study showed normal morphological findings concerning the pelvic diaphragm in dogs. However, the study includes limitations. The most important limitation of this study was the inclusion of the large breed dogs over 15.00 kg weight. We were able to evaluate the muscles in all the sections, which might be limited in smaller cases. Besides, the cases were chosen randomly without prospective follow up; thus, the predisposition of these animals to perineal hernia is not clear. The results of this study present the normal anatomical features of *levator ani* and coccygeus muscles in dogs.

These findings can help to detect abnormalities influencing the shape, size and opacity of the muscles and will be beneficial to uncover the morphological changes of the pelvic diaphragm muscles for clinical use and future studies.

### Acknowledgments

The authors thank the support of Small Animal Hospital, Faculty of Veterinary Medicine, University of Tehran, Tehran, Iran.

### Conflict of interest

The authors declare that there is no conflict of interest.

### References

1. Budras KD, McCarthy PH, Fricke W, et al. Anatomy of the dog: an illustrated text. 5<sup>th</sup> ed. Hannover, Germany: Schlütersche 2007; 72-75.
2. Evans HE, De Lahunta A. Miller's anatomy of the dog. 4<sup>th</sup> ed. St. Louis, USA: Elsevier Health Sciences; 2013; 228-232.
3. Slatter DH. Textbook of small animal surgery. 3<sup>rd</sup> ed. Philadelphia, USA: Elsevier 2003; 485- 513.
4. Blakely C, Evanston I. Canine surgery. Evanston, USA: American Veterinary Publications 1957; 458.
5. Bongartz A, Carofiglio F, Balligand M, et al. Use of autogenous fascia lata graft for perineal herniorrhaphy in dogs. *Vet Surg* 2005; 34(4): 405-413.
6. Aliabadi A, Dehghani S. Internal obturator transposition herniorrhaphy of three perineal hernia cases in dogs. *Iran J Vet Surg* 2007; 2(3): 84-90.
7. Pettit GD. Perineal hernia in the dog. *Cornell Vet* 1962; 52: 261-279.
8. Krahwinkel DJ. Rectal diseases and their role in perineal hernia. *Vet Surg* 1983; 12(3): 160-165.
9. Shahar R, Shamir MH, Niebauer GW, et al. A possible association between acquired nontraumatic inguinal and perineal hernia in adult male dogs. *Can Vet J* 1996; 37(10): 614-616.
10. Johnston SA, Tobias, KM. Veterinary surgery: Small animal expert consult. 2<sup>nd</sup> ed. St. Louis, USA: Elsevier Health Sciences 2017; 1778-1793.
11. Niebauer GW, Shibly S, Seltenhammer M, et al. Relaxin of prostatic origin might be linked to perineal hernia formation in dogs. *Ann N Y Acad Sci* 2005; 1041: 415-422.
12. Hall MI, Plochocki JH, Rodriguez-Sosa JR. Male and female anatomical homologies in the perineum of the dog (*Canis familiaris*). *Vet Med Sci* 2019; 5(1): 39-47.
13. Mann F, Nonneman DJ, Pope ER, et al. Androgen receptors in the pelvic diaphragm muscles of dogs with and without perineal hernia. *Am J Vet Res* 1995; 56(1): 134-139.
14. Gill SS, Barstad RD. A Review of the surgical management of perineal hernias in dogs. *J Am Anim Hosp Assoc* 2018; 54(4): 179-187.
15. Burrows CF, Harvey CE. Perineal hernia in the dog. *J Small Anim Pract* 1973; 14(6): 315-332.
16. Orsher RJ. Clinical and surgical parameters in dogs with perineal hernia analysis of results of internal obturator transposition. *Vet Surg* 1986; 15(3): 253-258.
17. Vnuk D, Lipar M, Matičić D, et al. Comparison of standard perineal herniorrhaphy and transposition of the internal obturator muscle for perineal hernia repair in the dog. *Vet Arh* 2008; 78(3): 197-207.