

Available online at www.sciencedirect.com

ScienceDirect

journal homepage: www.elsevier.com/locate/radcr

Case report

Rapid 3D reconstruction guided embolization for catastrophic bleeding following vacuum assisted breast biopsy; A case report and review of the literature [☆]

Martin Halicek, PhD^{a,*}, Chenghao Qian, MD^b, Driss Raissi, MD^c, Xiaoqin Wang, MD^c, Yevgen Chornenkyy, MD^d, William B. Bates, MD^a, Michael Winkler, MD^a

^a Medical College of Georgia at Augusta University, Department of Radiology, Augusta, GA, USA

^b University of California Davis, Department of Internal Medicine, Davis, CA, USA

^c University of Kentucky Chandler Medical Center, Department of Radiology, Lexington, KY, USA

^d Northwestern University, Department of Pathology, Chicago, IL, USA

ARTICLE INFO

Article history:

Received 27 June 2021

Revised 19 August 2021

Accepted 20 August 2021

Keywords:

Breast needle biopsy

Bleeding

Hematoma

3D reconstruction

Embolization

ABSTRACT

The most clinically significant complication associated with stereotactic core needle biopsy of the breast is hematoma formation, which only occurs in less than 1% of biopsies and may require treatment. Cases of uncontrollable bleeding, refractory to repeated compression, resulting from biopsy are exceedingly rare. We present a case of catastrophic, uncontrollable bleeding and large hematoma formation resulting from stereotactic vacuum-assisted breast biopsy of a breast mass identified in screening mammography. Percutaneous embolization was planned and guided using 3D reconstructions from computed tomographic angiography, and bleeding was successfully controlled with micro-coil embolization.

© 2021 The Authors. Published by Elsevier Inc. on behalf of University of Washington.

This is an open access article under the CC BY-NC-ND license

(<http://creativecommons.org/licenses/by-nc-nd/4.0/>)

Introduction

We present a rare case of uncontrollable bleeding with large expansile hematoma after stereotactic guided vacuum-assisted breast biopsy (VABB) of a breast mass. Treatment with

percutaneous micro-coil embolization was needed to control the bleeding. Treatment planning was performed using 3D reconstructions from Computed tomographic angiography (CTA). Our institutional review board does not require or encourage review of case reports of less than three patients. No consent was obtained, as there is no identifiable information

[☆] Competing interests: The authors declare they have no competing interests.

* Corresponding author.

E-mail address: mhalicek@augusta.edu (M. Halicek).

<https://doi.org/10.1016/j.radcr.2021.08.053>

1930-0433/© 2021 The Authors. Published by Elsevier Inc. on behalf of University of Washington. This is an open access article under the CC BY-NC-ND license (<http://creativecommons.org/licenses/by-nc-nd/4.0/>)

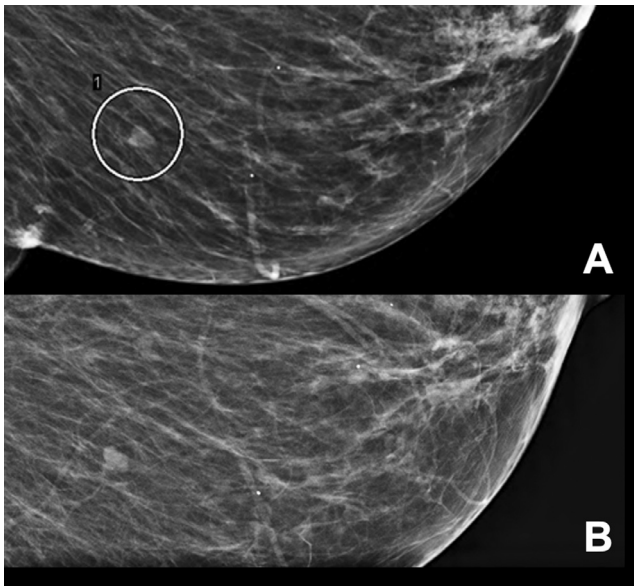


Fig. 1 – (A) Mediolateral oblique view of the mass measures 7 mm in size and is located 7 cm from the nipple. (B) Spot compression evaluation of the mass demonstrates the mass in the same view.

present in this case report and thus no risk to the patient's privacy or wellbeing.

Case report

A 71-year-old female was called back for additional imaging work up for a 7 mm oval-shaped mass in her left breast, 8:00 position, 7 cm from the nipple, which was found on her annual screening mammography (see Fig. 1). This mass persisted on the diagnostic mammogram and had no ultrasound correlate. This mass was assessed as Breast Imaging Reporting and Data System 4A lesion. Thus, mammogram guided stereotactic VABB was recommended by the radiologist for this 7 mm mass. She has a medical history of diabetes, hypertension, and esophageal reflux, with no known history of coagulopathy. Physical examination revealed a palpable area of concern at the 4 o'clock position near the infrathoracic fold with a 2 cm inflamed subcutaneous lesion with tract to skin, most consistent with resolving infected sebaceous cyst. No evidence of exudate was noted. Patient denied skin changes or nipple discharge.

Stereotactic VABB of the mass was performed of the left breast at 8:00, 7 cm from the nipple (see Fig. 2A). The biopsy site was compressed for 10 minutes by a nurse as a routine practice. Post-procedure mammogram was performed which demonstrated an 8.4 cm × 5.7 cm post-procedure hematoma and the ribbon marker was displaced 47 mm posterior from the biopsy site (Fig. 2B). Post-procedural high-resolution real-time color US demonstrated a hematoma measuring 8.7 cm in maximum dimension. Additional 30 minutes manual compression was applied to the biopsy site. Repeat doppler evalu-

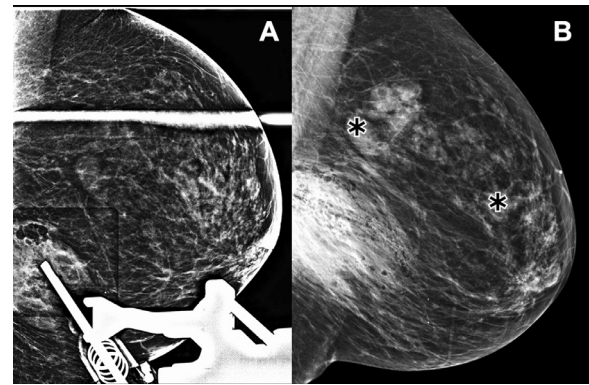


Fig. 2 – (A) Stereotactic biopsy of the mass in the left breast at 8:00, 7 cm from the nipple. (B) Post-procedure scan demonstrated an 8.4 cm x 5.7 cm hematoma and displaced ribbon marker 47 mm posterior from biopsy site.

ation demonstrated no active bleeding (Fig. 3A). However, focused US reevaluation of the hematoma 2 hours later showed a 0.6 cm increase in size (Fig. 3B) in spite of additional 30 minutes compression in an attempt to control the bleeding. Patient was transferred to the emergency department as she reported not feeling well. A CTA was ordered to evaluate the hematoma and bleeding.

Imaging with CTA confirmed left breast hematoma with active bleeding from a small anterior intercostal arterial branch at the inferomedial aspect of the hematoma, evidenced by extravasation of contrast media into the hematoma (Fig. 4). The patient was transferred to the interventional radiology department for further management. 3D reconstruction of CTA revealed the source of bleeding was from a perforating branch off the T4 branch of the left internal thoracic artery (Fig. 5). As shown, the culprit perforating branch was selected using the provided 3D reconstruction to guide interventional therapy.

Via a 5 French guide catheter, a 2.4 French microcatheter was advanced through the internal thoracic artery, which resulted in a marked degree of arterial spasm. Nitroglycerin was used to facilitate access into the T4 anterior intercostal branch. Technically successful coil embolization of the culprit was achieved using 3 mm micro-coils (Fig. 6). The patient tolerated the procedure with no complications. She was admitted for two nights until hemoglobin levels stabilized around 10 g/dl. Patient was discharged in stable condition. Three-month follow-up focused US evaluation of the hematoma showed a decrease in maximum dimension from 9 cm to 5 cm.

Discussion

Breast hemorrhage or hematoma following breast biopsy typically resolves with continued manual pressure for 30 minutes [1]. Bleeding refractory to pressure is rare and may require escalation of care. Post-biopsy bleeding that cannot be controlled with manual compression is a rare but severe complication of VABB.

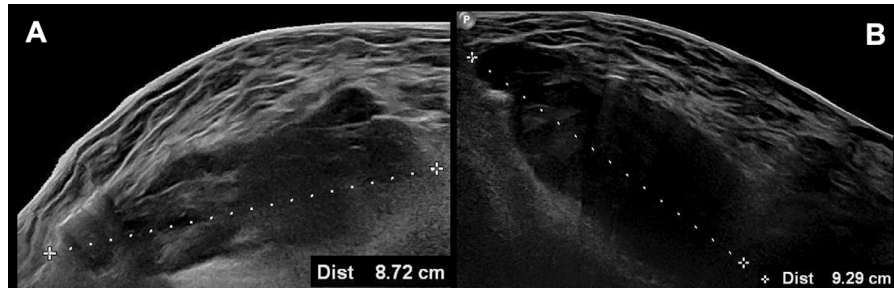


Fig. 3 – (A) Post-procedural high-resolution real-time US scanning demonstrated a hematoma measuring 8.7 cm in maximum dimension. (B) A focused US reevaluation of the hematoma 2 h later showed a 0.6 cm increase in size (9.3 cm).

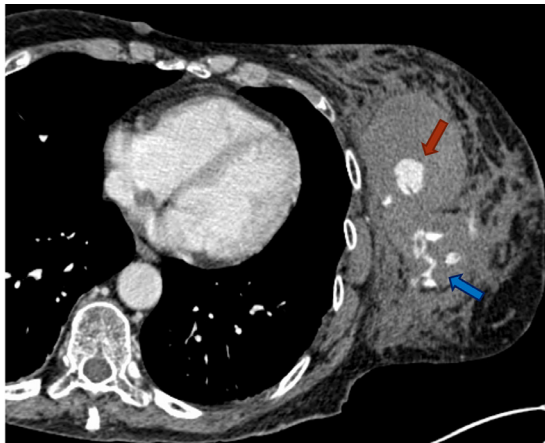


Fig. 4 – Axial CTA showed a 7 mm pseudoaneurysm (red arrow) with active arterial extravasation (blue arrow) surrounded by the left breast hematoma. “(Color version of figure is available online)”

According to a meta-analysis by Bruening et al. of 83 studies, uncontrollable bleeding or hematoma requiring treatment can occur in 0.72% and 0.09% of biopsies, respectively [2]. In this meta-analysis, these were the most common severe complications associated with stereotactic-guided VABB with no reported deaths.

In general, hematoma formation after breast biopsy has been associated with factors such as large needle gauge, adjacent vessels and anticoagulant use [3–4,5]. However, cases of uncontrollable catastrophic bleeding are exceedingly rare. A 2019 retrospective study of nearly 5000 patients found that clinically significant complications of VABB were present in only 0.3% of biopsies [6]. In the 13 years the study ran, only 10 cases of clinically significant hematoma were identified out of 4776 biopsies, none of which required embolization [6].

Only a small number of case reports on uncontrollable bleeding following breast biopsy requiring emergency embolization have been reported [7,8]. Binh et al. described successful embolization in a case of post breast biopsy soft tissue large hematoma with arterial pseudoaneurysm formation [8] Fischman et al. reported two cases of embolization to control arterial hemorrhage in a 35-year-old and 43-year-old patient [7].

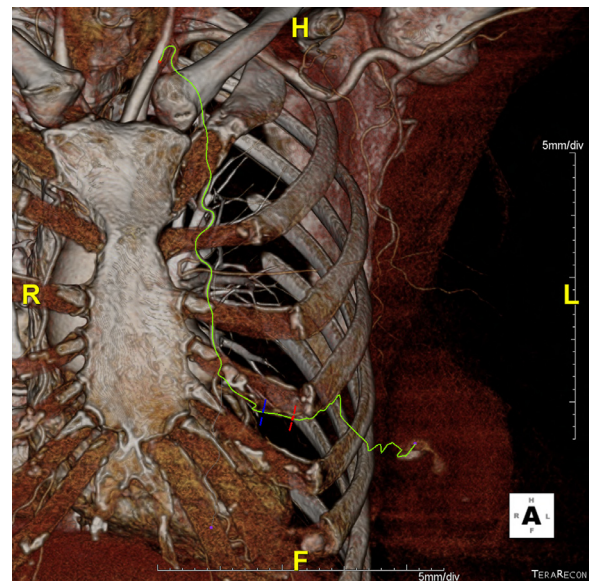


Fig. 5 – 3D reconstruction demonstrated bleeding from a T4 perforator branch off the left internal thoracic artery. The arterial segment (between blue and red) was selected for coil deployment. “(Color version of figure is available online)”

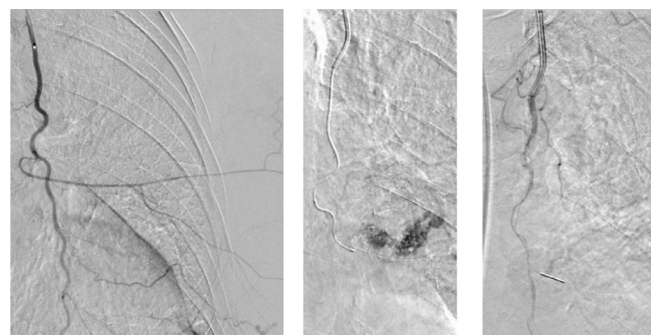


Fig. 6 – (Left) Microcatheter-microwire combination was used to advance through internal thoracic artery. (Middle) Contrast extravasation identified from anterior T4 intercostal artery. (Right) Technically successful coil embolization of the culprit branch.

Coils were selected as embolic media in this case due to their ease of use, operator familiarity, and the rich perfusion and low resting oxygen demand of skeletal muscle, the target tissue in this case. Neither gelfoam or thrombin were considered due to the dual risks of microcatheter occlusion and non-target embolization associated with these agents. Furthermore, the use of gelfoam in superficial soft tissues has been associated with heightened risks of infection and inflammatory reaction [9,10].

CTA is a routine tool for diagnosis and periprocedural planning in the management of vascular emergencies, and 3D reconstruction of CTA data can precisely simulate the way bleeding will appear during conventional angiography, obviating the need for non-selective angiography and hastening embolization [11]. Rapid periprocedural planning using 3D reconstructions of CTA has been utilized for embolization of bleeding, as was reported in a case of major bleeding post paracentesis [12].

Color or power doppler US may be used to detect superficial post biopsy pseudoaneurysms and guide subsequent direct thrombin injections in stable patients [13]. The role of direct thrombin injection in the setting of hemodynamic instability is less clear. In this case, color and power modes ultrasound failed to reveal a pseudoaneurysm within or in proximity to the post biopsy hematoma. Operator inexperience, hematoma size, and the urgency of the situation may have affected the accuracy of the modality in this setting. Once the patient arrived at the ER, localization of bleeding proceeded per protocol, first with CTA and then with conventional angiography.

In summary, the case presented highlights the utility of 3D volume visualization reconstruction in the emergent management of an exceedingly rare arterial bleed resulting from VABB. This patient had no history coagulopathy, which demonstrates the risk of aggressive vacuum assist even in patients with normal coagulation. In this case, the breast tissue has a rich vascular supply with multiple contributing vessels including internal thoracic, lateral thoracic, and thoracodorsal artery. 3D reconstruction allowed accurate localization of culprit bleeding branch and development of a therapeutic plan. Our case demonstrates that this intervention can also be applied to arterial trauma in breast tissue, especially to those that are refractory to conventional manual compression therapy.

Patient consent

Institutional Review Board (IRB) formal review was not required by our institutional review board (University of Ken-

tucky Chandler Medical Center). No consent was obtained as there is no risk to the patient's privacy and no identifiable information is present in this case report.

REFERENCES

- [1] Ingram AD, Mahoney MC. An overview of breast emergencies and guide to management by interventional radiologists. *Tech Vasc Interv Radiol* 2014;17(1):55–63.
- [2] Bruening W, Fontanarosa J, Tipton K, Treadwell JR, Launders J, Schoelles K. Systematic review: comparative effectiveness of core-needle and open surgical biopsy to diagnose breast lesions. *Ann Intern Med* 2010;152(4):238–46.
- [3] Chetlen AL, Kasales C, Mack J, Schetter S, Zhu J. Hematoma formation during breast core needle biopsy in women taking antithrombotic therapy. *Am J Roentgenol* 2013;201(1):215–22.
- [4] Yap LP, Rouse H, Cawson J. An extensive breast hematoma following stereotactic 9 gauge vacuum assisted large-core biopsy. *Breast J* 2010;16(2):199–200.
- [5] McMahon P, Reichman M, Dodelzon K. Bleeding risk after percutaneous breast needle biopsy in patients on anticoagulation therapy. *Clin Imaging* 2021;70:114–17.
- [6] Young Lin LL, Gao Y, Lewin AA, Toth HK, Heller SL, Moy L. Overstated harms of breast cancer screening? a large outcomes analysis of complications associated with 9-gauge stereotactic vacuum-assisted breast biopsy. *Am J Roentgenol* 2019;212:925–32.
- [7] Fischman AM, Epelboym Y, Siegelbaum RH, Weintraub JL, Kim E, Nowakowski FS, et al. Emergent embolization of arterial bleeding after vacuum-assisted breast biopsy. *Cardiovasc Intervent Radiol* 2012;35:p194–7.
- [8] Thai Binh N, Minh Duc N, Tra My TT, Viet Dung L, Tien Luu D, Tuan Linh L. Emergency embolization for breast pseudoaneurysm following vacuum-assisted biopsy: a case report. *Pan Afr Med J* 2021;38:135.
- [9] Anderson CK, Medlin E, Fontenot Ferriss A, Sheeder J, Davidson S, Gibbs R, et al. Association between gelatin-thrombin matrix use and abscesses in women undergoing pelvic surgery. *Obstet Gynecol* 2014;124(3):589–95.
- [10] Lindstrom PA. Complications from the use of absorbable hemostatic sponges. *AMA Arch Surg* 1956;73:133–41.
- [11] Baliyan V, Shaqdan K, Hedgire S, Ghoshhajra B. Vascular computed tomography angiography technique and indications. *Cardiovasc Diagn Ther* 2019;9(Suppl 1):S14–27.
- [12] Siddiqi N, Issa M, Raissi D, Qian C, Gabriel G, Winkler M. Manual on-the-fly physician postprocessing of computed tomographic angiography data guides embolotherapy of atypical bleeding following paracentesis; a case report. *Clin Imaging* 2019;58:1–4.
- [13] Adler K, Samreen N, Glazebrook KN, Bhatt AA. Imaging features and treatment options for breast pseudoaneurysms after biopsy: a case-based pictorial review. *J Ultrasound Med* 2020;39(1):181–90.