

Case report

Open Access

Laryngeal Involvement of Rhabdomyosarcoma in an Adult

Hüseyin Abali¹, Sercan Aksoy*¹, Arzu Sungur² and Suayib Yalçın¹

Address: ¹Hacettepe University Oncology Institute, Department of Medical Oncology, Ankara, Turkey and ²Hacettepe University Faculty of Medicine, Department of Pathology, Ankara, Turkey

Email: Hüseyin Abali - habali@hacettepe.edu.tr; Sercan Aksoy* - saksoy07@yahoo.com; Arzu Sungur - asungur@hacettepe.edu.tr; Suayib Yalçın - suayibyalcin@yahoo.com

* Corresponding author

Published: 17 September 2003

Received: 12 July 2003

World Journal of Surgical Oncology 2003, 1:17

Accepted: 17 September 2003

This article is available from: <http://www.wjso.com/content/1/1/17>

© 2003 Abali et al; licensee BioMed Central Ltd. This is an Open Access article: verbatim copying and redistribution of this article are permitted in all media for any purpose, provided this notice is preserved along with the article's original URL.

Abstract

Background: Although initial presentation of sarcomas in the head and neck region is relatively common, involvements of the larynx by rhabdomyosarcoma either primary or metastatic have been reported rarely.

Case report: A case of rhabdomyosarcoma in the right thigh, which involved laryngeal structures three years after the diagnosis, is presented.

Conclusions: The laryngeal involvement by primary and metastatic rhabdosarcomas is very rare, however when it occurs it can result in life treating upper airway obstruction. After emergency intervention, radiotherapy and / or chemotherapy must be undertaken for long-term benefit and surgery may be helpful only in selected cases.

Introduction

Laryngeal cancer is an important cause of morbidity and mortality in smokers accounting for 25% of the head and neck cancers [1]. Over 95 percent of the cancers of the larynx are of squamous histology. Non-squamous histology including sarcomas and salivary gland tumors are quite rare. Primary involvement of the larynx by mesenchymal tumors has been reported as case reports [2,3]. Metastasis to the larynx from a neoplasia elsewhere is even rare, making 0.09 % to 0.4 % of total [4]. Until present, about 150 metastatic cancers of larynx of various histology have been reported. Here, we report a case of rhabdomyosarcoma in the right thigh, which involved laryngeal structures three years after the diagnosis.

Case Report

A 45 year-old man presented with a complaint of a lump in the inner side of the right thigh for the past 2 months. Excision biopsy was performed. Histologically the tumor was composed of sheets of malignant round and spindled cells in a variably myxoid stroma. Some cells had abundant eosinophilic cytoplasm. Atypical mitotic figures were seen (Figure 1). Immunohistochemical stains revealed that the tumor cells were positive for vimentin, desmin and myod1. With a diagnosis of rhabdomyosarcoma combination chemotherapy with ifosfamide (2500 mg/m² for 3 days, together with mesna at the same doses) and adriamycine (60 mg/m² on day 1) was given for six cycles as adjuvant treatment. Five months following completion of chemotherapy, a hemipelvectomy was performed upon local recurrence of the tumor in the previous location. The pathological examination was consistent with

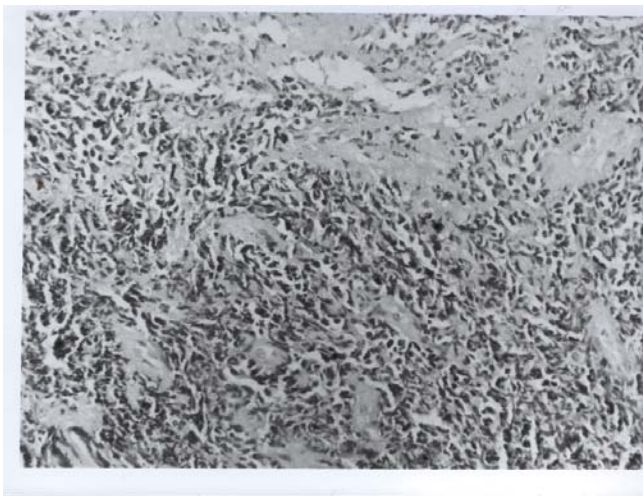


Figure 1
Photomicrograph showing sheets of round and spindled cells (H&E ×230)

rhabdomyosarcoma. The DICE (dexamethasone, ifosfamide, carboplatin and etoposide) combination adjuvant chemotherapy was started. However, it had to be stopped after the 3rd cycle due to elevation of aminotransferases as high as 5 times the upper limit of normal ranges. After almost a year of uneventful period, a 3 cm metastatic nodule in the superior segment of left lower lobe was discovered and metastatectomy was performed. The histopathological examination was consistent with malignant mesenchymal tumor. He had received a total 4 courses of ifosfamide at the dose of a total of 14 g/m² in 7 days with hematopoietic growth factor support every month. Four months after the last course he began to experience hoarseness and mild dyspnea. Physical examination showed multiple polypoid masses in the sub-glottic region. Magnetic resonance images of head and neck were showed the laryngeal masses (Figure 2). Biopsy revealed rhabdomyosarcoma. As the curative surgery was not feasible, palliative radiotherapy was given to relieve his symptoms. He experienced only a mild throat pain during radiotherapy. However, 2 months later he noticed a mass of an almond size in his mouth. On inspection of oral cavity, a 3 cm mass just between left tonsil and tongue, covered with a necrotic pseudomembrane, was discovered. Excisional biopsy showed rhabdomyosarcoma. CT of head and region disclosed several other metastatic lesions. He was re-admitted to hospital 7 days after following his last discharge with acute severe dyspnea and wheezing. His complaints responded well to dexamethasone 16 mg/day. Palliative chemotherapy with VAC (vincristine, actinomycine, cyclophosphamide) every week was started. After the 1st cycle, the mass in the floor of mouth disappeared.

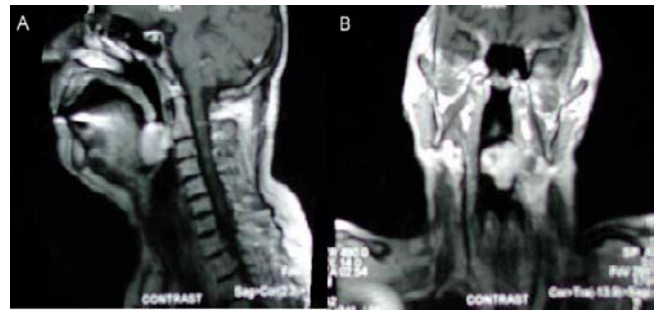

Figure 2
Figure 2a and 2b. Magnetic resonance images of head and neck showing the laryngeal mass

Discussion

Rhabdomyosarcoma is a tumor of striated muscle. It has mainly two subtypes: Embryonal and alveolar. While the loss of heterozygosity of chromosome 11p15 identifies the first one, latter is characterized by the translocation t(2;13) (q35;q14) [5]. It is the most common malignant mesenchymal tumor in children. Therefore most of the information is inspired from pediatric studies. It is quiet rare in adults. The most common site of presentation is head and neck region (35 %). Lungs, bone marrow, bones, liver and brain are among the most common sites of metastases [5]. Ifosfamide, adriamycin, etoposide, vincristine and actinomycin are among effective agents in the treatment of soft tissue sarcomas [6–9]. Survival ranges from 30% in patients with metastatic presentation to 80% in those where the disease is localized and complete resection is performed [7].

Upper airway obstruction, irrespective of the cause, is an emergency. Therefore it is a must to intervene rapidly. Corticosteroids may be beneficial by relieving accompanying edema. However immediate tracheotomy can be required and when necessary should be performed undoubtedly. After emergency intervention, palliative measures like radiotherapy and / or chemotherapy must be undertaken for long-term benefit. However surgery may be helpful only in selected cases.

Although it is difficult to make the distinction between metastatic or primary for sure, we supposed our case was a metastatic invasion rather than primary in an adult owing to previous diagnosis of rhabdomyosarcoma, similar histology and multiplicity of the tumor and rarity of primary involvement of larynx in adults [4].

References

1. Shaha AR, Patel S, Shaha D and Harrison LB: **Head and neck cancer.** In *Clinical Oncology* 1st edition. Edited by: Lenhard RE, Osteen RT, Gansler T. Atlanta: The American Cancer Society Inc; 2001:297-327.

2. Akyol MU, Sözeri B, Küçükali T and Öğretmenoğlu O: **Laryngeal pleomorphic rhabdomyosarcoma.** *Eur Arch Otorhinolaryngol* 1998, **255**:307-310.
3. Rinaldo A, Howard DJ and Ferlito A: **Laryngeal chondrosarcoma: A 24-year experience at the Royal National Throat, Nose and Ear Hospital.** *Acta Otolaryngol* 2000, **120**:680-688.
4. Puxeddu R, Pelagatti CL and Ambu R: **Colon adenocarcinoma metastatic to the larynx.** *Eur Arch Otorhinolaryngol* 1997, **254**:353-355.
5. Marcus KC: **Pediatric solid tumors.** In *Clinical Oncology* 1st edition. Edited by: Lenhard RE, Osteen RT, Gansler T. Atlanta: The American Cancer Society Inc; 2001:577-609.
6. Gullu I, Yalcin S, Tekuzman G, Barista I, Alkis N, Celik I, Zengin N, Guler N, Kars A and Baltali E et al.: **High-dose ifosfamide by infusion with Mesna in advanced refractory sarcomas.** *Cancer Invest* 1996, **14**:239-42. [PMID: 8630686]
7. Barista I, Tekuzman G, Yalcin S, Gullu I, Guler N, Ozisik Y, Kars A, Celik I, Turker A, Altundag K, Zengin N, Uner A, Baltali E and Firat D: **Treatment of advanced soft tissue sarcomas with ifosfamide and doxorubicin combination chemotherapy.** *J Surg Onco* 2000, **73**:12-6.
8. Yalcin S, Gullu I, Barista I, Tekuzman G, Ozisik Y, Celik I and Kars A: **Treatment of advanced refractory sarcomas with ifosfamide and etoposide combination chemotherapy.** *Cancer Invest* 1998, **16**:297-302.
9. Yalcin S, Barista I, Tekuzman G, Güllü I and Fýrat D: **Dramatic response to ifosfamide, mesna and doxorubicine chemotherapy regimen in an adult with clear cell sarcoma of the kidney.** *Journal of Urology* 1996, **155**:224.

Publish with **BioMed Central** and every scientist can read your work free of charge

"BioMed Central will be the most significant development for disseminating the results of biomedical research in our lifetime."

Sir Paul Nurse, Cancer Research UK

Your research papers will be:

- available free of charge to the entire biomedical community
- peer reviewed and published immediately upon acceptance
- cited in PubMed and archived on PubMed Central
- yours — you keep the copyright

Submit your manuscript here:
http://www.biomedcentral.com/info/publishing_adv.asp

