

Contents lists available at [ScienceDirect](https://www.sciencedirect.com)

## International Journal of Surgery Case Reports

journal homepage: [www.casereports.com](http://www.casereports.com)

## Perforated diverticulitis in the setting of ulcerative colitis: An unusual case report

M. Baimas-George, L. Cetrulo, A. Kao, K.R. Kasten\*

Division of Gastrointestinal and Minimally Invasive Surgery, Department of Surgery, Carolinas Medical Center, Charlotte, NC, United States

## ARTICLE INFO

## Article history:

Received 20 April 2018

Received in revised form 12 June 2018

Accepted 20 June 2018

Available online 3 July 2018

## Keywords:

Case report

Diverticulitis

Ulcerative colitis

Inflammatory bowel disease

Colonic perforation

## ABSTRACT

**INTRODUCTION:** The association of diverticulitis with ulcerative colitis (UC) is rare and not well described. The sequelae of inflammatory bowel disease (IBD) such as perforation and fistula formation can mimic diverticular complications. Therefore, in an IBD patient, it can be difficult to distinguish the etiology of such complications and render definitive care.

**PRESENTATION OF CASE:** A 43-year-old man with a long history of UC presented with spontaneous sigmoid perforation and subsequent complications of colovesicular and colocutaneous fistulae requiring multiple procedural interventions. Ultimately, the etiology was confirmed as perforated diverticulitis superimposed on severe ulcerative colitis.

**DISCUSSION:** As perforated diverticulitis superimposed on UC is a rare entity in the current literature and there are many diagnostic difficulties that complicate this scenario. It is important to rule out other entities such as misdiagnosis of IBD or segmental colitis associated with diverticula (SCAD) that may have overlapping features.

**CONCLUSION:** Although diverticulitis in the setting of UC is an uncommon presentation, it remains important for medical practitioners to consider this scenario when encountering patients who may present in a similar fashion. As such, we put forth a process to aid in a diagnosis and management such that definitive care may not be delayed.

© 2018 The Author(s). Published by Elsevier Ltd on behalf of IJS Publishing Group Ltd. This is an open access article under the CC BY-NC-ND license (<http://creativecommons.org/licenses/by-nc-nd/4.0/>).

## 1. Introduction

Ulcerative colitis (UC) with superimposed diverticulitis is uncommon and there are currently few reports identifying such presentations; one study cited a prevalence of 0.3% [1–3]. Complications from inflammatory bowel disease (IBD) can resemble diverticular sequelae. Colonic perforations and enterovesicular fistulas are more common in Crohn's disease, a diagnosis that alters surgical treatment; and segmental colitis associated with diverticula (SCAD) manifests comparably to IBD creating diagnostic challenges [4–9]. Therefore, in IBD, it can be difficult to distinguish the etiology of such complications and render definitive care. We present a 43-year old male with apparent sigmoid colon perforation in setting of diverticulitis and UC who was a diagnostic challenge secondary to a history of IBD and chronic pain. We review the literature of IBD with diverticular disease and the diagnostic difficulties that complicate the clinical scenario, and put forth a process for aid in diagnosis and management of patients who present in similar fashion.

This work has been reported in line with the SCARE criteria [10].

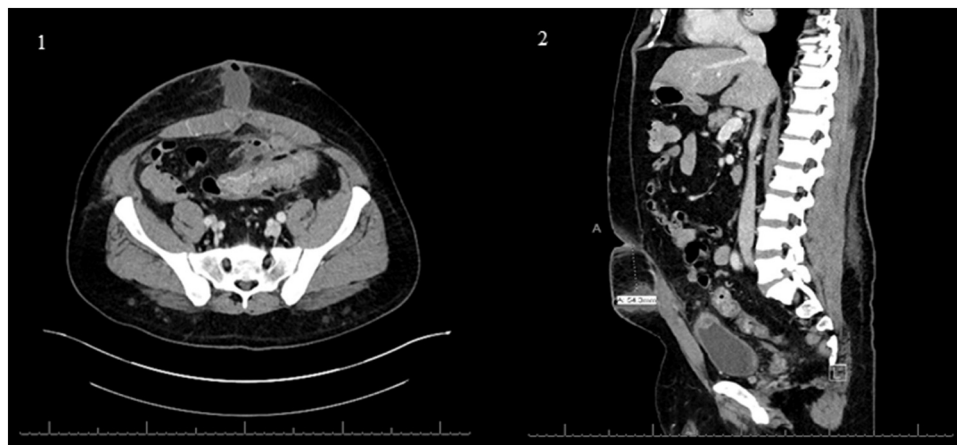
## 2. History

This 43-year old man's history began in 2007 with onset of bloody diarrhea. Colonoscopy diagnosed segmental sigmoid colon UC and treatment was initiated using prednisone before transitioning to Colazal. Due to persistent abdominal pain, he underwent repeat colonoscopy in 2009 showing abnormal sigmoid colon with edema, erythema, purulent exudate and contact bleeding. Pathology confirmed chronic inflammatory infiltrate with acute inflammatory cells, focal cryptitis and lack of granulomas or dysplasia. Diverticulosis was not noted and treatment for UC (infliximab, 6 MP and mesalamine) continued with reasonable symptom control. In 2016, a colonoscopy revealed diffuse continuous ulceration, erosions, congestion and granularity throughout entire colon and rectum, all without indication of backwash ileitis.

In May 2017, the patient presented with severe abdominal pain and diarrhea. Per report, his UC was stable on current therapy. GI PCR for *clostridium difficile* was positive and he received appropriate treatment, ultimately leading to resolution of diarrhea and negative PCR. He subsequently returned with two weeks of worsening lower abdominal pain, anorexia and intermittent fevers. Imaging in mid-June demonstrated left and sigmoid colon diverticulitis

\* Corresponding author at: Carolinas Medical Center, 1025 Morehead Medical Drive, Suite 300, Charlotte, NC 28204, United States.

E-mail address: [Kevin.kasten@carolinashealthcare.org](mailto:Kevin.kasten@carolinashealthcare.org) (K.R. Kasten).



**Figs. 1 and 2.** Colovesicular fistula and intra-abdominal abscess tracking towards the anterior abdominal wall.

with associated  $6 \times 5 \times 5$  cm abscess abutting the bladder requiring intravenous antibiotics and percutaneous drainage.

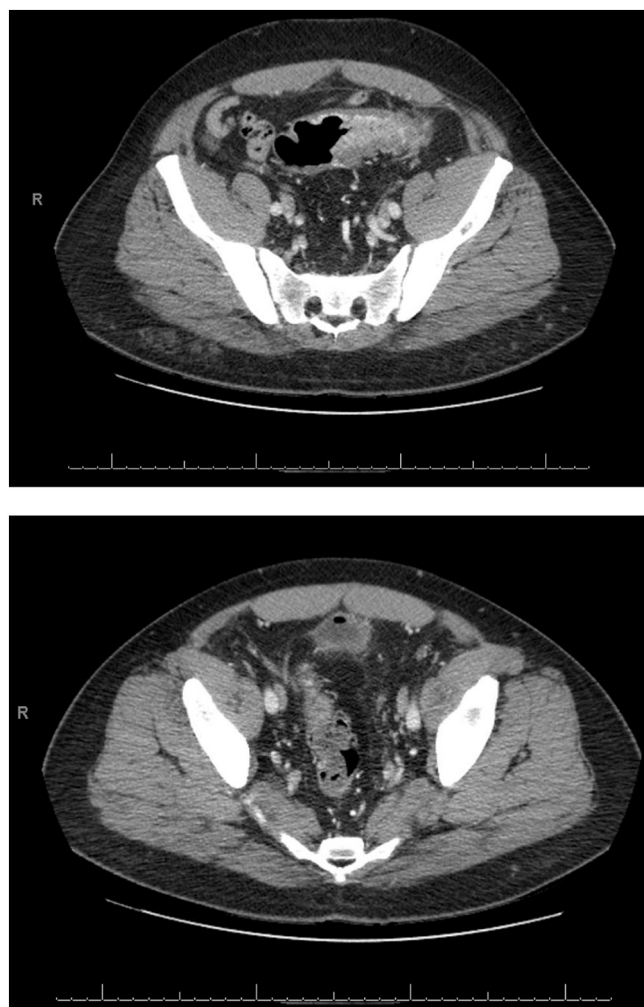Several months later, he moved cities and presented to our hospital, an academic institution, with another episode of significant abdominal pain. Of note, the patient was taken off infliximab and started on Apriso, but promptly stopped due to an allergy. After diagnostic evaluation demonstrated concern for colovesicular fistula and intraabdominal abscess tracking towards the abdominal wall (Figs. 1 and 2), patient underwent operative drainage. Although he initially did well postoperatively, he continued to complain of UC flares. Imaging demonstrated thickening of the distal descending and sigmoid colon with air adjacent to his bladder (Figs. 3 and 4). Due to the unclear etiology of his persistent inflammation, he was scheduled for diagnostic laparoscopy and colectomy to achieve symptom control and more definitive pathologic evaluation. Significant inflammation involving the sigmoid colon adherent to the anterior abdominal wall and left pelvic inlet was noted. The rectum and proximal descending colon were grossly normal, thus an end colostomy was fashioned. The patient was discharged on postoperative day 3, with foley catheter removed in clinic after CT cystogram.

The patient continued to report episodic abdominal pain and bloody diarrhea, consistent with flares. He underwent endoscopic evaluation demonstrating severe proctitis and pancolitis. Treatment with prednisone was initiated, however following one month of high-dose steroids, and three months after Hartmann's operation, he underwent a minimally-invasive total abdominal colectomy with end ileostomy and preservation of the rectum in anticipation of future proctectomy with ileopouch-anal anastomosis (IPAA). This operation was completed as patient could not wean from high-dose steroids, was becoming medically recalcitrant, and our team would not attempt pouch creation while on his prednisone dose. He tolerated this well and is currently awaiting his minimally-invasive IPAA.

### 3. Pathology

Pathologic evaluation of his sigmoid colon resection revealed acute and chronic diverticular disease with peridiverticular abscess formation (Fig. 5) in the background of chronic active colitis, without evidence of dysplasia or granulomas (Fig. 6). The pattern of mucosal inflammation was consistent with known UC.

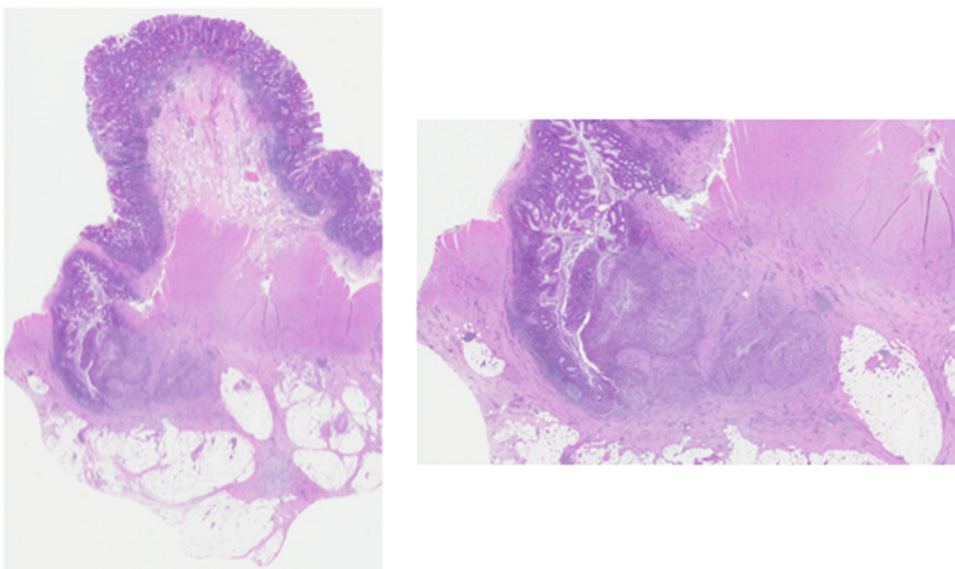
During his flares following Hartmann's procedure, repeat colonoscopy demonstrated pancolitis with biopsies again confirming UC. Following his total colectomy, patchy mildly active chronic colitis consistent with UC was seen.



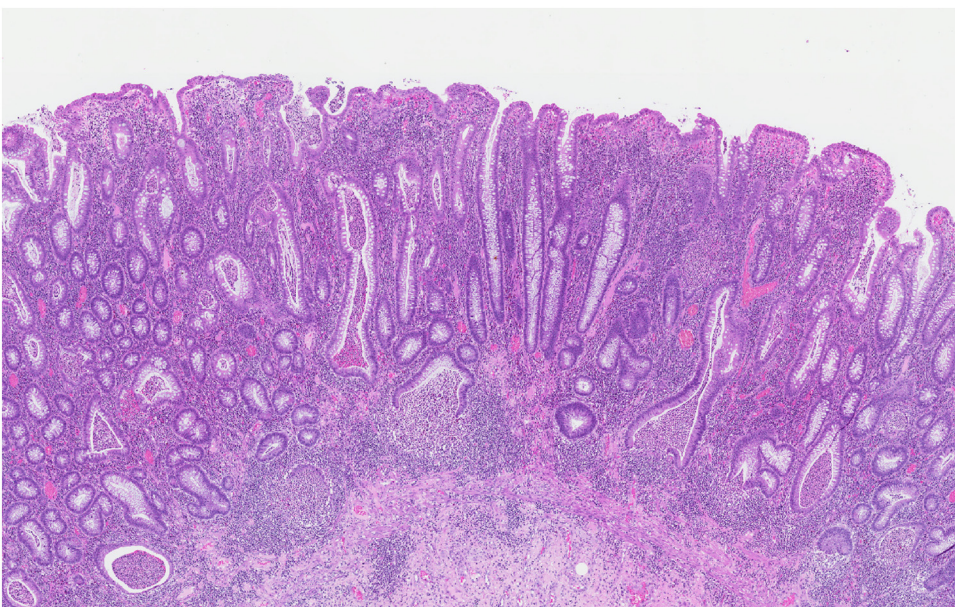
**Figs. 3 and 4.** Thickening of the distal descending and sigmoid colon and air near bladder tracking towards prior operative incision and drainage wound.

### 4. Discussion

Here we present a 43-year old male with apparent sigmoid colon perforation in setting of diverticulitis and UC who proved a diagnostic dilemma due to history of IBD, chronic abdominal pain, and recent move complicating history taking and evaluation. His ultimate diagnosis of perforated diverticulitis complicated by



**Fig. 5.** Diverticulitis with peridiverticular abscess formation; H&E stain A) 0.5 magnification B) 2.0 magnification.



**Fig. 6.** 20× magnification, H&E stain; Background colonic mucosa with moderately active chronic colitis.

colovesicular and colocutaneous fistula in the setting of chronic UC is extremely uncommon in the literature. Given the low prevalence of diverticulosis in young IBD patients, let alone perforated diverticulitis superimposed on UC, clinicians must consider alternate diagnoses including misdiagnosis of IBD and SCAD [1,3].

The prevalence of diverticular disease with UC is rare with estimated prevalence of 0.3% [1–3]. Casseri's prospective study of 600 patients demonstrated a significant decrease of diverticulosis in UC compared with general population [3]. In older patients, diverticulosis is more likely to predate UC, possibly related to a protective effect on diverticular formation through defects in colonic smooth muscle contraction [1]. Interestingly, Sultan investigated whether this causative relationship existed and demonstrated significantly later onset of IBD in patients with diverticular disease. They proposed that diverticulosis creates an ideal colonic microenvironment through inflammation and bacterial overgrowth that triggers IBD [11]. Other small studies have described acute or

fulminant UC after diverticular disease, leading to a marked rise in morbidity and mortality [12]. Beranbaum described the radiographic findings of acute diverticulitis with UC and hypothesized that chronic UC with scar formation can destroy diverticular ostia, which may partially explain the rarity of dual disease presentation [4]. While critical to rule out more common etiologies of colonic perforation, clinicians should include this rare entity.

Given the setting of the patient's intestinal perforation with fistula, Crohn's disease was also considered. Perforations are more common in Crohn's with rates of <2% [4–7]. Enterovesicular fistulae are reported to occur in <6% of Crohn's patients, usually ileovesical [5,13,14]. Colovesical fistulae are most commonly secondary to diverticulitis, accounting for 71% of all cases [15]. The possibility of misdiagnosis is well-established in the literature; a national survey found 10% of responders were misdiagnosed with UC instead of Crohn's and a change in diagnosis between the diseases occurs in 3.3% [16,17]. Misdiagnosis of UC is more likely in patients present-

ing with non-bloody diarrhea or weight loss [18]. This diagnostic ambiguity results from significant phenotypic variability, heterogeneity in endoscopy, absence of defining histology, non-specific pathologic characteristics, and exceptions to classic IBD pathologies [19,20]. Feakins demonstrated the difficulty in sub-classifying IBD based off colorectal biopsies, outlining a multitude of “pitfalls” challenging accurate identification [21]. Up to 20% of adult and 33% of pediatric patients are labeled with indeterminate colitis, creating a need for further molecular staining and continued multi-disciplinary diagnostic approach to tailor treatment [22,23]. In our patient, diagnostic uncertainty led to limited surgical resection for management of his perforation and resultant fistulae, as it should when the differential diagnosis includes Crohn’s.

Segmental colitis associated with diverticula was also a consideration, which identifies patients with chronic mucosal inflammation at the diverticular segment of the sigmoid colon that spares the rectum and proximal colon. SCAD is rare, occurring in only 1.3% [8] and manifests similarly to IBD with comparable extraintestinal presentations, making it difficult to distinguish [9]. Like IBD, SCAD typically presents with rectal bleeding, urgency, and tenesmus, and has analogous pathologic and endoscopic findings [9,24–26]. There is no consensus on its diagnosis, although several criteria are proposed. Inflammatory changes must be present only in the diverticular segments of the colon and, unlike UC, there must be complete rectal sparing. SCAD mimics the histological features of Crohn’s, often containing transmural granulomas, ulcerations, and crypt abscesses [27,28]. Similar to Crohn’s, the granulomatous reaction is secondary to compromised blood flow leading to mucosal injury, ischemia, and altered bacterial environment [28]. A literature review demonstrated biopsy similarities and histology to UC, with proposed pathophysiology involving genetically predisposed patients, aberrant immune systems, and imbalanced microbiomes, suggesting SCAD may either progress, or be related to, UC [9]. UC patients, even with relative rectal sparing per gross endoscopic exam, will have some degree of rectal inflammation, making a rectal biopsy essential for differentiation [8].

Our patient presented a diagnostic conundrum across multiple hospitals before undergoing definitive therapy. After pathologic evaluation, the etiology of his acute presentation appeared secondary to perforated diverticulitis in the setting of UC. SCAD was ruled out after rectal biopsy demonstrated moderately active colitis. Further, there was no evidence of Crohn’s on pathology to suggest misdiagnosis. Making this determination allows for definitive therapy, with or without IPAA, and cure of his IBD. While the patient will require an additional procedure for completion colectomy, conservative bowel resection in this setting was the right decision and our recommendation for other surgeons. As always, it remains important for medical practitioners to consider the above discussion when encountering these patients.

## Disclosures

All authors confirm they have no relevant disclosures.

## Conflict of interest

None.

## Funding

None.

## Ethical approval

Ethical approval for the submission of this case report has been exempted by my institution.

## Consent

Written informed consent was obtained from the patient for publication of this case report and accompanying images. A copy of the written consent is available for review by the Editor-in-Chief of this journal on request.

## Author contributions

**M. Baimas-George:** Drafted and revised article.

**L. Cetrulo:** Second surgeon of the case; Revised article.

**A. Kao:** Revised article.

**K.R. Kasten:** First surgeon of the case; article conception, supervision, and revision.

## Registration of research studies

N/A.

## Guarantor

Kevin Kasten.

## Acknowledgment

We wish to thank Dr. Michal Kamionek for his assistance with pathologic evaluation and providing necessary figure photos.

## References

- [1] A. Rispo, et al., Lower prevalence of diverticulosis in patients with ulcerative colitis, *Dis. Colon Rectum* 50 (8) (2007) 1164–1168.
- [2] A. Tursi, et al., Inflammatory manifestations at colonoscopy in patients with colonic diverticular disease, *Aliment. Pharmacol. Ther.* 33 (3) (2011) 358–365.
- [3] C. Cassieri, et al., Prevalence of colonic diverticulosis in patients affected by ulcerative colitis: a prospective study, *J. Clin. Gastroenterol.* 50 (Suppl. 1) (2016) S33–5.
- [4] S.L. Beranbaum, M. Yaghmai, E.R. Beranbaum, Ulcerative colitis in association with diverticular disease of the colon, *Radiology* 85 (5) (1965) 880–886.
- [5] A.J. Greenstein, A.H. Aufses Jr., Differences in pathogenesis, incidence and outcome of perforation in inflammatory bowel disease, *Surg. Gynecol. Obstet.* 160 (1) (1985) 63–69.
- [6] A.J. Greenstein, et al., Spontaneous free perforation and perforated abscess in 30 patients with Crohn’s disease, *Ann. Surg.* 205 (1) (1987) 72–76.
- [7] A. Softley, et al., Perforation of the intestine in inflammatory bowel disease. An OMGE survey, *Scand. J. Gastroenterol. Suppl.* 144 (1988) 24–26.
- [8] L.M. Makapugay, P.J. Dean, Diverticular disease-associated chronic colitis, *Am. J. Surg. Pathol.* 20 (1) (1996) 94–102.
- [9] A.M. Mulhall, et al., Diverticular disease associated with inflammatory bowel disease-like colitis: a systematic review, *Dis. Colon Rectum* 52 (6) (2009) 1072–1079.
- [10] R.A. Agha, et al., The SCARE Statement: consensus-based surgical case report guidelines, *Int. J. Surg.* 34 (2016) 180–186.
- [11] K. Sultan, et al., The nature of inflammatory bowel disease in patients with coexistent colonic diverticulosis, *J. Clin. Gastroenterol.* 40 (4) (2006) 317–321.
- [12] D.C. Collins, The grave prognosis of ulcerative colitis engrafted upon acute diverticulitis coli, *Am. J. Gastroenterol.* 35 (1961) 222–229.
- [13] J. Kyle, C.M. Murray, Ileovesical fistula in Crohn’s disease, *Surgery* 66 (3) (1969) 497–501.
- [14] J.E. Teitelbaum, et al., Infliximab in pediatric Crohn disease patients with enterovesicular fistulas, *J. Pediatr. Gastroenterol. Nutr.* 44 (2) (2007) 279–282.
- [15] S.G. Pollard, et al., Colovesical fistula, *Ann. R. Coll. Surg. Engl.* 69 (4) (1987) 163–165.
- [16] H.S. Lee, et al., Change in the diagnosis of inflammatory bowel disease: a hospital-based cohort study from Korea, *Intest. Res.* 14 (3) (2016) 258–263.
- [17] E. Team, The Invisible Journal of IBD: 2017 in America Results [cited 2018 March 30, 2018]; Available from: 2017 <https://crohnsdisease.com/infographic/invisible-journey-ibd-in-america/>.

- [18] G.Y. Melmed, et al., Predicting a change in diagnosis from ulcerative colitis to Crohn's disease: a nested, case-control study, *Clin. Gastroenterol. Hepatol.* 5 (5) (2007) 602–608, quiz 525.
- [19] R. Odze, Diagnostic problems and advances in inflammatory bowel disease, *Mod. Pathol.* 16 (4) (2003) 347–358.
- [20] G.E. Tontini, et al., Differential diagnosis in inflammatory bowel disease colitis: state of the art and future perspectives, *World J. Gastroenterol.* 21 (1) (2015) 21–46.
- [21] R.M. Feakins, Ulcerative colitis or Crohn's disease? Pitfalls and problems, *Histopathology* 64 (3) (2014) 317–335.
- [22] G.T. Martland, N.A. Shepherd, Indeterminate colitis: definition, diagnosis, implications and a plea for nosological sanity, *Histopathology* 50 (1) (2007) 83–96.
- [23] Y.R. Yu, J.R. Rodriguez, Clinical presentation of Crohn's, ulcerative colitis, and indeterminate colitis: symptoms, extraintestinal manifestations, and disease phenotypes, *Semin. Pediatr. Surg.* 26 (6) (2017) 349–355.
- [24] M.A. Peppercorn, Drug-responsive chronic segmental colitis associated with diverticula: a clinical syndrome in the elderly, *Am. J. Gastroenterol.* 87 (5) (1992) 609–612.
- [25] G.E. Sladen, M.I. Filipe, Is segmental colitis a complication of diverticular disease? *Dis. Colon Rectum* 27 (8) (1984) 513–514.
- [26] G.M. Van Rosendaal, M.A. Andersen, Segmental colitis complicating diverticular disease, *Can. J. Gastroenterol.* 10 (6) (1996) 361–364.
- [27] L. Ludeman, N.A. Shepherd, What is diverticular colitis? *Pathology* 34 (6) (2002) 568–572.
- [28] A. Gledhill, M.F. Dixon, Crohn's-like reaction in diverticular disease, *Gut* 42 (3) (1998) 392–395.

#### Open Access

This article is published Open Access at [sciencedirect.com](https://www.sciencedirect.com). It is distributed under the [IJSCR Supplemental terms and conditions](#), which permits unrestricted non commercial use, distribution, and reproduction in any medium, provided the original authors and source are credited.