



Immune tolerance strategies in siblings with infantile Pompe disease – Advantages for a preemptive approach to high-sustained antibody titers



Elizabeth O. Stenger^a, Zoheb Kazi^b, Emily Lisi^c, Michael J. Gambello^c, Priya Kishnani^{b,*}

^a Aflac Cancer and Blood Disorders Center, Children's Healthcare of Atlanta, Emory University, Atlanta, GA, United States

^b Division of Medical Genetics, Department of Pediatrics, Duke University Medical Center, Durham, NC, United States

^c Division of Medical Genetics, Department of Human Genetics, Emory University, Atlanta, GA, United States

ARTICLE INFO

Available online 15 June 2015

Keywords:

Infantile Pompe disease
Immune tolerance induction
High sustained antibody titers
Bortezomib

ABSTRACT

Enzyme replacement therapy (ERT) has led to a significant improvement in the clinical course of patients with infantile Pompe disease (IPD), an autosomal recessive glycogen storage disorder characterized by the deficiency in lysosomal acid α -glucosidase. A subset of IPD patients mounts a substantial immune response to ERT developing high sustained anti-rhGAA IgG antibody titers (HSAT) leading to the ineffectiveness of this treatment. HSAT have been challenging to treat, although preemptive approaches have shown success in high-risk patients (those who are cross-reactive immunological material [CRIM]-negative). More recently, the addition of bortezomib, a proteasome inhibitor known to target plasma cells, to immunotherapy with rituximab, methotrexate, and intravenous immunoglobulin has shown success at significantly reducing the anti-rhGAA antibody titers in three patients with HSAT. In this report, we present the successful use of a bortezomib-based approach in a CRIM-positive IPD patient with HSAT and the use of a preemptive approach to prevent immunologic response in an affected younger sibling. We highlight the significant difference in clinical course between the two patients, particularly that a pre-emptive approach was simple and effective in preventing the development of high antibody titers in the younger sibling, thus supporting the role of immune tolerance induction (ITI) in the ERT-naïve high-risk setting.

© 2015 The Authors. Published by Elsevier Inc. This is an open access article under the CC BY-NC-ND license (<http://creativecommons.org/licenses/by-nc-nd/4.0/>).

1. Introduction

Enzyme replacement therapies (ERT) have significantly improved the lifespan and clinical outcomes of patients with lysosomal storage disorders and other inherited disorders, such as Pompe disease. Pompe disease is an autosomal recessive glycogen storage disease characterized by a deficiency in lysosomal acid α -glucosidase (GAA) [1]. The classic infantile form of Pompe disease (IPD) results from complete or near complete deficiency of GAA leading to a severe clinical phenotype [2,3]. Untreated IPD leads to death by 2 years of age due to cardiorespiratory failure [4,5]. Recombinant human GAA (rhGAA, alglucosidase alfa, Genzyme, Cambridge, MA) was FDA approved in 2006 for the treatment of Pompe disease, and its use in IPD has significantly improved the course of disease [2,3,6–9]. The effectiveness of rhGAA treatment depends on several factors including age, stage of disease at start of treatment, and the development of anti-rhGAA IgG antibodies [10,11].

Anti-rhGAA IgG antibodies develop in 89% of IPD patients treated with rhGAA [12], with a large majority developing immunological tolerance with continued treatment [10,11]. A subset of IPD patients forms high sustained anti-rhGAA IgG antibody titers (HSAT; defined as $\geq 1:51,200$

on two occasions ≥ 6 months from the start of ERT) which have been shown to negatively impact clinical outcomes [11,13]. The majority of patients with HSAT produce no native GAA enzyme and are designated cross-reactive immunological material (CRIM)-negative [14]. CRIM-positive patients produce low levels of GAA enzyme (either functioning or non-functioning), and while they are expected to form tolerance to rhGAA, a subset of CRIM-positive patients (both infantile and late onset cases) also develops HSAT [14,15].

The elimination of anti-rhGAA IgG antibodies, particularly HSAT, has been challenging. Initial immune suppression strategies (with combinations of rituximab, intravenous immunoglobulin [IVIg], plasmapheresis, methotrexate, and cyclophosphamide) have required prolonged use of these agents and have been met with limited to no success in patients with HSAT, suggesting that it is extremely hard to eliminate long-lived plasma cells. Timing of immune tolerance induction (ITI) is thus critical in order to prevent an immune response [13,16]. Prophylactic ITI has therefore been instituted in high-risk CRIM-negative patients, and these regimens have been shown to prevent the development of anti-rhGAA IgG antibodies and achieve immune tolerance [17]. The failure of ITI with previous regimens, particularly in the setting of HSAT, has been hypothesized to be due to failure to target antibody-secreting plasma cells [13]. Bortezomib, a proteasome inhibitor that is FDA approved for the treatment of multiple myeloma, depletes plasma cells

* Corresponding author.

E-mail address: priya.kishnani@duke.edu (P. Kishnani).

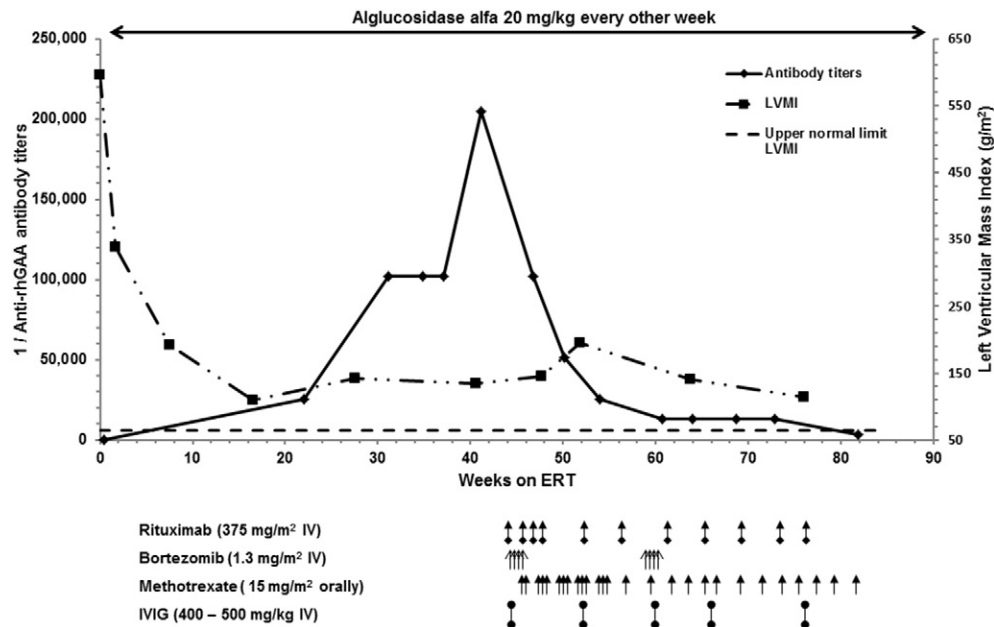


Fig. 1. Bortezomib-based immune tolerance induction (ITI) strategy in Patient 1 with high-sustained antibody titers (HSAT). Patient 1 developed HSAT (1:102,400) approximately 8 months into treatment with alglucosidase alfa (20 mg/kg every 2 weeks) which coincided with slight worsening of left ventricular mass index (LVMI; g/m^2 with upper normal limit of LVMI designated as $64 \text{ g}/\text{m}^2$ per published reports [24]) and worsening of clinical status. A bortezomib-based four drug ITI strategy was initiated at approximately 11 months of age with concomitant decline in antibody titers from peak of 1:204,800 (prior to start of ITI) to 1:51,200. A second course of bortezomib was repeated at that time with subsequent decline of antibody level to 1:3200. Decrease in LVMI corresponded with decrease in antibody level.

and may mitigate damage to skeletal muscle [18–21]. Based upon these effects, bortezomib was added to an ITI regimen of rituximab, IVIG, and methotrexate and was shown to successfully eliminate HSAT in three IPD patients (two CRIM-positive, one CRIM-negative) who had concomitant improvements in clinical measures [22].

Herein we present two brothers with IPD treated with ITI — one with this four drug bortezomib-based ITI regimen in the setting of HSAT and the second as prophylaxis with the three drug ITI regimen (rituximab, methotrexate and IVIG) during initiation of treatment with rhGAA. Differences are highlighted showing the advantages of earlier treatment as well as institution of an ITI regimen in the prophylactic setting in a high-risk infant.

2. Methods

Both patients met criteria for classic IPD per standard criteria [22] and were CRIM-positive by mutation analysis and Western blot (Patient 1: Integrated Genetics, Westborough, MA; Patient 2: Duke University, Durham, NC). Anti-rhGAA IgG antibody titers were evaluated serially by Genzyme. Analysis of left ventricular mass index (LVMI, in g/m^2) was performed as previously described [2]. To monitor B-cell recovery, flow cytometry was used to assess CD19% using standard methods. Both patients were enrolled in this study (# 00001562) for CRIM determination and longitudinal follow-up which was Institutional Review Board (IRB)-approved through Duke University (LDN6709 Site 206; NCT01665326). Written informed consent for ITI was obtained from the patients' parents for this study in November 2013. Patient 1 (index case) developed HSAT and received a bortezomib-based regimen as outlined in Fig. 1 and based on published case series [22]. Patient 2 received prophylactic ITI at the time of initiation of treatment with rhGAA as outlined in Fig. 2 and as previously published [17]. Followup is reported on both patients through December 2014.

3. Results

Patient 1 was a 10-month-old African American male born full term and diagnosed as a neonate with classic IPD. Shortly after birth, he

developed supraventricular tachycardia with Wolff–Parkinson–White syndrome and hypertrophic cardiomyopathy. These findings, in addition to mild macroglossia and hypotonia, prompted evaluation for IPD. Genetic testing demonstrated a missense change in allele 1 (c.2105G>T) and a nonsense mutation in allele 2 (c.2512C>T) in the GAA gene. Parental testing confirmed that each parent carried one mutation. The missense mutation in allele 1 results in leucine replacing arginine 702 (p.Arg702Leu), a nucleotide change reported previously in only one individual with Pompe disease [23]. The mutation in allele 2 was predicted to result in a premature stop (p.Gln838X), a nucleotide change not previously reported but predicted to be disease causing. CRIM status was determined as CRIM-positive by Western blot analysis (Integrated Genetics). Treatment with alglucosidase alfa (20 mg/kg every 2 weeks) was initiated at age 23 days with improvement in clinical status, particularly LVMI (Fig. 1). Swallow study as a neonate demonstrated aspiration, therefore he received feeds via a nasogastric tube.

Seronegative status was confirmed prior to initiation of ERT. After approximately 5 months of ERT, the patient developed detectable anti-rhGAA IgG antibodies, initially at a titer of 1:25,600 (Fig. 1). He then developed HSAT with titer of 1:102,400 on two occasions with concomitant worsening of clinical status. Treatment with a bortezomib-based ITI was initiated based on published data [22] around 11 months of age with subsequent decline in antibody titers. Three and a half months into ITI, bortezomib was repeated (due to antibody titer remaining at 1:51,200) resulting in a subsequent decline to 1:1200. CD19⁺ B-cells decreased to <1% of total while blood cell (WBC) count approximately 2 months from the start of ITI and remained <1% (Table 1). Rituximab was weaned to every 8 weeks beginning approximately 9 months into ITI.

Prior to initiation of ITI, the patient was not requiring respiratory support. He developed respiratory failure requiring invasive ventilation on three occasions, all due to viral respiratory tract infections (with respiratory syncytial virus, rhinovirus, and rhinovirus/adenovirus respectively) and/or aspiration. Infection and/or aspiration in the setting of advanced disease were clinically felt to be the primary trigger for these events. Given that the patient was receiving IVIG and had normal WBC count and absolute neutrophil count throughout his admissions,

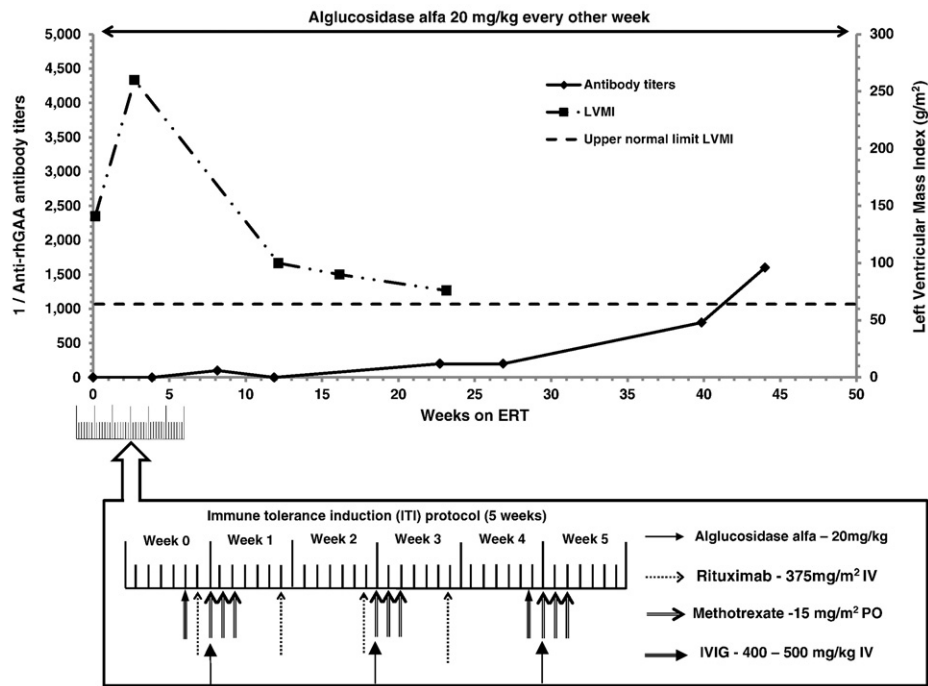


Fig. 2. Prophylactic immune tolerance induction (ITI) in Patient 2. Patient 2 received a five week course of prophylactic ITI with rituximab, IVIG and methotrexate which was initiated prior to first dose of alglucosidase alfa (20 mg/kg every 2 weeks). Left ventricular mass index (LVMI; g/m^2 with upper normal limit of LVMI designated as $64 \text{ g}/\text{m}^2$ per published reports [24]) peaked prior to start of enzyme replacement therapy (ERT) with subsequent decline. Antibody titer remained low during and following ITI on continued ERT.

immune suppression from ITI was clinically felt to have a minor etiologic role. Following the second admission, he was discharged home on BiPAP at night. During the third admission (around age 20 months), a tracheostomy was placed due to repeated failure at extubation. Gastrostomy tube was placed around 19 months of age and ultimately converted to a gastrojejun tube due to concerns of recurrent aspiration. Both a tracheostomy and a gastrostomy tube were recommended during previous admissions, but the family was unwilling to proceed until the third admission. The delay in these procedures likely contributed to the repeated and prolonged admissions.

The patient had significant decline in his motor development. Following his first admission, the patient was admitted to inpatient rehabilitation for 17 days, during which time he was pulling to stand and sitting independently. These developmental gains coincided with decline in antibody titers. Following his second admission, he was admitted to inpatient rehabilitation for 14 days, during which time he was no longer pulling to stand or sitting. He was able to hold objects in his hands, clap his hands, and place objects in his mouth, and he did have good head control. On most recent

assessment by Physical Medicine and Rehabilitation (December 2014), he was unable to hold his head up or bring his hands to his mouth. He was able to hold objects when they were placed in his hand, but otherwise he had little movement of his extremities and no obvious antigravity movements.

Patient 2 was a 3-week-old African American male born full term who was diagnosed with classic IPD prenatally due to his brother's known disease status. Genetic testing was performed on prenatal amniocentesis at 18 weeks and demonstrated a missense change in allele 1 (c.2105G>T) and a nonsense mutation in allele 2 (c.2512C>T) in the GAA gene (identical to brother's testing). The diagnosis was confirmed by blood GAA enzyme level on day of life 2. Based upon his brother's disease phenotype with the development of HSAT despite early initiation of ERT, prophylactic ITI with rituximab, methotrexate, and IVIG was initiated at the time of first alglucosidase alfa dose (20 mg/kg every 2 weeks; Fig. 2). Seronegative status was confirmed prior to the initiation of ERT. The patient seroconverted after two months of alglucosidase alfa with anti-rhGAA IgG antibody titer of 1:100, but antibody levels remained low through continued treatment with maximum level of 1:3200 at 12 months. This was in contrast to the older sibling's titer of 1:204,800 at age of 10 months. $\text{CD}19^+$ B-cells decreased to <1% of total WBC three weeks from the start of ITI and normalized by approximately 5 months (Table 1). Antibody titers have remained low ranging from 1:200 to 1:3200 following normalization of B-cell counts. His baseline LVMI was markedly elevated at $252 \text{ g}/\text{m}^2$ prior to initiation of ERT and steadily decreased over time (Fig. 2). Following the completion of ITI, the LVMI normalized. He has been receiving physical and occupational therapy for mild developmental delays. At 12 months of age, he was sitting independently and standing with support, and at age 18 months, he began walking. He has been tolerating a normal diet by mouth with no clinical concerns for aspiration. His weight has increased from <3rd percentile to the 15th percentile, and his height remains at the 15–50th percentile for age. His immunizations were held during ITI, but they were resumed with recovery of B-cell counts and were up-to-date.

Table 1
Effect of ITI on percentage and absolute number of $\text{CD}19^+$ B lymphocytes.

Weeks on ERT	Patient 1		Patient 2	
	% CD19	# CD19	% CD19	# CD19
0	38	1524	32	928
3	–	–	<1	3
7	–	–	<1	4
10	<1	<1	–	–
17	<1	9	–	–
20	<1	<1	–	–
22	–	–	40	2035
36	<1	1	–	–
44	<1	1	–	–

4. Discussion

ERTs have significantly improved clinical outcomes and survival in patients with many inherited diseases, but the development of immune responses to ERT can negate these effects. While CRIM-negative IPD patients are most likely to develop HSAT, they can occur in CRIM-positive patients [14,15,25]. Patients with IPD who develop HSAT have very poor treatment outcomes, and ITI regimens with rituximab, methotrexate, IVIG and bortezomib have shown success at reducing the antibody titers [22]. Without the addition of bortezomib, there has been limited to no success in the elimination of HSAT [11,13]. Given the success with the bortezomib-based regimen and the elimination of HSAT in patients with an established immune response, this regimen was initiated in Patient 1 and resulted in a 64-fold decrease in antibody titers [17,22]. This patient received only 2 cycles of bortezomib, showing rapid responsiveness to the high titers with addition of bortezomib, in contrast to prior publications without its use [13,26]. As there is significant concordance in clinical progression in classic IPD [27], the sibling was treated in the ERT-naïve setting and has continued to have low antibody titers. The two patients presented expand upon the use of a bortezomib-based regimen for HSAT and extend the use of preemptive ITI to a high-risk CRIM-positive patient, the latter of which is no different from the CRIM-negative high-risk setting. The proband developed high antibody titers despite starting ERT early (within the first month of life) further adding to the understanding, especially with newborn screening for Pompe disease on the horizon, that early ERT does not necessarily prevent the development of HSAT.

The three previously reported patients appeared to tolerate the bortezomib-based regimen well with steady clinical improvements correlating with decline in antibody titers [22]. Our Patient 1 also did not appear to have adverse events related to ITI, although he had a complicated clinical course felt to be secondary to advanced disease. At the beginning of each admission for respiratory failure, he had at least 1 virus isolated on nasopharyngeal culture, and 2 of 3 admissions were preceded by an event clinically consistent with aspiration. Aspiration was also felt to complicate his respiratory failure during each admission. His need for respiratory support appeared to escalate between admissions coinciding with continued disease progression in the setting of HSAT. Tracheostomy was discussed during each admission and gastrostomy tube during the latter two admissions, but the family preferred to continue to monitor him closely without these procedures. Delay in tracheostomy and gastrostomy tube placement may have contributed to recurrent aspiration events and admissions for respiratory failure. This highlights the importance of supportive care in these complicated patients.

While successful ITI using a bortezomib-based regimen was initiated after the development of HSAT in Patient 1, this case highlights several key observations: 1) the development of HSAT even when ERT is initiated early (in this case by age 26 days), 2) the challenges in abrogating antibody titers in the entrenched setting, and 3) the inability to completely recover from possibly irreversible muscle damage when titers are high, rendering ERT essentially ineffective. Regarding the latter point, as antibody titers take weeks to decline to clinically insignificant levels and continued accumulation of glycogen furthers muscle damage, enzyme is less likely to have an effect during this period of HSAT and disease continues to progress. These patients are also at high-risk for aspiration events and typically sensitive to minor viral respiratory infections, as evidenced by our patient's clinical course. While the ITI regimen used is immune suppressive, this was felt to be a minor trigger for respiratory failure in our patient relative to his advanced IPD.

Comparable to that reported in high-risk CRIM negative patients, Patient 2 received a short course of three drug ITI beginning 1 day prior to the initiation of ERT at age 21 days (which is similar to the proband) [17]. There is little variability in the clinical course of IPD (in contrast to late onset disease) and significant concordance in clinical phenotype has been demonstrated between siblings ($R = 0.6$) [27]. Thus, it is very

likely that this patient would have developed HSAT if not treated preemptively with ITI, and while the role of other minor factors in his favorable outcome cannot be excluded (such as favorable genetic polymorphisms), such factors are unlikely to have contributed significantly. The advantages of preemptive ITI are highlighted in this patient, including exposure to fewer ITI drugs, shorter duration of therapy, and improved clinical outcome by preventing prolonged exposure to HSAT. While both patients began ERT early in life, they have had significant differences in outcome related to the development (or prevention) of HSAT.

Precious time is wasted in a rapidly progressive disorder such as IPD. In patients at high-risk for developing HSAT, including CRIM-negative patients and affected siblings of CRIM-positive patients with HSAT, short course ITI with rituximab, IVIG and methotrexate can prevent the development of HSAT and improve clinical outcomes. In patients who have already developed HSAT, a bortezomib-based ITI can successfully and rapidly decrease antibody levels to a clinically insignificant level compared to regimens that do not target plasma cells. Similar to our previous report, this regimen was overall well tolerated with adverse events felt primarily to be due to advanced disease and not to the ITI regimen. ITI should be initiated as early as possible, as clinical response to ERT is minimal with persistent HSAT. It is critical, therefore, that we continue to find ways to predict which patients are at high-risk for HSAT (aside from CRIM status) or treat all cases with a regimen that is safe and well tolerated so that preemptive ITI can be initiated in these patients to improve clinical outcomes.

Acknowledgments

We thank Kathryn L. Berrier, MS, CGC for her assistance in enrolling the patients to Institutional Review Board (IRB)-approved Protocol 00001562 through Duke University (LDN6709 Site 206; NCT01665326). This research was supported by the ACTSI KL2-Mentored Clinical and Translational Research Program (EOS) and the National Institutes of Health (NIH) Grant KL2TR000455 (EOS). This research was also supported in part by a grant from the Genzyme Corporation (PK), a Sanofi Company (Cambridge, MA), and in part by the Lysosomal Disease Network (PK), a part of NIH Rare Diseases Clinical Research Network (RDCRN). The Lysosomal Disease Network (U54NS065768) is a part of NIH RDCRN, supported through collaboration between the NIH Office of Rare Diseases Research (ORDR) at the National Center for Advancing Translational Science (NCATAS), the National Institute of Neurological Disorders and Stroke (NINDS), and National Institute of Diabetes and Digestive and Kidney Diseases (NIDDK). ZBK is also supported by the University of Minnesota and Lysosomal Disease Network fellowship (NIH U54NS065768). The content is solely the responsibility of the authors and does not necessarily represent the official views of the NIH. The funders had no role in the study design, data collection and analysis, decision to publish, or preparation of the manuscript.

References

- [1] P.S. Kishnani, R.D. Steiner, D. Bali, K. Berger, et al., Pompe disease diagnosis and management guideline, *Genet Med* 8 (2006) 267–288 Disease AWGoMoP.
- [2] P.S. Kishnani, M. Nicolino, T. Voit, R.C. Rogers, A.C. Tsai, et al., Chinese hamster ovary cell-derived recombinant human acid alpha-glucosidase in infantile-onset Pompe disease, *J Pediatr* 149 (2006) 89–97.
- [3] A. Amalfitano, A.R. Bengur, R.P. Morse, J.M. Majure, L.E. Case, et al., Recombinant human acid alpha-glucosidase enzyme therapy for infantile glycogen storage disease type II: results of a phase I/II clinical trial, *Genet Med* 3 (2001) 132–138.
- [4] H.M. van den Hout, W. Hop, O.P. van Diggelen, J.A. Smeitink, G.P. Smit, et al., The natural course of infantile Pompe's disease: 20 original cases compared with 133 cases from the literature, *Pediatrics* 112 (2003) 332–340.
- [5] P.S. Kishnani, W.L. Hwu, H. Mandel, M. Nicolino, F. Yong, et al., A retrospective, multinational, multicenter study on the natural history of infantile-onset Pompe disease, *J Pediatr* 148 (2006) 671–676.
- [6] P.S. Kishnani, D. Corzo, M. Nicolino, B. Byrne, H. Mandel, et al., Recombinant human acid [alpha]-glucosidase: major clinical benefits in infantile-onset Pompe disease, *Neurology* 68 (2007) 99–109.

- [7] P.S. Kishnani, D. Corzo, N.D. Leslie, D. Gruskin, A. Van der Ploeg, et al., Early treatment with alglucosidase alpha prolongs long-term survival of infants with Pompe disease, *Pediatr Res* 66 (2009) 329–335.
- [8] M. Nicolino, B. Byrne, J.E. Wraith, N. Leslie, H. Mandel, et al., Clinical outcomes after long-term treatment with alglucosidase alfa in infants and children with advanced Pompe disease, *Genet Med* 11 (2009) 210–219.
- [9] S.N. Prater, S.G. Banugaria, S.M. DeArmedy, E.G. Botha, E.M. Stege, et al., The emerging phenotype of long-term survivors with infantile Pompe disease, *Genet Med* 14 (2012) 800–810.
- [10] J. Wang, J. Lozier, G. Johnson, S. Kirshner, D. Verthelyi, et al., Neutralizing antibodies to therapeutic enzymes: considerations for testing, prevention and treatment, *Nat Biotechnol* 26 (2008) 901–908.
- [11] S.G. Banugaria, S.N. Prater, Y.K. Ng, J.A. Kabori, R.S. Finkel, et al., The impact of antibodies on clinical outcomes in diseases treated with therapeutic protein: lessons learned from infantile Pompe disease, *Genet Med* 13 (2011) 729–736.
- [12] Myozyme (2006) [Package Insert], Cambridge (MA): Genzyme Corporation.
- [13] S.G. Banugaria, T.T. Patel, J. Mackey, S. Das, A. Amalfitano, et al., Persistence of high sustained antibodies to enzyme replacement therapy despite extensive immunomodulatory therapy in an infant with Pompe disease: need for agents to target antibody-secreting plasma cells, *Mol Genet Metab* 105 (2012) 677–680.
- [14] P.S. Kishnani, P.C. Goldenberg, S.L. DeArmedy, J. Heller, D. Benjamin, et al., Cross-reactive immunologic material status affects treatment outcomes in Pompe disease infants, *Mol Genet Metab* 99 (2010) 26–33.
- [15] T.T. Patel, S.G. Banugaria, L.E. Case, S. Wenninger, B. Schoser, et al., The impact of antibodies in late-onset Pompe disease: a case series and literature review, *Mol Genet Metab* 106 (2012) 301–309.
- [16] N.J. Mendelsohn, Y.H. Messinger, A.S. Rosenberg, P.S. Kishnani, Elimination of antibodies to recombinant enzyme in Pompe's disease, *N Engl J Med* 360 (2009) 194–195.
- [17] Y.H. Messinger, N.J. Mendelsohn, W. Rhead, D. Dimmock, E. Hershkovitz, et al., Successful immune tolerance induction to enzyme replacement therapy in CRIM-negative infantile Pompe disease, *Genet Med* 14 (2012) 135–142.
- [18] P.G. Richardson, B. Barlogie, J. Berenson, S. Singhal, S. Jagannath, et al., A phase 2 study of bortezomib in relapsed, refractory myeloma, *N Engl J Med* 348 (2003) 2609–2617.
- [19] K. Neubert, S. Meister, K. Moser, F. Weisel, D. Masada, et al., The proteasome inhibitor bortezomib depletes plasma cells and protects mice with lupus-like disease from nephritis, *Nat Med* 14 (2008) 748–755.
- [20] E. Gazzo, S. Assereto, A. Bonetto, F. Sotgia, S. Scarfi, et al., Therapeutic potential of proteasome inhibition in Duchenne and Becker muscular dystrophies, *Am J Pathol* 176 (2010) 1863–1877.
- [21] B.C. Beehler, P.G. Sleph, L. Benmassaoud, G.J. Grover, Reduction of skeletal muscle atrophy by a proteasome inhibitor in a rat model of denervation, *Exp Biol Med* (Maywood) 231 (2006) 335–341.
- [22] S.G. Banugaria, S.N. Prater, J.K. McGann, J.D. Feldman, J.A. Tannenbaum, et al., Bortezomib in the rapid reduction of high sustained antibody titers in disorders treated with therapeutic protein: lessons learned from Pompe disease, *Genet Med* 15 (2013) 123–131.
- [23] M. Kroos, R.J. Pomponio, L. van Vliet, R.E. Palmer, M. Phipps, et al., Update of the Pompe disease mutation database with 107 sequence variants and a format for severity rating, *Hum Mutat* 29 (2008) E13–E26.
- [24] M. Vogel, W. Staller, K. Buhlmeyer, Left ventricular myocardial mass determined by cross-sectional echocardiography in normal newborns, infants, and children, *Pediatr Cardiol* 12 (1991) 143–149.
- [25] J.M. de Vries, N.A. van der Beek, M.A. Kroos, L. Ozkan, P.A. van Doorn, et al., High antibody titer in an adult with Pompe disease affects treatment with alglucosidase Alfa, *Mol Genet Metab* 101 (2010) 338–345.
- [26] T.E. Hunley, D. Corzo, M. Dudek, P. Kishnani, A. Amalfitano, et al., Nephrotic syndrome complicating alpha-glucosidase replacement therapy for Pompe disease, *Pediatrics* 114 (2004) e532–e535.
- [27] W.E. Smith, J.A. Sullivan-Saarela, J.S. Li, G.F. Cox, D. Corzo, et al., Sibling phenotype concordance in classical infantile Pompe disease, *Am J Med Genet A* 143A (2007) 2493–2501.