



A Case-Based Review of Management of CNS Melioidosis

Debajyoti Datta¹ Arunkumar Sekar¹ Ashis Patnaik¹ Srujana Mohanty²

¹Department of Neurosurgery, All India Institute of Medical Sciences, Bhubaneswar, Odisha, India

²Department of Microbiology, All India Institute of Medical Sciences, Bhubaneswar, Odisha, India

Address for correspondence Arunkumar Sekar, Department of Neurosurgery, All India Institute of Medical Sciences, Bhubaneswar, Odisha 751019, India (e-mail: arunkumar3002@hotmail.com).

Asian J Neurosurg 2023;18:836–838.

Introduction

India is recently witnessing a surge in cases of melioidosis, usually considered an endemic disease and an important public health problem in Southeast Asia and Northern Australia.¹ It is caused by *Burkholderia pseudomallei*, an environmental saprophytic gram-negative bacterium, which predominantly affects persons with diabetes mellitus and various other underlying predispositions such as heavy alcohol intake, chronic pulmonary disease, chronic renal disease, glucocorticoid therapy, and malignancy. The clinical manifestations range from a mild subacute disease with localized lesions to a fulminant septicemic form. Involvement of central nervous system (CNS) is an unusual event. We report a case of intracranial melioidosis manifested as a brain abscess in an occupationally unexposed patient, who had an excellent outcome owing to appropriate neurosurgical intervention, accurate etiological identification, and effective antibiotic therapy.

Case Report

A 48-year-old lady was presented to the emergency room with a history of headache for the last 10 days, holocranial in nature, associated with episodes of vomiting followed by altered sensorium for last 2 days. She was a known diabetic and hypertensive on irregular medication. She was drowsy on examination with right hemiparesis. Her noncontrast computed tomography head, upon admission, showed a hypodense space-occupying lesion present in left parietal region with significant perilesional edema, and midline shift toward right present. Extradural collection was present in

the left parietal region along with developing infarct in the left posterior cerebral artery territory. Contrast-enhanced magnetic resonance imaging done outside showed T1 hypointense, T2 hyperintense, ring enhancing lesion present in left parietal region with restriction of diffusion suggestive of abscess. Extradural collection was present over the left parietal region with contrast enhancement of the dura suggestive of extradural empyema. In view of her poor sensorium, she was immediately intubated and taken up for urgent surgery. All the three samples (intraparenchymal pus, extradural collection, and excised dura) yielded pure growth of *B. pseudomallei* sensitive to ceftazidime, meropenem, and trimethoprim–sulfamethoxazole. Postoperative imaging (→Fig. 1) showed complete evacuation of the abscess cavity. Her echocardiography, blood culture, and other systemic evaluation did not reveal any infective foci. The patient recovered well from surgery and improved in neurology at 1-year follow-up.

Discussion

B. pseudomallei, the causative organism of melioidosis, is a gram negative, opportunistic, facultative intracellular, motile, saprophytic bacterium, endemic to South and Southeast Asia, China, and Northern Australia.² Melioidosis was first identified in Rangoon in 1911 by Alfred Whitmore, a British doctor and his assistant, CS Krishnaswami.³ Infection by *B. pseudomallei* can be acute, chronic, or latent, although in immunocompetent individuals it most commonly presents as a subclinical infection. Only those patients who are clinically symptomatic are considered to have melioidosis.³ Routes of infection of *B. pseudomallei* are

DOI <https://doi.org/10.1055/s-0043-1776736>.
ISSN 2248-9614.

© 2023. Asian Congress of Neurological Surgeons. All rights reserved.

This is an open access article published by Thieme under the terms of the Creative Commons Attribution-NonDerivative-NonCommercial-License, permitting copying and reproduction so long as the original work is given appropriate credit. Contents may not be used for commercial purposes, or adapted, remixed, transformed or built upon. (<https://creativecommons.org/licenses/by-nc-nd/4.0/>)

Thieme Medical and Scientific Publishers Pvt. Ltd., A-12, 2nd Floor, Sector 2, Noida-201301 UP, India

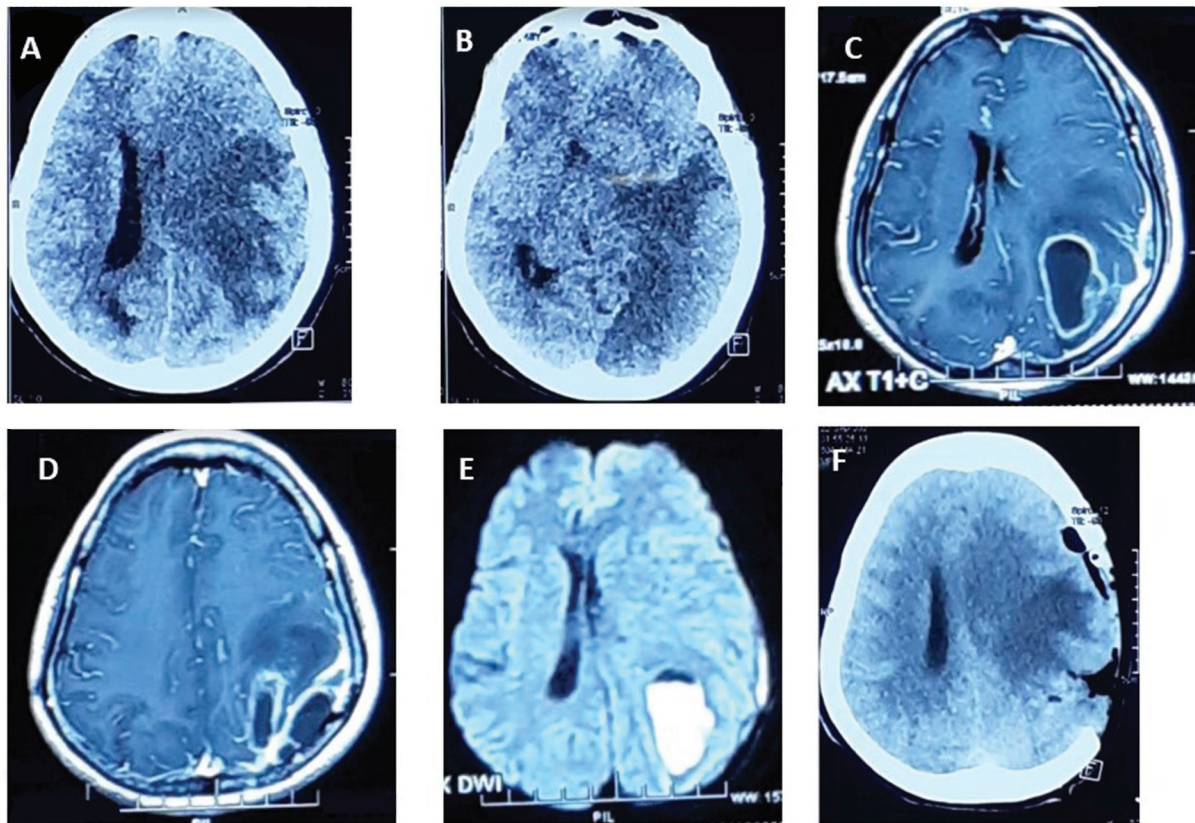


Fig. 1 (A) Preoperative computed tomography showing hypodense space-occupying lesion present in the left parietal region with significant perilesional edema and midline shift toward left. (B) Preoperative computed tomography brain showing developing infarct in left posterior cerebral artery territory. (C) Preoperative magnetic resonance imaging brain showing ring enhancing lesion present in the left parietal region. (D) Preoperative contrast-enhanced magnetic resonance imaging brain showing presence of extradural collection in left parietal region with enhancement of the dura. (E) Preoperative diffusion-weighted image showing presence of diffusion restriction within the lesion. (F) Postoperative computed tomography brain showing complete evacuation of the abscess cavity. Parietal craniectomy defect present.

through ingestion, inhalation, and skin penetration. Nosocomial infections have also been reported to occur through contaminated wound irrigation fluid, antiseptics, and hand wash.^{4,5} The average incubation period of period of melioidosis is 9 days.⁶ CNS is rare, with 1.5 to 5% cases of melioidosis having a neurological involvement.¹ The usual presentation of melioidosis is pneumonia.³ Diabetes mellitus is the most significant risk factor for the development of melioidosis, conferring a 12-fold higher risk. Excess alcohol use, liver disease, prolonged steroid use, and immunosuppression are other risk factors.²

Wongwangdee and Linasmita in their review of CNS melioidosis found that the median age of the affected patients was 40 years, the youngest being 10 days old and the oldest aged 75 years.² Most of the patients identified in their review were acute melioidosis. Encephalomyelitis was the most common presentation followed by cerebral abscess. Patients with cerebral abscess presented with fever, unilateral weakness, and altered sensorium. Fifty-six percent patients had neck stiffness and 40% patients developed seizures. Cranial nerve palsies were reported in 48% cases with facial palsy being the most common. Frontal and parietal lobe, cerebellar hemispheres, and brainstem are the most common sites affected by CNS melioidosis.

The diagnosis of cerebral abscess due to *B. pseudomallei* can be made by imaging followed by isolation of the organism. Pus from the abscess, brain tissue, or cerebrospinal fluid (CSF) can be used for culture. Routine examination of the CSF shows mononuclear pleocytosis with increased protein and decreased glucose levels. Blood culture can also grow *B. pseudomallei* suggestive of hematogenous spread. If there is an overlying infection of the cranial bones or the scalp, these can also be used for culture. Serology with indirect hemagglutinin assay is not reliable enough for clinical practice.³

Medical management of *B. pseudomallei* includes an intensive phase of 8 weeks and an eradication phase of 6 months. Guidelines recommend ceftazidime and meropenem to be the drug of choice for intensive phase and trimethoprim-sulfamethoxazole for eradication therapy.⁷ Surgical management is warranted to establish the diagnosis and to relieve the mass effect. No definite guidelines are available regarding the choice of surgical strategy for cerebral abscess due to melioidosis. Available options are burr hole and tapping of abscess with stereotaxy if available for surgical drainage of the abscess with excision. The surgical strategy must be decided on a case-by-case basis by the treating surgeon.

Conclusion

B. pseudomallei causing cerebral abscess is a rare pathology and may pose a diagnostic dilemma. Appropriate and rapid diagnosis along with treatment should be initiated as this presentation is associated with a high mortality (25%).⁸

Ethical Approval and Consent to Participate

Institute ethical standards were followed. Consent to participate was taken from individual patient.

Consent for Publication

Publication consent taken from the patient and the parent.

Availability of Data and Material

All available data presented in the article.

Authors' Contributions

A.S. was involved in patient care and preparation of the final draft. D.D. helped in first draft preparation, review of literature, and patient care. A.P. and S.M. were involved in patient care.

Funding

None.

Conflict of Interest

None declared.

References

- 1 Mohapatra PR, Mishra B. Burden of melioidosis in India and South Asia: challenges and ways forward. *Lancet Reg Health Southeast Asia* 2022;2:100004
- 2 Wongwande M, Linasmita P. Central nervous system melioidosis: a systematic review of individual participant data of case reports and case series. *PLoS Negl Trop Dis* 2019;13(04):e0007320
- 3 Wiersinga WJ, Virk HS, Torres AG, et al. Melioidosis. *Nat Rev Dis Primers* 2018;4(01):17107
- 4 Merritt AJ, Peck M, Gayle D, et al. Cutaneous melioidosis cluster caused by contaminated wound irrigation fluid. *Emerg Infect Dis* 2016;22(08):1420–1427
- 5 Gal D, Mayo M, Smith-Vaughan H, et al. Contamination of hand wash detergent linked to occupationally acquired melioidosis. *Am J Trop Med Hyg* 2004;71(03):360–362
- 6 Currie BJ, Fisher DA, Anstey NM, Jacups SP. Melioidosis: acute and chronic disease, relapse and re-activation. *Trans R Soc Trop Med Hyg* 2000;94(03):301–304
- 7 Lipsitz R, Garges S, Aurigemma R, et al. Workshop on treatment of and postexposure prophylaxis for *Burkholderia pseudomallei* and *B. mallei* Infection, 2010. *Emerg Infect Dis* 2012;18(12):e2
- 8 Chadwick DR, Ang B, Sitoh YY, Lee CC. Cerebral melioidosis in Singapore: a review of five cases. *Trans R Soc Trop Med Hyg* 2002;96(01):72–76