

Total hip arthroplasty (S-ROM stem) and subtrochanteric osteotomy for Crowe type IV developmental dysplasia of the hip

Liangtao Li, Mingyang Yu¹, Chen Yang, Guishan Gu

ABSTRACT

Background: Developmental dysplasia of the hip (DDH) in adults with severe pain and disability is best treated by total hip arthroplasty (THA). The purpose of this study was to retrospectively evaluate the outcomes of subtrochanteric shortening osteotomy combined with THA using S-ROM stem for those severe patients with a special focus on the effect of two shapes in the subtrochanteric osteotomy ends: Oblique and transverse.

Materials and Methods: Twenty one cases with mean age of 43.6 years who met inclusion criteria and were operated between February 2007 and February 2012 were included in the study. Those cases had been divided into two groups (oblique vs. transverse) and all records between the two groups were analyzed.

Results: The Harris hip score significantly improved from 30.6 (range 18–59) preoperatively to 91.2 (range 87–98) postoperatively by the latest followup. Complications including one deep venous thrombosis, one intraoperative fracture of femur and two dislocations occurred while they were addressed properly afterward. The oblique group showed significant advantages in operative time, union time and additional fixation in comparison with the transverse group.

Conclusions: In the primary THA for the treatment of irreducible DDH, subtrochanteric oblique osteotomy combined with the freely-rotatable S-ROM stem provided favorable short term outcomes by affording both morphological and functional advantages.

Key words: Developmental dysplasia of the hip, S-ROM stem, subtrochanteric oblique osteotomy, total hip arthroplasty

MeSH terms: Hip dysplasia, congenital, hip dislocation, hip replacement, total, osteotomy

INTRODUCTION

Developmental dysplasia of the hip (DDH) Crowe type-IV is a myriad of abnormalities of the hip joint due to the long term dislocation of the femoral head, which constitute a lot of difficulties for restoration of normal hip anatomy. Total hip arthroplasty (THA) in those patients with severe DDH has traditionally been associated with higher failure and complication rates. The optimal

surgical treatment for the patients with high dislocation of the hip remains controversial. Most authors suggest that the rotational center should be at the level of the true acetabulum because of the reduced contact hip stress and a low failure rate of cups reported by many literatures.^{1,2} In such circumstances, the femur should be shortened in order to reduce the hip easily and to avoid excessive limb length.³

Various osteotomy techniques have been described to shorten the femur. Those techniques can be classified as three types: Intertrochanteric,⁴ subtrochanteric⁵ and supracondylar⁶ osteotomy. Intertrochanteric osteotomy has the limited ability to shorten the femur and destroys the metaphysis, which provides anti-rotation resistance for stem. The supracondylar osteotomy increases the wound surface and makes a second surgery necessary. Hence, more and more attention has been paid on subtrochanteric osteotomy and four kinds of shapes have been developed at the osteotomy ends. Of those shapes, both step-cut⁷ and double-chevron⁸ osteotomies have a complex operation, although the two shapes techniques seem to make the osteotomy site more stable. Recently, more and more researchers focus on oblique⁹ and transverse¹⁰ osteotomy technique.

Department of Joint Surgery, The First Hospital of Jilin University, Changchun 130021, Jilin, ¹Affiliated Zhongshan Hospital of Dalian University, Dalian 116001, Liaoning, P. R. China

Address for correspondence: Prof. Guishan Gu, Department of Joint Surgery, The First Hospital of Jilin University, No. 71, Xinmin Street, Changchun 130021, Jilin, P. R. China. E-mail: guguishan13@163.com

Access this article online	
Quick Response Code:	Website: www.ijoonline.com
	DOI: 10.4103/0019-5413.177575

The S-ROM prosthesis becomes the optimal choice in this cohort of patients with completely dislocated hips due to its versatility.¹¹ Correction of the increased femoral anteversion found in patients with DDH is facilitated by derotational osteotomy in conjunction with a modular femoral stem. This study reports our experience of subtrochanteric shortening osteotomy and S-ROM stem to treat Crowe type IV developmental dysplasia of the hip.

MATERIALS AND METHODS

21 primary THAs with subtrochanteric shortening and derotational osteotomies in 17 patients secondary to severe DDH conducted between 2007 and 2012 were included in this study. All cases were type IV according to Crowe's classification¹² (among 11 bilateral patients in the study, 7 patients included only one hip with high dislocation). There were 11 females and 6 males with a mean age at surgery of 43.6 years (range 17–63 years). The indications for THA were severe pain and/or considerable difficulty in walking and performing activities of daily living [Table 1]. The study protocol had been approved by the institutional review board of our hospital. Written informed consents were obtained from all the individuals in this manuscript to publish these case details.

None of the patients had undergone Schanz osteotomy previous to this study. All hips were evaluated by use of the Harris hip score (HHS) preoperatively. Abductor function was assessed according to Trendelenburg signs. The patients were assessed preoperatively by standard anteroposterior (AP) and lateral radiographs of the pelvis and hip, lumbosacral spine and lower limbs. Limb-length discrepancy (LLD) was appraised on the plain film of lower limbs. Parameters of the true acetabulum, including location, size, depth and anteversion angle as well as a bone defect of anterior or posterior borders, obtained by CT (Siemens Medical Solutions, Germany) scan. Hip dislocation height was also measured on the radiographs based on methods of the triangle of Ranawat.¹³ Templating on radiographs was used to determine the length, diameter and position of the femoral stem. Postoperatively, patients were kept at partial weight bearing for 6 weeks and progressed to full weight bearing thereafter. HHS and radiographs were obtained at regular postoperative intervals. No patients were lost to followup.

The radiographs were examined by an independent senior radiologist who experienced in reviewing orthopedic radiographs. Radiographs of the hip prosthesis were evaluated using the Gruen *et al.*¹⁴ method and the DeLee and Charnley¹⁵ method for the stem and the cup, respectively. Progressive radiolucency of over two

millimeters in width or migration of over five millimeters in any direction was considered to be loosening, with the pelvic teardrops used as reference points. The stability of femoral components was classified as bone ingrown, fibrous stable or unstable according to the system of Engh *et al.*¹⁶ Heterotopic ossification was evaluated according to the Brooker *et al.*¹⁷ classification.

Osteotomy healing was assessed using postoperative radiographs at an interval of 2 weeks during the healing period. Criteria for the union of the osteotomy included callus and no pain at the osteotomy site, restoration of cortical continuity between proximal and distal fragments on the AP or lateral radiograph and no progressive migration or gapping at the osteotomy site on serial radiographs.

All cases were divided into two groups according to the osteotomy configuration: Subtrochanteric oblique osteotomy was completed in 9 hips; the remained 12 hips were performed with subtrochanteric transverse osteotomy. The results were compared between these two groups. Statistical analysis was performed using SPSS version 21 software (SPSS, Inc., Chicago, Illinois, USA). Statistical significance was set at $P < 0.05$.

Operative procedure

Surgery was performed by the senior surgeons (GS Gu, JG Liu and X Qi) in our institute with the patient under general anesthesia. The surgical approach to the hip was the posterolateral and extensive incision for facilitating subtrochanteric osteotomy in all cases. Surgery was aimed at restoring the anatomic hip center.

The elongated hypertrophic joint capsule was resected, and the small fibrous fatty tissue filled acetabulum was identified. Approximately, 1 cm proximal to the lesser trochanter, the deformed femur head was removed using an L-shaped osteotomy appropriate for the S-ROM sleeve. The abductor muscles were left untouched; the piriformis tendon was sectioned and the psoas tendon was partially released. The fibers of the gluteus maximus were released proximally, and their direction was changed to become more vertical, thus facilitating the surgery. Laxity of the vastus lateralis due to the femoral shortening osteotomy was corrected by advancing the posterior half of the muscle to a more proximal insertion in the region of the greater trochanter. The acetabulum was then widened and deepened at a designated angle of abduction and anteversion.

Case 5 showed that the estimated cup coverage was <80%, thus structural autografting from the resected femoral head was performed in order to augment the superolateral

Table 1: Clinical details of patients

Case No.	Sex/age	Side	Osteotomy type	Followup (month)	Femoral shortening (mm)	Radiographic lengthening (mm)	Trendelenburg signs	Osteotomy union time	Complication	Intraoperative blood loss (ml)	Operative time (min)
1	Female/33	Right	Transverse	25	40	25	Yes	3.5	None	1200	145
2	Female/58	Left	Transverse	63	29	30	No	4.5	Dislocation	1000	198
3	Female/52	Right	Transverse	30	50	34	No	4.0	Deep vein thrombosis	1600	157
		Left	Transverse	29	50	34	No	3.5	Deep vein thrombosis	2000	175
4	Female/55	Right	Transverse	50	35	27	No	5.0	None	1200	151
5	Male/46	Right	Transverse	63	30	45	No	3.5	None	2700	210
6	Female/17	Left	Transverse	59	55	47	Yes	7.0	Dislocation	800	134
7	Female/32	Right	Transverse	87	38	43	No	4.0	None	4500	215
8	Male/21	Right	Transverse	88	25	29	No	3.5	None	2000	163
		Left	Transverse	89	25	29	No	3.5	None	1500	142
9	Male/20	Right	Transverse	95	46	20	Yes	3.5	None	1000	144
		Left	Transverse	96	46	20	Yes	3.0	None	800	126
10	Female/49	Right	Oblique	25	35	30	No	3.0	None	800	132
		Left	Oblique	24	35	30	No	3.5	None	1000	141
11	Male/50	Right	Oblique	28	25	45	No	3.0	None	1500	105
12	Female/50	Left	Oblique	33	31	37	No	4.0	Intraoperative fracture	2000	118
13	Female/51	Right	Oblique	29	40	32	No	3.0	None	1600	105
14	Female/63	Right	Oblique	27	45	28	Yes	3.5	None	2500	150
15	Male/44	Right	Oblique	39	50	24	Yes	3.0	None	1200	142
16	Female/45	Left	Oblique	31	47	27	No	3.0	None	1000	113
17	Female/56	Left	Oblique	27	39	36	No	2.5	None	800	96

bone defect. A cemented cup was used in case 2 for the acetabulum with a severe bone deficiencies in the anterior border. In all cases except the case 2, acetabular fixation was uncemented, and screws were utilized to increase cup stability.

Subtrochanteric oblique ($n = 9$) [Figure 1] or transverse ($n = 12$) [Figure 2] shortening and derotational osteotomy was performed according to the technique described by Huo *et al.*⁹ and Masonis *et al.*¹⁸ respectively. Below the lesser trochanter 1 cm, the oblique osteotomy was performed using an oscillating saw from an inferomedial direction toward a superolateral direction at 45° to the longitudinal axis of the femoral shaft. If the osteotomy line was perpendicular to the femoral shaft axis, it became transverse osteotomy. Intraoperatively, the surgeon decided whether the osteotomy site should be augmented. If, at the end of the procedure, there was any sign of instability at the osteotomy site, it must be revised or additional fixation used; and there were other cases requiring more robust fixation, such as in young men. All the patients in the study had implantation of the S-ROM three-piece femoral component made of titanium alloy without cement. During the operative procedures, we did not explore nor palpate the sciatic nerve to evaluate tensions. The operation time and intraoperative blood loss were recorded.

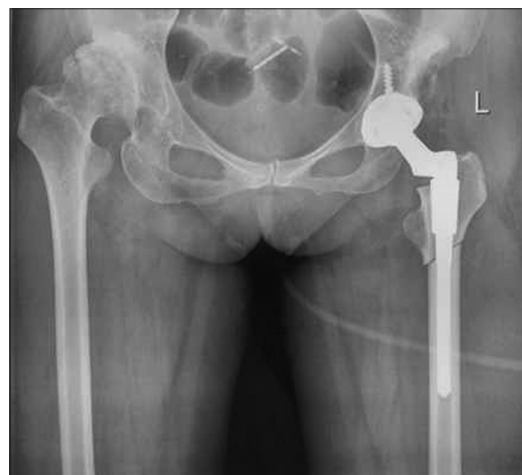

Figure 1: Immediate postoperative x-ray pelvis with proximal thigh and hip joint anteroposterior view showing subtrochanteric oblique osteotomy and total hip arthroplasty with S-ROM stem (case 17)

RESULTS

The mean followup period was 49.3 months (range 24–96 months). The average HHS was improved from 30.6 (range 18–59) preoperatively to 91.2 (range 87–98) postoperatively by the latest followup ($P < 0.01$). The femoral head was reduced into the anatomical acetabulum for each hip. In the 21 cases studied, the mean length of bone removed was 38.8 mm (range 25–55 mm).

Postoperatively, the average limb lengthening was 32 mm (range 20–47 mm). Mean LLD significantly decreased from 45 mm (range 19–70 mm) before surgery to 17 mm (range 8–32 mm) at latest followup evaluations. The mean duration of surgery was 145 min (range 96–215 min). Mean blood loss was 1557 ml (range 800–4500 ml). There was no significant difference between the two groups in the total blood loss ($P = 0.395$), but the operation time showed that the oblique group was shorter than the transverse group ($P < 0.05$) [Table 2]. All patients had positive Trendelenburg signs preoperatively. The sign became negative in 12 hips (57%) at one month after the operation. Two hips (9.5%) maintained a positive Trendelenburg sign resulting in a mild limp until the final followup.

All patients were treated with an S-ROM femoral stem (DePuy, Warsaw, Indiana). Cementless acetabular cup systems (DePuy, Warsaw, Indiana) were used in all patients except one cemented cup. Superolateral acetabular bone-grafting was performed in one hip. The mean outer

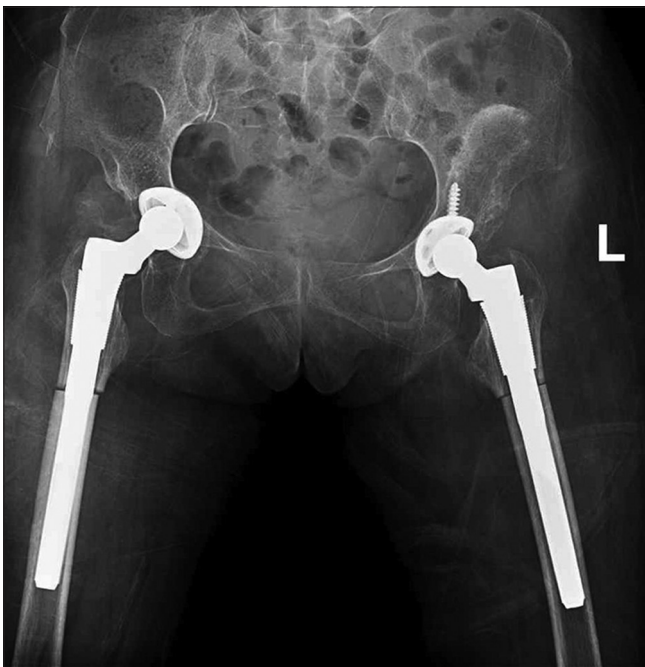


Figure 2: X-ray pelvis with both hip joints with proximal half of thigh anteroposterior view showing immediate postoperative subtrochanteric transverse osteotomy and total hip arthroplasty with S-ROM stem (case 3)

Table 2: The comparison between the oblique and transverse group*

Clinical outcomes	Oblique	Transverse	P
Intraoperative blood loss (ml)	1377.7±580.46	1691.6±1051.80	0.394
Operative time (min)	122.4±19.34	163.3±29.84	0.001
Bone removal	38.5±8.00	39.0±10.38	0.896
Osteotomy union time (month)	3.1±0.43	4.0±1.07	0.033
Additional fixation	1	7	0.037

*t-test was used for comparing intraoperative blood loss, operative time, osteotomy removal and osteotomy union time. Fisher's exact test was used for additional fixation

diameter of the acetabular components was 46 mm (range 42–54 mm). The mean diameter of the femur head was 25 mm (range 22–28 mm). The average distal diameter of the stems was 11 mm (range 8–13 mm). There was no significant difference between the two groups in the distal diameter of the stem and the cup ($P = 0.65$ and 0.32 , respectively). In transverse group, 5 cases needed to secure stability by allograft struts and cables and 2 cases by plate fixation with mean operation time 156 min (range 132–215 min). By contrast, in oblique group, only 1 case needed to be fixed by allograft struts and cables with operation time 114 min (range 96–150 min). There was a significant difference between the two groups in the additional fixation ($P = 0.037$) [Table 2].

No nonunion of the osteotomy site were observed by the latest followup. The mean period for osteotomy union was 3.7 months (range 2.5–7.0 months). There was significant difference between the two groups in the mean period for osteotomy union ($P = 0.033$), and in the transverse group, two delayed union occurred and the time for union (mean 4.0 months) was longer than the oblique group (mean 3.1 months).

There was no neurologic complication. No infection or loosening of the prosthesis was observed at the final followup. However, deep venous thrombosis developed in one case (case 3) and successfully managed by anti-coagulants. One intraoperative crack of the distal segment happened in case 12 and treated with cerclage wires (LINK, Hamburg, Germany) for fixation. Two dislocations (case 2 and 6) were encountered within 1-month postoperatively and managed with closed reduction under anesthesia.

DISCUSSION

Restoration of the distorted anatomy of the hip due to DDH with high dislocation is indispensable for successful THA. When the most severely dislocated femur (Crowe type IV) is reduced to the level of the original acetabulum, various osteotomies for shortening of the femur have been developed. Subtrochanteric shortening osteotomy has been advocated recently by most authors among those techniques.^{19,20} Our results are similar to other studies focused on THA in patients with highly dislocated hip;¹⁹ in addition, we tried to deepen our insight of configuration of osteotomy ends for rotational stability by comparison with the overall results of two types of osteotomy techniques (oblique versus transverse).

Putting the acetabular component at the anatomical acetabular level has been approved to be the best choice in DDH by different researches, because the biomechanics of

hips has been restored to normal and the failure rate of an acetabular component is evidently lower than other places. However, due to the hypoplasia of the true acetabulum, it is usually difficult to achieve sufficient coverage for an acetabular component. In such situation, we use small components deeply seated in order to obtain enough cup coverage. In our study, an autologous bulk bone-grafting was done in one case (case No. 5) and a cemented cup was used in one case (case 2). During the latest followup, we have seen no graft resorption and the union of the grafts was satisfactory. However, few studies have suggested that superolateral bone grafting may actually be unnecessary. Centralized reaming, medialization and using small cup components with screws, reliable fixation of the cup was always achieved without bone grafting and the need for superolateral acetabular grafting was eliminated.²¹ However, we insist that autologous bulk bone grafting or a cemented cup is needed in a few cases. The superolateral deficient acetabulum problem was been solved by a structural autogenous femoral head bone graft however cup coverage was still less than 80% through those methods. Even worse, if anatomical acetabulum has the anterior or posterior wall defects, the cemented acetabulum will be another choice (case 2).

After placing an acetabular component in the true acetabulum to restore the anatomic center of hip rotation, another consideration is high dislocation rate, nerve stretch and correction of the excessive femoral anteversion. All the goals can be achieved by subtrochanteric derotational shortening osteotomy. However, the nonunion of the osteotomy site is a major concern associated with this technique. Instability of the osteotomy site results in complications, such as a delayed union and nonunion, which have been reported from 0% to 13%.¹⁹

Different surgical techniques have been developed to increase rotational stability in the osteotomy site.⁴⁻⁶ One way is to increase the inherent rotational stability of the osteotomy technique itself by changing the shape of osteotomy ends. Step-cut and double chevron osteotomy have once advocated by some authors,²² but both the two techniques are complicated and time-consuming procedures. On the other hand, the oblique or transverse osteotomy has been reported with good or excellent results. So, those complicated procedures (step-cut and double chevron osteotomy) have abandoned by many authors.^{20,23} However, it is still controversial to decide which one is preferable to be used in the specific THA, the oblique osteotomy or the transverse osteotomy. Some authors criticise transverse osteotomy technique lacks rotational stability while other authors think that oblique osteotomy is more complex than transverse technique and cannot

correct excessive anteversion repetitiously by osteotomy technique itself.²⁴

The other way to increase rotational stability is utilization of the extra medullary fixation, such as allograft struts and cables or plate fixation.¹ The results indicate that oblique osteotomy is less needed for an extra medullary fixation with less operative time and has better performance in union time [Table 2] than the transverse group. Through S-ROM prosthesis, the need of adjusting the excessive anteversion of the distorted proximal femur by the osteotomy technique itself has been excluded.

Incongruence between proximal and distal canal diameters after subtrochanteric shortening osteotomy leads to problems regarding the achievements of secure fixation between osteotomy sites and might increase the likelihood of nonunion.²⁵ In that condition, the modular S-ROM stem will be the best choice due to its ability that providing rotational stability and compression pressure at the osteotomy site with a stepped proximal sleeve and polished distal flutes and fins individually in both the proximal and distal parts of the femur.¹¹ In addition, the S-ROM stem is a modular system designed to enable free adjustment of the rotation alignment of the stem neck around 360°, regardless of the type of rotational deformity of the proximal femur.²⁶ Furthermore, modular implants with trial sleeves can protect the fit of the stem in the proximal bone fragment during implant trialing. The length of the stem is vital in achieving stability. It must bypass the osteotomy by at least twice the diameter of the diaphysis.²⁷ This view is verified by our above mentioned biomechanics study, in which the distal fragment of the femur bears most of the stresses and plays a key role in the initial stability of the stem.

Although great progress has been achieved by performing various surgical techniques, results have not paralleled those of similar age-matched patients with primary degenerative joint disease of the hip.²⁸ In our series, one intraoperative fracture occurred in the distal fragment of the femur during implant impaction. Some authors suggest that the prophylactic wire should be employed.²⁹ In our series, we didn't use this strategy because whether this strategy indeed reduces the incidence of fractures has not yet been confirmed. Furthermore, in most cases, the fracture does not occur and the application of cerclage wires after fractures can also obtain satisfactory results even if fractures occur. So it does not constitute a necessity to adopt this strategy. Two postoperative dislocations occurred, which were attributed to slightly larger acetabular anteversion. This means it is very hard to completely correct the excessive anteversion in some cases. Nowadays, combined anteversion have been advocated and is effective for DDH patients who receive

those types of THA.³⁰ In future work, we will adopt this approach to reduce the risk of postoperative dislocation.

The limitations of this study are of retrospective nature, the relatively short followup used to determine the outcomes and the small number of patients enrolled. Hence, large-scale, long term followup studies are needed to confirm these benefits.

In conclusion, the combined use of the subtrochanteric oblique osteotomy and the S-ROM stem in THA for Crowe type IV DDH give satisfactory results.

REFERENCES

- Krych AJ, Howard JL, Trousdale RT, Cabanela ME, Berry DJ. Total hip arthroplasty with shortening subtrochanteric osteotomy in Crowe type-IV developmental dysplasia. *J Bone Joint Surg Am* 2009;91:2213-21.
- Eskelinen A, Helenius I, Remes V, Ylinen P, Tallroth K, Paavilainen T. Cementless total hip arthroplasty in patients with high congenital hip dislocation. *J Bone Joint Surg Am* 2006;88:80-91.
- Perry KI, Berry DJ. Femoral considerations for total hip replacement in hip dysplasia. *Orthop Clin North Am* 2012;43:377-86.
- Paavilainen T, Hoikka V, Solonen KA. Cementless total replacement for severely dysplastic or dislocated hips. *J Bone Joint Surg Br* 1990;72:205-11.
- Sponseller PD, McBeath AA. Subtrochanteric osteotomy with intramedullary fixation for arthroplasty of the dysplastic hip. A case report. *J Arthroplasty* 1988;3:351-4.
- Lai KA, Liu J, Liu TK. Use of iliofemoral distraction in reducing high congenital dislocation of the hip before total hip arthroplasty. *J Arthroplasty* 1996;11:588-93.
- Sener N, Tözün IR, Asik M. Femoral shortening and cementless arthroplasty in high congenital dislocation of the hip. *J Arthroplasty* 2002;17:41-8.
- Chareancholvanich K, Becker DA, Gustilo RB. Treatment of congenital dislocated hip by arthroplasty with femoral shortening. *Clin Orthop Relat Res* 1999;360:127-35.
- Huo MH, Zatorski LE, Keggi KJ. Oblique femoral osteotomy in cementless total hip arthroplasty. Prospective consecutive series with a 3-year minimum Followup period. *J Arthroplasty* 1995;10:319-27.
- Zadeh HG, Hua J, Walker PS, Muirhead-Allwood SK. Uncemented total hip arthroplasty with subtrochanteric derotational osteotomy for severe femoral anteversion. *J Arthroplasty* 1999;14:682-8.
- Mattingly DA. The S-ROM modular femoral stem in dysplasia of the hip. *Orthopedics* 2005;28:s1069-73.
- Crowe JF, Mani VJ, Ranawat CS. Total hip replacement in congenital dislocation and dysplasia of the hip. *J Bone Joint Surg Am* 1979;61:15-23.
- Ranawat CS, Dorr LD, Inglis AE. Total hip arthroplasty in protrusio acetabuli of rheumatoid arthritis. *J Bone Joint Surg Am* 1980;62:1059-65.
- Gruen TA, McNeice GM, Amstutz HC. "Modes of failure" of cemented stem-type femoral components: A radiographic analysis of loosening. *Clin Orthop Relat Res* 1979;17-27.
- DeLee JG, Charnley J. Radiological demarcation of cemented sockets in total hip replacement. *Clin Orthop Relat Res* 1976;20-32.
- Engh CA, Bobyn JD, Glassman AH. Porous-coated hip replacement. The factors governing bone ingrowth, stress shielding, and clinical results. *J Bone Joint Surg Br* 1987;69:45-55.
- Brooker AF, Bowerman JW, Robinson RA, Riley LH Jr. Ectopic ossification following total hip replacement. Incidence and a method of classification. *J Bone Joint Surg Am* 1973;55:1629-32.
- Masonis JL, Patel JV, Miu A, Bourne RB, McCalden R, Macdonald SJ, *et al.* Subtrochanteric shortening and derotational osteotomy in primary total hip arthroplasty for patients with severe hip dysplasia: 5-year Followup. *J Arthroplasty* 2003;18:68-73.
- Kiliçoglu OI, Türker M, Akgül T, Yazıcıoğlu O. Cementless total hip arthroplasty with modified oblique femoral shortening osteotomy in Crowe type IV congenital hip dislocation. *J Arthroplasty* 2013;28:117-25.
- Dallari D, Pignatti G, Stagni C, Giavaresi G, Del Piccolo N, Rani N, *et al.* Total hip arthroplasty with shortening osteotomy in congenital major hip dislocation sequelae. *Orthopedics* 2011;34:e328-33.
- Bernasek TL, Haidukewych GJ, Gustke KA, Hill O, Levering M. Total hip arthroplasty requiring subtrochanteric osteotomy for developmental hip dysplasia: 5- to 14-year results. *J Arthroplasty* 2007;22:145-50.
- Hotokebuchi T, Sonohata M, Shigematsu M, Mawatari M. A new device for a V-shaped subtrochanteric osteotomy combined with total hip arthroplasty. *J Arthroplasty* 2006;21:135-7.
- Reikerås O, Haaland JE, Lereim P. Femoral shortening in total hip arthroplasty for high developmental dysplasia of the hip. *Clin Orthop Relat Res* 2010;468:1949-55.
- Ermis MN, Dilaveroglu B, Erçeltik O, Tuhanioglu U, Karakas ES, Durakbasa MO. Intermediate-term results after uncemented total hip arthroplasty for the treatment of developmental dysplasia of the hip. *Eklemler Hastalıkları Cerrahisi* 2010;21:15-22.
- Yoon PW, Kim JI, Kim DO, Yu CH, Yoo JJ, Kim HJ, *et al.* Cementless total hip arthroplasty for patients with Crowe type III or IV developmental dysplasia of the hip: Two-stage total hip arthroplasty following skeletal traction after soft tissue release for irreducible hips. *Clin Orthop Surg* 2013;5:167-73.
- Tamegai H, Otani T, Fujii H, Kawaguchi Y, Hayama T, Marumo K. A modified S-ROM stem in primary total hip arthroplasty for developmental dysplasia of the hip. *J Arthroplasty* 2013;28:1741-5.
- Spitzer AI. The S-ROM cementless femoral stem: History and literature review. *Orthopedics* 2005;28:s1117-24.
- Boyle MJ, Frampton CM, Crawford HA. Early results of total hip arthroplasty in patients with developmental dysplasia of the hip compared with patients with osteoarthritis. *J Arthroplasty* 2012;27:386-90.
- Bruce WJ, Rizkallah SM, Kwon YM, Goldberg JA, Walsh WR. A new technique of subtrochanteric shortening in total hip arthroplasty: Surgical technique and results of 9 cases. *J Arthroplasty* 2000;15:617-26.
- Zhang J, Wang L, Mao Y, Li H, Ding H, Zhu Z. The use of combined anteversion in total hip arthroplasty for patients with developmental dysplasia of the hip. *J Arthroplasty* 2014;29:621-5.

How to cite this article: Li L, Yu M, Yang C, Gu G. Total hip arthroplasty (S-ROM stem) and subtrochanteric osteotomy for Crowe type IV developmental dysplasia of the hip. *Indian J Orthop* 2016;50:195-200.

Source of Support: Nil, **Conflict of Interest:** None.