

# Laparoscopic Repair of Abdominal Hernias Using an ePTFE Patch — A Modification of a Previously Described Technique

Eduardo Phillips, MD, Anthony N. Dardano, DO, Andrew Saxe, MD

## ABSTRACT

**Background:** A variety of laparoscopic procedures for the repair of abdominal wall hernias have been described. The repair described in this paper represents a modification and improvement of one approach.

**Methods:** Our technique employs an Origin Tacker (Origin Medsystems, Inc, Menlo Park, CA) and a Gore suture passer (W. L. Gore, Flagstaff, AZ) to secure an expanded polytetrafluoroethylene (ePTFE) patch, (DualMesh, W. L. Gore, Flagstaff, AZ) to the anterior abdominal wall.

**Results:** This approach simplifies the repair by minimizing the number of steps required to secure the ePTFE graft to the anterior abdominal.

**Conclusions:** We have found this to be a safe and reliable technique that may be used in the laparoscopic repair of ventral, umbilical, or inguinal hernias.

**Key Words:** Hernia, ePTFE mesh, Laparoscopic.

## INTRODUCTION

Improvement in both technology and surgical technique have revolutionized the repair of abdominal wall hernias. Among the most popular techniques for repairing ventral abdominal wall hernias is the transperitoneal laparoscopic repair using expanded polytetrafluoroethylene (ePTFE) mesh patches. This approach is a modification of techniques widely used for repairing inguinal hernias.<sup>1,2</sup> This manuscript describes an advancement upon the techniques reported by LeBlanc and Booth<sup>3</sup> as modified by Dr. Guy Voeller from Memphis, Tennessee, and by Tagaya et al.<sup>4</sup> Our technique addresses the persistent problems of obtaining adequate expansion of the mesh around the entire hernia defect and of simplifying attachment of the mesh to the abdominal wall.

## METHODS

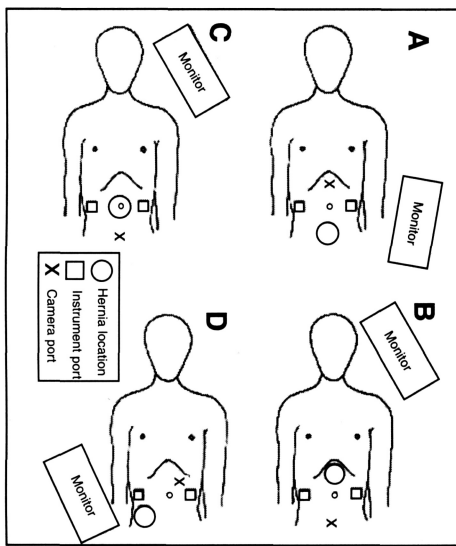
With the patient under general anesthesia, the abdomen is insufflated with CO<sub>2</sub> in a standard fashion. The location and number of laparoscopic ports is individualized according to the size and location of the hernia (**Figure 1**). It is important to place the camera on the side of the umbilicus opposite the hernia and to place the monitor directly facing the surgeon. Aligning surgeon, camera, instrument ports, hernia and monitor in that order maintains proper orientation of anatomy and instrument movement on the monitor. It is important, also, to place the working ports sufficiently far from the edges of the defect to facilitate manipulation of the mesh. Particularly for mid-abdominal defects this requires that port sites be placed as laterally as possible.

After defining the anatomy of the hernia, any incarcerated viscera are reduced. The borders of the defect are marked on the abdominal wall with a marking pen by palpating the edges of the defect. A piece of DualMesh (W. L. Gore, Flagstaff, AZ) of appropriate size is selected and cut to correspond to the size of the abdominal wall defect. The smooth side is marked with a standard skin crayon to assure that it will be placed facing the viscera. The mesh is rolled longitudinally and placed through an established port. The pneumoperitoneum is reestablished and, using graspers, the mesh is unfurled on top of the viscera with the smooth side facing the viscera.

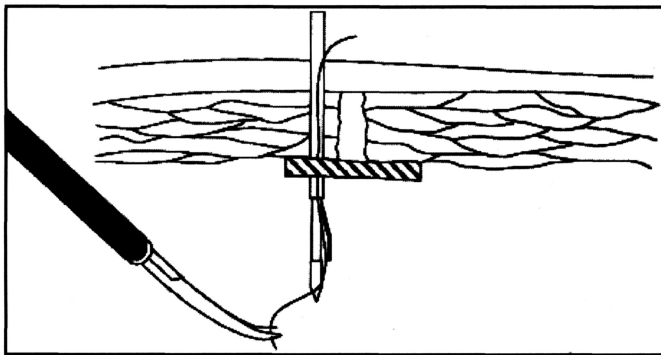
The mesh is anchored to the abdominal wall with at least three cm extending beyond the defect in all dimensions. This approximation is performed using the Origin Tacker (Origin Medsystems, Inc, Menlo Park, CA) starting on the

Department of Surgery, Sinai Hospital, Detroit, MI.

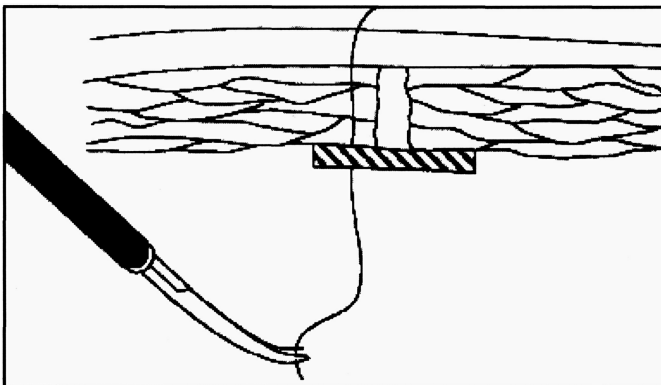
Address reprint request to: Andrew Saxe, MD, Department of Surgery, Sinai Hospital, 6767 West Outer Drive, Detroit, MI 48235, USA. Telephone: (313) 493-6394, Fax: (313) 493-7526



**Figure 1.** Positioning of camera, ports, and monitors for abdominal wall hernias (a) below the umbilicus, (b) above the umbilicus, (c) at the umbilicus, and (d) in the lateral abdominal wall.



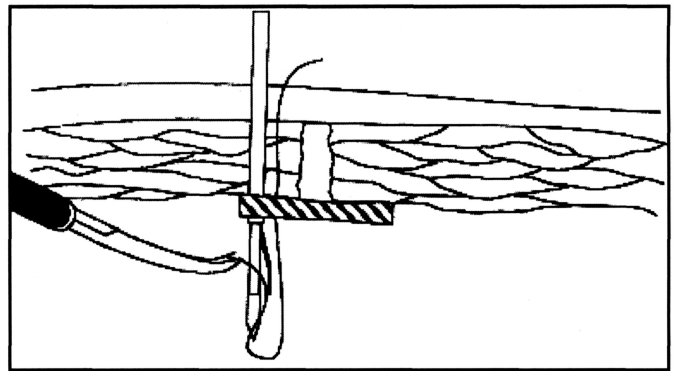
**Figure 2.** A suture passer has introduced a 0-Neurolon strand through the abdominal wall and mesh.



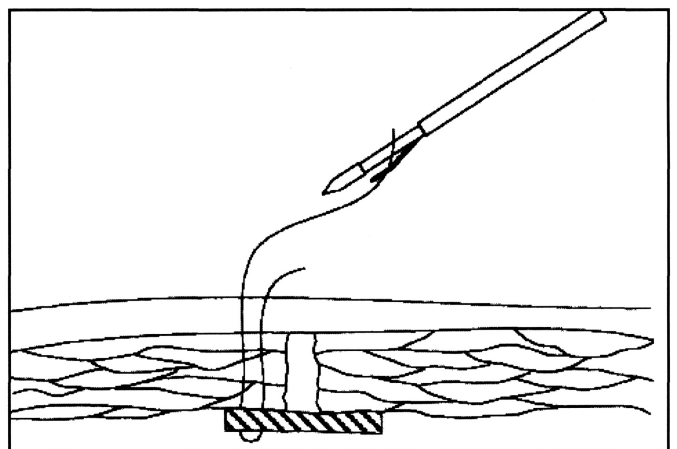
**Figure 3.** The suture has been grasped to permit removal of the suture passer.

side of the defect farthest away from the surgeon and progressing circumferentially toward the surgeon.

With the mesh splayed out and covering the defect, it is secured to the abdominal wall using the following technique. Four 2 mm skin punctures are made with a number 11 scalpel blade at sites that correspond to the edges of the mesh. Through these sites the Gore suture passer (W. L. Gore, Flagstaff, AZ) is placed through both the abdominal



**Figure 4.** An empty suture passer has been reintroduced through the same skin incision but through a different portion of the mesh. The end of the previously placed suture is fed into the empty suture passer.



**Figure 5.** The suture has been retrieved and will be tied in the subcutaneous tissue.

wall and the mesh with a 0-Neurolon (Ethicon, Somerville NJ) suture attached (**Figure 2**). An assistant grasps the suture to keep it in the abdominal cavity and the suture passer is withdrawn (**Figure 3**). The suture passer (without suture) is reintroduced through the same skin incision but through a different portion of the mesh to enter the peritoneal cavity (**Figure 4**). The free suture is grasped in the suture passer and withdrawn through the abdominal wall. The suture is tied in the subcutaneum to fashion a mattress suture (**Figure 5**).

## DISCUSSION

The technique we have described incorporates the use of a mesh we believe to be the best currently available and an improved method of securing the mesh. We believe that fixing the mesh to the abdominal wall in a circumferential fashion from distal to proximal before suturing the mesh establishes proper tension on the mesh. Substituting the Gore suture passer to place four or five sutures for multiple passes with Keith needles<sup>2</sup> with the attendant confusion of loose sutures within the abdominal cavity, simplifies securing the mesh in proper position.

## References:

1. Arregui ME, Navarrete J, Davis CJ, Castro D, Nagan RF. Laparoscopic inguinal herniorrhaphy. Techniques and controversies. *Surg Clin North Am.* 1993;73:513-527.
2. Rosenthal D, Franklin ME. Use of percutaneous stitches in laparoscopic mesh hernioplasty. *Surg Gynecol Obstet.* 1993;176:491-492.
3. LeBlanc KA, Booth WV. Laparoscopic repair of incisional abdominal hernias using expanded polytetrafluoroethylene: preliminary findings. *Surg Laparosc Endosc.* 1993;3:39-41.
4. Tagaya N, Milami H, Kogure H, Ohyama O. Laparoscopic repair of an abdominal hernia using an expanded polytetrafluoroethylene patch secured by a four-corner tacking technique. *Surgery Today.* 1995;25:930-931.